

# **PATHOLOGY OF AIDS**

**Version 26**

**by**

**Edward C. Klatt, MD**

**Mercer University  
School of Medicine  
Savannah**

**May 14, 2015**

**Copyright © by Edward C. Klatt, MD  
All rights reserved worldwide**

## **Dedication**

**To persons living with HIV/AIDS past, present, and future who provide the knowledge, to researchers who utilize the knowledge, to health care workers who apply the knowledge, and to public officials who do their best to promote the health of their citizens with the knowledge of the biology, pathophysiology, treatment, and prevention of HIV/AIDS.**

## **TABLE OF CONTENTS**

<b>CHAPTER 1 - HUMAN IMMUNODEFICIENCY VIRUS</b>	<b>6</b>
<b>INTRODUCTION</b>	<b>6</b>
<b>BIOLOGY OF HUMAN IMMUNODEFICIENCY VIRUS</b>	<b>8</b>
<b>HUMAN IMMUNODEFICIENCY VIRUS SUBTYPES</b>	<b>22</b>
<b>OTHER HUMAN RETROVIRUSES</b>	<b>25</b>
<b>EPIDEMIOLOGY OF AIDS</b>	<b>29</b>
<b>RISK GROUPS FOR HUMAN IMMUNODEFICIENCY VIRUS INFECTION</b>	<b>37</b>
<b>NATURAL HISTORY OF HIV INFECTION</b>	<b>38</b>
<b>PROGRESSION OF HIV INFECTION</b>	<b>42</b>
<b>IDIOPATHIC CD4+ T-LYMPHOCYTOPENIA</b>	<b>47</b>
<b>PREVENTION OF HIV TRANSMISSION</b>	<b>48</b>
<b>TREATMENT FOR HIV/AIDS</b>	<b>50</b>
<b>CHAPTER 2 - DIAGNOSIS OF AIDS</b>	<b>66</b>
<b>DIAGNOSTIC TESTS FOR HUMAN IMMUNODEFICIENCY VIRUS</b>	<b>66</b>
<b>PEDIATRIC HIV INFECTION AND AIDS</b>	<b>88</b>
<b>CRITERIA FOR AIDS-RELATED COMPLEX</b>	<b>92</b>
<b>OTHER CAUSES OF IMMUNOSUPPRESSION</b>	<b>93</b>
<b>CHAPTER 3 - OPPORTUNISTIC INFECTIONS IN AIDS</b>	<b>94</b>
<b>PNEUMOCYSTIS JIROVECI INFECTIONS</b>	<b>94</b>
<b>CYTOMEGALOVIRUS INFECTIONS</b>	<b>98</b>
<b>MYCOBACTERIAL INFECTIONS</b>	<b>100</b>
<b>CRYPTOCOCCUS NEOFORMANS INFECTIONS</b>	<b>108</b>
<b>HERPESVIRUS INFECTIONS</b>	<b>111</b>

<b>CANDIDA INFECTIONS</b>	<b>115</b>
<b>TOXOPLASMA GONDII INFECTIONS</b>	<b>118</b>
<b>HISTOPLASMA CAPSULATUM INFECTIONS</b>	<b>120</b>
<b>COCCIDIOIDES IMMITIS INFECTIONS</b>	<b>122</b>
<b>GASTROINTESTINAL PROTOZOAL INFECTIONS</b>	<b>124</b>
<b>BACTERIAL INFECTIONS SEEN WITH AIDS</b>	<b>127</b>
<b>CHAPTER 4 - NEOPLASMS ASSOCIATED WITH AIDS</b>	<b>137</b>
<b>KAPOSI SARCOMA</b>	<b>137</b>
<b>MALIGNANT LYMPHOMAS</b>	<b>140</b>
<b>OTHER NEOPLASMS</b>	<b>146</b>
<b>CHAPTER 5 - ORGAN SYSTEM PATHOLOGY IN AIDS</b>	<b>149</b>
<b>RESPIRATORY TRACT PATHOLOGY IN AIDS</b>	<b>149</b>
<b>GASTROINTESTINAL TRACT PATHOLOGY IN AIDS</b>	<b>169</b>
<b>CENTRAL NERVOUS SYSTEM PATHOLOGY IN AIDS</b>	<b>188</b>
<b>PERIPHERAL NERVE AND MUSCLE PATHOLOGY IN AIDS</b>	<b>206</b>
<b>OPHTHALMIC PATHOLOGY IN AIDS</b>	<b>213</b>
<b>LYMPH NODE PATHOLOGY IN AIDS</b>	<b>217</b>
<b>BONE MARROW AND PERIPHERAL BLOOD IN AIDS</b>	<b>224</b>
<b>THYMUS IN AIDS</b>	<b>229</b>
<b>ENDOCRINE ORGAN PATHOLOGY IN AIDS</b>	<b>231</b>
<b>HEPATOBIILIARY SYSTEM PATHOLOGY IN AIDS</b>	<b>234</b>
<b>CARDIOVASCULAR PATHOLOGY IN AIDS</b>	<b>241</b>
<b>GENITOURINARY PATHOLOGY IN AIDS</b>	<b>246</b>
<b>DERMATOPATHOLOGY IN AIDS</b>	<b>254</b>
<b>PANCREAS IN AIDS</b>	<b>268</b>

<b>PREGNANCY AND THE PLACENTA IN AIDS</b>	<b>270</b>
<b>HEAD AND NECK PATHOLOGY IN AIDS</b>	<b>271</b>
<b>BONE, JOINT, AND SOFT TISSUE PATHOLOGY IN AIDS</b>	<b>273</b>
<b>CYTOPATHOLOGY IN AIDS</b>	<b>276</b>
<b>PEDIATRIC AIDS</b>	<b>277</b>
<b>CHAPTER 6 - SAFETY PROCEDURES WITH AIDS</b>	<b>283</b>
<b>EDUCATIONAL GOALS</b>	<b>283</b>
<b>UNIVERSAL PRECAUTIONS</b>	<b>284</b>
<b>OSHA REGULATIONS</b>	<b>285</b>
<b>OCCUPATIONAL AND NON-OCCUPATIONAL HIV EXPOSURES</b>	<b>290</b>
<b>INVASIVE AND SURGICAL PROCEDURES</b>	<b>293</b>
<b>THE SURGICAL PATHOLOGY LABORATORY</b>	<b>295</b>
<b>THE AIDS AUTOPSY</b>	<b>296</b>
<b>MORTUARY AND FORENSIC LABORATORY PROCEDURES</b>	<b>297</b>
<b>ATHLETICS AND HIV INFECTION</b>	<b>299</b>
<b>CHAPTER 7 - MEDICOLEGAL ISSUES AND AIDS</b>	<b>302</b>
<b>DEATH INVESTIGATION AND CERTIFICATION IN AIDS</b>	<b>302</b>
<b>DETERMINATION OF CAUSE AND MODE OF DEATH WITH HIV INFECTION</b>	<b>302</b>
<b>ETHICAL ISSUES ARISING FROM THE AIDS PANDEMIC</b>	<b>305</b>
<b>HIV TESTING AND COUNSELING</b>	<b>307</b>
<b>BLOOD AND TISSUE BANKING AND AIDS</b>	<b>309</b>
<b>TABLES 1 - 10</b>	<b>312</b>
<b>REFERENCES</b>	<b>322</b>

## CHAPTER 1 - HUMAN IMMUNODEFICIENCY VIRUS

### INTRODUCTION

The human immunodeficiency virus (HIV) was unknown until the early 1980's but since then has infected millions of persons in a worldwide pandemic. The result of HIV infection is relentless destruction of the immune system leading to onset of the acquired immunodeficiency syndrome (AIDS). The AIDS pandemic has already resulted in the deaths of over half its victims. All HIV-infected persons are at risk for illness and death from opportunistic infectious and neoplastic complications because of the inevitable manifestations of AIDS.[1,2]

Once HIV infection became established in humans, the spread of HIV has been driven by multiple factors. The advent of quick air travel in the 20<sup>th</sup> century provided a means for spread not present in past human pandemics. Urbanization has led to increased numbers of persons at risk in close proximity. Human sexual practices with promiscuity have included a larger number of persons in populations around the world. A practical and easily available means for delivery of drugs of abuse through injection became more widespread in the 20<sup>th</sup> century.[2]

The AIDS pandemic has evolved over time, with four main phases of evolution. In the initial phase, HIV emerged from endemic rural areas to spread among urban populations at an accelerating rate. In the second phase, dissemination occurred and involved definable risk groups. Behaviors in these risk groups, including sexual promiscuity and injection drug use, led to the third phase of escalation, which occurred through the 1980's. A fourth phase of stabilization has occurred in some regions such as western Europe, North America, and Australia, where control measures appear to be having a positive effect. However, some regions such as central Africa and Asia continued to experience escalation of the pandemic through the 1990's and into the 21<sup>st</sup> century.[3,4]

Although the HIV infection rate in the United States increased rapidly in the 1980's, peaked in the 1990's, and has declined since, the reservoir of HIV-infected persons developing AIDS and requiring therapy continued to increase through the 1990's and into the 21<sup>st</sup> century. At the end of 2008, nearly 1.2 million persons were living with HIV in the U.S., including almost 0.25 million whose infection was undiagnosed.[5,6] Globally, the incidence of new HIV infections probably peaked in 1997. At the end of the 20<sup>th</sup> century, over 21 million persons worldwide had died from AIDS, over 34 million were living with HIV infection, and over 95% of HIV infected persons resided in developing nations. Nine countries in southern Africa, with 2% of the world's population, accounted for a third of all HIV-infected persons.[7]

At the start of the 21<sup>st</sup> century, the prevalence of HIV infection stabilized at about 0.8%. The age group most affected, young persons from 15 to 24 years of age, accounted for 45% of new HIV infections. Worldwide, over half the victims of AIDS are women, and a consequence of this is perinatal infection resulting in a significant number of children born with HIV infection. The scope of the AIDS pandemic has already led to serious consequences, not only for health care systems of countries unable to cope with many AIDS victims, but also for the national economies of those countries because of the loss of young to middle aged who are economically most productive.[8]

There were an estimated 300,000 deaths from AIDS in 1990. Deaths from AIDS peaked worldwide in 2006, at 1.7 million deaths. In 2010, the 1.5 million estimated deaths from AIDS

represented 2.8% of the 52.8 million worldwide deaths in that year.. AIDS was the sixth leading cause of years of useful life lost (YLL) worldwide in 2010.[9]

Costs for detection, diagnosis, and treatment are considerable when effective therapies for persons with complications of HIV infection are instituted to prolong survival. In the 1990's in the U.S., the average cost for medical care of an HIV-infected patient was double the average income for half of all such patients.[10] Though the pharmacologic therapies exist for prolonging the lives of persons infected with HIV, such therapies are expensive and out-of-reach for many persons worldwide. The years of useful life lost by the predominantly younger population infected by HIV has a serious economic impact.[11] In the era of antiretroviral therapy in the U.S. the average life expectancy for persons diagnosed with HIV infection increased from 10.5 years in 1996 to 22.5 years in 2005.[12]

According to the United Nations Development Program, when the prevalence of AIDS reaches 1% of the adult population, the pandemic will become difficult to constrain or reverse unless drastic and effective measures are taken.[13] In Eastern Europe, Asia, and Africa governmental responses to the spread of HIV have often been delayed and haphazard. One notable exception has been Thailand, which mounted a countrywide campaign to educate and screen its population. When less than 5% of adult men visit commercial sex workers, or barrier precaution use is high, and rates of injection drug use remain low, then the spread of HIV remains low.[14]

Targeting high risk groups with educational campaigns, increasing condom use, male circumcision, reducing sexually transmitted diseases, increasing the availability of antiretroviral drugs, and needle-exchange programs for injection drug users have shown success in reducing or stabilizing rates of HIV infection. Treatment programs for those with AIDS are expensive and difficult to administer. Brazil has had success in reducing health care costs of HIV infection with use of more widely available antiretroviral drugs. Some pharmaceutical manufacturers have agreed to subsidize the costs, or allowed generic production of antiretroviral agents, lessening therapy to about 1\$ U.S. per day, but the numbers of infected persons make treatment an expensive option for many countries. Lack of resources for health care has limited budgets to deal with HIV when other health problems loomed large.[7,8,15]

Considerable effort has been placed into education of persons potentially at risk for acquiring HIV.[16] A proper understanding of AIDS issues, including the nature of HIV and its means of spread, should precede decisions regarding allocation of health care resources and control measures.[17] Prevention strategies for HIV will require ongoing education, despite a general public perception, particularly among young persons, that AIDS is a peripheral threat that does not call for changes in lifestyle. The battle against AIDS will require political alliances that allow prevention strategies to be implemented across national borders. The reservoir of infected persons is so large, global human interaction so broad, and costs of AIDS so high that everyone on earth is affected in some way by the AIDS pandemic.[18,19] Prevention strategies can include the following:[20]

- Make HIV testing a routine part of medical care.
- Implement new models for diagnosing HIV infections outside medical settings.
- Prevent new infections by working with persons diagnosed with HIV and their partners.
- Provide antiretroviral drugs to infected persons who need them
- Further decrease perinatal HIV transmission.

## BIOLOGY OF HUMAN IMMUNODEFICIENCY VIRUS

Human immunodeficiency virus (HIV) and its subtypes are retroviruses, and they are the etiologic agents of AIDS. Human retroviruses were unknown until the 1980's, though animal retroviruses such as feline leukemia virus had been detected previously. HIV belongs to a large family of ribonucleic acid (RNA) lentiviruses that are characterized by association with diseases of immunosuppression or central nervous system involvement and with long incubation periods following infection before manifestations of illness become apparent.[21,22]

**ORIGINS OF HIV.--** Lentiviruses similar to HIV have been found in a variety of primate species, and some of these are associated with a disease process called simian AIDS. Unlike other retroviruses, the primate lentiviruses are not transmitted through the germ line, and no endogenous copies of the virus exist in the genome of susceptible species.[23] Molecular epidemiologic data suggest that HIV type 1 (HIV-1), the most common subtype of HIV that infects humans, has been derived from the simian immunodeficiency virus, called SIVcpz, of the *Pan troglodytes troglodytes* subspecies of chimpanzee. The lentivirus strain SIVcpz is highly homologous with HIV-1, and another form of simian immunodeficiency virus found in sooty mangabeys (SIVsm) has similarities as well and likely gave rise to HIV-2.[24]

There are HIV-1 four subtypes of HIV-1 called groups M, N, O, and P, and each of these groups appears to have arisen from an independent cross-species transmission event. Group M is the pandemic form of HIV-1 that has spread widely to infect millions of persons worldwide. There is molecular epidemiologic evidence for multiple cross-species transmissions of SIVcpz to humans occurring in the first half of the 20<sup>th</sup> century to establish group M, likely between the years 1910 and 1930. Based on the biology of these retroviruses, transmission to humans likely occurred through cutaneous or mucous membrane exposure to infected primate blood and/or body fluids. Such exposures occur most commonly in the context of hunting. Group O was discovered in 1990 and represents less than 1% of global HIV-1 infections; it is mainly in Cameroon, Gabon, and neighboring. Group N was identified in 1998 and so far, only 13 cases have been documented, all in persons living in Cameroon. Group P was discovered in 2009 in two persons from Cameroon.[25]

One additional major human retrovirus, called HIV-2, has more similarity to simian immunodeficiency virus (SIV) than to HIV-1. HIV-2 is mostly found in West Africa, with its highest prevalence rates recorded in Guinea-Bissau and Senegal.[25]

Zoonotic infection of man with retroviruses is possible, as documented by infection of primate handlers with simian foamy retroviruses.[26] There is evidence for ongoing cross-species transmission, supporting the concept of prior transmissions of SIV to humans.[27] Retrospective studies performed on frozen sera have shown evidence for HIV in patients in Africa prior to 1960.[28] Reports in the early 1980's referred to the agent causing AIDS as either human T-lymphocytotropic virus, type III (HTLV-III) or as lymphadenopathy associated virus (LAV). This originally discovered virus is known as HIV-1.[29,30]

Zoonotic infection of humans may have occurred long in the past, but only in the late 20<sup>th</sup> century did demographic and social conditions change significantly to permit HIV to spread more rapidly. European colonization of Africa led to growth in the population of cities, many of which had a disparate demography with more men than women, favoring greater sexual interactions with more partners. In addition, colonial health programs included measures to try

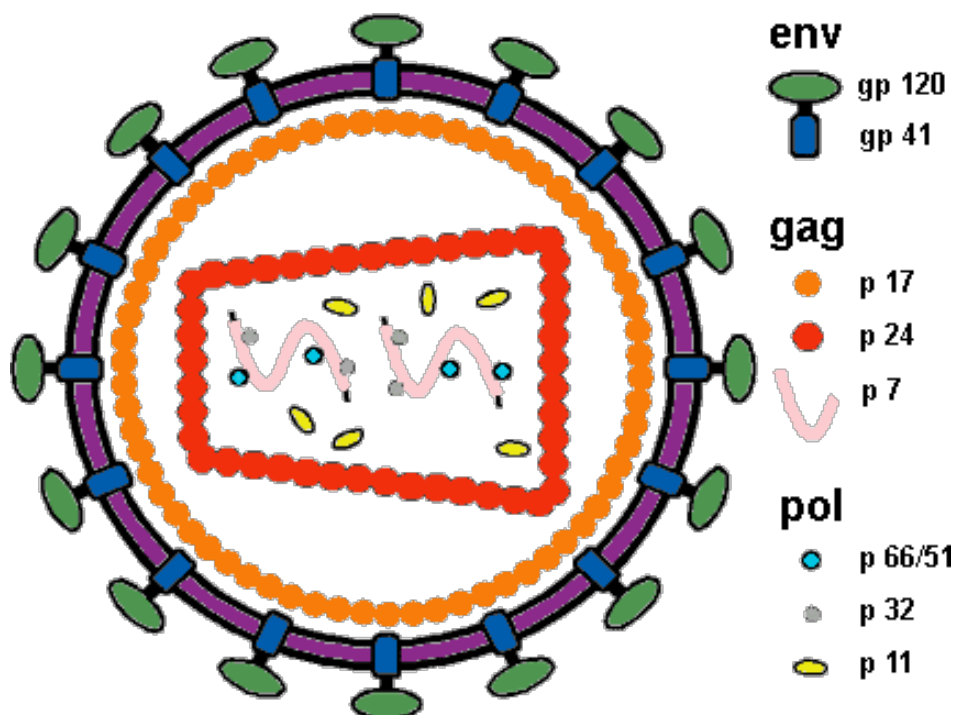


and control tropical diseases, doing so via intravenous injections of medications, often without adequate cleansing of injection equipment such as needles. Additional viral diseases transmitted via contaminated injections included hepatitis B virus, hepatitis C virus, and human lymphocytotropic virus type I. Parenteral transmission may have expanded the range and number of HIV infections during the 1950's, followed by expansion through heterosexual transmission in the 1960's, followed by spread to other countries with expanded availability of travel opportunities from the 1970's onward.[31]

**STRUCTURE OF HIV.**-- The mature virus consists of a bar-shaped electron dense core containing the viral genome--two short strands of ribonucleic acid (RNA) about 9200 nucleotide bases long--along with the enzymes reverse transcriptase, protease, ribonuclease, and integrase, all encased in an outer lipid envelope derived from a host cell. This envelope has 72 surface projections, or spikes, containing an antigen, gp120 that aids in the binding of the virus to the target cells with CD4 receptors. A second glycoprotein, gp41, binds gp120 to the lipid envelope.[22,32,33]

By electron microscopy, the plasma membrane of an infected CD4+ lymphocyte exhibits budding virus particles approximately 100 nanometers in diameter. The virion has an asymmetric core consisting of a conical capsid (a geometric “fullerine cone”) with a broad electron dense base and hollow tapered end. Virions bud from plasma membranes or from cytoplasmic vacuoles of infected host cells. Spikes are inserted onto the membrane of the developing virion, which buds to a complete sphere. Aberrant virion formation is common, including double buds, giant virions, empty nucleoids, and misplaced electron dense material. Simplistic organisms such as lentiviruses just do not have the error checking genetic equipment for quality assurance, but make up for it with sheer numbers of particles released.[33,34]

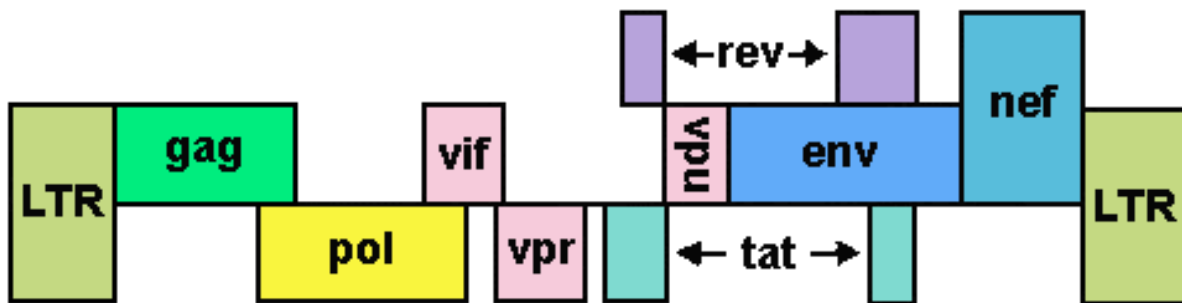
A diagrammatic representation of HIV is shown below:



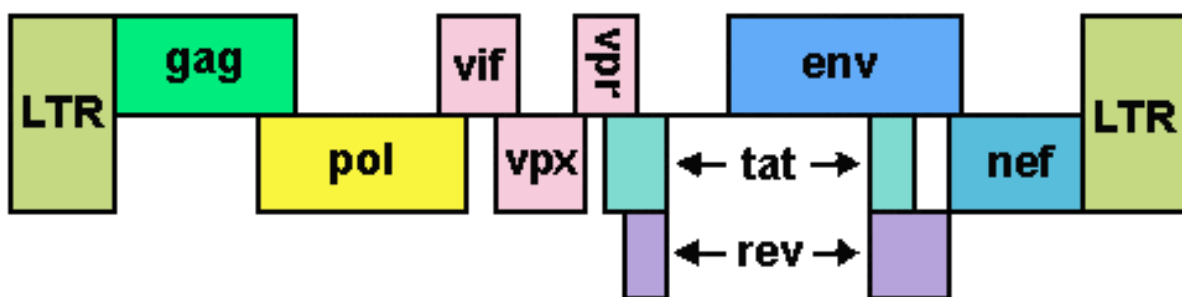
The genome of HIV, similar to retroviruses in general, contains three major genes--*gag*, *pol*, and *env*. These genes code for the major structural and functional components of HIV, including envelope proteins and reverse transcriptase. The structural components encoded by *env* include the envelope glycoproteins: outer envelope glycoprotein gp120 and transmembrane glycoprotein gp41 derived from glycoprotein precursor gp160. Components encoded by the *gag* gene include core nucleocapsid proteins p55 (a precursor protein), p40, p24 (capsid, or "core" antigen), p17 (matrix), and p7 (nucleocapsid); the important proteins encoded by *pol* are the enzyme proteins p66 and p51 (reverse transcriptase), p11 (protease), and p32 (integrase). [22,32,33]

Although most of the major HIV viral proteins, which include p24 (core antigen) and gp41 (envelope antigen), are highly immunogenic, the antibody responses vary according to the virus load and the immune competence of the host. The antigenicity of these various components provides a means for detection of antibody, the basis for most HIV testing.[35]

The viral genome for HIV-1 is shown below:



The viral genome for HIV-2 is shown below:



Accessory genes carried by HIV include *tat*, *rev*, *nef*, *vif*, *vpr*, and *vpu* (for HIV-1) or *vpx* (for HIV-2). The *rev* gene encodes for a regulatory protein which switches the processing of viral RNA transcripts to a pattern that predominates with established infection, leading to

production of viral structural and enzymatic proteins. The long terminal repeat (LTR) serves as a promoter of transcription.[22,30,32,33]

The *tat* (trans-activator of transcription) gene plays multiple roles in HIV pathogenesis. It produces a regulatory protein that speeds up transcription of the HIV provirus to full-length viral mRNAs. It functions in transactivation of viral genes. In addition, *tat* modulates host cell gene expression. The effects of such modulation may include enhanced immune suppression, apoptosis, and oxidative stress.[36]

The *nef* (negative factor) gene produces a regulatory protein that modifies the infected cell to make it more suitable for producing HIV virions, by accelerating endocytosis of CD4 from the surface of infected cells. The *vif*, *vpr*, and *vpu* genes encode proteins that appear to play a role in generating infectivity and pathologic effects. *Vif*, *vpu*, and *vpr* protein products link to members of a superfamily of modular ubiquitin ligases to induce the polyubiquitylation and proteasomal degradation of their cellular targets. More specifically, *vpr* (viral protein r) has the ability to delay or arrest infected cells in the G2 / M phase of the cell cycle and facilitates infection of macrophages, and it promotes nuclear transport of the viral preintegration complex. *Vif* antagonizes the antiviral effect of apolipoprotein B mRNA-editing enzyme catalytic polypeptide-like 3G, or the protein product of the gene *APOBEC3G* (*A3G*). *Vpu* enhances efficient release of virions from infected cells.[37]

**PATHOGENESIS OF HIV INFECTION.**-- Retroviruses are unable to replicate outside of living host cells and do not contain deoxyribonucleic acid (DNA). The pathogenesis of HIV infection is a function of the virus life cycle, host cellular environment, and quantity of viruses in the infected individual. After entering the body, the viral particle is attracted to a cell with the appropriate CD4 receptor molecules where it attaches by fusion to a susceptible cell membrane or by endocytosis and then enters the cell. The probability of infection is a function of both the number of infective HIV virions in the body fluid which contacts the host as well as the number of cells available at the site of contact that have appropriate CD4 receptors.[33]

HIV infection can occur through oropharyngeal, cervical, vaginal, and gastrointestinal mucosal surfaces, even in the absence of mucosal disruption. Routes of HIV entry into mucosal lamina propria include dendritic cells, epithelial cells, and microfold (M) cells. Dendritic cells can bind to gp120 through a C type lectin, suggesting that dendritic cells that squeeze between "tight" epithelium may capture HIV and deliver it to underlying T cells, resulting in dissemination to lymphoid organs. HIV can cross a tight epithelial barrier by transcytosis during contact between HIV-infected cells and the apical surface of an epithelial cell. The presence of mucus on epithelial surfaces further retards viral entry, particularly in the endocervix where there is just a single columnar epithelial cell layer.[38,39]

HIV can transmigrate across fetal oral mucosal squamous epithelium that has few layers, 5 or less. HIV-infected macrophages, but not lymphocytes, are able to transmigrate across fetal oral epithelia. HIV-infected macrophages and, to a lesser extent, lymphocytes can transmigrate across fetal intestinal epithelia. However, efficient viral transmission through adult mucosal epithelia is difficult because of a mechanical barrier of stratified epithelia with tight junctions that prevent penetration of virions into the deeper layers of the epithelium, and from expression of the anti-HIV innate proteins HBD2, HBD3, and SLPI that inactivate virions.[40]

Transcytosis of virions through intact epithelium is favored via surface expression of syndecans and chemokine receptors by epithelial cells. However, the efficiency of transcytosis is poor, with only 0.02% of the original inoculum of HIV able to navigate across genital

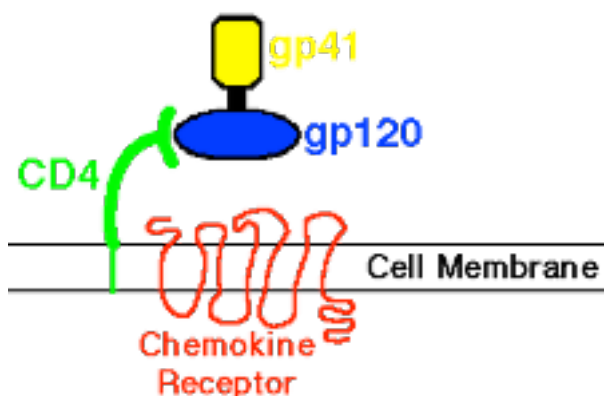
epithelium. Thus, intact epithelium is a significant barrier to HIV infection, but the presence of antigen processing cells and inflammatory cells increases HIV transmission.[41] Exposure to HIV-1 can upregulate pro-inflammatory cytokine production by genital epithelial cells, including tumor necrosis factor (TNF)- $\alpha$  that impairs the tight junction barrier, allowing HIV-1 and luminal bacteria to translocate across the epithelium.[42]

Endothelium may also harbor HIV virions following parenteral transmission and during HIV viremia following infection. Endothelial cells express surface syndecans that mediate adsorption of HIV by binding of viral gp120 to heparan sulfate chains of syndecan. Although syndecan does not substitute for HIV entry receptors, it enhances infectivity and preserves virus infectivity for a week, whereas unbound virus loses its infectivity in less than a day. In addition, the ligand for E-selection (CD62L) is incorporated into the virion during budding and can enhance virion attachment to endothelial cells and accelerate transfer of HIV to CD4 cells.[43]

HIV primarily infects cells that have CD4 cell-surface receptor molecules, using these receptors to gain entry. Many cell types share common receptor epitopes, though CD4 lymphocytes play a crucial role. Cells with CD4 receptors susceptible to HIV infection may include cells of the mononuclear phagocyte system, principally blood monocytes and tissue macrophages, as well as T lymphocytes, natural killer (NK) lymphocytes, dendritic cells (epithelial Langerhans cells and follicular dendritic cells in lymph nodes), hematopoietic stromal cells, and microglial cells in brain. Galactosylceramide expressed by human monocyte derived immature dendritic cells as well as dendritic cells isolated from blood and mucosal tissue and in situ on mucosal tissue can act as a mucosal epithelial receptor for gp41 on HIV.[22,44,45]

HIV entry into cells can occur independently of CD4 receptor interaction. Such entry is less efficient and less extensive. Such entry has been described for renal tubules, gut enterocytes, vascular endothelium, cardiac myocytes, and astrocytes. Infection of these cells may play a role in the pathogenesis of HIV-related diseases occurring at tissue sites with those cells.[46]

In addition to the CD4 receptor, a coreceptor known as a chemokine enables HIV entry into cells. Chemokines are cell surface membrane-bound fusion-mediating molecules found on many cells. A diagrammatic representation of the relationship of the chemokine receptor to the CD4 receptor is shown below:



HIV entry into a host cell begins with gp120 binding to CD4 receptor, which induces a conformational change in gp120, exposing coreceptor binding sites. The V3 loop region of

gp120 determines whether the host cell CCR5 or CXCR4 chemokine coreceptor will be engaged. After the chemokine coreceptor is engaged, the gp41 on the HIV surface undergoes a conformational change. The gp41 transmembrane coreceptor consists of HR1 and HR2 helical regions along with a fusion peptide. Conformational change in gp41 through HR1 and HR2 interaction leads to formation of a stable structure that allows fusion of HIV and host cell membranes, with a fusion pore through which the viral core enters the host cell. These cores can utilize host cell microtubules to move toward the cell nucleus.[47,48]

The chemokine coreceptors include the CXC family (CXCR1 to CXCR5) and the CC family (CCR1 to CCR9). Their presence on cells can aid binding of the HIV envelope glycoprotein gp120, promoting infection. Initial binding of HIV to the CD4 receptor is mediated by conformational changes in the gp120 subunit, but such conformational changes are not sufficient for fusion. The chemokine receptors produce a conformational change in the gp41 subunit of HIV, which allows fusion of HIV.[49]

The differences in chemokine coreceptors that are present on a cell also explain how different strains of HIV may infect cells selectively. There are strains of HIV known as T-tropic strains, which selectively interact with the CXCR4 ("X4") chemokine coreceptor to infect lymphocytes. The M-tropic strains of HIV interact with the CCR5 ("R5") chemokine coreceptor, and also CCR2 and CCR3, to infect macrophages and dendritic cells. CCR8 has been identified as a cofactor to permit infection by either T-cell tropic or by M-tropic strains of HIV. Dual tropic HIV strains have been identified that can use more than one chemokine coreceptor.[49]

Over time, mutations in HIV may increase the ability of the virus to infect cells via these routes, beginning with dominance of CCR5 tropic strains of virus, then CCR5/CXCR4 dual tropic virus, and finally the more cytopathic CXCR4 tropic strain predominance. CCR5 tropic virus predominates early in HIV infection because it more readily infects dendritic cells and macrophages, has a high rate of replication, and is less visible to cytotoxic lymphocytes.[30] The gastrointestinal tract is a preferential site for HIV infection because most CD4 cells at that location are expressing CCR5,[50]

The presence of chemokine coreceptor mutations may explain the phenomenon of resistance to HIV infection in some persons. Four mutational chemokine variants, including CCR5-delta32, CCR2-64I, CCR5-P1, and a primary ligand of CXCR4 known as SDF-1-3'A, have been discovered. These variants may impart resistance to HIV-1 infection and explain differences in infectivity within and among populations.[51]

Cellular localization of chemokine receptors may help explain how HIV infection can occur. Macrophages and monocytes, as well as subpopulations of lymphocytes, can express the CCR5 receptor. Neurons, astrocytes, and microglia in the central nervous system also express this chemokine receptor. In other tissues, CCR5 is expressed on epithelium, endothelium, vascular smooth muscle, and fibroblasts. Areas of inflammation contain increased numbers of mononuclear cells with CCR5, and this may facilitate transmission of HIV at those sites.[52]

Many virions are nonspecifically endocytosed on host cells and never enter the cytoplasm. The interplay of CD4 and CCR5 receptors with viral proteins for entry is enhanced by localization of cell surface receptors within cell membrane cholesterol rich lipid rafts that provide lateral mobility and mediate fusion. Fusion requires formation of membrane pores. After gaining entry to the host cell, virions can use microtubules for movement to a perinuclear location. Once within the nucleus HIV integrase localizes to areas of euchromatin.[53]

Once within the cell, the viral particle uncoats from its spherical envelope to release its RNA. This "plus sense" RNA requires reverse transcription followed by DNA integration. The

enzyme product of the *pol* gene, a reverse transcriptase that is bound to the HIV RNA, synthesizes linear double-stranded cDNA that is the template for HIV integrase. It is this HIV proviral DNA which is then inserted into the host cell genomic DNA by the integrase enzyme of the HIV. The integrase catalyses an initial 3' processing of the nascent cDNA ends, followed in the cell nucleus by their covalent attachment to the 5' phosphates of a double-stranded staggered cut in chromosomal DNA. Proviral DNA is activated and transcribed under direction of HIV *tat* and *rev* genes. Viral components such as Gag proteins are assembled at the inner part of the host cell membrane, and virions then begin to bud off. During the budding process, HIV protease cleaves viral proteins into their functional forms.[35,54,55,56]

The principal constituent of HIV-1 is Gag, accounting for half the entire virion mass. Viral membrane lipids account for about a third of the mass, and other viral and cellular proteins together contribute an additional 20%. The HIV-1 genomic RNA and other small RNAs comprise only 2.5% of virion mass. The Gag, Gag-Pro-Pol, Env, the two copies of genomic RNA, the tRNA primer, and the lipid envelope are all necessary for viral replication. HIV gene products are encoded on the genomic RNA, which also serves as mRNA for Gag and Gag-Pro-Pol, whereas singly or multiply spliced RNAs are translated to produce Env and accessory proteins, respectively. The HIV Gag and Gag-Pro-Pol proteins move from cytoplasmic sites of synthesis to the infected cell plasma membrane. These proteins then sort into detergent-resistant membrane microdomains. Virion production is cholesterol and sphingolipid dependent, and the virus is enriched in “raft”-associated proteins and lipids from the host cell membrane. The viral Env glycoproteins reach the plasma membrane independently of Gag.[33,57]

Viral maturation begins along with, or immediately following, virion budding, and is driven by viral PR cleavage of the Gag and Gag-Pro-Pol polyproteins at ten different sites. Assembly of HIV requires the viral Gag protein, a multi-domain polyprotein with three folded domains: matrix (MA), capsid (CA) and nucleocapsid (NC). There are three shorter peptides SP1, SP2 and p6. The virus is initially formed as a noninfectious, immature virion, containing largely uncleaved Gag polyproteins. Formation of an infectious virion requires processing of Gag by HIV protease at five specific sites, leading to separation of functional domains and a dramatic rearrangement of the interior virion organization.[33,57]

Maturation produces the fully processed components MA, CA, NC, p6, protease, reverse transcriptase, and integrase proteins, which rearrange to create a mature infectious virion. With viral assembly two copies of the capped and polyadenylated full-length RNA genome are incorporated into the virion. The outer capsid shell of the core particle is typically conical and consists of roughly 250 hexameric subunits with a 9.6-nm hexamer–hexamer spacing and exactly 12 pentamers, 5 at the narrow and 7 at the broad end. The capsid approaches the matrix closely at both ends. The capsid surrounds the nucleocapsid, which typically resides at the wide end of the capsid.[33,57]

Release of HIV from the host cell occurs in several steps. The p55 protein of HIV directs formation of a capsid (CA) protein that surrounds the RNA of HIV, a nucleocapsid (NC) protein that interacts with the RNA within the capsid, and matrix (MA) protein that surrounds the capsid and lies just beneath the viral envelope. A protease enzyme encoded by the *pol* gene of HIV cleaves the large precursor proteins to produce the MA, CA, and NC proteins. Budding virions utilize host cell membrane to help form the outer virion envelope of the budding virion necessary for production of infectious particles. The process of viral budding relies on cellular endosomal sorting complexes required for transport (ESCRT) that sort proteins and form multivesicular bodies (MVBs) that are intermediates in the formation of secretory lysosomes.[47,57]

Infective virions can enter susceptible host cells. Most often, cells with CD4 receptors at the site of HIV entry become infected and viral replication begins within them. The infected cells can then release virions by surface budding, or infected cells can undergo lysis with release of new HIV virions, which can then infect additional cells. Some of the HIV virions are carried via the lymphatics to regional lymph nodes.[35,54,58]

Though most macrophages become infected via HIV binding to gp120 and chemokine coreceptor with cell membrane fusion, macropinocytosis without cell surface binding can introduce HIV into macrophages. Most of the HIV is taken up into cytoplasmic macropinosomes and destroyed, but some HIV becomes localized to intracellular vesicles, escaping destruction and causing infection.[59]

In addition, peripheral blood monocytes and derivative macrophages express surface integrins, which are cell adhesion receptors, consisting of noncovalently linked alpha and beta subunits. Viruses use integrins to enter and exit cells. The alpha-V integrin of macrophages, when activated, upregulates nuclear factor kappa B (NF- $\kappa$ B) and facilitates production of HIV within the cell.[60]

Monocytes infected with HIV upregulate production of two cytokines that diminish the inflammatory response of CD4 lymphocytes. Programmed death-1 (PD-1) is upregulated during HIV infection when microbial products and the increased amounts of inflammatory cytokines in the blood of HIV-infected individuals induce the upregulation of PD-1 on monocytes. Once PD-1 is triggered, it upregulates production of the anti-inflammatory cytokine IL-10 by monocytes.[61]

Macrophages play a role in all stages of HIV infection. In acute infection, macrophages become infected with HIV, though not as readily as CD4 lymphocytes. Nevertheless, sufficient macrophages become infected to contribute to establishment of HIV infection. Once infected, macrophages, acting as antigen presenting cells, can assist in the immune response that leads to antibody production and cytotoxic CD8 lymphocyte responses. Thus, macrophages, assist in the immune response that reduces the viral load. However, long-lived macrophages harbor HIV during the latent phase of infection. Though macrophages can elaborate viral restriction factors, the interplay of HIV proteins and the restriction factors leads to continuing HIV proliferation.[62]

Dendritic cells play a key role in HIV infection. Two populations of dendritic cells have been characterized. The conventional dendritic cells such as Langerhans cells are found in epithelia and mark with CD11c. They become infected with HIV, and they can transport HIV via lymph and blood to multiple sites within the body. They secrete interleukin-12 that induces cytotoxic lymphocyte responses to infection. In contrast, plasmacytoid dendritic cells mainly circulate in blood but can migrate to many tissue sites. These cells are CD123 positive and produce type I interferons that can stimulate conventional dendritic cells. Dendritic cells circulating in blood tend to decrease inversely in proportion to the increase in HIV viremia. This may be due to apoptosis of HIV-infected dendritic cells, redistribution to lymphoid organs, or to decreased production.[63]

Both conventional and plasmacytoid dendritic cells can activate NK cells, which provide an innate immune response. However, the HIV *nef* gene encodes a protein that downregulates HLA-A and B, but not C, expression of infected cells to evade cytotoxic lymphocyte responses and killing by NK cells that recognize mainly HLA-C. Also, HIV reduces cytokines that activate NK cells. Dendritic cells infected with HIV become resistant to NK cell destruction.[63]



The HIV envelope glycoprotein gp120 may affect the physiologic functions of NK cells. The gp120 suppresses NK cell cytotoxicity, proliferation, and the ability to secrete IFN-gamma. Extended exposure to HIV gp120 resulted in apoptosis of NK cells. These effects upon NK cells aid in diminishing the innate immune response to HIV infection and make establishment of HIV infection at the site of entry more likely.[64]

Within the lymph nodes, HIV virions are trapped in the processes of follicular dendritic cells, where they reside in endosomal compartments formed from invaginations of cell surface membrane. These compartmentalized virions in dendritic cells may infect CD4 lymphocytes that are percolating through the node. Langerhans cells in the epithelia function similarly. The dendritic cells themselves may become infected, but are not destroyed.[53] Stromal dendritic cells can become infected via the chemokine receptor pathway, but also have a surface protein called dendritic cell-specific ICAM3-grabbing non-integrin (DC-SIGN) that can capture HIV by binding to the HIV envelope. DC-SIGN-bound HIV is more infectious and has a longer half-life than free HIV.[59] Dendritic cells can migrate in lymph and blood to carry HIV throughout the body.[65] The presence of gp120 of HIV appears to reduce the capacity of dendritic cells to produce interleukin-12, suppressing cell-mediated immune responses.[66]

Within the cytoplasm of an infected cell, HIV reverse transcription begins in a reverse transcription complex (RTC). The RTC complex migrates to the cell nucleus. Proviral DNA is then transcribed. Proviral DNA is detectable within hours in infected CD4 lymphocytes, but may require 36 to 48 hours to appear within macrophages. Integration of HIV into host cellular DNA can occur without mitosis.[59]

Most HIV infections likely begin from a single virus—a "founder" virus, from which subsequent clones develop. The initial infectious process is inefficient because the virus persists poorly in the environment and must find a host cell quickly, so most virions perish. Host cells elaborate an antiviral apolipoprotein B mRNA-editing enzyme catalytic polypeptide-like-3G (APOBEC3G) with cytidine deaminase activity that leads to defective viral replication. In addition, the HIV gene for reverse transcriptase has a high mutation rate and a high rate of error for reverse transcription. Thus, most initial HIV interactions with host cells do not result in established infections.[67]

After initial entry of HIV into host cells and establishment of infection, HIV virions are released from infected cells, may then enter the systemic circulation, and are carried to widespread sites within the body. Cells of the mononuclear phagocyte system, including those in lymph nodes, spleen, liver, and bone marrow can then become infected with HIV. Besides lymph nodes, the gut associated lymphoid tissue in gastrointestinal submucosa provides a substantial reservoir for HIV. Primary HIV infection is followed by a burst of viremia in which virus is easily detected in peripheral blood in mononuclear cells and plasma. In the period of clinical latency of HIV infection, there is little detectable virus in peripheral blood, but viral replication actively continues in lymphoid tissues.[58]

Though neutralizing antibodies are present in significant amounts 12 weeks following infection, these antibodies do not control the infection. By then there are enough viral variants to resist neutralization, particularly virions with increased glycosylation of their envelopes. Viral variants with epitope variation to resist cytotoxic CD8 lymphocyte responses also evolve. Thus, neither early humoral or cell mediated immune responses are able to eliminate HIV infection.[35]

Infection of the central nervous system by HIV requires that HIV-infected peripheral blood mononuclear cells cross the blood-brain barrier. Then infection of macrophages and



microglial cells can occur. The immune activation leads to release of neurotoxic factors that further stimulate microglial activation along with neuronal apoptosis.[59]

**IMMUNOLOGIC RESPONSE TO HIV.--** Once the HIV proviral DNA is within the infected cell's genome, it cannot be eliminated or destroyed except by destroying the cell itself. The HIV proviral DNA then directs its replication by infected host cells. This replication may first occur within inflammatory cells at the site of infection or within peripheral blood mononuclear cells (CD4 lymphocytes and monocytes) but then the major site of replication quickly shifts to lymphoid tissues of the body (lymph nodes and gastrointestinal tract). The initial burst of viral replication that follows infection is followed by replication at a lower level, which accounts for the clinically apparent latency of infection. However, viral replication is stimulated by a variety of cytokines such as interleukins and tumor necrosis factor, which activate CD4 lymphocytes and make them more susceptible to HIV infection.[35,54]

Activation of viral synthesis leads to release of new infective particles from the host cell surface by budding. Replication may also cause cell lysis with release of additional infective viral particles. Host cell death may be mediated via several diverse mechanisms: direct viral cytopathic effects, fusion to multinucleated giant cells (syncytia formation), cytotoxic immune response by other lymphocytes (CD8+ cytotoxic T-lymphocytes), autoimmune mechanisms, disruptive interaction of HIV envelope proteins with the cell membrane, immune clearance from alteration of antigenicity of the host cell, activation of apoptosis (programmed cell death), or toxic accumulation of viral DNA, RNA, or proteins.[21,22,35,54]

Apoptosis plays a key role in the decline in T cell numbers during HIV infection. Acute HIV infection results in immune activation with apoptosis of infected lymphocytes. Expression of tumor necrosis factor (TNF) related apoptosis-inducing ligand (TRAIL) and FAS ligand increase and have a paracrine effect to promote further apoptosis of bystander cells.[67] Mechanisms that contribute to continued HIV-associated lymphocyte apoptosis include chronic immunologic activation via gp120/160 of the CD4 receptor, enhanced production of cytotoxic ligands or viral proteins by monocytes, macrophages, B cells, and CD8 cells, and direct infection of target cells by HIV resulting in apoptosis. HIV envelope glycoprotein induces chemokine CXCR4-dependent autophagy of uninfected lymphocytes, which is required for caspase-dependent, apoptotic cell death and caspase-independent, nonapoptotic cell death. Apoptosis of lymphocytes is increased with progression of HIV disease and diminished with effective antiretroviral therapy.[68,69]

In addition to direct infection, CD4+ lymphocytes can be destroyed via pyroptosis. Inflammasomes are multiprotein cytosolic complexes that can form in response to stimulation of cell surface receptors. HIV infection can upregulate production of cytokines, including caspase-3 and caspase-1. Caspase-3 primarily plays a role in apoptosis of virally infected CD4 cells. Caspase-1 triggers inflammasome formation and pyroptotic cell death. Thus, lymphoid tissues can be depleted by both apoptosis and pyroptosis following HIV infection. The process of pyroptosis is a useful inflammatory response for rapidly clearing bacterial infections, but becomes counterproductive with ongoing chronic inflammation, as in HIV infection.[70]

Subsets of the CD4+ lymphocyte population are important in determining the host response to infection. The subset known as T<sub>H</sub>1 (T helper 1) is responsible for directing a cytotoxic CD8+ T-lymphocyte response, but the T<sub>H</sub>2 (T helper 2) subset of CD4+ and CD8+ T-lymphocytes diminishes the cytotoxic lymphocyte response while increasing antibody production. Persons infected with HIV who have a dominant T<sub>H</sub>1 response tend to survive

longer. CD8+ lymphocytes can inhibit HIV infection through both HLA-restricted cytotoxicity as well as suppressive activity mediated through release of multiple suppressive factors collectively termed CD8 antiviral factor (CAF).[59]

The switch from a  $T_H1$  to a  $T_H2$  response has been suggested as a factor in the development of AIDS. CD4+ lymphocytes produce IL-2 and IFN- $\gamma$  in a  $T_H1$  response, and IL-4 and IL-10 as part of a  $T_H2$  response. Production of interleukin-5 (IL-5) and interferon- $\gamma$  (IFN- $\gamma$ ) by CD4+ and CD8+ T-lymphocytes expressing CD30 is associated with promotion of B-lymphocyte immunoglobulin production.[71,72] The imbalance in the T helper response to a predominantly  $T_H2$  response is mediated by HIV proteins gp120 and Tat, which trigger the release of cytokines necessary for a  $T_H2$  response. These HIV proteins stimulate mast cells and basophils. The Tat protein upregulates chemokine receptor CCR3 on mast cells and basophils and renders them susceptible to infection by CCR3 tropic HIV. Increased serum IgE levels suggest that a  $T_H2$  response has occurred and predict a poorer prognosis.[73]

The subset of helper T cells known as  $T_H17$  cells may become infected with HIV. All  $T_H17$  cells express the chemokine receptor CCR6, and a subset of those are also CCR5 positive and preferentially infected with HIV. Though most  $T_H17$  cells are not directly infected by HIV, they tend to diminish during the course of HIV infection.  $T_H17$  cells are found in the gastrointestinal tract lamina propria and aid in mucosal immunity. Depletion of  $T_H17$  cells may predispose to opportunistic infections involving the gastrointestinal tract. Long-term antiretroviral therapy can restore  $T_H17$  cells in the gastrointestinal tract, which may be associated with better prognosis.[74,75]

The CD8+ lymphocyte response to early HIV infection is not sufficient to contain continued viral replication. Though the “founder” clone of HIV may be reduced or eliminated by a CD8 cytotoxic response, HIV mutations introduce clones, so-called “escape mutants”, that continue the infection. In acute HIV infection, a limited number of specific CD8 T cell responses occur to suppress viremia. The efficacy of this early CD8 cell response determines the set point of plasma viremia that predicts the subsequent course of HIV infection. Over time, more varied and robust CD8 T cell responses occur, but without a change in the control of viral replication or further reduction in the viral set point. Thus, CD8 cell responses in acute HIV infection appear able to suppress viral replication, but responses generated in the chronic phase of HIV infection are impaired.[76]

Tissue mast cells may form a reservoir for HIV infection. Progenitor mast cells (prMC) are derived from pleuripotential CD34+ stem cells. The prMC express CD4, CXCR4, and CCR5 surface receptors and are thus susceptible to HIV infection, mainly via CCR5. Once prMCs reach their target tissue destination, maturation to mast cells results in loss of these surface chemokine coreceptors and loss of susceptibility to HIV infection.[77]

B-lymphocytes may assist early spread of HIV following infection. B cells express the complement receptor CR2 (CD21). Virions can bind to this receptor.[67]

Macrophages and dendritic (Langerhans) cells in epithelial tissues of the body, such as the genital tract, are also important as both reservoirs and vectors for spread of HIV in the body. Macrophages originate from blood monocytes and give rise to the body's mononuclear phagocyte system. Persons on antiretroviral therapy who are otherwise healthy may have demonstrable HIV-1 within their alveolar macrophages.[78]

Langerhans cells (a subset of blood dendritic cells) originate in bone marrow and migrate to peripheral epithelial locations in skin and mucous membranes, acting as antigen presenting cells

for lymphocytes. Dendritic cells can cross endothelium and circulate freely into both lymphoid and mucosal tissues. HIV can be replicated within dendritic cells for up to 45 days.[79]

Both macrophages and Langerhans cells can be HIV-infected but are not destroyed. Dendritic cells can capture HIV in their processes, providing a focus for infection of other cells. In experimental cell cultures, the two pathways of HIV-1 spread are: (1) fluid-phase diffusion of cell-free virions, and (2) cell-cell spread of virus. The latter is potentially more efficient, and this is likely the case in vivo. Cell-cell transfer can include budding with fusion of closely opposed cell membranes occurs as well as cell-cell fusion to give syncytia. Viral particles may undergo endocytosis, may be stored in a cell surface-accessible compartment, or just directly infect a cell via receptors. Though long-term transmission of HIV from dendritic cells to CD4 cells can be the result of active infection of the dendritic cells rather than just trapping and presenting virion, short-term transmission occurs principally through cell surface HIV interaction. There are pockets of plasma membrane that harbor virions on dendritic cells that provide the means to present virions to CD4 cells via a so-called "infectious synapse." [80]

When HIV is carried to sites in the body, particularly to regional lymph nodes and to gut-associated lymphoid tissue (GALT), the antigen-presenting cells such as macrophages or dendritic cells act as a "Trojan horse". [81] Macrophages proliferating in response to other infections, such as mycobacterial infections, may increase this reservoir capacity and promote progression of HIV infection. [82] Macrophages may replicate virions on their cytoplasmic membranes, including Golgi apparatus, and if virions are limited to intracellular compartments, they are not seen by the immune system. [34] Langerhans cells can become infected with HIV, even at sites distant from initial infection and during primary infection. [83]

In the host, HIV continues to replicate, mainly within lymphoid tissues. Germinal centers of lymph nodes and GALT contain many follicular dendritic cells (FDCs). GALT becomes a persistent reservoir for HIV infection. [35] Lymphoid tissue FDCs not only have CD4 receptors on their surface membranes, but also express a surface protein, CD-SIGN, to which HIV envelope protein can bind. The FDCs can accumulate high numbers of HIV virions, acting as virion "warehouses". [84] Any CD4 lymphocytes percolating through the germinal centers of lymph nodes may become infected through contact with FDCs harboring HIV virions on their surfaces. Budding of viral particles from their surfaces indicates that productive infection of FDCs also occurs. [85] The virions can become trapped in the interdendritic spaces of FDCs, or they may even undergo receptor-mediated endocytosis to become localized within the FDCs, and may escape to reside freely within the FDC cytoplasm, providing a significant reservoir of HIV infection. The FDCs proliferate in response to early HIV infection, leading to lymphadenopathy. [54,58,65,86]

Memory T lymphocytes play a role in maintenance of HIV infection. Resting memory cells are long-lived. Memory CD4 cells that become infected with HIV constitute a significant reservoir for transcriptionally silent provirus. They remain unaffected by antiretroviral treatment and provide a source for continuing infection. [87] In addition, CD4+ CCR5+ memory T cells in GALT become infected in high numbers, while induction with activation of remaining uninfected CD4+ cells leads to their apoptosis, quickly depleting CD4 lymphocyte numbers. [67]

T regulatory (Treg) cells may be involved in the immune responses following HIV infection. Persistent immune activation following HIV infection leads to Treg expansion. The population of Tregs may either suppress generalized T cell activation to reduce inflammatory responses, or weaken specific immune responses to HIV. The former is beneficial, but the latter is detrimental. Transforming growth factor-beta (TGF- $\beta$ ) is one such marker of chronic immune

activation that is associated with HIV disease progression. The balance between Treg responses may modulate the course of HIV infection.[88,89]

Chronic immune activation can be driven by HIV replication. Persons who can control viral replication tend to have less immune activation and inflammation. However, some immune activation continues with HIV infection. Activated T-cells are present regardless of the number of CD4 lymphocytes. When immune activation markers are rising, they predict CD4 cell decline. Even in patients receiving antiretroviral therapy have some degree of immune activation, despite undetectable viral loads.[89]

T-follicular helper (Tfh) cells are a subset of CD4 lymphocyte. The Tfh cells can be induced by CXCR5, along with loss of T-cell zone homing chemokine receptor CCR7, leads to Tfh cell relocation to germinal centers. The Tfh cells secrete cytokines that drive B-cell expansion and plasma cell proliferation. Thus, the Tfh cells contribute to immune activation, and contribute to the continued replication of HIV.[89]

The magnitude of HIV-1 production in infected persons is enormous. The numbers of "productively infected cells" (those cells with 20 or more copies of HIV-1 RNA) are initially quite high. Within 3 to 4 weeks following initial HIV infection, a peak viremia occurs. The HIV-1 RNA level at this peak is often in the range of 1,000,000 copies/mL. CD4 cell numbers, in contrast, are falling at peak viremia.[67]

When primary HIV-1 infection occurs, most of the productively infected cells are CD4 lymphocytes, accounting for about 80% of all infected cells at the site(s) of mucosal inoculation and 90% of infected cells in lymphoid tissues. However, follicular dendritic cells (FDCs) within the lymphoid tissues provide the greatest reservoir in well-established HIV-1 infections, particularly throughout the clinically latent period before the onset of AIDS, harboring an estimated  $10^{11}$  copies of HIV-1 RNA. The pool of  $10^7$  to  $10^8$  productively infected CD4 cells within the body, averaging 50 - 100 copies per cell, gradually diminishes over time, eventually leading to immune failure and the onset of AIDS. The total virion production per day in an infected person averages greater than  $10^9$  to  $10^{10}$  copies. Additional reservoirs of HIV-infected cells may be present in the central nervous system, lung, and liver.[90,91]

Since the HIV provirus becomes part of the infected host's cellular DNA, the host's cells may be infectious even in the absence of a demonstrable HIV serum viremia or detectable HIV antibodies.[54] However, antibodies formed against HIV are not protective, and a viremic state can persist despite the presence of even high antibody titers. HIV has the additional ability to mutate easily, in large part due to the error rate in production of the reverse transcriptase enzyme, which introduces a mutation approximately once per 2000 incorporated nucleotides. Such a mutation rate is a million times faster than of mammalian DNA. This high mutation rate leads to the emergence of HIV variants within the infected person's cells that can then resist immune attack, exhibit greater cytotoxicity, generate syncytia more readily, or can impart drug resistance. Over time, various tissues of the infected host's body may harbor differing HIV variants.[21,22,32,92]

Moreover, the primary target of HIV is the immune system itself, which is gradually destroyed. Viral replication actively continues following initial HIV infection, and the rate of CD4 lymphocyte destruction is progressive. Clinically, HIV infection may appear "latent" for years during this period of ongoing immune system destruction. During this time, enough of the immune system remains intact to provide immune surveillance and prevent most infections. Eventually, when a significant number of CD4 lymphocytes have been destroyed and when

production of new CD4 cells cannot match destruction, then failure of the immune system leads to the appearance of clinical AIDS.[22,32]

HIV infection is sustained through continuous viral replication with reinfection of additional host cells. Both HIV in host plasma and HIV-infected host cells appears to have a short lifespan, and late in the course of AIDS, the half-life of plasma HIV is only about 2 days. Thus, the persistent viremia requires continuous reinfection of new CD4 lymphocytes followed by viral replication and cell turnover. This rapid turnover of HIV and CD4 lymphocytes promotes the origin of new strains of HIV because of the continuing mutation of HIV. Presence or emergence of different HIV subtypes may also account for the appearance of antiretroviral drug resistance as well as the variability in pathologic lesions as different cell types are targeted or different cytopathic effects are elicited during the course of infection.[22,93,94]

Active replication of HIV occurs at all stages of the infection. However, a month after initial infection and peak viremia occur, equilibrium begins to be established between HIV replication and control of HIV by the host immune system. In general, clearance rates of HIV are similar among persons, but the rate of HIV production determines the viral load in the steady state. This marks the clinically latent phase of HIV infection. The presence of viremia, as detected by serum HIV-1 RNA, suggests that the immune system is not able to contain the virus. Increasing levels of serum HIV-1 RNA suggest a loss of the equilibrium and emergence from latency to a more rapid progression to AIDS. The absence of a detectable serum HIV-1 RNA suggests a slower progression to clinical AIDS. Greater HIV-1 RNA levels in patients with symptomatic acute HIV infection suggest that such persons may progress more rapidly to AIDS.[95] As the number of CD4 cells diminishes in the late stages of AIDS, macrophages still serve as key sites for continuing viral replication.[59] Even after years of viral suppression with antiretroviral drugs, there is typically a rebound of detectable peripheral blood viremia within 2 weeks of cessation of therapy, suggesting that reservoirs for persistent HIV infection remain.[35]

Cytokine activation of CD4 lymphocytes can increase the production of HIV by infected cells. Activated T cells increase intracellular nuclear factor kappa B (NF- $\kappa$ B) levels, which enhances proviral transcription to generate new virions. Proinflammatory cytokines that stimulate virion production include tumor necrosis factor alpha (TNF- $\alpha$ ), interleukin 1 (IL-2), and interleukin 6 (IL-6).[96] The ongoing destruction of gut-associated lymphoid tissue (GALT) may allow bacterial products, such as lipopolysaccharides, that stimulate immune activation, to increase.[35]

Innate immune responses may play a role in HIV replication. A population of T lymphocytes in the gut mucosa, known as gamma delta T cells, is a first line of defense against intestinal pathogens. They have been shown to produce T<sub>H</sub>1 and T<sub>H</sub>2 types of cytokines, as well as viral suppressive factors including RANTES. Alpha and beta interferons produced in response to viral infection can promote a T<sub>H</sub>1 response and help prevent T lymphocyte apoptosis. The CC cytokines produced by activation of macrophages, dendritic cells, T cells, NK cells, and gamma delta lymphocytes can block CCR5 coreceptors of HIV. Apolipoprotein B mRNA-editing, enzyme-catalytic polypeptide-like-3G, or APOBEC3G, is an intracellular anti-viral factor that can inhibit HIV. However, HIV can produce compounds that counter these innate immune mechanisms.[37,97]

Virally infected cells that produce interferons may diminish HIV replication via protein products upregulated by the interferons. One such protein is tetherin, a transmembrane cell protein. Tetherin forms a membrane anchor to entrap enveloped virions and prevent their release from the cell. Reduction in release of virions will diminish viremia.[98]

Genetic variability in HIV also leads to differences in biological phenotypic characteristics of viral pathogenic effects. HIV can be divided into three groups: (1) non-syncytium-inducing (NSI) variants that have a low replicative capacity; (2) non-syncytium-inducing variants with a high replicative capacity; and (3) syncytium-inducing (SI) variants. From 30 to 60% of HIV-infected persons may eventually develop such variants. The SI variants appear to evolve from NSI variants, with a change in surface gp120, during the course of HIV infection, usually at a time marked by a peripheral blood CD4 lymphocyte count between 400 and 500/ $\mu$ L. SI variants use the CCR5 chemokine receptor for cell entry, while NSI strains use CXCR4 receptors. The appearance of SI variants is associated with CD4+ cell tropism, rapid CD4+ cell decline, higher HIV-1 RNA plasma levels, symptomatic HIV disease, male sex, and rapid progression of HIV infection. However, only about half of patients with AIDS have the SI variants, and NSI variants can also be seen with disease progression.[95,99]

Phylogenetic studies can identify genetic clusters of HIV-1 *env* genes, which are known as subtypes, or clades, that have arisen along with progression of the AIDS pandemic worldwide. The V3 loop amino acid sequences of these genetic variants influence HIV phenotype and immune response.[100] Thus, the biologic properties of HIV can vary with the subtype. This is possible even within a single HIV-infected person, where variants of HIV may arise over time that are "neurotropic" or "lymphocytotropic" for example.[22,92] Variability in transmission may occur, which is associated with greater heterosexual transmission, aided by its propensity to infect dendritic cells that can be found in mucosal epithelium.[101] However, the role of HIV-1 subtypes in transmission and pathogenesis of HIV remains, for the most part, unclear.[102]

## HUMAN IMMUNODEFICIENCY VIRUS SUBTYPES

There are four major groups of HIV-1, based upon phylogenetic analysis, which likely arose from different transmission events in history among chimpanzee and gorilla primates and humans. These groups are defined as M (major), N (nonmajor and nonoutlier), O (outlier), and P. These groups are very similar to simian immunodeficiency viruses SIVcpz (M and N) and SIVgor (O and P).[103]

Within these HIV-1 groups are subtypes. The predominant group M has recognized subtypes A, B, C, D, F, G, H, J, and K.[104] Group O is distinctly different and genetically more closely related to simian immunodeficiency virus (SIV) and HIV-2.[107,105] Group N appears to have arisen from interaction between a group M and a group O virus.[106] The vast majority of HIV-1 infections have been with group M. In contrast, only about 100,000 infections with group O have occurred, and group N and P infections are rare.[30]

Even within HIV-1 subtypes, genetic diversity can reach 15 to 20%; between subtypes, it is 25 to 30%. Different subtypes of HIV-1 that have arisen and will continue to arise in the course of the AIDS pandemic have been identified with certain geographic distributions, though movement of individuals among populations creates more variability over time.[104] Variability of HIV subtypes may also confound testing strategies, because diagnostic sensitivity and specificity of laboratory tests may not be the same across all subtypes.[107]

There is increasing diversity of HIV-1 in the form of recombination of subtypes. Recombinants between subtypes are termed circulating recombinant forms (CRFs). Through 2011 there were 48 different CRFs described. The term unique recombinant form (URF) is used to designate strains of HIV-1 not meeting these criteria. In a study of 65,913 samples from HIV-

infected persons obtained in 109 countries between 2000 and 2007, data from 2004 – 2007 showed subtype C accounted for nearly half (48%) of all global infections, followed by subtypes A (12%) and B (11%), CRF02\_AG (8%), CRF01\_AE (5%), subtype G (5%) and D (2%). Subtypes F, H, J and K together accounted for fewer than 1% of all global HIV infections. Other CRFs and URFs were each responsible for 4% of global infections, bringing the combined total of worldwide CRFs to 16% and all recombinants (CRFs along with URFs) to 20%. Thus, there has been a global increase in the proportion of CRFs, a decrease in URFs and an overall increase in recombinants.[108]

The migration pathways of some subtypes and CRFs have been traced. Subtypes A and D appear to have originated in central Africa, but eventually established epidemics in eastern Africa. Subtype C is predominant in southern Africa from where it spread to India and other Asian countries. Subtype B that accounts for most HIV-1 infections in Europe and the Americas appears to have arisen from a single African strain first spread to Haiti in the 1960s and then onward to the US and other western countries.[25]

The detection of mosaic HIV-1 sequences suggests that persons can become coinfecting with differing HIV-1 subtypes that can then undergo recombination to new strains that may have different biologic characteristics from the original strains. Mutations and recombination's can confer antiretroviral drug resistance. The major groups and subtypes of HIV-1 as listed above, with epidemiologic correlates for locations of greatest prevalence. Recombinant forms are appearing more frequently as the pandemic progresses.[104]

At the beginning of the 21<sup>st</sup> century, over 90% of new HIV infections are emerging in Asia, Africa, and Eastern Europe. The non-B HIV-1 subtypes A and C are more prevalent in these regions and appear to be transmitted more efficiently than the subtype B, which is more common to developed nations of Europe and North America. The more virulent subtype C accounts for half of all new infections. The evolutionary changes in HIV accounting for differences in subtype transmission have included *env* gene mediated receptor affinity and LTR and *tat* gene mediated transcriptional activation.[109]

### Subtypes of HIV-1

#### Group M

Subtype A	East and Central Africa; Central Asia; Eastern Europe
Subtype AE	Southeast Asia
Subtype AG	West Africa
Subtype B	Americas; Western Europe; East Asia; Oceania
Subtype C	India; Southern and Eastern Africa
Subtype D	East Africa
Subtype G	West Africa
Subtype H	Central Africa
Subtype J	Central America
Subtypes F, H, J, K	Variable

#### Group N

Cameroon

#### Group O

West Africa

**Group P**

Cameroon



## OTHER HUMAN RETROVIRUSES

HIV-2:-- The numerous strains of HIV-1 isolated from various geographic regions of the world are all immunologically similar and differ only slightly in their DNA sequences. A second retrovirus designated HIV-2 has been isolated from a number of patients with AIDS, first in 1986 in West African countries and subsequently in locations in Western Europe (principally Portugal and France), India, the United States, and elsewhere that migration from West Africa occurred. Worldwide there are 1 to 2 million cases of HIV-2 infection, and most cases have appeared in West Africa and but only sporadically in other parts of the world.[110,111]

HIV-2 is believed to have been present in Africa as early as the 1940's. HIV-2, which has greater homology to simian immunodeficiency virus (SIV) than to HIV-1, appears to have become established in human populations as a zoonotic infection from the primate reservoir of sooty mangabeys (*Cercocebus atys*), originating from SIVsmm.[24,44]

HIV-2 infection is mainly found in West African nations, including Guinea-Bissau, The Gambia, Senegal, Cape Verde, Cote d'Ivoire, Mali, Sierra Leone, and Nigeria. HIV-2 is spread in a manner similar to HIV-1, though the high-risk groups are commercial sex workers and persons with other sexually transmitted diseases. The peak age of persons infected with HIV-2 appears to be higher than that of HIV-1, but there appears to be no sex difference in rates of infection.[111,112]

Persons infected with HIV-2 infection have a longer asymptomatic phase, higher CD4 cell counts, lower viral RNA levels, and slower progression to AIDS than HIV-1 infection.[49] There is a well-preserved and functionally heterogeneous HIV-specific memory CD4+ T cell response that is associated with delayed disease progression in the majority of people infected with HIV-2.[113] The risk factors for transmission are the same as for HIV-1, but heterosexual transmission and maternal transmission is less efficient. Broadly neutralizing antibodies, rare in HIV-1 infection, are present with HIV-2 infection and their presence is equivalent to a vaccine response.[111]

The diminished virulence of HIV-2, compared with HIV-1, explains the slower progression to AIDS and progression at higher CD4 counts. The cellular immune responses to HIV-2 tend to be more polyfunctional. Greater IL-2 production maintains higher lymphocyte counts. Innate immune responses are greater. HIV-2 appears to utilize the same cellular mechanisms for infection as HIV-1, including the use of CD4 receptors and chemokine coreceptors CCR5 and CXCR4, but HIV-2 utilizes a wider array of chemokine receptors, including CCR1, CCR2, CCR3, and CXCR6. The CXCR3 isolates of HIV-2 tend to resist neutralizing antibodies and are more likely to be found in patients with advanced stages of infection, while persons with the CCR5-tropic isolates are more likely to have asymptomatic infection.[110,111]

When HIV-1 and HIV-2 coexist in the same populations, as in West Africa where up to 1% of HIV infections are co-infections, there has been a reduction in seroprevalence of HIV-2 over time. Thus, the overall prevalence of HIV-2 in endemic areas appears to have declined in the early part of the 21<sup>st</sup> century. This decline may be due to a low rate of vertical transmission (about 4%) and to low infectivity from few viral particles shed into genital secretions. The lower infectivity of HIV-2 is likely related to lower viral RNA levels, which average 30 times lower than for HIV-1.[110,111]

Once persons with HIV-2 infection have progressed to clinical AIDS, the manifestations are similar to those of persons with AIDS from HIV-1 infection. In endemic regions for HIV-2, tuberculosis is a frequent complication of AIDS. Clinical findings more common with HIV-2 include severe multi-organ cytomegalovirus infection, encephalitis, cholangitis, chronic bacterial diarrheal illness, and wasting syndrome. Findings less common with HIV-2 include Kaposi sarcoma and oral candidiasis.[110]

Just as HIV-1 has distinct subtypes, so does HIV-2. There are 8 strains labeled A through H, but groups A and B account for pandemic spread, and group A accounts for most infections worldwide. There is up to a 25% difference in genetic homology among these subtypes. All five subtypes can be detected by enzyme immunoassay (EIA) and Western blot assays for HIV-2 similar to those for HIV-1. The reverse transcriptase enzyme is similar in structure and function in both HIV-1 and HIV-2. Infection with HIV-2 eventually leads to AIDS. Persons can be coinfecting with HIV-1 and HIV-2.[111,112,114]

The genetic sequences of HIV-1 and HIV-2 are only partially homologous. HIV-2, or other as yet uncharacterized members of the HIV-group of viruses, will not necessarily be detected by using the various laboratory tests for HIV-1 antibody, including enzyme immunoassay (EIA) and Western blot (WB) tests, in general use for HIV-1. Instead, separate EIA and WB assays are employed for diagnosis of HIV-2. HIV-2 is genetically more closely related to simian immunodeficiency virus (SIV) than HIV-1.[115]

This potential problem of genetic variation with HIV was illustrated in 1994 with the detection of a strain of HIV-1 (designated MVP-5180, or subtype O), a new HIV variant originating in the region of West-Central Africa, which showed only slightly more homology with other HIV-1 strains than with HIV-2. This variant is detectable with many testing methods for HIV-1, but false negative results may occur. This subtype O of HIV-1 demonstrates higher heterogeneity in *env* sequences than the more prevalent HIV-1 subtypes such as B.[105,116]

The appearance of additional HIV subtypes requires more complex testing schemes in locations where HIV-2, or other possible HIV virus subtypes, are prevalent. The natural history of HIV-2 infection is characterized by a longer latent period before the appearance of AIDS, a less aggressive course of AIDS, and a lower viral load with higher CD4 lymphocyte counts and lower CD4 cell turnover than HIV-1 infection until late in the course of the disease, when clinical AIDS is apparent. Thus, the pathogenicity of HIV-2 appears to be lower than that of HIV-1. This may explain the more limited spread of HIV-2, compared to HIV-1, both in West African countries and elsewhere, due to less efficient transmission, particularly via heterosexual and perinatal modes.[111,112]

HTLV:-- Another group of human retroviruses different from HIV are the human T-lymphotrophic viruses, types 1 and 2 (HTLV-1 and HTLV-2). Along with simian T-cell lymphoma virus type 1, they constitute a group of retroviruses known as the primate T-cell leukemia/lymphoma viruses. HTLV's can be transmitted in the same manner as HIV, though even less efficiently. Persons can be coinfecting with HIV and HTLV. There is faster clinical progression and a shorter survival time with HTLV-1 and HIV-1, even if the CD4 cell count is higher than with HIV infection alone. However, HTLV-2 coinfection appears to exert a protective effect, with more persons progressing slowly to AIDS.[117] The CD4 lymphocytes are the cells primarily infected by HTLV. Laboratory testing methodology for HTLV's is similar to that for HIV. The enzyme immunoassay test for HTLV-1 will also detect HTLV-2.

Confirmatory Western blot testing, in combination with testing for the presence of envelope peptide p21env-r helps to distinguish HTLV-1 from HTLV-2.[118,119]

HTLV-1 infection is widespread in tropical and subtropical regions, with the main endemic foci in the Caribbean, southern Japan, central Africa, South Africa, and South America, particularly Brazil. Other endemic foci are found in southern India, northern Iran, aboriginal populations of northern Australia, and islands in the tropics. Transmission is perinatal, as a sexually transmitted disease, and through parenteral exposure (contaminated blood products or shared needles with injection drug usage). Vertical transmission occurs mostly via breast-feeding. In Europe and North America, HTLV-1 infection is primarily associated with injection drug users and with immigrants from endemic areas. The seroprevalence varies widely, even in communities located close together, and ranges from 0.1% in non-endemic areas to 6% in some Caribbean endemic regions and as high as 10% in southern Japan.[120]

HTLV-1 is associated with adult T-cell leukemia/lymphoma (ATLL) and with a form of chronic progressive neurologic disease known as HTLV-associated myelopathy/tropical spastic paraparesis (HAM/TSP). HTLV-1 is also associated with inflammatory conditions including arthropathy, Sjögren syndrome, thyroiditis, pneumonopathy, crusted scabies, infective dermatitis, and leprosy. The time from exposure to onset of HTLV-1 related disease is long--from 2 to 3 decades on average. However, the lifetime risk for ATLL in infected persons is only about 2-6% for persons infected before the age of 20. There is a lower risk for the less serious complications of infectious dermatitis, uveitis, polymyositis, and arthropathy. The lifetime risk for HAM/TSP is about 0.25% in Japan and 3% elsewhere. ATLL is uniformly fatal, while HAM/TSP is not.[120]

HAM/TSP typically manifests as a slowly progressive spastic paraparesis with neurogenic bladder disturbance. Lower limb weakness usually progresses without remission, beginning after the age of 30, with wheelchair dependence occurring after another 20 years. Bladder problems commonly occur and include urinary frequency, urgency, incontinence and/or retention. Additional problems include back pain, constipation, sexual dysfunction, and lower extremity sensory symptoms. The microscopic pathologic findings include chronic meningo-myelitis of white and grey matter with subsequent axonal degeneration that preferentially affects the lower thoracic cord. There is perivascular and parenchymal infiltration of T lymphocytes. Lesions become less cellular and more atrophic later in the course of the disease.[120]

Laboratory findings with HTLV-1 include atypical lymphocytes seen on peripheral blood films, hypergammaglobulinemia, and a false positive VDRL. Examination of CSF may reveal a mild lymphocyte pleocytosis, a mild to moderately increased protein, and oligoclonal bands. These findings usually are present in the first few years of disease, but they can persist as long as 10 years after symptom onset. HTLV-1 antibodies are found in the CSF, with higher titers in symptomatic persons. The HTLV-1 provirus can be demonstrated in the CSF of HAM/TSP patients by PCR. Men are more likely to develop ATLL, while HAM/TSP is more common in women.[120]

HTLV-2 was initially identified as an endemic infection in two distinct populations: native peoples of the New World and pygmy tribes of Africa. However, most infections now occur as a result of injection drug use, particularly in metropolitan areas of Europe, the U.S., South America, and Asia. There is no clear association between HTLV-2 and ATLL. Chronic neurologic disease linked to HTLV-2 infection may include tropical spastic paraparesis,

progressive spastic myelopathy, spastic ataxia, spinocerebellar syndrome, and chronic progressive neurologic disease.[121,122]

HTLV-3 and HTLV-4 agents have been identified in African populations. These agents belong to the primate T lymphotropic virus group (PTLV). HTLV-1/2 commercial tests are used for the detection of HTLV-3 and 4. Few cases have been discovered. The long latency of HTLV will mean that decades can pass before the modes of transmission and pathologic effects become characterized fully.[123]

## EPIDEMIOLOGY OF AIDS

Considerable epidemiologic and clinical work has been performed to understand the transmission of HIV from one person to another. As in past epidemics, the spread of AIDS is facilitated by human travel. Syphilis in the 16th century, bubonic plague in the 17th century, and influenza early in the 20th century also arose from endemic foci to become widespread. Modern means of travel by jet aircraft readily available to many people provide an easy route for the spread of AIDS from one location or population to another.[124]

However, unlike most infections in past epidemics, AIDS is distinguished by a very long latent period before the development of any visible signs of infection in affected persons. The average HIV-infected person may have an initial acute self-limited illness, may take up to several weeks to become seropositive, and then may live up to 8 or 10 years, on average without treatment, before development of the clinical signs and symptoms of AIDS. In virtually all past infectious disease epidemics, infected persons were soon easily recognized so that measures could be taken to prevent the spread of disease. But persons infected with HIV cannot be recognized by appearance alone, are not prompted to seek medical attention, and are often unaware that they may be spreading the infection.[32,54,125]

The transmission of HIV is a function of both where the virus appears in the body and how it is shed. HIV can be present in a variety of body fluids and secretions, as shown in Table 1. The presence of HIV in genital secretions and in blood, and to a lesser extent breast milk, is significant for spread of HIV. However, the appearance of HIV in saliva, urine, tears, and sweat is of no major clinical or social importance, as transmission of HIV through these fluids does not routinely occur, primarily because of the low concentration of HIV in these fluids.[126] Though infectious particles of HIV are frequent in cerebrospinal fluid, contact with this fluid in daily life is extremely rare.[22,127] Cerumen (ear wax) does not carry identifiable HIV.[128]

The most important feature of HIV is the means of spread (Table 2). Unlike most epidemics of infectious diseases wherein much of a population is at risk, HIV infects definable population subgroups ("risk groups"). This happens because HIV is primarily a sexually transmissible disease. Homosexual, bisexual, and heterosexual transmission all can occur. Although sexual intercourse between males has remained the greatest risk for transmission in developed nations of Western Europe and the United States, heterosexual transmission has increased over time, but still remains less common than in Africa, Asia, or parts of the Caribbean.[125,129,130]

Transmission of HIV can occur from male to male, male to female, and female to male. Female to female transmission remains extremely rare, though women with same-sex contact are also often bisexual and have additional risk factors for HIV infection.[131,132] Even a partial modification of sexual behavior practices may help retard the rate and extent of HIV transmission. Amongst males having sex with males in the U.S. in the 1990's, the prevalence of HIV infection remained high at 7.2%, and the prevalence of unprotected anal intercourse over a prior 6 month period was 41%.[133] In a study from 2008, the prevalence of HIV was 19% among men having sex with men, and 44% of them were unaware of their infection.[134]

Educational efforts in AIDS prevention must be ongoing and must specifically target not only persons belonging to identifiable risk groups for HIV infection but also teenagers beginning sexual intercourse (and who often lack a sense of their own mortality), as well as young adults. The Centers for Disease Control in the U.S. has a strategic plan to reduce HIV infection through

a three-part plan that includes: (1) intensifying efforts to help all infected persons learn their HIV status; (2) establishing new prevention programs to help HIV-infected persons establish and maintain safer behaviors, combined with improved linkages to treatment and care; and (3) expanding highly targeted prevention programs to reach all HIV-negative persons at greatest risk.[135]

Worldwide, heterosexual transmission accounts for the majority of cases of HIV infection. The important factors that promote heterosexual transmission include:[136]

- \* More sexual partners
- \* Frequent change of sexual partners
- \* Unprotected sexual intercourse (lack of barrier precautions)
- \* Presence of additional sexually transmitted diseases
- \* Lack of male circumcision
- \* Social vulnerability of women and young persons
- \* Economic and political instability of the community

The lack of economic and political stability makes it difficult to institute programs to change behavior, to promote condom use, to treat sexually transmitted diseases, to test for HIV infection, and to treat HIV infection with antiretroviral therapies that reduce viral load and the risk of transmission.[136] If HIV-infected persons have access to HIV testing, counseling, and treatment, then the prevalence of HIV in the population will drop.[134]

Practicing "safe" sex will diminish the prevalence of HIV infection in populations where HIV has become well established. Though transmission of HIV can be reduced, transmission cannot completely be eliminated once it is established in a population.[16,17] Modification of risky behaviors is most efficacious for persons recently infected with HIV. High levels of viremia may persist on average for 3 months, and the level of virions in genital secretions and blood is high during this time. Therefore, early diagnosis and monitoring of HIV infection can support behavior modification to reduce HIV transmission.[137]

Risk reduction interventions, including education on abstinence and safer sex, are beneficial. Abstinence intervention has a short-term effect over months, while safer sex interventions have a longer lasting effect, particularly amongst adolescents who have previously had sexual intercourse. These interventions appear to reduce the frequency of sexual intercourse. Promotion of the use of condoms as a barrier precaution has also been shown to reduce the rate of HIV infection, and is a mainstay of prevention efforts.[138] The availability of condoms has a significant effect upon condom use and does not appear to increase rates of sexual activity.[139]

A marked increase in the number of incarcerated persons in the U.S. has paralleled an increase in HIV infection within the prison population. Half the increase in prisoners has resulted from convictions for drug offenses, and drug abuse fuels risk for HIV infection. It is estimated that a fourth of HIV infected persons in the U.S. are incarcerated for at least part of each year. In 2004, 1.8% of U.S. prison inmates were HIV positive, a rate four times that of the entire U.S. population. Prison administrators have generally been reluctant to institute prevention measures such as those promulgated by the World Health Organization.[140]

There are three major variables that explain the sexual transmission of HIV: (1) transmission efficiency, (2) number of sexual partners, and (3) seroprevalence (numbers of infected individuals in a population). HIV transmission through sexual exchange of semen or vaginal fluids is much less efficient than transmission of either gonorrhea or hepatitis B virus.

Usually, multiple sexual exposures are necessary to increase the likelihood for transmission of HIV from infected persons. It is estimated that gonorrhea may be transmitted in 22 to 25% of sexual encounters involving an infected individual, hepatitis B virus in 20 to 30% of encounters, and hepatitis C in 2% of sexual encounters. In contrast, HIV transmission occurs much less often--approximately 0.1% (1 infection per 1000 contacts) on average per genital sexual contact with an HIV-infected person in the absence of factors that increase likelihood of transmission. The greatest risk for transmission occurs soon after seroconversion when viremia is highest. However, some persons have become HIV-infected after a single sexual contact, while other persons have remained uninfected after hundreds of contacts.[141,142]

Estimates of HIV infectivity depend upon the nature of the sexual practice. For women the risk is 0.1% to 10% per receptive vaginal intercourse. The risk ranges from 0.1 to 1% for male insertive vaginal intercourse. For insertive anal intercourse, the risk varies from 0.1 to 1%, but 1% to 30% for receptive anal intercourse. [143]

The rate of sexual transmission of HIV may depend upon the number of viral particles in genital secretions. The number of CD4 cells per  $\mu\text{L}$  of seminal fluid ranges from  $10^2$  to  $10^3$ , while the number of virions can range from undetectable to over  $10^6$ . The numbers of virions in the female genital tract is generally lower. Transmission can occur both cell-to-cell as well as from cell-free fluid.[144,145] Thus, the transmission rate is two to three times higher from infected males to females than from infected females to males, without other cofactors.[146]

The location of HIV in cells of the genital tract of infected persons varies between men and women. In men, both the cells within seminal fluid, as well as the seminal fluid, harbor virions of HIV, but spermatozoa are not a major source for HIV. Since most of the cell-free HIV in the semen of men arises distal to the vas deferens, a vasectomy may have minimal impact on the infectivity of seropositive males to sexual partners.[147] Seminal vesicles harbor macrophages containing HIV.[148] In women, the greatest number of virions is present at the squamocolumnar junction of the cervix, with far less HIV in vaginal epithelium. Langerhans cells and macrophages in the lamina propria capable of harboring HIV can be found in a variety of epithelia.[149]

The type of mucosa it contacts affects transmission of HIV. HIV can be sequestered within squamous epithelium of the genital tract and can traverse epithelium via transcytosis, endocytosis-exocytosis, and productive infection with release of virions, or via penetration of gaps between epithelial cells. Though the thinnest epithelium (single cell layer) is in endocervix, the surface area of stratified squamous epithelia of vagina and ectocervix is much greater. HIV transmission can occur in the absence of cervix and uterus. In males, the poorly keratinized foreskin is the most vulnerable to HIV infection, and though circumcision may reduce the risk for transmission, HIV infection can occur in the absence of foreskin, most likely through penile urethra. Transmission of HIV through gastrointestinal tract mucosa is a function of oral and anal sexual practices. Gut-associated lymphoid tissue plays a role in this process. Additional cells that can become infected or harbor HIV within the epithelium or submucosa include CD4 lymphocytes as well as Langerhans cells and macrophages.[142]

For persons who have regular intercourse with a single HIV infected (index) partner, risk of transmission of HIV-1 depends upon the stage of HIV-1 infection. The risk is highest, 0.0082/coital act, within 2.5 months of seroconversion of the index partner. The risk drops to 0.0015/coital act within 6 to 15 months after index partner seroconversion and remains low throughout the stage of clinical latency of HIV-1 infection. The risk rises again in the late stage

of clinical AIDS, at a rate of 0.0028 per coital act, within 6 to 25 months of death of the index partner.[150]

The rate of HIV sexual transmission may also be due to the low infectivity of an individual strain of virus, propensity for only selected individuals to transmit infective virus in secretions, or presence of individual susceptibility factors.[114] Some HIV-1 subtypes may be more easily transmitted heterosexually, particularly subtype AE which is more prevalent in Asia. There is a greater tropism of the E subtype for Langerhans cells than subtype B, which is more prevalent in the U.S. and Europe.[104,149]

Sexual contact with persons whose HIV viral load is greater increases the transmission risk. Persons with HIV infection undergoing antiretroviral therapy that measurably lowers the viral burden in blood will have a reduction in viral particles in genital fluids of men and women that will render them less infective to others.[151,152] However, even with aggressive antiretroviral therapy, HIV may be detectable at low levels in blood and genital fluid.[153]

The risk for HIV transmission from an HIV-infected person increases as that person's immune status diminishes, as measured by a decrease in CD4 lymphocytes or an increase in HIV-1 RNA in plasma, so that infectivity is greater in the later stages of AIDS; likewise, a greater risk for transmission exists with the pronounced HIV viremia during primary HIV infection. Transmission rarely occurs when the HIV-1 RNA level in serum is less than 1500 copies/mL.[154] 136 In one model of heterosexual HIV transmission, the likelihood increased by 20% and that the annual risk of progression to an AIDS-defining illness or related death increased by 25% with every 0.3 log<sub>10</sub> increment in HIV-1 RNA. A 0.5 log<sub>10</sub> increment in HIV-1 RNA was associated with 40% greater risk of heterosexual transmission and 44% increased risk of progression to AIDS or death. A 1.0 log<sub>10</sub> increment in HIV-1 RNA was associated with 100% greater risk of heterosexual transmission and 113% increased risk of progression to AIDS or death.[155]

Variation in HIV-1 that occurs via viral mutation over time can lead to multiple variants co-existing within an infected person, and these variants may explain differences in progression of HIV infection, in progression, and in complications that develop. However, the nature of the HIV-1 transmitted via sexual intercourse appears to be closer to variants present earlier in the course of infection of the host. Thus, intrahost diversity of HIV is greater than interhost diversity. This may slow development of HIV diversity within populations.[156]

The presence of specific chemokine receptors plays a role in HIV transmission. Chemokine receptors provide a pathway, separate from CD4 receptors, for entry of HIV into cells. Mutations in the chemokine receptor genes appear to afford increased resistance to HIV infection or progression of disease for hosts homozygous for this genetic trait. Approximately 11% of Caucasians and 2% of Blacks are homozygous for the CCR5-delta32 mutation.[149]

The presence of cervical ectopia, oral contraceptive use, or pregnancy or menstruation in women, intact foreskin in men, and genital ulcer disease in either sex increases the risk for HIV infection. Cervical ectopy, with replacement of squamous by columnar epithelium, may increase the risk of HIV infection for women 5-fold.[141,149] The greatest determinant of HIV in cervical and vaginal secretions is the plasma level of HIV-1 RNA.[145] Increased detection of HIV can occur in women with vitamin A deficiency and in women receiving high dose oral contraceptives or depot contraceptives.[157]

Male circumcision reduces heterosexual transmission of HIV. The large numbers of Langerhans cells in foreskin and frenulum are poorly protected by keratin.[158] Herpes simplex virus type 2 (HSV-2), human papillomavirus (HPV), and genital ulcer disease among men, and



reduces bacterial vaginosis and trichomoniasis among female sexual partners. HIV acquisition in circumcised men may be reduced by 11% from reduction in symptomatic genital ulcers and by 9% from reduction in HSV-2 infections. Thus, male circumcision affords some degree of protection, so that the incidence of HIV infection is reduced 1.84-fold over uncircumcised men.[159,160]

There are multiple mechanisms by which the coexistence of other sexually transmissible diseases (STDs) may increase the infectivity of HIV. Both *Chlamydia trachomatis* and *Treponema pallidum* infection appear to increase HIV-1 replication. In men, urethritis with infection by *Neisseria gonorrhoeae* and *Trichomonas* has been shown to increase the amount of HIV-1 in semen. Likewise, in women cervicovaginal fluids contain more HIV-1, as well as CD4 cells when additional STDs are present.[149]

*Chlamydia trachomatis*, *Neisseria gonorrhoeae*, and *Trichomonas*, or diseases producing genital ulcers such as herpes simplex virus, chancroid (*Haemophilus ducreyi*) or syphilis (*Treponema pallidum*), all enhance infectivity by HIV. For example, HIV-1 virions can consistently be detected in genital ulcers caused by herpes simplex virus-2.[161,162] Both infectious HSV-2 and noninfectious particles induce Langerhans cell activation and decrease langerin expression as well as function. Continuous HSV-2 shedding from mucosal tissues maintains the presence of HSV-2 that blocks langerin function and induces the activation of Langerhans cells that aid in capture of HIV.[163]

Chancroid ulcer size is increased with presence of HIV, and there is increased viral shedding via ulcer exudation or bleeding. The pyogenic lymphadenitis (bubo) of chancroid often ulcerates as well. The *H ducreyi* infection increases CCR5 chemokine coreceptor expression by macrophages. HIV infection increases the incubation period for *H ducreyi* and increases the number of genital ulcers. There is slower healing with therapy for chancroid when HIV is present.[164]

Though treatment of these STDs may help to reduce the number of new HIV-1 cases, this is not always possible, since it has been shown that treatment with acyclovir to suppress herpes simplex virus does not reduce the incidence of infection with HIV-1.[165] The cofactor effect of genital ulcer disease is approximately five times higher for female-to-male than for male-to-female transmission. A higher prevalence of STD's in the population will equalize HIV transmission between the sexes.[146]

Intravaginal practices during sexual intercourse that introduce a variety of fluids or introduce objects that reduce vaginal lubrication ("dry sex") may increase the risk for transmission of HIV. This may occur through damage to the vaginal epithelium, increased inflammation, and greater prevalence of bacterial vaginosis.[166] The presence of bacterial vaginosis in HIV-infected women may increase the risk for transmission of HIV to male sexual partners.[167]

The use of crack cocaine can increase the transmission rate for HIV. This increase in infectivity can be due either to the greater numbers of oral sores with inflammatory cells containing HIV in the infected person or to the increased numbers of inflammatory cells with CD4 receptors in the contact person waiting to become infected, from the loss of an intact epithelial barrier.[168]

The use of methamphetamine may enhance transmission of HIV infection. Methamphetamine upregulates the expression of CCR5 receptors on macrophages. Methamphetamine also suppresses intracellular IFN- $\gamma$ /STAT1 expression to promote HIV infection of macrophages.[169]

Genital ulcers with inflammation also provide a more direct route to lymphatics draining to lymph nodes containing many CD4 lymphocytes, macrophages, and follicular dendritic cells.[164] Tissue trauma during intercourse does not appear to play a role in HIV transmission.[141] HIV-1 can be demonstrated in semen even in the first few weeks following acute infection, with a peak viral load at 30 days, then declining to reach a nadir at 10 weeks.[170] The transmission of HIV can occur with the act of sexual intercourse in any style or position, though a greater relative risk exists with anal receptive intercourse.[141]

Once HIV is introduced into a promiscuous population, seroprevalence increases with time. Increasing the number of sexual partners increases the likelihood of contacting a seropositive individual.[171,172] If the number of infected individuals in a population is high, then even one sexual encounter carries a significant probability of contacting an infected individual. This was demonstrated in one high risk group over a three year period (1978-1981) early in the AIDS pandemic in which the HIV infection rate was 44%.[173] Overall, the most important factor for both the spread and the risk of infection from HIV is the degree of sexual activity with multiple sexual partners.[142]

HIV has another important secondary means of spread through blood or blood products (Table 2). Parenteral exposure to blood and blood products is the most highly efficient method of HIV transmission—from 67% to over 90%.[143,174] There are many more peripheral blood mononuclear cells capable of either harboring or becoming infected by HIV in blood than are present in other body fluids or secretions. The number of infectious HIV particles free in peripheral blood can range from undetectable to well over a million per mL.[154]

The primary risk group for HIV transmission via blood exposure is injection drug users sharing infected needles. The estimates of infectivity per intravenous drug injection range from 0.63 to 2.4%. If needles are not shared, then this form of transmission will not occur. Less common practices of blood co-mingling, or use of instruments such as tattoo needles not properly disinfected, also carries a potential risk for HIV infection (Table 2). Health care workers with percutaneous exposures to HIV-containing blood, however, have an average rate of infection of only 0.3%.[174,175,176]

Before laboratory tests were developed to detect HIV, persons who received blood or blood products by transfusion were also at risk. Now when rigorous testing of donor blood is routinely done, this form of infection is extremely rare-- with a risk for occurrence of 1 case for 1 900 000 single donor units of screened blood for persons receiving transfusions of blood products in the U.S.[177] In a Canadian study encompassing years 2006 to 2009, the risk was 1 occurrence in 8 000 000 donations.[178] However, in developing nations where economic and political problems interfere with screening programs for blood products, 5 to 10% of HIV infections may occur from exposure to infected blood products.[179]

Even though HIV has been found in a variety of body fluids such as saliva, urine, feces, and tears, non-sexual transmission of HIV by these body fluids is improbable.[175,180,181] There is no evidence for HIV transmission by the aerosol route.[176] The lack of transmission is related in part to the paucity of HIV-infected cells in such secretions. Oral transmission of HIV by seminal fluid, milk, and colostrum may be due to their isotonicity, which overcomes hypotonic salivary inactivation. Even though the amount of virus is small in body secretions and presents a very small risk with routine household contact, prolonged contact or contact in sexually intimate situations with such fluids should be avoided.[182]

Transmission of HIV through anal receptive intercourse remains a significant factor driving prevalence of HIV infection, particularly in men having sex with men. A single layer of

columnar epithelium lines the rectum, and the underlying lamina propria contains abundant lymphoid cells. Rates of transmission average 0.3% to 5% per encounter.[142]

Oral transmission of HIV via oral-genital, oral-anal, or oral-oral routes is uncommon, with rates of transmission averaging just 0.04% per encounter.[142] Though there is a non-keratinized stratified squamous epithelium lining oropharynx, reduced rates of transmission are likely the result of fewer CD4+ lymphocytes in oral mucosa, presence of IgA antibodies in saliva, and endogenous salivary antiviral factors including lysozyme, defensins, thrombospondin and secretory leukocyte protease inhibitor (SLPI). However, the presence of erosions, ulcers or inflammation with bleeding (gingivitis or periodontitis) within the oral cavity may increase the risk of HIV transmission.[183]

Routine transmission of HIV occurs only through semen, vaginal fluid, blood or blood components, and breast milk.[22,184] In a liquid environment at room temperature, the virus can survive for at least 15 days, but despite HIV presence and survival in such an environment, infection through casual household and institutional contacts is rare, even when hepatitis is transmitted in the same setting.[180,185,186] Significantly, HIV transmission by insect vectors such as mosquitoes appears highly improbable.[181]

HIV infection can also be acquired as a congenital infection perinatally or in infancy (Table 2). Mothers with HIV infection can pass the virus to their babies transplacentally, at the time of delivery through the birth canal, or through breast milk in infancy and childhood. Of all perinatal transmissions, intrauterine transmission accounts for 15 to 20% of infections, while 45 to 50% occur during labor and delivery. Postpartum, up to 24 months, following birth, 30 to 40% of HIV transmission mother-to-child can occur. HIV-1 transmission to the fetus may occur through the placenta or by swallowing large amounts of infected amniotic fluid in utero or through contact with blood and vaginal secretions during delivery. Postpartum, HIV in milk from breastfeeding can cross mucosal surfaces in the gastrointestinal tract. Ingested fluids and cells with HIV can pass through the neonatal stomach that lacks an acid environment and reach the intestine. The passage of cell-free virus across placental trophoblasts is restricted, so transmission of HIV may rely on breaches of the placental barrier or on direct infection of placental cells or transcytosis of cell-associated virus. HIV can be detected in syncytiotrophoblasts, Hofbauer cells, and placental macrophages in the placenta during both early and late stage of pregnancy.[187,188]

The probability of breast-milk transmission of HIV-1 is calculated to be 0.00064 per liter ingested and 0.00028 per day of breast-feeding. Breast-milk infectivity is significantly higher for mothers with more advanced disease with higher prenatal HIV-1 RNA plasma levels and CD4 cell counts. The probability of HIV-1 infection per liter of breast milk ingested by an infant is similar in magnitude to the probability of heterosexual transmission of HIV-1 per unprotected sex act in adults.[189]

Vertical transmission of HIV-1 from mother to child from breast-feeding has been estimated to occur in 14% to 16% of women who breast-feed with an established maternal HIV-1 infection and in 29% with acute maternal HIV-1 infection. The risk for HIV-1 transmission from an infected mother to an infant through breast-feeding is increased with the duration of breast-feeding and with increased maternal viral load.[190] The risk for transmission of HIV-1 is also increased with presence of mastitis or breast abscess.[191] Most cases of HIV-1 transmission through maternal milk occur early during breast-feeding. HIV-1 can be detected in over half of breast milk samples from infected mothers.[184,187,192]. Replication of HIV-1 within mammary epithelial cells has been demonstrated, and is increased by hormonal

stimulation in pregnancy.[193] HIV and HIV-infected macrophages can transmigrate across fetal oral mucosal squamous epithelium. HIV-infected macrophages and, to a lesser extent, lymphocytes can transmigrate across fetal intestinal epithelia.[40]

Perinatal transmission leading to congenital AIDS occurs, on average, in one fourth of babies born to untreated HIV-1 infected mothers who appear well, and in two thirds of mothers with HIV related disease or prior vertical transmission. The most significant maternal risk factor for perinatal transmission is the HIV-1 viral load, but there is no safe threshold. Additional maternal factors cited for congenital HIV-1 transmission are: a low CD4 lymphocyte count, p24 antigenemia, prematurity, and placental chorioamnionitis or funisitis. Parity, race, mode of HIV acquisition, and sex of the baby do not appear to be significant factors in the vertical transmission of HIV.[194,195]

The likelihood for vertical HIV-1 transmission is markedly reduced, down to only 1%, by employment of multiple strategies: antiretroviral prophylaxis during pregnancy and in the intrapartum period, elective caesarean section, and neonatal antiretroviral prophylaxis. Mother to child transmission of HIV is further reduced by avoidance of breast-feeding. For patients with access to health care in developed nations, such strategies are possible, but not for disadvantaged patients.[196] A reduced duration of breast-feeding for uninfected children born to HIV-infected mothers living in low-resource settings has been associated with significant increases in mortality, even extending into the second year of life. Intensive maternal nutritional and counseling interventions reduce but do not appear to eliminate this excess mortality.[197]

Features of HIV-1 that appear to correlate with perinatal transmission include: rapid or high-titer replication in maternal human peripheral blood mononuclear cells, T-cell tropism, and resistance to neutralization or a sensitivity to enhancement of infection by maternal serum.[195] Measurement of maternal HIV-1 RNA can predict perinatal transmission risk. High levels of HIV-1 RNA late in gestation and/or during labor and delivery increase the risk for perinatal transmission. The frequency of perinatal HIV-1 transmission in the first and second trimesters is low. The risk for intrapartum transmission of HIV-1 increases with presence of virions within the genital tract, genital ulcer disease, cervical or vaginal lacerations, maternal-fetal microtransfusions from breaks in the placental barrier, and prolonged rupture of membranes.[198]

Though HIV-1 transmission from mother to fetus may still occur over a wide range of plasma HIV-1 RNA levels and of CD4 lymphocyte counts, antiretroviral therapy that reduces the HIV-1 RNA level to below 500 copies/mL appears to minimize the risk of perinatal transmission as well as improve the health of the mother. Thus, the maternal HIV-1 RNA level can predict the risk, but not the timing, of HIV transmission to their infants.[199,200]

To date, most reported perinatal HIV-1 cases in the United States have been a consequence of injection drug use by mothers, but an increasing proportion of cases is appearing from heterosexually acquired HIV by mothers.[194] Congenital AIDS is most common in populations where heterosexual HIV transmission and the frequency of women infected with HIV is higher. In contrast, perinatal transmission of HIV-2 occurs far less frequently, with a rate of only 1 to 2%.[201]

## **PATTERNS FOR HUMAN IMMUNODEFICIENCY VIRUS INFECTION**

Worldwide, three patterns of spread of HIV infection have been identified. In pattern 1, which affected primarily urban areas of the Americas and Western Europe early in the pandemic, the majority of HIV infections occurred in males having sexual intercourse with other males (homosexual and bisexual males), followed by infections in injection drug users. Fewer cases were initially observed among heterosexuals. Pattern 2 occurred in those areas in which HIV had been present longer and the number of HIV-infected persons in the population was greater. Men and women were affected equally, and heterosexual intercourse was the major means of transmission for HIV. These areas included sub-Saharan Africa and parts of the Caribbean where HIV infection occurred throughout the heterosexual population, and congenital AIDS was a significant problem. Pattern 3 occurred in areas of the world in which HIV has been introduced only recently, defined risk groups have not emerged, and only sporadic cases are reported. In the 21<sup>st</sup> century, education, prevention, and treatment campaigns have modified and reduced the spread of HIV.[202]

## **RISK GROUPS FOR HUMAN IMMUNODEFICIENCY VIRUS INFECTION**

Risk groups for HIV infection based upon behavior patterns that put persons at risk are detailed in Table 2. In countries such as the United States, through the first decade of the AIDS pandemic, about half of AIDS cases were reported in men having sex with men (homosexual or bisexual). The second largest risk group is comprised of injection drug users, accounting for 20% to 25% of reported AIDS cases in the United States. The percentage of HIV infections seen in heterosexual adults (marital sex, casual sex, commercial sex workers) has increased over time in developed nations. Pediatric AIDS in the United States and elsewhere is largely a function of maternal risk factors, particularly from injection drug use. In countries of sub-Saharan Africa and Asia, HIV infection is spread more widely in the population through heterosexually active urban adults [3,125,203]

The demography of the spread of HIV depends upon the population subgroups into which HIV has been introduced and the contact that other segments of the population have with them. Thus, commercial sex workers and injection drug use may both be important means for spread of HIV through the heterosexual population. AIDS among heterosexual adults in the United States is increasing more than any other risk group, and over half of all heterosexually acquired HIV infections occur in women. This represents a significant risk to the promiscuous or injection drug using heterosexual person. Screening of blood products for HIV has virtually eliminated the risk from transfusion or blood product therapy in locations where such screening is routinely performed.[204]

On average, about 5 to 10% of persons who develop AIDS will report no identifiable risk factor for HIV infection. Over time, many of them will be found to have a defined risk factor when historical data becomes available. The number of cases of HIV infection with no identifiable risk factor has not increased significantly over time, confirming the observation that HIV infection is not acquired through casual contact.[125,186]

## NATURAL HISTORY OF HIV INFECTION

On average, there is a latent period of 7 to 10 years from initial infection to clinical AIDS in adults, though AIDS may be manifested in less than two years or be delayed in onset beyond 10 years. About 10% of persons will rapidly progress to AIDS in 5 years following HIV infection, while up to 5% have not progressed to AIDS even after 10 years.[205,206] It is clear that the longer an individual is infected, the more likely the development of illness and subsequent death will be. Thus, HIV infection does not follow the pattern of more traditional viral diseases in which the risk of serious illness or death decreases with time. There has been no study to date that shows a failure of HIV-infected persons to evolve to clinical AIDS over time, though the speed at which this evolution occurs may vary, and a small number of HIV-infected persons will not progress to AIDS for many years.[125]

The development of disease states with AIDS from ongoing HIV infection can result from multiple mechanisms. Reduction in CD4+ lymphocytes through ongoing viral destruction, leads to loss of cell mediated immunity. This lack of immune surveillance increases the risk for opportunistic infections and development of neoplasms. Activation of mononuclear cells such as macrophages with release of cytokines promotes inflammation with cellular damage. Chronic immune activation can lead to endothelial cell dysfunction that promotes tissue damage.[46]

Primary HIV infection, also known as acute retroviral syndrome, may produce a mild and self-limited disease in 50 to 90% of persons infected with HIV, regardless of the mode of transmission. The time from mucosal infection to viremia is about 4 to 11 days. The time from exposure to development of symptoms averages 2 to 6 weeks. The symptoms may persist for 1 to 2 weeks, after which symptoms subside over 1 to 2 months. Prospective studies of acute HIV infections show that fever, fatigue, arthralgia or myalgia, lymphadenopathy, pharyngitis, diffuse erythematous macular or mixed maculopapular rash (often involving the trunk), diarrhea, nausea or vomiting, weight loss, night sweats, mucocutaneous ulcerations, and headache are the most common symptoms seen with acute HIV infection. An acute meningoencephalitis may be seen in some recent infections and appear as an “aseptic meningitis.” The symptoms of acute HIV infection resemble a flu-like or an infectious mononucleosis-like syndrome. Primary HIV infection is not life-threatening.[207,208] Primary HIV infection in children is usually accompanied by one or more of the following: mononucleosis-like syndrome, dermatitis, or generalized lymphadenopathy.[209]

In acute HIV infection, the peripheral blood may demonstrate lymphopenia and/or thrombocytopenia. However, atypical lymphocytes are absent. Although the CD4 cells are decreasing, the levels may initially remain in the normal range, but depletion continues. Simultaneously, there is an increase in cytotoxic CD8 lymphocytes that continues as symptoms subside and viremia decreases.[208]

During this acute phase of HIV infection, there is active viral replication, particularly in CD4 lymphocytes, and a marked HIV viremia. This peripheral blood viremia is at least as high as 50,000 copies/mL and often in the range of 1,000,000 to 10,000,000 copies/mL of HIV-1 RNA. High titers of cytopathic HIV are detectable in the blood so that the p24 antigen test is usually (but not always) positive, while HIV antibody tests (such as enzyme immunoassay) are often negative in the first three weeks. The viremia is greater in persons whose primary HIV infection is symptomatic.[21,95,207,208]

During this viremic phase, HIV disseminates throughout the body to lymphoid tissues and other organs such as brain. The doubling time for HIV virions may be just 20 hours. There are alterations in peripheral blood mononuclear cells marked by a decline in CD4+ lymphocytes. Persons acutely infected with HIV are highly infectious because of the high levels of HIV, both in blood as well as in genital secretions. Over half of all HIV infections may be transmitted during this period.[207]

Generally, within 3 weeks to 3 months following initial infection with HIV, the immune response is accompanied by a simultaneous decline in HIV viremia. Both humoral and cell mediated immune responses play a role. The CD4 lymphocytes rebound in number after primary HIV infection, but not to pre-infection levels. Seroconversion with detectable HIV antibody by laboratory testing such as enzyme immunoassay accompanies this immune response, sometimes in as little as a week, but more often in two to four weeks.[21,22,58] Prolonged HIV-1 infection without evidence for seroconversion, however, is an extremely rare event.[210] Persons infected with HIV who develop an acute retroviral illness and who have a shorter time to seroconversion tend to progress to AIDS faster than persons with longer seroconversion times.[211]

The laboratory staging of acute HIV infection is based upon the appearance of measurable laboratory markers. There are five initial stages, followed by a final stage with progression to AIDS. There is an initial eclipse period of 7 to 21 days in which no laboratory test is positive. Stage I lasts from 5 to 10 days and is marked by detection of HIV-1 RNA in blood. Stage II lasting 4 to 8 days has p24 antigenemia. Stage III over the next 2 to 5 days is marked by appearance of a positive enzyme immunoassay (EIA) on blood. Stage IV lasts 4 to 8 days, with an indeterminate Western blot test. Stage V is marked by a positive Western blot appearing over the next 40 days, though the p31 band is negative. In the late Stage VI years later, the p31 band is present.[212]

The HIV infection then becomes clinically "latent." During this phase, there is little or no viral replication detectable in peripheral blood mononuclear cells and little or no culturable virus in peripheral blood. The CD4 lymphocyte count remains moderately decreased. However, the immune response to HIV is insufficient to prevent continued viral replication within lymphoid tissues. Though lymph nodes may not become enlarged and their architecture is maintained, active viral replication continues.[44,213] Tests for HIV antibody will remain positive during this time but p24 antigen tests are usually negative. Seroreversion, or loss of antibody, is a rare event in HIV-infected persons, even those on antiretroviral therapy with prolonged suppression of viremia, and has been so far only reported in patients receiving antiretroviral therapy early after infection.[214]

Though the time to development of AIDS is statistically similar in men and women, the viral load of women tends to be lower. Women with half the viral load of men have a similar time to development of AIDS as men. Women with the same viral load as men have a 1.6-fold higher risk of AIDS. The biologic basis for this difference is unclear.[215]

In many viral infections, an immune response consisting of virus-specific CD4 lymphocytes helps to contain the infection. However, such a response is typically lacking in HIV-infected persons. A minority of HIV infected persons does mount a persistent polyclonal CD4 lymphocyte proliferation directed against HIV, which controls viremia. This response results in a cytokine response with elaboration of interferon gamma and beta chemokines. Such a response may also occur with antiretroviral therapy.[216]

As FDC's are diminished over time with HIV infection, the capacity for stimulation of CD4 lymphocytes is also diminished, and CD4 memory cells decline as well. However,

remaining FDCs continue to promote ongoing production of antibody to HIV. CD4 memory cells may also be lost by formation of syncytia with infected FDCs. Finally, when the stage of AIDS is reached, development of FDCs from stem cells is diminished.[101]

Cells of the innate immune system, including mononuclear phagocytic cells (monocytes and macrophages) are infected by HIV, and these relatively long-lived cells become a reservoir for infection. However, HIV can disrupt innate immune processes.[217] Also, HIV viremia is associated with increased Toll-like receptor (TLR) expression and responsiveness that plays a role in innate immune dysfunction.[218] Such disruption makes bacterial infections more likely to occur.

Though no clinical signs and symptoms are apparent, the immune system, primarily through depletion of CD4 lymphocytes, deteriorates. Not only CD4 cells are lost, but also cytotoxic CD8 cells, and the most avid ones in particular, leading to exhaustion of controlling T cell responses. Levels of cytokines driving lymphoid proliferation, such as IL-2, decrease.[96] The virus continues to replicate in lymphoid organs, despite a low level or lack of viremia.[58] HIV can be found trapped extracellularly in the follicular dendritic cell network of germinal centers in lymphoid tissues or intracellularly as either latent or replicating virus in mononuclear cells. The period of clinical latency with HIV infection, when infected persons appear in good health, can be variable--from as short as 18 months to over 15 years. This latent period lasts, on average, from 8 to 10 years.[21,58]

There is evidence that the thymus may retain some capacity to produce new T lymphocytes, even into adulthood, and that HIV could affect the dynamics of thymic function. A surrogate marker for thymic activity is the T-cell receptor excision circle (TREC) that is the result of the splicing of the variable (V), diversity (D) and joining (J) regions of the T-cell receptor (TCR) gene. TRECs are almost exclusively of thymic origin, are stable and do not degrade easily over time, and do not divide when a cell divides. Indeed, TREC may increase in chronically infected HIV patients who receive antiretroviral therapy.[219]

Emergence of HIV infection from clinical latency is marked by a decline in the CD4 lymphocyte count and an increase in viremia. Replication of HIV increases as the infection progresses. There is loss of normal lymph node architecture as the immune system fails. Before serologic and immunologic markers for HIV infection became available, clinical criteria established emergence from latency by development of generalized lymphadenopathy. This condition, described by the term persistent generalized lymphadenopathy (PGL), is not life-threatening.[22]

Another phase of HIV infection described clinically but no longer commonly diagnosed in practice, is the condition known as AIDS-related complex (ARC), which is not necessarily preceded by PGL. ARC lacks only the opportunistic infections and neoplasms, which define AIDS. ARC patients usually show symptoms of fatigue, weight loss, and night sweats, along with superficial fungal infections of the mouth (oral thrush) and fingernails and toenails (onychomycosis). It is uncommon for HIV-infected persons to die at the stage of ARC. The staging of HIV disease progression with CD4 lymphocyte counts and plasma HIV-1 RNA levels has made use of the terms PGL and ARC obsolete.[22]

The stage of clinical AIDS that is reached years after initial infection is marked by the appearance of one or more of the typical opportunistic infections or neoplasms diagnostic of AIDS by definitional criteria. The progression to clinical AIDS is also marked by the appearance of syncytia-forming (SI) variants of HIV in about half of HIV-infected patients. These SI viral variants, derived from non-syncytia-forming (NSI) variants, have greater CD4+



cell tropism and are associated with more rapid CD4<sup>+</sup> cell decline. The SI variants typically arise in association with a peripheral blood CD4 lymphocyte count between 400 and 500/ $\mu$ L, prior to the onset of clinical AIDS. However, appearance of the SI phenotype of HIV is a marker for progression to AIDS that is independent of CD4<sup>+</sup> cell counts.[96]

HIV superinfection can and does occur by subtypes of HIV different from the original infecting strain. This is not the same as coinfection, when a person is infected with two different HIV strains at the same time. Superinfection is difficult to diagnose, but it is estimated that the incidence rate may be up to 7.7% per year. Superinfection can have implications for disease progression, treatment, and viral evolution. The adaptive immune response following infection with HIV may prevent a superinfection from becoming productive. Conversely, a lack of heterologous neutralizing antibodies may predispose to superinfection. Superinfection may be suspected with any of the following: sudden increase in viral load, sudden drop in CD4 cell count, or recurrence of acute HIV symptoms. The most optimal period for a second infection appears to be restricted to a window period of less than 3 years after the initial infection, with the first few months after primary infection the most favorable for superinfection. Superinfections have been reported to occur during treatment interruptions. The incidence of HIV superinfections is mainly controlled by risk exposure, which consists of two aspects: risk behavior and HIV prevalence. Superinfections increase when HIV-1 prevalence goes up. In most, but not all superinfected patients, the second infection leads to faster disease progression. HIV superinfection can contribute to viral diversity by the generation of recombinant viruses. Recombination between HIV-1 genomes is an important viral evolutionary strategy. More than 20% of the current HIV-1 infections in Africa are estimated to represent recombinant strains.[220,221]

## PROGRESSION OF HIV INFECTION

The development of signs and symptoms of AIDS typically parallels laboratory testing for CD4 lymphocytes. A decrease in the total CD4 lymphocyte count below  $500/\mu\text{L}$  presages the development of clinical AIDS, and a drop below  $200/\mu\text{L}$  not only defines AIDS, but also indicates a high probability for the development of AIDS-related opportunistic infections and/or neoplasms. The risk for death from HIV infection above the  $200/\mu\text{L}$  CD4 level is low.[222,223]

Serum beta<sub>2</sub>-microglobulin (B2-M) is a polypeptide that forms the light chain of the class I major histocompatibility complex found on the surface membrane of most cells, including lymphocytes. It is increased with lymphocyte activation or destruction associated with HIV disease progression, but B2-M can also be elevated with viral infections such as cytomegalovirus and with malignant lymphomas. An increase in B2-M suggests progression of HIV infection. B2-M can be a less expensive surrogate marker for laboratory testing, compared with more expensive tests of lymphocyte subsets (CD4, CD8) and HIV-1 viral load.[224]

Other laboratory findings which indicate progression to AIDS include HIV p24 antigen positivity, elevated serum IgA, or increased neopterin levels in serum, cerebrospinal fluid, or urine. The p24 antigen is a highly specific predictor of progression, but only about 60% of HIV-infected persons develop p24 antigenemia prior to onset of clinical AIDS. Neopterin, a product of macrophages, is also a measure of immune system activation and can predict HIV disease progression. The information provided by these tests is similar, so no advantage accrues from performing all of them simultaneously.[225]

The best laboratory measure for determination of the progression of AIDS for therapeutic purposes is the level of HIV-1 RNA in peripheral blood. The predictive value of HIV-1 RNA levels is independent of the CD4 lymphocyte count and of age in adults. During the acute phase of HIV infection prior to any immune response, plasma levels of HIV-1 RNA typically exceed 10,000 copies/ $\mu\text{L}$ . The initial viral load following HIV infection is 50,766 copies/mL in men and 15,103 copies/mL in women.[215]

These levels of HIV-1 RNA generally drop following initial infection, but may fluctuate for a period ranging from 6 to 9 months. After this time, a “set point” is reached for the level of HIV-1 RNA that remains low and relatively constant during the latent phase of HIV infection. Factors influencing this set point include the strain of HIV-1, host anti-HIV response, and the number of cells, including CD4 lymphocytes and macrophages, available for infection. The initial viremia may be higher, and the set point may not be reached until after infancy, in cases of congenital HIV infection.[226] Genital inflammation during early HIV-1 infection is associated with higher viral load set point and CD4 depletion that predict more rapid disease progression.[227]

The set point levels of HIV-1 RNA correlate with the time to development of AIDS. The set point can range from <50 to 1,000,000 copies/mL. Persons with a higher set point tend to lose CD4 cells more rapidly and progress to AIDS more quickly. Levels of HIV-1 RNA can remain at a steady state for months to years, but usually fall with time. Levels in any individual person may vary with time and even change rapidly, though a variation of  $<0.7 \log_{10}$  copies/mL is typical, but an upward progression is an ominous sign of probable progression to AIDS. Less than half of persons with low levels (<4500 copies/mL) of HIV-1 RNA have progressed to AIDS at 10 years following seroconversion, and those with levels <200 copies/mL do not appear to progress at all. Conversely, persons with >100,000 copies/mL are 10 times more likely to

progress to AIDS in 5 years. For persons in the top quartile ( $>36,270$  copies/mL) the median time to development of AIDS is 3.5 years.[95,226] The presence of opportunistic infections and neoplasms increases the risk for progression to death from HIV infection.[228] In spite of the initial viral load difference between men and women, the rates of progression to AIDS are similar.[215]

Persons with HIV infection can be categorized as typical progressors, rapid progressors, long-term nonprogressors, and elite controllers. The typical progressors average 7 to 10 years of “latent” HIV infection following a fall in HIV viremia after acute infection and before the appearance of clinical AIDS. They maintain nonsyncytium-inducing HIV variants that replicate slowly over time, until more rapidly replicating variants develop during progression to AIDS. About 10% of HIV-infected persons rapidly progress to AIDS in less than 5 years following initial infection. These persons have a high viral load during acute HIV infection that does not fall to the levels seen with typical progressors. They may have become infected with more virulent strains of HIV. Long-term nonprogressors maintain a high CD4 count for more than 7 to 10 years without antiretroviral therapy, and up to 5 to 10% of HIV-infected persons may follow this course. Elite controllers suppress HIV-1 RNA to undetectable levels for more than a year without antiretroviral therapy. Regardless of the variations in the course of HIV infection, all persons will eventually progress to AIDS if left untreated.[206,229]

Genetic factors play a role in progression of HIV infection. Persons with HLA alleles B\*5701, B\*5703, B\*5801, B27, and B51 exhibit better viral control and slower progression of disease to AIDS. Persons with the 801le variant of the Bw4 motif, a ligand for the killer immunoglobulin-like receptors KIR3DS1 and KIR3DL1, which control NK cell function, also have delayed progression to AIDS.[67] The course of progression of HIV infection in children is often faster than that for adults. Genetic factors known to accelerate HIV disease progression in children include the presence of CCR5 59029A, CXCL12 3'A, CX3CR1 2491, MBL-2, and APOBEC3G.[230]

Recombination of HIV subtypes may produce more evolutionarily fit viral strains. HIV subtype recombination may give rise to a more pathogenic strain of virus if genomic fragments from different subtypes join together in a better replicating virus. CRF19 is a recombinant of HIV subtypes D, A, and G. Subtype D has been associated with faster and A with slower disease progression. CRF19 appears evolutionary very fit and has been reported to cause rapid progression to AIDS in many newly infected patients in Cuba.[231]

Though most HIV infections follow a standard progression, the course can be variable, and previously asymptomatic persons may suddenly die from an overwhelming opportunistic infection, while persons with clinically defined AIDS may survive for years. Progression to AIDS in persons with HIV infection does not appear to be modified by race, and the course of HIV infection is not modified by risk factor for infection. Progression to AIDS does appear to be accelerated in persons who are older or who smoke.[232,233,234] Persons who manifest symptomatic acute HIV infection have a faster progression to clinical AIDS.[207]

Women can have different immune responses to HIV infection than men. Following HIV-1 infection with seroconversion, women may have up to 40% lower HIV-1 RNA and higher CD4+ T-lymphocyte counts. However, with a similar viral load, progression to AIDS is faster in women. There is greater innate immune activation in women, with higher amounts of interferon-alpha.[235]

Older age at seroconversion with HIV infection is associated with faster progression to AIDS. Elderly persons may be at greater risk of HIV disease progression and poorer response to

treatment because: (1) they have greater thymic involution and fewer T cells, which may impair recovery of CD4+ cell numbers with treatment; (2) they have increased T cell chemokine co-receptor expression, which may facilitate viral entry into certain immune cells; and (3) older adults have reduced production of IL-2 and IL-2 receptors that affects T cell function and promotes a shift from naïve to more terminally differentiated T cells, leading to immunosenescence. Hence, CD4+ cell reconstitution with antiretroviral therapy is significantly slower than in younger patients, even despite a better virologic response. Side effects and toxicities of antiretroviral drugs occur more frequently in older patients, who also have more co-morbidities and a higher chance of pharmacological interactions with other medications they may be taking. [236]

Co-infection with the flavivirus GB virus C (GBV-C), also known as hepatitis G virus, is associated with a slower rate of progression of HIV infection with a reduced mortality rate. Hepatitis G virus itself is not known to be associated with any specific disease process. However, the presence of GBV-C may inhibit HIV replication, as shown in vitro with inhibition of HIV with coinfection of peripheral blood mononuclear cells by GBV-C. The prevalence of GBV-C is 1.8% in blood donors, though its presence does not preclude blood donation. The prevalence of GBV-C in HIV infected persons is about 40%. [237]

Dietary supplementation with the trace element selenium has been suggested to partially suppress induction of HIV-1 replication in chronically infected mononuclear cells exposed to tumor necrosis factor (TNF). Selenium supplementation may increase cellular antioxidant activity. Selenium deficiency has been associated with increased mortality from HIV-1 infection in some studies. [238]

About 5 to 10% of persons infected with HIV-1 are long-term nonprogressors, or "long survivors," who do not demonstrate a significant and progressive decline in immune function over more than 10 years. They do not appear to progress to AIDS in a manner similar to the majority of HIV-infected persons. Findings in these "long survivors" include: a stable CD4 lymphocyte count, negative plasma cultures for HIV-1, fewer HIV-infected cells, and a strong virus-inhibitory CD8+ T-lymphocyte response. Differences in viral load do not appear to be associated with viral subtype, viral growth kinetics, or with the presence of neutralizing antibodies. [206,229]

In addition, by microscopic examination the lymph node architecture of "long survivors" with HIV infection is maintained without either the hyperplasia or the lymphocyte depletion that is common to progression to AIDS. Though peripheral blood mononuclear cells contain detectable HIV-1 and viral replication continues in long survivors, their viral burden remains low. [239] A strong host virus-specific CD4 lymphocyte response in these persons may also aid in controlling HIV viremia. [216]

The "elite controllers" of HIV typically suppress viremia below the limit of detection, <50 copies/mL, even in the absence of antiretroviral therapy. Though they have an initial viremia following primary infection with HIV, their immune systems quickly gain control. They have a minimal CD4 lymphocyte decline, and their CD4 response is polyfunctional, without loss of specific CD4 clones. Their cytolytic NK cells are preserved. They have a more polyfunctional CD8 cytotoxic lymphocytic response, with strong granzyme-B-mediated cytotoxicity. [240] Less than 1% of HIV-infected persons achieve such control, and are demographically heterogeneous with diverse racial backgrounds and modes of HIV transmission. [241]

There is evidence that genetic polymorphisms in the chemokine receptors present on cells susceptible to HIV infection may play a role in progression of AIDS. At least in some persons infected with HIV, the presence of chemokine receptor variants, including the CCR5 delta32 deletion or the CCR2B-64I mutation, have a favorable effect in slowing the progression of disease. The CCR5 gene encodes the coreceptor for macrophage-tropic HIV-1, so reduced expression of CCR5 leads to reduced viral replication in macrophages.[242] A lower density of CCR5 molecules on peripheral blood mononuclear cells has been shown to correlate with lower plasma HIV-1 RNA levels and reduced loss of CD4 cells over time.[243] Patients homozygous for the chemokine receptor CX3CR1 progress to AIDS more rapidly than those with other genotypes.[244]

Genetic variations in HIV may play a role in disease progression. The HIV-1 *nef* gene product activates production of T-cell attracting chemokines and contributes to the development HIV infection associated brain damage. Nef also downregulates CD4 and CCR5 expression and downregulates a subset of class I MHC molecules which contributes to viral immune evasion. Extracellular nef may facilitate the spread of T-cell-tropic HIV variants and mediate a switch in dominant replicating HIV strains from macrophage-tropic to T-cell-tropic viruses. Nef-deleted or nef-attenuated may be present in nonprogressors.[245]

Genetic variations in major histocompatibility (HLA) genes may determine HIV disease progression. An HIV-1 envelope glycoprotein fragment mimics both HLA class 1C molecules and an immune regulatory epitope in the HLA DR beta chain, which furnishes peptides predicted to bind optimally to HLA class 1B alleles. The HLA class I genes A29 and B22 are significantly associated with rapid progression, while the alleles B57, B27, B14, and C8 are significantly associated with non progression of AIDS.[246,247,248]

HLABw480I alleles imparting reduced risk for HIV infection have the potential to bind NK cell inhibitory KIR (KIR3DL1). The combined expression of specific KIRs in conjunction with their HLA class I ligands is protective in HIV-1 disease. The HIV-1 Nef protein provides immune evasion. Nef protein triggers the accelerated endocytosis or retention of HLA class I molecules. Nef downregulates HLA class I molecules differentially to protect infected cells from NK cell mediated lysis. *Nef* mostly downregulates HLA-A to reduce recognition by specific cytotoxic CD8 cells. *Nef* partially downregulates HLA-B, but spares HLA-C, both of which are the primary ligands for inhibitory NK cell receptors.[249]

For cases of perinatally acquired HIV infection prior to availability of antiretroviral therapy, the observed time period from birth or neonatal life to the development of clinical AIDS was variable and often shorter than in adults. Clinical signs associated with HIV infection appeared in over 80% of seropositive infants by the age of 5 months. Infants in whom such signs appeared at 3 months or less tended to have decreased overall survival. In the era of antiretroviral therapy, with over 90% of infants receiving such therapy by age 5, at least three fourths survive to age 10 and almost half to age 16, with only one fifth progressing to AIDS by adolescence.[250,251]

The level of HIV-1 RNA rises rapidly in the first one to two months of life but remains high, and declines only slowly during the first two years of life. This suggests that the neonatal and infant immune system is not able to effectively contain HIV replication. Those babies whose HIV-1 RNA levels are very high, not only in the first few months of life, but also in the first two years, tend to progress to AIDS more rapidly than those with lower levels.[252]

Progression of disease appears to be faster in children whose strains of HIV-1 show tropism for monocyte-derived macrophages and also whose viral strains are rapidly

replicating.[253] Skin test anergy as demonstrated by the loss of delayed-type hypersensitivity to standard antigens such as *Candida* and *Trichophyton* also correlates with HIV disease progression.[254]

Adolescents with HIV infection may have variable clinical courses. Adolescents acquiring HIV infection via sexual intercourse or injection drug use tend to have progression of their infection similar to adults. Those with congenital AIDS or who acquired their infection from blood products as young children will have a course different from long-term surviving adults.[226]

In summary, multiple factors influence the time course for progression to AIDS. In general the prognosis is worse from probable accelerated progression when:

- \* Less favorable chemokine receptor variants are present
- \* Syncytia-forming (SI) variants of HIV are present
- \* Acute HIV infection is symptomatic
- \* HIV infection occurs with a drug-resistant strain
- \* A higher “set point” of HIV-1 RNA follows initial viremia after infection
- \* There is an older age at seroconversion
- \* The infected person is a smoker
- \* An opportunistic infection or neoplasm is present
- \* In congenital cases there are signs of infection at <3 months of age

In addition, progression to AIDS from the period of clinical latency in persons with HIV infection is suggested by:

- \* CD4 lymphocyte counts <500/ $\mu$ L
- \* Failure to maintain normal lymph node function
- \* p24 antigenemia appears in peripheral blood
- \* Increasing HIV-1 RNA levels

## IDIOPATHIC CD4+ T-LYMPHOCYTOPENIA

Increased laboratory testing in patients with immunodeficiency states has led to the recognition that CD4 lymphocyte counts in some cases can be markedly decreased in the absence of laboratory evidence for HIV infection. These uncommon, sporadically reported cases are unlikely to represent infection by new HIV subtypes that are not detectable by current laboratory testing methods. Criteria for diagnosis of ICL include:

- \* The absolute CD4 lymphocyte count is  $<300/\mu\text{L}$  or more in adults and children  $>2$  years ( $<1000/\mu\text{L}$  in children  $<2$  years) on more than one determination, or in children a T-lymphocyte count that is  $<20\%$  of total lymphocytes; and
- \* There is no serologic evidence for HIV infection (even if in a child and the mother is HIV seropositive); and
- \* There is no defined immunodeficiency or therapy associated with T-cell depletion

Though some patients with ICL may have a risk factor for HIV infection or even an opportunistic infection, the CD4 lymphocyte count does not progressively decrease over time as with AIDS. Almost all patients with ICL have normal serum immunoglobulin levels. The initial CD4/CD8 ratio is  $<1$  in 85% of cases. The stable CD4 lymphocyte counts may be accompanied by reductions in the levels of other lymphocyte subsets, including CD8+ T-lymphocytes, natural killer cells, and B-lymphocytes. This disorder appears to be rare and is generally associated with transient illness. The presence of ICL does not constitute evidence for a new transmissible infectious agent.[255,256] A Behçet-like syndrome has been reported in conjunction with ICL.[257]

Most ICL patients will present in middle age with an opportunistic infection. The most common opportunistic infections with ICL are cryptococcosis, human papillomavirus, and nontuberculous mycobacteria. Less common infections include histoplasmosis, mucosal candidiasis, herpes zoster, *Pneumocystis* pneumonia, and cytomegalovirus pneumonia. About a fourth of ICL patients have an autoimmune disease at some point in the course of their disease, including such conditions as systemic lupus erythematosus, antiphospholipid syndrome, Graves disease, autoimmune hemolytic anemia, ulcerative colitis, psoriasis, vitiligo, and thyroiditis. About a fifth of patients have resolution of lymphocytopenia after three years.[258]

Molecular studies have shown that ICL is associated with a defect in CXCR4 expression on the surface of CD4 lymphocytes. There is abnormal intracellular accumulation of CXCR4 and of its natural ligand, the chemokine CXCL12. This abnormality reduced the CD4 cell chemotactic response to CXCL12 but preserved CXCL8 sensitivity. Administration of IL-2 reversed the defect.[259] There is increased CD4 cell activation and increased turnover that may represent an abnormal response to a triggering infection.[258]

## PREVENTION OF HIV TRANSMISSION

If everyone with a risk factor for HIV infection underwent prompt HIV testing, and if everyone identified as positive for HIV received ongoing antiretroviral therapy, then viremia could be suppressed to undetectable levels so that infectivity to others would be very low. Decreasing infectivity to near 0 by this strategy would markedly reduce the number of new infections. Infected persons could live a near normal lifespan on antiretroviral therapy.

The transmission of HIV in definable risk groups allows control measures to be taken that prevent the spread of AIDS. Since HIV is primarily spread as a sexually transmissible disease, then educational efforts must be aimed at sexually active persons and must be explicit regarding the behaviors that lead to the spread of HIV. A significant number of both boys and girls become sexually active as teenagers and must be included in prevention strategies. Given that the level of promiscuity will often be difficult to modify within a population, then educational campaigns are best focused upon the use of barrier precautions, particularly condom use. All sexually active persons with more than one sexual partner, or whose partner is a member of a risk group for AIDS, should use condoms. Persons who know that they are infected with HIV should inform their sexual partners.[260,261,262] Sexual activity does not appear to increase with condom use.[139]

Health care providers need to offer HIV testing when the situation warrants it, in order to identify infected persons. Persons who do not know they are infected are more likely to infect others. In a study involving persons in an urban setting, over 90% of whom were seen by a physician who was a general practitioner, over half with an identifiable risk factor for HIV infection did not have HIV testing proposed to them. Over 80% of patients who had an identifiable AIDS-related illness did not have HIV testing proposed.[263] In another study from an academic hospital emergency department, only 28% of patients tested for syphilis, and only 4% tested for either gonorrhea or chlamydial infection, were also tested for HIV.[264] Opportunities to provide HIV testing should not be missed.

Socioeconomically disadvantaged persons, and women in particular, are at increased risk for HIV infection. They have more limited educational opportunities. They may not have access to treatment for sexually transmitted infections and for HIV testing. They often lack access to antiretroviral therapy following infection.[265,266,267]

The spread of HIV by injection drug use creates a major reservoir for HIV infection that can then be transmitted to other segments of the population, particularly heterosexual adults, including the sexual partners of injection drug users. Drug users must be educated about the risks of needle sharing. Cleaning of needles with undiluted bleach appears effective in preventing HIV transmission.[268] They can be provided with clean needles to prevent the spread of HIV, and can be advised to use condoms.[269]

Congenital AIDS can be prevented by efforts to educate women of childbearing age about the hazards to the fetus if they are HIV-infected. Potential mothers can be provided with means of contraception. Antiretroviral therapy for mothers can reduce perinatal HIV transmission. Confidential HIV testing should be made available along with counseling services to persons in all risk groups to encourage voluntary testing and prevent unknowing transmission of HIV.[270]

Transmission of HIV through blood product therapy has become vanishingly rare when screening and testing of donors is applied. Such screening is costly. Since HIV infection is not



spread by casual contact in public places, households, or in the workplace, no modifications of routine activities of daily living or work practices is necessary. Insect vectors do not spread HIV, and insect control programs will have no effect upon HIV transmission in a population.

HIV/AIDS prevention programs have successfully produced long-term behavior change with reduction in incidence of HIV infection.[271] In order for such programs to be effective, several principles must be applied: sustained interventions are more likely to lead to sustained behavior change; more intense interventions are more likely to result in greater risk reduction; accessibility to devices (such as clean needles and condoms) that are necessary to safer practices reduces the risk for HIV infection; modification of community norms appears to enhance behavior change; and explicit HIV prevention programs must be provided prior to the time that adolescents become sexually active.[16]

Research has been aimed at prevention of HIV transmission during sexual intercourse. This approach could be of potential benefit to HIV discordant couples. A study comparing once-daily oral tenofovir (TDF), combination tenofovir–emtricitabine (TDF–FTC), and placebo showed that either TDF or TDF-FTC was effective in reducing HIV transmission in heterosexual men and women.[272]

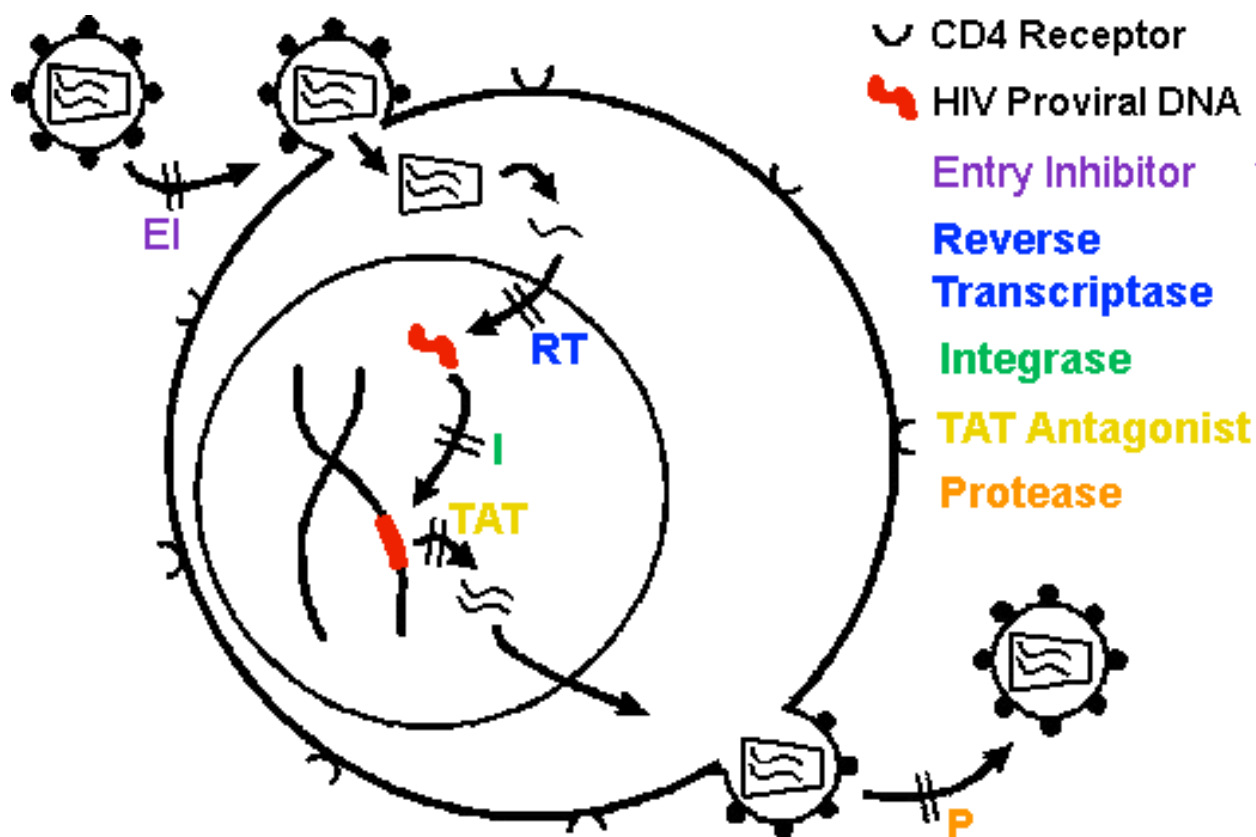
A summary of AIDS prevention strategies is given below:[273,274]

### **Methods to Reduce Rates of HIV Transmission**

- \* Treat HIV infection as an illness, not as a social stigma
- \* Reduce levels of poverty in society that lead to increased risks through drug abuse and promiscuity
- \* Provide HIV testing and counseling to identify infected persons who can reduce their risk to others
- \* Provide educational programs for children and adults which describe how to avoid sexually transmitted diseases
- \* Promote sexual barrier precautions among high risk commercial sex workers and clients
- \* Provide clean needles for injection drug users
- \* Offer male circumcision
- \* Create health care programs with ongoing support to provide antiretroviral therapy to extend life and reduce HIV transmission rates
- \* Give HIV-infected pregnant women antiretroviral therapy to reduce perinatal HIV transmission
- \* Consider pre-exposure prophylaxis with antiretroviral drugs
- \* Provide antiretroviral therapy suppressing viral load to undetectable levels

## TREATMENT FOR HIV/AIDS

A variety of therapies has been developed since 1984 for persons infected with HIV. Bone marrow transplantation, lymphocyte transfusions, thymic transplantation, and therapeutic apheresis to remove virus-bearing cells were tried without significant success against HIV infection and are no longer employed.[275] Antiretroviral therapies are aimed at diminishing HIV replication and subsequent destruction of the immune system with progression to AIDS. A variety of pharmacologic agents has been developed to treat HIV infection.[276] None of these agents can completely eliminate HIV from infected persons. Moreover, experimental *in vitro* anti-viral effects do not always occur *in vivo*. [226] Table 3 lists drugs available to treat HIV infection. The following diagram shows potential target points in the HIV life cycle for drugs.



**REVERSE TRANSCRIPTASE INHIBITORS.**-- The first effective antiretroviral agent was zidovudine (ZDV), a nucleoside analog initially called azidothymidine (3'-azido-3'-deoxythymidine), or AZT. ZDV, a thymidine analogue, is phosphorylated by cellular enzymes to an active triphosphate form that, as a nucleoside analog, interferes with viral reverse transcriptase. ZDV is structurally similar to building blocks of nucleic acids, but with replacement of the hydroxy group in the 3' position by another group unable to form the 5' to 3' phosphodiester linkage required for DNA elongation, thus competing with natural substrates and incorporating into viral DNA to act as a chain terminator in synthesis of HIV proviral DNA.[276] ZDV is useful in prolonging the lives of treated patients by decreasing the frequency

and severity of opportunistic infections, by partially suppressing HIV replication, and by transiently increasing CD4 lymphocyte counts.[277]

In the 1990's, additional nucleoside analog drugs with clinically useful antiretroviral effect against HIV were developed, including didanosine (ddI), zalcitabine (ddC), stavudine (d4T), lamivudine (3TC), and abacavir. These drugs are known as nucleoside reverse transcriptase inhibitors (NRTIs). All of the NRTI's require phosphorylation to an active triphosphate metabolite. Didanosine is converted to dideoxyadenosine and then phosphorylated to an active triphosphate within cells. Zalcitabine is metabolized within cells to dideoxycytidine (ddC) in an active triphosphate form. Stavudine is also phosphorylated intracellularly to the active form of the drug stavudine-5'-triphosphate. Lamivudine undergoes intracellular phosphorylation to lamivudine triphosphate. Abacavir, unlike the other NRTI's, is a guanine analogue that, when converted to the active form carbovir triphosphate, competes with the natural substrate dGTP.[278]

The acyclic nucleoside phosphonates include adefovir, tenofovir, and cidofovir and have antiretroviral activity but do not require phosphorylation. This feature helps to avoid the potential rate-limiting phosphorylation step that may limit activity in some infected cells. These drugs also have limited cross-resistance to the nucleoside NRTI drugs. Toxicity is similar to the NRTI's, but may also include nephrotoxicity from toxic acute tubular necrosis.[278,279] Another nucleotide reverse transcriptase inhibitor (NtRTI) is tenofovir (tenofovir disoproxil fumarate) that is an acyclic phosphonate analogue and which may be useful for treatment in cases where HIV mutations have rendered nucleoside analogue drugs ineffective.[280]

Drug intolerance and drug toxicity are significant problems for all drugs used to treat HIV infection. Many of these adverse effects appear to be mediated via mitochondrial toxicity, such as liver toxicity with steatosis and lactic acidosis seen with NRTI therapy, manifested by abdominal pain, nausea, or vomiting, and with a mortality rate near 50%.[281] Patients must be monitored carefully for signs and symptoms of these complications. Zidovudine can cause gastrointestinal symptoms of nausea and vomiting, like other NRTI's, as well as headache, but more importantly, it can occasionally lead to severe bone marrow suppression with anemia, usually in the first few months of administration. Myopathy may also occur with long term zidovudine therapy.[277] Hepatic mitochondrial damage can occur with the NRTIs zidovudine or didanosine.[282]

Major toxicities associated with didanosine therapy that limit its use include hepatotoxicity, pancreatitis, peripheral neuropathy, and gastrointestinal problems such as diarrhea. Zalcitabine therapy was most often complicated by peripheral neuropathy (which led to its removal from use), pancreatitis, maculovesicular cutaneous eruptions, and aphthous oral ulcers (stomatitis). Stavudine's major side effect is peripheral neuropathy, though anemia and pancreatitis may also occur. There are infrequent major adverse reactions with lamivudine therapy, the most common being gastrointestinal upset.[276,283] Abacavir therapy can be complicated by a hypersensitivity reaction with flu-like symptoms, abdominal cramping, diarrhea, and skin rash in up to 5% of cases.[278] Stevens-Johnson syndrome and/or toxic epidermal necrolysis has been reported to complicate NRTI, NNRTI, and PI therapy.[284]

Non-nucleoside reverse transcriptase inhibitors (NNRTIs) have been developed to treat HIV infection. These drugs act via direct and non-competitive binding to a hydrophobic pocket close to the active site of the reverse transcriptase enzyme of HIV. This binding causes a conformational change and disrupts the catalytic site of reverse transcriptase.[276] Mutations render HIV-1 group O and HIV-2 strains either resistant or less effective at non-toxic dosages to

all drugs within the entire NNRTI class, due to a single amino acid, Leu-188.[112] The first generation drugs include nevirapine, delavirdine, and efavirenz. Second generation drugs with less cross-resistance include the diarylpyrimidines: etravirine and rilpivirine. They are most useful when either is used in combination with other antiretroviral agents. The major complication after starting NNRTIs is skin rash, usually within six weeks.[283,285]

The NNRTIs nevirapine and efavirenz are inducers of hepatic cytochrome CYP3A4, while delaviridine inhibits it. Hepatotoxicity with hepatic enzyme elevation has been reported with NNRTIs. The use of PIs in combination with either efavirenz or nevirapine was associated with an increased risk of hepatotoxicity compared to efavirenz or nevirapine alone. In addition, nevirapine and efavirenz are associated with hypersensitivity reactions, including skin rash. The HLA-DRB1\*01 allele is significantly associated with isolated rash alone in patients exposed to nevirapine or efavirenz. Nevirapine has a high rate of treatment discontinuations from gastrointestinal intolerance. Nevirapine has with pancreatic toxicities, but not efavirenz.[282]

**PROTEASE INHIBITORS.--** Protease inhibitors are an important class of anti-HIV drugs. The processing of large HIV precursor proteins, such as p55 and p40 encoded by the *gag* and *gag-pol* genes of HIV into smaller structural proteins p17, p24, and p7 of the viral core is performed via proteolytic cleavage by an HIV-encoded aspartic protease. This late step in virus production is necessary for maturation of immature viral particles into infectious virions. These drugs are synthetic analogues of the HIV protein and block the action of HIV-protease to interfere with viral replication.[286] Tipranavir is a non-peptidic protease inhibitor.[287]

All protease inhibitors are substrates for cytochrome P450, mainly CYP3A4, and most are inhibitors of this metabolic pathway. Ritonavir is the most potent inhibitor. both lopinavir and tipranavir are inducers of CYP3A4. Thus, protease inhibitors have extensive interactions with each other. Most antiretroviral regimens with protease inhibitors include ritonavir with another agent in order to boost effective drug concentrations.[276]

Problems in the development of this class of drugs have included finding an effective, specific inhibitor of HIV protease that does not also interfere with normal cellular proteases, as well as HIV viral resistance. Effective drugs include saquinavir (saquinavir mesylate), ritonavir, indinavir (indinavir sulfate), nelfinavir, and amprenavir, all of which are well tolerated and efficacious in reducing plasma HIV-1 RNA along with increasing CD4 lymphocyte counts. In addition, protease inhibitors show efficacy in combination with reverse transcriptase inhibitors. Nevertheless, HIV resistance to protease inhibitors does occur and limits effectiveness.[286,288]

Protease inhibitors are often most effective at high dosages, but adverse reactions to these toxic agents may limit their use. All of them may cause gastrointestinal symptoms including nausea, vomiting, and diarrhea. GI intolerance is a cause of lopinavir/ritonavir therapy modification or interruption. Their use may be accompanied by the adipose tissue redistribution known as protease inhibitor-associated lipodystrophy (PIAL), though this phenomenon may occur in persons with AIDS not taking protease inhibitors. This syndrome is associated with loss of facial fat, dorsocervical tissue accumulation, increased internal abdominal fat accumulation, hyperlipidemia (often exceeding 1000 mg/dL), peripheral insulin resistance and impaired glucose tolerance, but there is a wide variation in the severity and clinical presentation of these metabolic side effects. The dyslipidemia is most pronounced with ritonavir.[289] The agent atazanavir appears to affect glucose metabolism less than other protease inhibitors.[290]

All PIs, particularly ritonavir, can be associated with hepatic transaminase elevations as well as unconjugated hyperbilirubinemia, particularly with indinavir.[282] PI therapy can be a

risk factor for development of HIV-associated sensory neuropathy.[291] Nephrolithiasis may complicate indinavir therapy when patients do not receive adequate hydration. In addition, hyperbilirubinemia may occur with indinavir therapy. Paresthesias may complicate ritonavir therapy. Amprenavir is associated with skin rashes and with hypersensitivity reactions. Hypersensitivity to abacavir is determined by the presence of HLA B\*5701, which can be tested prior to starting therapy. Gastrointestinal intolerance frequently leads to saquinavir therapy modification or interruption. Dosing regimens for these and other medications can be complex and difficult to follow for patients, but must be followed carefully in order to have maximum effectiveness and prevent development of HIV resistance.[278,282,286,288] Since PIs are metabolized by the cytochrome CYP450 enzymes in the liver and small intestine, there is a potential for drug interactions via this metabolic pathway.[292]

The use of NRTIs, NNRTIs, and PIs formed the mainstay of antiretroviral therapy through the early 21<sup>st</sup> century. New classes of antiretroviral drugs include fusion inhibitors, integrase inhibitors, maturation inhibitors, and CCR5 antagonists. The rate at which new antiretroviral drugs are being produced suggests that multiagent, synergistic treatment regimens may keep viremia suppressed for decades in infected persons.

**HIV ENTRY BLOCKERS.--** Blocking HIV entry into host cells is another pharmacologic strategy because HIV infection is typically established by just a few "founder" viruses. The initial step of HIV attachment via the CD4 receptor can be blocked by soluble preparations of CD4 to bind viral gp120 and prevent attachment to cellular CD4, or by blocking of the CCR5/CXCR4 co-receptors. The V3 loop amino acid sequence of the HIV-1 gp120 surface protein determines whether HIV utilizes chemokines CCR5 or CXCR4 for host cell entry. HIV-1 can utilize CCR5, CXCR4, or both. Entry via CCR5 is more common, particularly in earlier stages of HIV infection. This approach can potentially work in the period immediately following HIV exposure. The entry inhibitors include vicriviroc and maraviroc, both selective CCR5 antagonists that prevent membrane fusion by blocking binding of the viral envelope protein gp120 to CD4 p T cell co-receptors. Cenicriviroc is an antagonist of both CCR5 and CCR2. It is important to note that this drug binds to a human target and not an HIV target.[293]

Fusion inhibitor therapy is based upon blocking gp41 mediated membrane fusion. A synthetic peptide has been produced that corresponds to 36 amino acids within the C-terminal heptad repeat region (HR1) of HIV gp41 subunit of the viral envelope (Env) protein. This prevents conformational changes to form a stable complex required for viral membrane fusion to target cells. This drug, enfuvirtide, must be delivered by subcutaneous injection. It has a low genetic barrier to resistance and must be used in combination.[293,294]

**INTEGRASE INHIBITORS.--** Integrase inhibitors interfere with strand transfer of viral DNA and prevent incorporation of the completed HIV proviral DNA copy into the host cell DNA. The HIV enzyme integrase catalyzes incorporation of viral DNA into the host's genomic material and has been considered an attractive drug target for some time. Raltegravir and elvitegravir are both integrase strand transfer inhibitors (InSTI), which specifically target the final step of the three steps by which viral DNA is inserted into the cellular genome. The integrase inhibitors raltegravir and elvitegravir are first generation integrase inhibitors that are active against HIV strains that demonstrate resistance to other classes of antiretroviral drugs, but they require use of the booster cobicistat, a CYP3A4 inhibitor that prevents rapid drug metabolism, but may interfere with other drugs. The second generation drug dolutegravir does

not require cobicistat. Integrase inhibitors display synergism with other antiretroviral drugs, but must be used in combination because resistance can quickly arise.[295,296]

**MATURATION INHIBITORS.**-- Maturation inhibition of HIV involves blocking the assembly of virions so that they are not released or they are non-infectious. Bevirimat is a maturation inhibitor with a mechanism of action that involves inhibition of the final rate-limiting step in HIV *gag* gene function. This requires release of a mature capsid protein, which is under the influence of the HIV *gag* gene. Inhibition of *gag* directed processing prevents release of mature capsid protein from its precursor (CA-SP1), resulting in the production of immature, non-infectious virus particles. The antiretroviral agent beviramat prevents this release and inhibits HIV replication.[297]

**HIV RESISTANCE.**-- The significant mutation rate during reverse transcription of HIV to proviral DNA within host cells (approximately once per 2000 incorporated nucleotides) enhances the development of antiretroviral drug resistance. Mutations introduce many “quasispecies” of HIV in addition to acquired “wild type” virus. Mutants least inhibited by drugs may become predominant. Reverse transcriptase is a heterodimer consisting of p66 and p51 polypeptide subunits. Most mutations affect the N-terminal polymerase domain of p66. There is a lower genetic barrier of HIV-1 to development of NNRTI-resistance mutations than NRTI-resistance mutations. Given that 50 copies of RT are introduced into a host cell after fusion of HIV-1, there are multiple opportunities for evasion of reverse transcriptase inhibition. However, use of NRTIs and NNRTIs in combination yields synergistic effects because of different inhibition mechanisms, and mutations imparting resistance to one agent may increase sensitivity to another.[298,299]

Resistance increases with the length of therapy, as multiple amino acid changes accumulate over time to yield virus variants. Common mutations include substitutions at position 215 for the NRTIs and 103N for the NNRTIs.[300] For HIV entry inhibitors, resistance mechanisms arise via reduction in affinity for an inhibitor of CD4 interaction, persistent receptor function despite a bound inhibitor, and bypass of the inhibitor.[301]

There are both high and low prevalence HIV drug resistance mutations. Standard PCR assays detect high prevalence drug resistance mutations in 8% and 16% of HIV-1 infected persons in North America and Europe. More sensitive assays may detect low prevalence mutations in an additional 14% of infected persons. There is an increased risk for antiretroviral treatment failure with these mutations as well as with high prevalence mutations.[302]

The monitoring of patients with HIV-1 RNA and CD4 lymphocyte counts is the primary means for determination of potential resistance. Use of HIV-1 genotypic and phenotypic susceptibility testing may direct subsequent changes in antiretroviral therapy. Such testing may improve patient survival.[303] Loss of clones of CD4 lymphocytes through HIV-mediated destruction may be slowed by antiretroviral therapy, but such clones will not be replaced, leaving patients at continued risk for opportunistic infections.[288]

A study of patients receiving antiretroviral therapy from the late 1990's showed that 76% with >500 HIV-1 RNA copies/mL were resistant to one or more antiretroviral drugs, of whom 13% had triple class resistance and 48% double-class resistance. Resistance was more likely with a history of drug use, advanced disease, higher viral load and lower CD4 cell count. A study of antiretroviral naïve patients from 2003 to 2004 in the U.S. found that 14.5% of them had documented resistance to one or more antiretroviral drugs, with resistance rates to NRTIs,

NNRTIs, and PIs of 7.1%, 8.4%, and 2.8%, respectively. Data from the longitudinal observational EuroSIDA study showed that among 3,496 individuals (2,230 treatment-experienced and 266 treatment-naïve), all of whom started ART in 1997/1998, the incidence of triple class failure was negligible shortly after initiation of ART, but 21.4% of treatment-experienced patients and 11.2% of treatment-naïve patients had triple class failure 6 years after starting treatment, reinforcing the importance of selecting first-line treatment regimens that are as potent and tolerable as possible.[304]

The incidence of new resistance mutations in patients remaining on stable antiretroviral therapy despite continued viremia is approximately 1.6/person-year (95% CI: 1.36 – 1.90). Failure to adhere to prescribed therapies threatens the emergence of resistance. The development of resistance to all three main classes of drugs leads to limited range of subsequent treatment options, higher rates of disease progression, poorer clinical outcomes and increased risk of transmission of resistant virus to others.[304]

**TREATMENT GUIDELINES.--** The use of antiretroviral therapy (ART) with combinations of drugs forms the basis for therapy of HIV infection, and such therapy has similarities to cancer chemotherapy. Initial testing for HIV1 positive persons includes:

CD4 T-lymphocyte count  
HIV1-RNA viral load

Additional testing may include:

HIV1 genotype resistance assay (may not work if viral load <1000 copies/mL)  
Blood glucose (fasting)  
Serum lipids  
Complete blood count  
Serum electrolytes, including urea nitrogen and creatinine  
Serum transaminases  
Serologic testing for viral hepatitis A, B, and C

The guidelines from the International AIDS Society (IAS) recommend antiretroviral therapy (ART) for all patients regardless of CD4 cell count.[305] A significant potential benefit of ART is reducing the risk for HIV transmission. The risk reduction is 96% on ART, and close to 100% when suppressing viral load to undetectable levels.[274]

The recommendations from the World Health Organization, more applicable to resource-limited settings, base ART for adults upon the CD4 cell count, and are as follows:[306]

CD4 cells (per $\mu$ L)	Recommendation for Treatment
Symptomatic HIV disease	Recommend Therapy
<350	Recommend Therapy
$\geq 350$ but $\leq 500$	Defer Therapy (unless viral load >100,000 copies/mL or CD4 counts declining rapidly)
>500	Defer Therapy

Recommendations for initiation of antiretroviral therapy in children and adolescents are different. One problem in comparing adult to pediatric populations is the variability of CD4 lymphocyte counts in younger persons. Hence, a CD4 percentage of the total lymphocyte count can be employed as follows:[307]

Age	Recommendation for Treatment
Infants, <1 yr	Treat all patients  Treatment deferral and intense monitoring may be considered in asymptomatic infants with CD4 >30% and uncertainty about the feasibility of adequate adherence
Children 1 to <3 yr	Treat all children with CDC class B or C disease Treat all children with CD4 <25% or <750/ $\mu$ L Closer monitoring if HIV-1 RNA load >250,000 copies/mL
Children 3 to <5 yr	Treat all children with CDC class B or C disease Treat all children with CD4 <20% or <500/ $\mu$ L Closer monitoring if HIV-1 RNA load >100,000 copies/mL
Children and adolescents 5 yr or more	Treat all with CDC class B or C disease Treat all with CD4 <350/ $\mu$ L

The ART regimens may include combinations of one or more of a nucleoside reverse transcriptase inhibitor (NRTI), nucleotide reverse transcriptase inhibitor (NtRTI) non-nucleoside reverse transcriptase inhibitor (NNRTI), and protease inhibitor (PI). Various combinations are possible, based upon clinical trials that determine efficacy, adverse effects, interactions, and ease of use. The standard recommended regimens are as follows: [278,306]

#### **Standard ART Regimens for HIV-1**

- \* NRTI + NRTI + NNRTI
- \* NtRTI + NRTI
- \* NtRTI + NNRTI
- \* NRTI + NRTI + PI
- \* NRTI + NRTI + PI + PI

With ART, the CD4 count typically increases.[278] . The use of ART can reduce the total health care cost for persons with AIDS.[308] Despite ART, the reconstitution of the immune system may be partial or incomplete, with considerable variability in the magnitude of the response. CD4 counts may remain below normal. Persons with higher baseline HIV-1 RNA levels and more acute, pre-therapy CD4 cell decreases have greater CD4 cell increases following institution of ART. However, some patients continue to have good suppression of HIV replication in spite of no or only a modest increase in the CD4 cell count. Half of persons



starting ART may not suppress the HIV-1 RNA level below 400 copies/mL. Persons older than 50 years of age have more adverse reactions, but better virological responses, to ART compared with younger patients. Though their initial immunological responses are blunted, after 3 years they have similar CD4 T-cell counts as younger persons.[309]

**IMMUNE RECONSTITUTION INFLAMMATORY SYNDROME (IRIS).--** In persons with significant immune reconstitution in response to antiretroviral therapy, there may be a paradoxical accelerated clinically apparent presentation to latent, smoldering, or subclinical infections or to relapse of ongoing treated infections because of an increased inflammatory response. This is known as immune reconstitution inflammatory syndrome (IRIS), or immune restoration disease (IRD). Immune reconstitution is defined as a CD4 lymphocyte count  $>200/\mu\text{L}$  and an increase of  $\geq 100/\mu\text{L}$  over baseline any time since starting antiretroviral therapy. IRD can be characterized by an atypical presentation of a current or past opportunistic infection or tumor in an HIV-infected persons responding to ART, along with a decrease in plasma HIV-1 RNA.[310,311]

Additional inflammatory features of IRIS include a polyclonal hypergammaglobulinemia and autoimmune phenomena. Features can include high levels of CD8 lymphocytes, high levels of IL-6 and soluble IL-6 receptor, high levels of CD30 and CD26 activity, increased interferon gamma-producing inflammatory cells such as macrophages with delayed type hypersensitivity reactions, increased chemokine expression on inflammatory cells, and features of a  $T_H17$  or  $T_H1$  cell mediated immune response.[310] There may be “compartmentalization” of the inflammatory response, with immune cells in greatest number at the tissue site of inflammation and not in peripheral blood.[311]

Risk factors for IRIS include a low CD4 cell count ( $<50/\mu\text{L}$ ) at the initiation of antiretroviral therapy, a viral load of at least 100,000 copies/mL, and presence of an AIDS definitional type B or type C illness (opportunistic infection / neoplasm). The most common IRIS-defining diagnoses include candidiasis, cytomegalovirus infection, disseminated *Mycobacterium avium* complex, *Pneumocystis* pneumonia, varicella zoster, Kaposi sarcoma and non-Hodgkin lymphoma. *Mycobacterium tuberculosis* occurs frequently in regions where the prevalence of this infection is high. Additional diseases falling outside of AIDS definitional criteria may occur with IRIS and include autoimmune hepatitis, ulcerative colitis, sarcoidosis, Graves disease, and reactive arthritis. Skin manifestations associated with IRIS may include molluscum contagiosum, cutaneous warts, herpes zoster, and genital herpes simplex virus.[312]

**ANTIRETROVIRAL THERAPY (ART) REGIMENS FOR HIV-1.--** ART is recommended for all persons in the advanced stage of HIV infection. Problems associated with therapy at this stage include drug interactions with agents used to treat opportunistic infections, as well as problems with toxicity less tolerated by very ill persons. Such persons may not respond as well to initial therapy or may require more frequent changes in therapy.[226]

Persons diagnosed with acute HIV infection may derive benefit from antiretroviral therapy, but the clinical guidelines for treatment remain variable. Such therapy may suppress the initial burst of viremia, potentially lower the “set point” of viremia that determines the rate of disease progression, and may reduce the rate of viral mutation. Conversely, antiretroviral drug resistance may occur earlier in the course of infection, limiting future options. In addition, there are potential adverse effects of drug therapy.[208,313] In addition, early antiretroviral therapy

does not appear to alter abnormalities in gut-associated lymphoid tissue, one of the major reservoirs for ongoing viral proliferation.[314]

Therapy for acute retroviral infection may include a combination of two NRTI's and one protease inhibitor. However, if the patient is infected with a drug resistant HIV strain, or if viremia is not suppressed significantly, then there is the risk for increasing drug resistance that limits the effectiveness of future therapy. After a year of therapy, assessment of HIV-1 RNA levels and CD4 lymphocyte counts will determine whether continued therapy during asymptomatic HIV infection is warranted.[226] A dramatic reduction in the numbers of infected CD4 lymphocytes is demonstrated following potent antiretroviral therapy.[213]

Infants and children with HIV infection may also benefit from antiretroviral therapy, and combination therapy begun early, particularly in those infants whose HIV-1 viral load is high, has shown effectiveness. Adverse drug reactions are not significant in most cases.[315] Adolescents with HIV infection who acquired their infection during adolescence will typically have a clinical course of infection similar to adults. The use of antiretroviral therapy (ART) has been shown to markedly reduce mortality in children and adolescents infected with HIV.[316]

Treatment of HIV-infected pregnant women with antiretroviral therapy is a complex issue. For women already on a treatment regimen when pregnancy is diagnosed, treatment may be discontinued because of a potential risk for teratogenicity during the first trimester, but the inevitable rise in HIV-1 RNA levels following discontinuation of therapy may place the fetus at greater risk for transmission of HIV later in pregnancy. HIV-infected women not on therapy who are diagnosed as pregnant may wish to delay instigation of antiretroviral therapy until after the first trimester. The goal in pregnancy should be to bring the viral load to levels that are undetectable.[317]

The U.S. Public Health Service have promulgated guidelines for prevention of mother-to-child transmission of HIV:[318]

- Combined antepartum, intrapartum, and infant ARV prophylaxis are recommended for maximal PMTCT
- Combination antepartum ARV regimens containing at least 3 drugs are recommended rather than single-drug regimens
- Combined ARV prophylaxis is recommended for all pregnant women infected with HIV regardless of plasma HIV RNA copy number or CD4 cell count
- Initiating ARV prophylaxis after the first trimester, but ideally no later than 28 weeks, is recommended for pregnant women infected with who do not require ARV for their own health
- Intrapartum prophylaxis and infant ARV prophylaxis are recommended for women who do not receive antepartum ARV to reduce risk of perinatal transmission
- The addition of single-dose intrapartum/newborn nevirapine (NVP) to standard antepartum combination therapy is not recommended because of the potential risk for development of NVP resistance and lack of added efficacy based on trial results
- A 6-week ZDV chemoprophylaxis regimen is recommended for all neonates exposed to HIV and should be started as close to time of birth as possible, preferably within 6 to 12 h of delivery
- Early diagnosis of HIV infection in infants remains a priority
- Decisions regarding use of additional ARV drugs in infants exposed to HIV depends on

- multiple factors and should be resolved with input from a pediatric HIV specialist
- In the United States, breastfeeding should be completely avoided given the increased risk of HIV transmission to the infant and availability of safe formula replacement feeding.

All pregnant women should receive antiretroviral therapy. In the vast majority of circumstances, that therapy should be a highly active regimen that includes zidovudine. Stavudine and didanosine in combination should not be used unless other regimens are not available. ART is recommended for women during pregnancy who require ongoing treatment. ART is also effective in reducing mother-to-child transmission in women with higher CD4 counts. The addition of a maternal and infant nevirapine dose to antenatal zidovudine can reduce the rate of transmission to below 5%, which is about half the transmission rate achieved by just a single dose of nevirapine. HIV resistance develops after nevirapine use in up to 60% of mothers and 50% of infants following a single dose, but the addition of zidovudine and lamivudine for 4–7 days postpartum can reduce the risk of HIV resistance to 10%. [317]

Even abbreviated regimens of zidovudine therapy have been demonstrated to reduce the rate of perinatal transmission of HIV. [319] A reduction in likelihood of perinatal transmission <2% is achieved with prenatal, intrapartum, and neonatal use of antiretroviral prophylaxis in combination with elective cesarean section and avoidance of breast feeding. [196] The rate is <1% in women with non detectable plasma HIV-1 RNA. [187]

Response to antiretroviral therapy must be monitored by HIV-1 RNA and/or CD4 lymphocyte counts. The HIV-1 RNA level provides a better indicator of clinical benefit than does the CD4 count. Before initiation of therapy, baseline values must be established by obtaining at least two measurements of these parameters. Following institution of therapy, response may be monitored aggressively with HIV-1 RNA and/or CD4 lymphocyte assays every 1 to 3 months. More conservative monitoring may occur at 6-month intervals. The goal of aggressive therapy is a complete suppression to a measurable level <50 copies/mL of HIV-1 RNA in plasma. [278]

In general, within two weeks of the start of aggressive antiretroviral therapy, plasma HIV-1 RNA will fall to about 1% of their initial value. A minimum 1.5 to 2.0-log decline should occur by 4 weeks, and an early response by 4 to 8 weeks suggests continued HIV suppression. Persons starting therapy with high plasma levels of HIV (>100,000 copies/mL) may take longer to suppress, but failure to suppress viremia <50 copies/mL by 16 to 24 weeks of therapy suggests poor adherence, inadequate drug absorption, or drug resistance. [278]

Suppression of viremia will reduce the level of HIV in genital secretions and reduce transmissibility of HIV from infected persons. [144,320] In general suppression of viremia in serum to a level below 1500 copies/mL is associated with a low rate of transmission of HIV. [154] Despite suppression of viremia, even to undetectable levels, persons with HIV infection must still be considered infectious and should continue to avoid behaviors that could transmit infection to others. Even persons with undetectable levels of HIV-1 RNA in plasma may still have virus detectable in genital secretions. [153]

Failure of treatment may not necessarily relate to the appearance of drug resistance. The problems of patient adherence to the drug regimen and the drug potency contribute to treatment failure. Patients who have a lower educational level have an increased risk for progression to AIDS and death, even if ART is available. [321] Though dosing regimens for antiretroviral therapy (ART) are complex, it is essential that patients adhere to the regimen for adequate and continued suppression of viremia. [322] An adherence rate of 95% is required for optimal

suppression of viremia.[278] complications, as shown by a study in which ART was not instituted until the CD4 count decreased below 250/ $\mu$ L and then discontinued when the count exceeded 350/ $\mu$ L. There was a significantly increased risk of opportunistic disease or death from any cause, as compared with continuous antiretroviral therapy.[323]

An important goal of aggressive antiretroviral therapy is suppression of HIV replication to reduce the emergence of antiretroviral drug-resistance strains, which are the rate-limiting factor to continued drug effectiveness and survival. At the end of the 20<sup>th</sup> century, ART therapy was unable to suppress HIV-1 RNA to less than 400 copies/mL in 10 to 40% of patients starting their first treatment regimen, and 20 to 60% of patients on a second or third antiretroviral regimen demonstrated treatment failure.[324,325] 288, 289 Suppression of viremia is best accomplished with simultaneous initiation of combination antiretroviral therapy, using drugs not previously given and drugs not known to be subject to cross-resistance.[226] If suppression of viremia is not adequate, then drug resistant HIV-1 variants arise that are capable of being transmitted to others and may impact the spread of HIV-1 through inability to suppress HIV-1 in infected persons.[326,327] 290, 291 In one study of newly infected persons, 16% had been infected with HIV-1 variants with known resistance to antiretroviral agents.[328] 292

A change in the treatment regimen for HIV infection may be instituted for a variety of reasons. Such a change may be prompted by increasing drug resistance, as indicated by detectable HIV-1 RNA reappearing in plasma after complete suppression, or increasing HIV-1 RNA levels in plasma. The HIV-1 RNA in plasma gives a good indication of the level of a therapeutic response.[386] The toxic effects of the medications and intolerance may require that an alternative regimen be considered. In addition, failure of patient compliance may force a change. If the patient were on a suboptimal regimen, such as a single antiretroviral agent, then a change would be indicated. A minimum of two CD4 cell counts and two HIV-1 RNA assays are recommended prior to initiating or changing antiretroviral therapy.[278]

The use of ART combinations mitigates onset of HIV resistance. Every HIV-infected person has multiple genetically related viral variants because of the high replication rate of HIV coupled with its error-prone replication process that has frequent recombination events leading to new HIV variants. Combinations of antiretroviral drugs are advantageous for treatment because it is unlikely that pre-existing viral variants will be resistant to more than three drugs in treatment naïve subjects. Suppression of viremia will slow the rate of viral evolution. New antiretroviral drugs may be more efficacious against mutants. In addition, increased drug levels can be obtained by use of pharmacokinetic enhancement with ritonavir or other compounds. Virologic failure not adequately addressed can lead to greater evolution of viral resistance that can include cross-resistance that requires more complex at toxic antiretroviral regimens that are less tolerable, making patient adherence more difficult, with a downward spiral to shorter duration of HIV suppression and re-emergence of virologic failure. Drug potency coupled with viral suppression is inversely proportional to evolution of viral resistance.[329]

Prevention and management of ART resistance can be summarized as follows:[329]

- Systematically screen for the presence of primary antiretroviral resistance in all patients entering clinical care, preferably as soon as possible after infection.
- Adjust the design of first-time treatment regimens to the genotypic resistance information obtained if needed. Obtaining a genotype from a patient as soon as he/she enters into clinical care may allow an increased detection of transmitted resistant viruses, which becomes harder to detect with time.

- Once primary resistance is ruled out, good adherence, forgiving pharmacology, drug potency, and high genetic barrier are the principal factors associated with reduced emergence of antiretroviral resistance.
  - Ritonavir-boosted protease inhibitor (PI)-containing regimens are associated with low rates of PI resistance at treatment failure and lower rates of NRTI resistance than NNRTI-based regimens.
  - On the other hand, first-line efavirenz-based regimens are more resilient to virological failure than ritonavir-boosted PIs tested to date, possibly due to lower compliance on PI regimens because of side effects.
- It is crucial to detect virological failure early and change failing therapy as soon as failure is confirmed, with the aim to re-suppress viral replication to <50 copies/mL.
- Use 2 or 3 new agents to achieve durable viral suppression and prevent the future emergence of viruses with resistance to 6-drug classes.

Despite antiretroviral therapy, proliferating CD4 cells and follicular dendritic cells within lymphoid tissues, and macrophages throughout the body, particularly in central nervous system and gastrointestinal tract, remain as reservoirs of infection.[330,331] Though the turnover of peripheral CD4 cells is rapid, the half-life of FDCs averages two weeks to one month, while some long-lived CD4 memory cells have a half-life of 7 months. Thus, clearance of HIV requires months of antiretroviral therapy.[95] Regeneration of the immune system can occur to some degree even in late stages of HIV infection, but will be slow, variable, and partial.[90]

Another potential complication of ART that includes tenofovir is accelerated loss of bone mineral density. The incidence of osteopenia and osteoporosis is increased in HIV infected males on such therapy. This complication may occur in association with lipodystrophy.[332]

Prophylaxis for *Pneumocystis jiroveci* pneumonia (PJP) in adults is indicated with CD4 lymphocyte counts below 200/ $\mu$ L and for patients with a history of oropharyngeal candidiasis.[223] Prophylaxis for PJP is indicated in infants beginning at 4 to 6 weeks of life.[333] It may be discontinued when HIV infection is excluded. Otherwise, PJP prophylaxis is recommended throughout infancy. For children 1 to 5 years of age, prophylaxis is indicated if the CD4 count is <15% of the total lymphocyte count or if <500/ $\mu$ L. For children and adolescents 5 years or more prophylaxis is indicated if the CD4 count is <15% or if <200/ $\mu$ L.[307] In patients receiving antiretroviral therapy in whom the CD4 count has increased above 200/ $\mu$ L for more than 3 months, PJP prophylaxis can be safely discontinued.[334]

The use of zidovudine and other antiretroviral agents, as well as increased effectiveness of treatments for opportunistic infections--and the use of prophylactic trimethoprim-sulfamethoxazole, dapsone, or aerosolized pentamidine (pentamidine isethionate) against *Pneumocystis jiroveci* (*carinii*) pneumonia in particular--has significantly prolonged survival in persons with AIDS. Access to prompt medical care for ongoing care, prophylactic therapies, and life-threatening complications of AIDS is also important for survival, as is maintenance of good nutrition and also psychosocial support.[223,232]

It is clear that use of combination therapies, particularly with inclusion of protease inhibitors, is quite effective in reducing both the morbidity and the mortality from HIV infection. The use of prophylactic therapies for prevention of *Pneumocystis jiroveci* (*carinii*) pneumonia, cytomegalovirus, and *Mycobacterium avium* complex (MAC) infections are most effective in reducing the prevalence of these infections when aggressive antiretroviral therapy is applied. The declines in morbidity and mortality occur for all risk groups, ages, races, and sexes.[335]

Minocycline has been investigated as an immunomodulator in HIV infection. Minocycline modifies T cell activation through decreased cytokine production, altered surface marker expression, suppression of proliferation, and cell cycle arrest. Minocycline can potentially diminish IL-2 signaling through decreased CD25 expression and decreased IL-2 production and thereby diminish the reactivation of latent HIV infection. Minocycline downregulates inflammatory mediators of NF-kB expression, including TNF-alpha and IL-1beta. This could stabilize and enhance antiretroviral therapy.[336] However, although IL-2 therapy has been shown to increase the CD4 lymphocyte count in HIV-infected persons, there does not appear to be a long-term clinical benefit.[337]

There has been considerable pressure to expedite investigational drug testing and approval, given the uniformly fatal outcome of AIDS. One problem for clinical research trials has been the propensity of AIDS patients to obtain drugs not on experimental protocols, thus confounding results of those trials. Patients who are understandably desperate to try anything that offers potential hope have also employed many homeopathic, naturistic medicinal compounds, or other substances such as dinitrochlorobenzene or ozone.

As in other chronic diseases, the use of complementary and alternative medicine (CAM) therapies to standard antiretroviral and antimicrobial therapies is widespread in persons with AIDS, with over half using such alternative therapies. However, less than half of these patients report CAM use to their physician. The most commonly reported alternative therapies include exercise, lifestyle changes, dietary supplements, counseling, herbal medications, megavitamins, and prayer. Of the persons who used such therapies, 70% reported a quality of life improvement.[338]

**ANTIRETROVIRAL THERAPY AND COMORBIDITIES.--** As persons with HIV are living longer, and given the wide age range of infected persons, the likelihood for presence of or development of diseases unrelated to HIV infection has become greater. Moreover, as persons with HIV infection become older, there are organ related changes from both disease and diminished physiologic reserve. Hepatic and renal reserve decline, with reduced drug metabolism and clearance. Diseases of the cardiovascular, respiratory, renal, and gastrointestinal systems may affect drug effectiveness and interactions. Hence, modifications to both antiretroviral and to organ and disease specific therapies may be necessary.[339]

**ANTIRETROVIRAL THERAPY FOR HIV-2.--** About 20% of persons infected with HIV-2 will likely progress to AIDS and need antiretroviral therapy. Antiretroviral drugs for HIV-1 do not have the same efficacy against HIV-2, including all nonnucleoside reverse transcriptase inhibitors (NNRTIs) and fusion inhibitors. Just three protease inhibitors (PIs), lopinavir, saquinavir and darunavir, have similar activity in HIV-1 and HIV. Integrase inhibitors (INIs) and entry inhibitors (EIs) have shown effectiveness in suppressing HIV-2 replication. Antiretroviral resistance is more likely to arise in persons infected with HIV-2 than HIV-1. Viral load assays on peripheral blood are not as useful for monitoring HIV-2 infection as for HIV-1.[340,341]

HIV-2 treatment guidelines include the following recommendations:

	NNRTI	PI	INI	EI
Initial Therapy	Tenofovir or Zidovudine, plus Emtricitabine or Lamivudine	Lopinavir or Darunavir with Ritonavir		
Second-line Therapy	As above consider Abacavir	As above consider Saquinavir	Raltegravir	Maraviroc

## NOVEL STRATEGIES FOR AIDS PREVENTION AND TREATMENT

Given the success of mother-to-child prevention of HIV transmission, studies have been aimed at prevention of HIV infection through other routes of transmission. Transmission of HIV through sexual intercourse could be prevented if the host immune response in mucosal tissues could limit the size of the founder population of infected cells below the level required for establishment of infection. If concentrations of antiretroviral drugs were present that inhibited viral replication, then infection could not occur. This strategy employs pre-exposure prophylaxis using available oral antiretroviral drugs. The drugs utilized are those that reach a high concentration in vaginal and rectal tissues, including emtricitabine (FTC) and tenofovir (TDF).[342] One study showed a 44% reduction in transmission, but was likely not higher due to problems with adherence to once daily drug use.[343]

A large component of AIDS research has been aimed at development of an effective vaccine. Though a universally efficacious vaccine would help stop the spread of AIDS, such a vaccine would be of little help to the millions of currently HIV-infected persons worldwide. Vaccine development has encountered several obstacles: HIV epitope variability, HIV avoidance of immune response through cell to cell transmission, lack of an effective neutralizing antibody response, and induction of adverse immune reactions through HIV homology to endogenous human proteins. Several vaccine strategies have been proposed, including induction of cell mediated and/or humoral immunity.[344]

Vaccine research initially centered on the use of the HIV gp120 or gp160 envelope proteins to induce a humoral response. Most neutralizing antibodies formed in persons infected with HIV are aimed at gp160. However, most research studies have focused on use of gp120 because it was simpler to manufacture and did not have any major disadvantages compared to gp160. The immunogenic response may be enhanced by removal of carbohydrate moieties from the heavily glycosylated gp120.[345] Enhancement of the immune response has been achieved in trials using lipopeptides, which are hybrid molecules composed of large synthetic peptide fragments of viral proteins covalently linked to a palmitoyl chain. This lipid moiety facilitates peptide entry into antigen-presenting dendritic cells to enhance the cell-mediated immune response.[346] Vaccines that induce a CD8 lymphocyte cytotoxic response have shown some efficacy in reducing HIV proliferation. This is based upon the observation that elite controllers of HIV infection can have cytotoxic lymphocytes directed against HIV gene products. These CD8 cells are directed against target cells with Nef viral epitope expression.[347] Both antibody mediated and CD8 lymphocyte mediated immunity together are likely needed to provide efficacious immunity to HIV.[348]

Alternative approaches include the use of poxviruses such as vaccinia as recombinant vectors for vaccination with HIV envelope proteins, and this has the advantage of inducing mucosal immunity that could block infection through the portal of entry in mucosal surfaces. Development of an attenuated virus vaccine has the potential for induction of the most effective and long-lasting immunity, but the long latency of HIV infection makes assessment of non-pathogenicity of such a vaccine difficult to ascertain. In addition, the vaccine must be effective against the various subtypes of HIV that have arisen or will arise. Through the early 21<sup>st</sup> century, no effective HIV vaccine was produced.[38,344,349]

Another approach to control of HIV infection is the use of gene therapy. One approach is immunization by direct injection of plasmid DNA encoding genes for specific HIV protein antigens.[344] An approach based upon introduction into susceptible cells, such as CD4



lymphocytes, of a gene that induces apoptosis in infected cells, has been employed with minimal therapeutic benefit. Gene therapy could be based upon the expression of antiviral genes in the target cells for HIV, termed intracellular immunization, but is hampered by the large size of the target CD4 cell population.[350]

In the early 21<sup>st</sup> century, just three candidate HIV vaccines completed clinical efficacy trials: a recombinant protein of the HIV-1 envelope (AIDSVAX), a nonreplicating adenovirus serotype 5 vector expressing an internal HIV-1 protein (gag), and a combination of a canarypox vector expressing HIV-1 immunogens (ALVAC) and the previously studied recombinant HIV-1 envelope protein (AIDSVAX). This third candidate vaccine had modest efficacy (31.2%) and short-lived, but there was an efficacy signal.[351]

Genetic modulation of HIV may be possible. There are mechanisms by which HIV becomes latent in host cells via multiple restrictions on proviral expression. Several transcription factors are known to recruit histone deacetylases and other complexes to the HIV-1 long terminal repeat (LTR) promoter, which results in histone modifications within chromatin at the HIV promoter that limit the ability of RNA polymerase to initiate transcription. Cellular miRNAs that bind HIV mRNAs may also restrict translation of early expressed HIV mRNAs and so reduce Tat production by HIV.[352]

Clearance of HIV from the host has the possibility of cure. Novel methods for clearance include: (1) human stem cell transplantation from a donor with the  $\Delta 32$  CCR5 mutation; (2) infusion of *ex vivo* transformed CD4 cells with zinc finger nuclease (ZFN)-modification; (3) reduction of latency via epigenetic modification of Nuc-1, a nucleosome located immediately downstream of the transcription initiation site that impedes long terminal repeat (LTR) activity; and (4) preventing reactivation of HIV from latent reservoirs.[353]

Another strategy involves clearing latent HIV from the host. During latency, there is minimal or no HIV replication within a pool of infected cells, so that such cells are neither targeted by antiretroviral drugs nor attacked and destroyed by a host immune response. Drugs such as vorinostat and valproic acid act as histone deacetylase inhibitors to allow histone lysine acetylation to persist and recruit transcriptional activators that facilitate transcription from the HIV promoter. The drug disulfiram depletes the phosphatase and tensin homolog inhibitors of the Akt intracellular pathway, leading to release of a transcription elongation factor that is recruited to the HIV promoter. Activation of the protein kinase C and nuclear factor-kappa B (NF- $\kappa$ B) pathways induces expression of quiescent HIV proviruses. NF- $\kappa$ B translocates to the nucleus, where it binds to the HIV LTR and promotes transcriptional activation. The agent prostratin in combination with the histone deacetylase inhibitors vorinostat and valproic acid synergistically increases production of virions. Bryostatin, a macrocyclic lactone, targets both protein kinase C and NF- $\kappa$ B pathways and downregulates the CD4 receptor on CD4 cells to reduce HIV entry.[354]

## CHAPTER 2 - DIAGNOSIS OF AIDS

### DIAGNOSTIC TESTS FOR HUMAN IMMUNODEFICIENCY VIRUS

There are multiple HIV testing methods available. Most are serologic methods based upon detection of antibody to HIV in blood or body fluids, while the p24 assay detects HIV antigen. The polymerase chain reaction and *in situ* hybridization techniques are used primarily with fresh and fixed tissue samples, but can also be applied to blood samples. HIV viral culture can be performed on both fluids and tissues. Immunologic alterations detected through lymphocyte subset quantification in blood are used clinically to detect and follow the effect of HIV infection on the immune system.

Though HIV can be present in a variety of body fluids, blood and blood components have the greatest concentration of viral components. Oral secretions and urine have also been employed for patient testing based upon ease of collection and processing. Laboratory personnel must employ universal precautions. As an alternative to whole blood, serum, or plasma, dried blood spots can be utilized because they are simpler to prepare, store, and transport. Such dried blood spots have been employed for initial HIV testing, viral load quantification, and HIV drug resistance testing.[355]

An acute HIV infection in the context of laboratory diagnosis may be defined as the time from viral acquisition until a seroconversion is detected. However, detection depends upon the host response and laboratory methodologies employed. An eclipse period from the time of establishment of HIV infection at the site of exposure until HIV enters the systemic circulation may last on average up to 10 days (range 7 to 21 days). When HIV-1 RNA is found at a concentration of 1 to 5 copies per milliliter in plasma, then it is detectable by nucleic acid amplification within 5 to 10 days of the eclipse period. At a concentrations of 50 copies/mL, HIV-1 is detectable using quantitative assays used to monitor viral load, starting after the eclipse period.[212,356]

When HIV enters lymphoid tissues, replication increases rapidly along with viremia, and HIV-1 RNA becomes detectable in blood, but antibodies may not yet be detectable. HIV core antigen p24 may be detectable 4 to 8 days after viremia appears, and can be useful for detection of perinatal infection because of passively acquired maternal HIV antibody. An acute retroviral syndrome may be present at this point. HIV antibodies detectable by enzyme immunoassay typically appear 2 to 5 days after p24 antigen, and usually within 3 weeks of infection. The Western blot assay may be indeterminate for 4 to 8 days, and then become positive over the next 40 days, but is usually positive a month after infection. The HIV antibodies remain throughout the life of the infected person.[212]

**ENZYME IMMUNOASSAY.**—The most common initial laboratory method for detection of HIV infection is the enzyme immunoassay (EIA) to detect HIV-1, HIV-2, and potentially other HIV subtypes. These serologic tests for HIV antibody make use of the human immunologic response to HIV infection in which antibodies, primarily directed against HIV proteins and glycoproteins such as gp120 and gp160, appear after acute HIV infection. The EIA is a simple test to perform for clinical laboratories with trained technicians and, therefore, is the "gold standard" for testing used extensively in blood banking and patient screening in most

places. The sensitivity and specificity of EIA testing by standard methods using serum exceeds 99%. [357]

Use of rapid serum EIA methods, defined as any test that yields results in less than 30 minutes, provides accuracy nearly as good as routine EIAs, but sensitivity is lower for early infections. Rapid assays are simpler to perform by persons without technical expertise, require no instrumentation, and can provide point-of-care testing that is cost-effective. Diagnosis is typically accomplished through the sequential use of 2 separate rapid HIV-1/2 antibody tests, and in resource-limited settings, concordant serological reactivity on 2 appropriately selected rapid tests is highly predictive of infection and is frequently considered to be sufficient for presumptive diagnosis of HIV infection. In more-developed countries, confirmation of antibody-positive rapid samples is accomplished using an independent serum-based HIV test method. [358]

Rapid EIAs provide results to patients without a waiting period, which loses some patients to follow up and counseling. [359] A rapid EIA can allow post-exposure prophylaxis to begin within 2 hours for persons with occupational exposure to HIV. However, errors in performance and interpretation are more likely to occur with rapid assays than with routine laboratory EIAs. [360,361]

EIA tests have improved over time. The first generation tests that became widely used in the 1990's could detect only IgG antibodies, and the window period from infection to seropositivity was 45 to 60 days. The fourth generation EIA tests combine both HIV antibody and p24 antigen detection, which reduces the "window" period for detection following infection to little more than 10 days, and reliably less than 3 weeks. These sensitive 4<sup>th</sup> generation assays can detect HIV-1 and HIV-2 with both IgG and IgM antibodies and p24 antigen. The 4<sup>th</sup> generation EIA seropositivity may precede Western blot positivity by 3 weeks. [362,363]

Use of EIA testing can also be applied to body fluid samples other than blood. Oral mucosal transudate (OMT) is a fluid derived from serum that enters the saliva from the gingival crevice and across oral mucosal surfaces. The OMT contains immunoglobulins that can be concentrated via collection devices such as pads held next to gums and oral mucosa. Testing via EIA of OMT yields results comparable to serum EIAs. [364]

Saliva can also be utilized for rapid EIA testing, and has the advantage of simplified collection and processing. The results with rapid oral HIV tests using saliva are slightly less sensitive and specific than for serum EIAs. Sensitivity is greater for established infections than for recent infections. However, patient adherence with repeat testing using this simpler methodology can improve detection of HIV infection. [365]

The EIA tests for HIV utilize either a whole virus lysate, recombinant proteins, or synthetic peptides for the solid phase antigen, and tests based on the latter two antigens are more sensitive and specific. [357] Kits are available that combine testing for both HIV-1 and HIV-2. These assays are very reliable. When antibodies to one or more antigenic components of HIV including reverse transcriptase (RT), p17, p24, p31, gp41, and gp120/160 are present, as in most cases, sensitivity and specificity are over 99%. Highly sensitive immune complex transfer enzyme immunoassay methods can also be employed. [366]

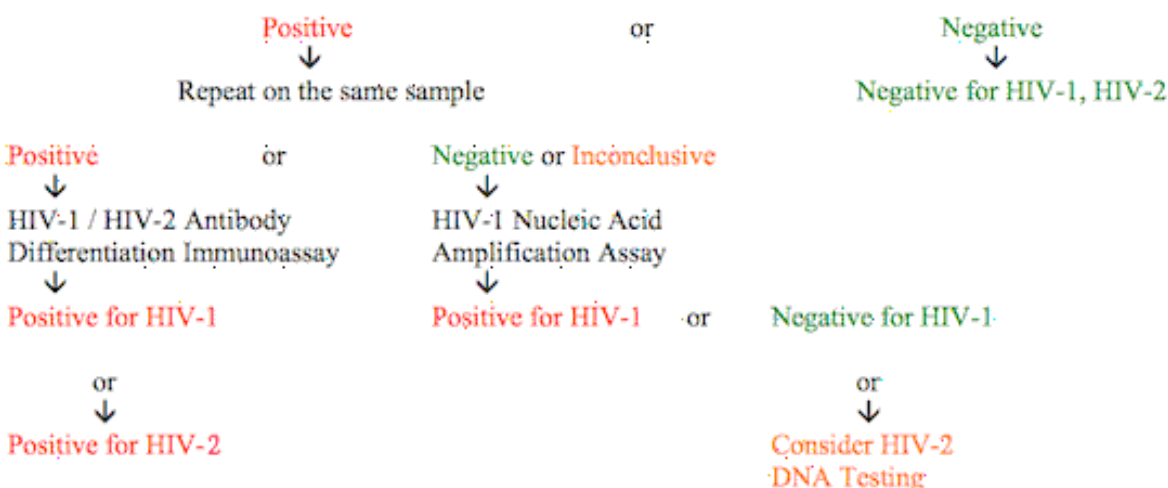
Many EIA assays detect HIV-2. The emergence of subtypes of HIV-1 complicates testing, as evidenced by groups O and M, which are not detected by all routine methods for HIV-1 testing. Group O and M HIV-1 infections can be diagnosed by EIA followed by viral RNA quantification and genotypic resistance assays. [367] In addition, the EIA method employing synthetic peptide antigens can distinguish HTLV types I and II. [357]

The standard protocol for EIA testing is initial determination of reactivity. Reactive tests are repeated in duplicate. If both repeat tests are reactive, the sample is considered positive and a confirmatory test is performed. If one of the repeat tests is negative, then there is a high probability of error in testing and another blood specimen should be obtained for testing. The level of reactivity gives an indication of predictive value of an EIA test—the more reactive the test, the more likely the test result is a true positive.[357]

A diagnostic algorithm for diagnosis of HIV infection incorporates a screening 4<sup>th</sup> generation EIA, followed by a differentiation immunoassay, and supplemented by nucleic acid amplification (NAT) testing.[368,369] The strategy is as follows:

#### HIV Testing Algorithm.

4<sup>th</sup> generation immunoassay (detects both HIV-1 and HIV-2 with IgM and IgG antibodies and p24 antigen)



As shown in the above algorithm, detection and confirmation of acute HIV infection requires use of a sensitive EIA for HIV-1, HIV-2 antigen/antibody, followed by a specific EIA for HIV-1 / HIV-2, followed by HIV-1 nucleic acid amplification testing (NAAT) for inconclusive results. Alternative tests for confirmation of a reactive EIA include Western blot (WB), line immunoassay (LIA), indirect immunofluorescence assay (IFA), HIV-1 RNA assay, or additional EIA testing. When rapid and simple testing is desired, then algorithms for use of EIAs may include: (1) a standard EIA followed by a rapid EIA, (2) two standard EIAs, or (3) two rapid EIAs. EIA tests can be utilized which have reactivity to different HIV antigens from different sources or using different methodologies.[361,362]

In a population with few risk factors and a low prevalence for HIV-1, about 6 or 7 positive EIA test results per million tests performed will be false positives. False positive EIA results may occur in persons with hematologic malignancies, acute DNA viral infections, serum autoantibodies, autoimmune diseases, alcoholic hepatitis, renal failure, cystic fibrosis, multiple pregnancies or blood transfusions, hemodialysis, anti-HLA-DR4 antibodies, and vaccinations for

hepatitis B, rabies, or influenza. Positive EIA specimens should be repeatedly positive, with confirmation by an additional laboratory test.[357,370]

False negative EIA results can occur. EIA will also miss recently infected persons in the "window" of time prior to seroconversion, which can be as little as a week, but up to 3 weeks, on average. EIA is of no value to detect infected infants of HIV-1 positive mothers since transplacentally acquired maternal antibody may persist up to 15 months postpartum. Though a very rare occurrence, not all HIV-1 infected persons have detectable antibody during all or part of their course because of delayed seroconversion.[210] Explanations for seronegativity include: marked hypogammaglobulinemia, B cell functional defects, chemotherapy, a non-detectable subgroup of HIV, or a laboratory error. In those patients with persistently decreased CD4 counts, the possibility of idiopathic CD4+ T-lymphocytopenia (ICL) may be considered. When there is evidence suggesting HIV infection but a negative EIA, then tests for p24 antigen, HIV-1 RNA, and/or viral culture can be considered.[371] There is no evidence for seroreversion, or loss of detectable antibody to HIV-1 once true seroconversion occurs.[214]

Dried blood or plasma spots on paper can be utilized to collect, store, and ship patient samples for HIV-1 RNA viral load testing or genotyping, particularly in places where resources are limited. One limitation is the small amount of blood in a dried spot, which may result in reduced sensitivity in detecting HIV-1 RNA when the viral burden is below 1000 to 4000 copies/mL. The spots have been stored for up to a year at room temperature without significant loss of HIV-1 RNA.[372]

Home-based testing kits utilizing EIA methodology have been marketed. Blood specimens are collected via fingerstick. When properly collected, the accuracy is similar to that of standard serum EIA testing collected by health care workers. However, specimens may not be properly collected. Counseling regarding test results may not be sought. When combined with counseling, the use of home testing for HIV can be an effective alternative to standard testing offered in the health care setting.[373] However, if home testing is mainly utilized by low risk populations soon after presumed exposures, then both false positive and false negative test results could increase.[374]

**NUCLEIC ACID TESTING.**—NAT, or nucleic acid amplification testing (NAAT) is based upon the amplification of HIV RNA in plasma. It is possible for this test to detect the presence of HIV RNA up to 11 to 12 days prior to ELISA and 3 to 6 days before the p24 antigen is detected. Thus, NAT has been utilized as a means for reducing the "window" period to only 10 to 12 days from HIV infection to serologic positivity for screening blood product donations. Such tests can potentially detect levels of HIV RNA as low as 5 to 40 copies/mL.[375,376]

**HIV-1 P24 ASSAY.**-- The HIV-1 p24 assay detects the core antigen p24 which is produced by the HIV-1 *gag* gene. This test is essentially the reverse of the enzyme immunoassay for HIV-1 antibody, because the methodology makes use of an antibody to HIV p24 coated on a solid phase that "captures" the p24 in a patient specimen. An enzyme conjugated second antibody to p24 is then added and a standard enzyme immunoassay method used for detection. The p24 assay can be utilized on non-lipemic or non-hemolyzed serum, on plasma, or on cerebrospinal fluid.[377,378]

The p24 antigen can be detected in some persons only 1 week after initial HIV-1 infection, but in other persons it is transient, disappearing and then reappearing months later. In most cases, p24 antigen can be detected 2 to 3 weeks following infection. The false positive rate

is significant because of interfering substances in serum such as immune complexes. In order for a p24 test to be interpreted as positive, it must be repeatedly reactive and have a positive neutralization test. A p24 test is “indeterminate” if it is repeatedly reactive but the neutralization test is negative or invalid. Since HIV antibody is typically detectable within a week of p24 antigen positivity, indeterminate results can be followed up by repeat antigen and EIA testing in a week. If the antigen test remains positive but the antibody test is negative, repeat EIA testing for HIV is recommended in another 8 weeks. Testing for HIV by PCR can be helpful in this setting.[379] False positive p24 assays are rare, but can occur from cross-reacting blood proteins.[360]

Though p24 assay is not attractive for routine screening, it does have usefulness in detecting HIV-1 infection in children born to HIV-1 infected mothers. The sensitivity of the p24 assay at birth is low (18%) but the specificity high.[380] The p24 antigen assay has a sensitivity and specificity of nearly 100% from 3 to 6 months of age, but specificity begins to fall after 6 months of age.[381] Loss of p24 antigen in HIV-1 seropositive persons may also signal the onset of clinical AIDS, but only about 60% of patients with HIV-1 infection have detectable p24 antigenemia at the time of progression to clinical AIDS.[222,225] Long-term therapy with zidovudine has been shown to decrease p24 antigenemia.[225] Free p24 antigen is often complexed with p24 antibody, limiting detection methods, but immune complex dissociation (ICD) with acid treatment or boiling of specimens improves detection of p24 antigen, which increases the usefulness of the p24 antigen assay as a marker for progression of HIV disease.[378]

**HIV-1 RNA ASSAY.--** The polymerase chain reaction (PCR) method can be applied to both tissues and plasma for detection of HIV. In tissues, a DNA probe is used to detect HIV-1 proviral DNA, but is much more sensitive than *in situ* hybridization because the target DNA is amplified many times to enhance sensitivity tremendously. Quantitation of the amount of HIV present is also possible. PCR can detect one copy of viral DNA in one cell out of 100 000 to 1 000 000 cells present. The disadvantage of PCR is that the tissue, either fresh or formalin-fixed paraffin-embedded, must be digested so that the exact localization of the HIV-1 within tissues cannot be determined.[382]

The PCR method has also been employed for early viral detection in serum of perinatally acquired HIV-1 infection. The sensitivity of this assay is sufficient to detect about half of infections in the first month of life. Between 30 and 60 days following birth, PCR will detect virtually all HIV infections of infants, and there should be no false negatives after 6 months, a sensitivity equivalent to HIV culture. Sensitivity is 29% in the first week, 79% at 8 to 28 days of age, and >90% at 29 days of age and thereafter. Therefore, HIV infection can be presumptively excluded with 2 negative virological tests, with one at 2 or more weeks of age and the second at 1 or more months of age. HIV infection can be definitively excluded with 2 negative virological tests, with one at 1 or more months of age and the second at 4 or more months of age. [378,383,384]

Quantitation of HIV-1 RNA in plasma or peripheral blood mononuclear cells can be performed by three methods: reverse transcriptase-polymerase chain reaction (RT-PCR), branched DNA (bDNA) testing, and nucleic acid sequence-based amplification (NASBA).[360] These assays provide a reliable means for monitoring progression of HIV infection independently of CD4 lymphocyte counts. Levels of HIV-1 are reported in viral copies per milliliter on patient plasma, and results may vary up to two-fold among these assays, so one

assay should be utilized consistently for a given patient.[385] The level of HIV-1 RNA may vary up to three-fold in a single patient. However, there appears to be no diurnal variation. The HIV-1 RNA level tends to increase as the CD4 lymphocyte count declines and HIV infection progresses.[386] However, the commercial viral load assay kits vary in their ability to quantify different HIV-1 subtypes.[387]

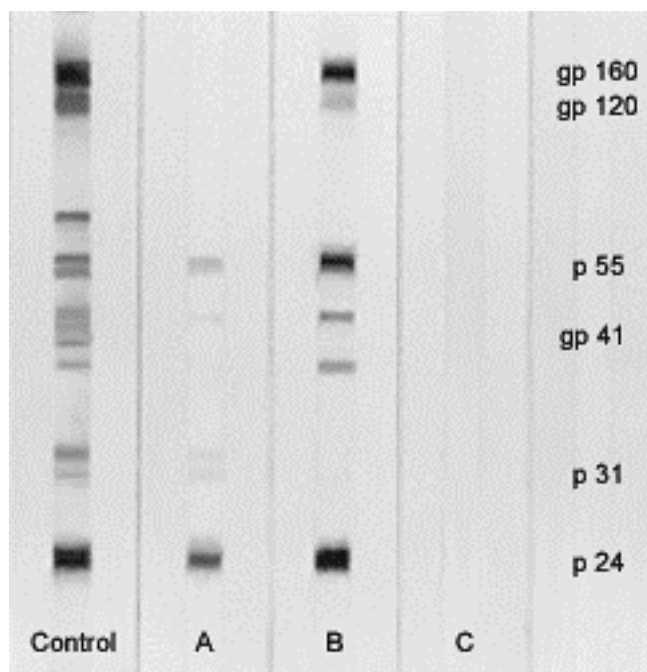
The levels of plasma HIV RNA detected correlate with the stages of HIV infection: a viremic "spike" following initial infection, then suppressed levels of HIV during the long "latent" phase of infection, and finally increased viremia with progression to clinical AIDS. The HIV-1 RNA correlates with plasma viremia and the level of p24 antigen, but is more sensitive, and can predict HIV disease progression independently of CD4 lymphocyte counts. This assay also has usefulness for closely monitoring patient response to antiretroviral therapy. An early response to therapy is marked by a decrease in viremia, while increasing drug resistance is indicated by increasing viremia.[388,389,390]

However, just as with CD4 lymphocyte counts, there can be variability in bDNA assays of HIV-1 RNA. Though there is no diurnal variation, the HIV-1 RNA level may have up to a 0.4 log<sub>10</sub> variance. Genetic subtypes of HIV-1 may provide differences up to a factor of 1.5. The plasma levels of HIV-1 RNA have been shown to increase transiently during bacterial infections. There is lack of standardization among different methodologies. Thus, testing for HIV-1 RNA is not routinely used for diagnosis of HIV-1 infection.[391,392]

A qualitative HIV-1 RNA test on plasma is available for use in the initial diagnosis of HIV infection. Detectable HIV-1 RNA may appear less than 2 weeks following infection. Quantitative HIV-1 RNA tests with sensitivity of 50 copies/mL can detect HIV infection before both the p24 antigen test and EIA tests, but RNA NAAT testing has been limited primarily to quantifying HIV-1 loads and screening blood donations because the tests are expensive and technically complex to perform. Moreover, low-positive HIV RNA levels (<5,000 copies/mL) may represent a false-positive test result, but HIV-1 RNA levels during acute HIV infection are usually quite high (>100,000 copies/mL).[360] Qualitative HIV-1 RNA testing has been applied as a confirmatory test for EIA positive specimens.[393]

**WESTERN BLOT.**-- The Western blot (WB) test was used prior to availability of more sensitive and specific EIAs to confirm screening EIA positives because of its high specificity. The method utilizes a substrate made by fractionating purified HIV-1 by molecular weight, using polyacrylamide gel electrophoresis, into discrete bands that are then transferred by electrophoretic blotting to a nitrocellulose membrane that is then cut into strips. A patient serum, urine, or saliva specimen is placed on the strip and any HIV-1 antibodies present will bind to the viral antigens. The bands are visualized by immunohistochemical methods.[394] The Western blot technique can be utilized to distinguish HIV-1, HIV-2, HTLV-I, and HTLV-II infections.[357]

Western blot testing requires high-quality reagents, careful interpretation of the band patterns, and rigorous quality control. Thus, WB testing should be done by or referred to qualified laboratories according to established criteria. Test strips showing no bands are negative. Positive findings are interpreted by a number of "standard" criteria that require the presence of two or more bands that represent specific denatured HIV-1 proteins including core (p17, p24, and p55), polymerase (p31, p51, p66), and envelope (gp41, gp120, gp160) proteins depending on the particular kit or method.[394]



A Western blot is positive if reactivity is detected with either:

gp41 and gp120/160 bands

or

either the gp41 or gp120/160 bands AND the p24 band

In the pictured example, the patient sample in lane B is positive while the result for patient C is negative. The presence of any bands that do not meet the criteria for a positive result is considered an indeterminate result, as shown in lane A above. Errors in interpretation occur with sample misidentification, cross-contamination of negative samples by adjacent positive samples, HLA antibodies in the viral lysate used in the preparation, or misinterpretation of band patterns. A WB should not be used as an initial HIV screening test because it has a much higher false positive rate than EIA. Likewise, plasma HIV-1 RNA testing should not be used for screening because of the false positive rate up to 3% (suggested by an assay yielding a low plasma viral load).[357]

The WB typically becomes positive 25 to 30 days following initial infection.[356] The "indeterminate" WB assays may result from repeatedly reactive true positive EIA assays on sera that are negative to WB in individuals at the early stage of HIV infection when a weak titer of HIV antibodies may be present. It may occur late in the course of AIDS with loss of core antibodies with loss of immunologic competence. Up to 10 to 20% of repeatedly reactive EIA assays can have an indeterminate WB assay.[360] Indeterminate WB assays may also result from cross-reaction from infection with HIV-2, HTLV, or a rare subtype of HIV. Indeterminate results may occur from nonspecific antibody reactions with autoimmune diseases, vaccination against influenza, viral infections such as hepatitis, or rabies, multiple pregnancies, recipients of multiple blood transfusions, and malignancies.[395] Indeterminate WB assays in persons who



are truly HIV negative may occur from contaminating proteins in the viral lysate, from reactivity due to prior exposure to similar proteins or other viruses, and hyperbilirubinemia.[357,396]

Approximately 3% of persons with indeterminate WB tests subsequently have laboratory evidence for HIV infection, and most of these persons will have identifiable risk factors for infection. Indeterminate results can usually be resolved by retesting the patient by EIA assay and WB. About one-third of persons with an indeterminate WB will not be repeatedly reactive by EIA assay after retesting in one month. After six or more months, most truly HIV-1 infected persons will be positive. However, an indeterminate WB can persist for years in some persons. [397,398] Additional testing to resolve indeterminate results can include detection in plasma of HIV-1 p24 antigen in 75% of early infections, nucleic acid testing (NAT), or HIV-1 RNA, which can identify virtually all early infections.[395,399]

Indeterminate WB results may also arise from non-specific reactivity of true negative sera for both EIA and WB assays. Some persons have stable indeterminate patterns and are not HIV-1 infected. Specific risk factors identified among women for presence of an indeterminate WB test include parity and also presence of autoantibodies, while in men the risks include a tetanus booster injection in the past two years or sexual contact with a prostitute.[397] Correlation of test results with clinical status is necessary.[400,401] Fourth generation enzyme immunoassays, and specific immunoassays can be performed for HIV-2 to confirm EIA positive tests. Long-term follow-up of persons donating blood and who have no risk factors for HIV infection reveals no evidence for HIV infection.[398]

WB testing may aid in identifying infected persons in the early post-seroconversion period. The WB has very high specificity for identifying persons within 30 days of seroconversion with the criterion of having 3 or fewer bands, and for persons within 90 days of seroconversion with the criterion of having 6 or fewer bands.[402]

**HIV-1 AVIDITY ASSAY.--** Though standard EIA and WB testing is useful to detect any HIV-positive person, it can be useful to differentiate recent and remote infections for epidemiologic purposes. The avidity assay measures antibody avidity, or strength of binding to target antigens. As the humoral immune response proceeds, production of antibodies evolves from low avidity to high avidity. Such avidity assays have been developed for HIV-1.[403]

**HIV-1 REVERSE TRANSCRIPTASE ASSAY.--** An alternative to measuring HIV-1 RNA viral load is the measurement of viral reverse transcriptase (RT). The equipment and technology for this alternative RT assay are simpler and less expensive than those for standard viral load testing. The RT assay compares comparably with viral load testing, but not genotyping.[404]

**LINE IMMUNOASSAY.--** The line immunoassay (LIA) methodology is similar to that of Western blot, but incorporates HIV-1 antigens onto nitrocellulose strips so that each reaction is visualized separately, making interpretation simpler because of the absence of additional bands and contaminating proteins. The antigens on the LIA strip are recombinant antigens or synthetic peptides, rather than lymphocyte-derived viral lysates. For interpretation of a line immunoassay as confirmation of true HIV-1 infection, the CDC requires at least two of three bands must be present: p24, gp41, or gp160/120. The World Health Organization (WHO) guidelines require the presence of two bands, gp41 and gp160/120, for confirmation of HIV-1 infection. The LIA can be used to confirm HIV-2 infection by addition of an HIV-2 specific antigen such as p36.[361]

**HIV-1 IgA ASSAY.**-- The HIV-1 IgA antibody assay on serum has been developed for detection of perinatal HIV-1 infection, because maternal IgA antibody does not cross the placenta. One commercially available method employs removal of IgG antibody in the specimen followed by a simple immunoblot technique with visual interpretation. The sensitivity and specificity of this test in infants over 6 months of age approaches that of the EIA method in adults, while at age 3 months about half are detectable, but only a minority of HIV-1 infections are diagnosable by HIV IgA assay under 1 month of age.[378,405]

**IMMUNOBINDING ANALYSIS.**-- Rapid serologic methods for cost-effective diagnosis of HIV-1 and HIV-2 infection have been developed for use in places where the high cost or longer turnaround time of the EIA assay with smaller numbers of samples makes application of routine HIV testing more difficult. Both the enzyme immunobinding (dot-blot) and particle agglutination assays do not require instrumentation or trained technicians and provide a rapid turnaround time (hours). The tests utilize recombinant-expressed peptides, derived from the protein envelope of HIV. The sensitivity and specificity of these assays are comparable to EIA and Western blot when the test is performed properly. There may be fewer indeterminate results than with conventional Western blot testing.[357,406] This form of rapid testing has been applied to forensic science, providing a rapid means for postmortem diagnosis of HIV infection.[407]

**IMMUNOHISTOCHEMISTRY.**-- Immunohistochemical staining methods for diagnosis of HIV-1 in tissues make use of a monoclonal antibody raised against HIV-1 antigen. This is used to detect cells containing HIV-1 provirus in 10% (v/v) neutral buffered formalin-fixed, paraffin-embedded tissues. The method is similar to other immunohistochemical staining methods and can be employed by many laboratories that already use this technique. However, it is not as sensitive as methods that employ DNA probes. Immunohistochemical reagents with antibody to the p24 can identify HIV infection involving follicular dendritic cells in lymphoid tissues. Additional cells that may be positive with p24 antigen include intrafollicular lymphocytes, small mantle zone lymphocytes, paracortical small and large lymphocytes, macrophages and multinucleated giant cells. Peripheral blood mononuclear cells and multinucleated giant cells may also be positive. Immunohistochemical identification may be limited because it requires visual interpretation, often made difficult by background staining, because cells staining for HIV-1 can be few in number.[408]

**IN SITU HYBRIDIZATION.**-- In situ hybridization (ISH) makes use of molecular hybridization techniques to create a DNA probe to detect target HIV-1 proviral DNA in fresh tissues, paraformaldehyde or alcohol fixed tissues, or 10% (v/v) neutral buffered formalin-fixed paraffin-embedded tissues. Probes are labeled either with isotopes, in which case autoradiography is required, or with biotin, which requires histochemical methods, for detection. This labeling allows the specific cell type to which the probe has hybridized to be identified by light microscopy, which is useful when the exact localization of HIV-1 within tissues is desired.[409]

**HIV-1 CULTURE.**-- HIV-1 viral culture for diagnosis requires cultivation of HIV-1 in vitro. This can be accomplished by co-cultivating peripheral blood mononuclear cells (PBMC's)

from the patient with normal uninfected PBMC's. Culture supernatants are assayed for HIV production twice weekly, typically by p24 antigen assay, for several weeks. As an alternative, plasma may be cultured to detect cell-free viremia. A whole blood co-culture technique may also be used that requires smaller sample volumes.[410] HIV-1 culture can detect approximately half of perinatal HIV-1 infections at birth and about three-fourths up to 3 months of age, with a specificity of 100%. Almost all infants and children beyond 3 months of age have detectable virus.[378,380]

The drawbacks to HIV culture include cost, prolonged time for results to be reported (up to a month), considerable laboratory expertise in performing culture, considerable biohazard to those performing this assay with need for stringent precautions to prevent accidental exposure of laboratory workers, and the possibility of not detecting early infections. Assay of viral reverse transcriptase and use of electron microscopy are additional tools used to assess the growth or cytopathic effects of HIV-1 in cell culture.[377,378]

**IMMUNOLOGIC SURROGATE BIOMARKERS.**-- T-cell lymphocyte subsets can be helpful in monitoring the course of HIV infection. HIV-1 infection produces quantitative abnormalities in cell populations of the immune system. The helper (inducer) lymphocytes designated as CD4 cells (T4 cells) decrease over time, for they are the prime targets of HIV. The lymphocytes that have a suppressor (cytotoxic) function, designated as CD8 cells (T8 cells), are not decreased and may initially be increased. Abnormalities in numbers of CD4 and CD8 T-cell subsets and the helper/suppressor ratio (CD4/CD8) were used very early in the AIDS pandemic to help define persons affected with AIDS before a screening test for HIV-1 was available. A low number of CD4 lymphocytes alone or in combination with a decreased CD4:CD8 ratio and total lymphocyte count can be useful as a predictor of HIV-1 seropositivity and progression of disease.

The CD4 lymphocyte count is typically measured by flow cytometry. Monoclonal antibodies to the various lymphocyte subpopulations (CD3, CD4, CD8, CD45, etc.) with fluorochrome marker are utilized. Guidelines for performance of this assay have been published by the Centers for Disease Control.[411]

In persons with HIV infection 6 years of age or older, a CD4:CD8 ratio of less than 1.0, a total CD4 lymphocyte count of less than 500/ $\mu$ L, and a total lymphocyte count of less than 1500/ $\mu$ L indicate a poor prognosis (see section on *Definition of Pediatric HIV Infection and AIDS* that follows for immunologic parameters in persons <6 years of age).[222,225] The CD4% and the CD4 count both correlate with disease progression, and overall discrepancies between them are small.[412] Elevated levels of soluble CD30 activation molecule from T-lymphocytes is another factor that is associated with progression to AIDS independent of other factors.[72]

The CD4 lymphocyte count can demonstrate variability, even in the same patient. There can be diurnal variations in the CD4 lymphocyte count that suggest obtaining blood samples in the morning.[413] Additional laboratory testing factors play a role in measurement of CD4 lymphocytes and include variations in total white blood cell count, lymphocyte percentage, and CD4 percentage. Physiologic factors may include exercise as well as consumption of tobacco, alcohol, and caffeine.[414]

Serum beta<sub>2</sub>-microglobulin (B2-M) is a polypeptide that forms the light chain of class I major histocompatibility complex antigens found on most nucleated cells, can be measured by immunoassays such as EIA. Rising levels of B2-M, which usually increases above background

in serum within 6 months of seroconversion, can be used as a marker of disease progression in HIV infection. Increased levels of B2-M in cerebrospinal fluid can be helpful as a marker for HIV-related neurologic diseases such as HIV dementia. Increased levels of B2-M also predict progression to AIDS in perinatally acquired cases of HIV infection. Zidovudine therapy appears to decrease B2-M levels in serum for 2 to 3 months following initiation of therapy, but levels increase to pretreatment levels by 6 months.[225]

An inflammatory biomarker of acute HIV infection is the acute phase protein serum amyloid A (A-SAA), that appears soon after infection; a high level may reflect hyperinfection. Interferon-gamma also increases with acute infection. The marker CD14 is associated with subclinical atherosclerosis progression and neurocognitive impairment. Inflammatory biomarkers that may accompany HIV and response to treatment may include high sensitivity C-reactive protein (hs-CRP), D-dimer, and interleukin-6 (IL-6). Both hs-CRP and IL-6 appear to increase with progression of HIV infection. IL-6 increases with immune reconstitution inflammatory syndrome (IRIS). An elevated fibrinogen level is associated with higher CD4 count, higher viral load, and increased risk for death. The D-dimer decreases in response to antiretroviral therapy.[415,416]

Neopterin is a product of macrophages and B-lymphocytes stimulated with interferon gamma. It increases in a variety of inflammatory conditions. Neopterin can be measured in serum, urine, and cerebrospinal fluid by radioimmunoassay and by chromatography. Increasing serum neopterin levels correlate with progression of HIV infection to AIDS. Within 1 to 2 months following initiation of zidovudine therapy, neopterin levels initially fall, then increase slightly and remain below pretreatment levels for about a year.[225]

**STRATEGIES FOR HIV TESTING.**-- The primary approach to detection of HIV infection remains use of EIA serologic tests for HIV antibody. EIA tests for HIV antibody must be repeatedly reactive and confirmed before reporting as positive. Strategies that employ two or more separate methodologies can be utilized to provide high sensitivity and specificity, while avoiding the use of WB that is technically difficult and may yield indeterminate results.[417] False negative results are extremely uncommon, and with repeat testing after 3 months to avoid the "window" of possible seronegativity following initial HIV infection, virtually eliminated. Perinatal infections can be confirmed by p24 antigen assay, HIV IgA assay, HIV-1 RNA assay, and by HIV viral culture. HIV-1-RNA assay is most often the practical choice. Disease progression and response to antiretroviral therapies can be monitored with measurement of plasma viremia by PCR or by following the CD4 lymphocyte count.

## **DIAGNOSTIC CRITERIA FOR AIDS IN CHILDREN, ADOLESCENTS AND ADULTS**

The Centers for Disease Control (CDC) have promulgated criteria for diagnosis, reporting, and clinical staging of AIDS in the United States based upon knowledge about HIV, available laboratory testing, and clinical course.[418,419,420,421,422]

The 2008 CDC revised surveillance case definition for HIV infection applies to any HIV (including HIV-1 and HIV-2) infection and incorporates the reporting criteria for HIV infection and AIDS into a single case definition and excludes confirmation of HIV infection through diagnosis of AIDS-defining conditions alone. The criteria are as follows:[423]

### **2008 Surveillance Case Definition for HIV Infection Among Adults and Adolescents**

For surveillance purposes, a reportable case of HIV infection among adults and adolescents aged  $\geq 13$  years is categorized by increasing severity as stage 1, stage 2, or stage 3 (AIDS) or as stage unknown.

#### **Laboratory Criteria**

Positive result from an HIV antibody screening test (e.g., reactive enzyme immunoassay [EIA]) confirmed by a positive result from a supplemental HIV antibody test (e.g., Western blot or indirect immunofluorescence assay test).

OR

Positive result or report of a detectable quantity (i.e., within the established limits of the laboratory test) from any of the following HIV virologic (i.e., non-antibody) tests: -- HIV nucleic acid (DNA or RNA) detection test (e.g., polymerase chain reaction [PCR]) -- HIV p24 antigen test, including neutralization assay -- HIV isolation (viral culture).

#### **Other Criterion (for Cases that Do Not Meet Laboratory Criteria)**

HIV infection diagnosed by a physician or qualified medical-care provider based on the laboratory criteria and documented in a medical record. Oral reports of prior laboratory test results are not acceptable.

#### **Case Classification**

A confirmed case meets the laboratory criteria for diagnosis of HIV infection and one of the four HIV infection stages (stage 1, stage 2, stage 3, or stage unknown). Although cases with no information on CD4+ T-lymphocyte count or percentage and no information on AIDS-defining conditions can be classified as stage unknown, every effort should be made to report CD4+ T-lymphocyte counts or percentages and the presence of AIDS-defining conditions at the time of diagnosis. Additional CD4+ T-lymphocyte counts or percentages and any identified AIDS-defining conditions can be reported as recommended.

**HIV Infection, Stage 1**

No AIDS-defining condition and either CD4+ T-lymphocyte count of  $\geq 500$  cells/ $\mu$ L or CD4+ T-lymphocyte percentage of total lymphocytes of  $\geq 29$ .

**HIV Infection, Stage 2**

No AIDS-defining condition and either CD4+ T-lymphocyte count of 200--499 cells/ $\mu$ L or CD4+ T-lymphocyte percentage of total lymphocytes of 14--28.

**HIV Infection, Stage 3 (AIDS)**

CD4+ T-lymphocyte count of  $< 200$  cells/ $\mu$ L or CD4+ T-lymphocyte percentage of total lymphocytes of  $< 14$  or documentation of an AIDS-defining condition (see below). Documentation of an AIDS-defining condition supersedes a CD4+ T-lymphocyte count of  $\geq 200$  cells/ $\mu$ L and a CD4+ T-lymphocyte percentage of total lymphocytes of  $\geq 14$ . Definitive diagnostic methods for these conditions are shown below from the 1993 revised HIV classification system and the expanded AIDS case definition and from the U.S. National Notifiable Diseases Surveillance System.

**HIV Infection, Stage Unknown**

No information available on CD4+ T-lymphocyte count or percentage and no information available on AIDS-defining conditions. (Every effort should be made to report CD4+ T-lymphocyte counts or percentages and the presence of AIDS-defining conditions at the time of diagnosis.)

A diagnosis of acute HIV infection indicates documented evidence of detectable HIV RNA or DNA or of p24 antigen in plasma or serum in the presence of a documented negative or indeterminate result from an HIV antibody test. These laboratory tests should be conducted on the same specimen or on specimens obtained on the same day. Acute HIV infection occurs approximately during the time from viral acquisition until seroconversion (i.e., the development of measurable levels of HIV-specific antibodies). During this period, early immune responses to the virus produce distinctive characteristics; 40% to 80% of patients develop clinical symptoms of a nonspecific viral illness (e.g., fever, fatigue, or rash) typically lasting 1--2 weeks.

**2008 Surveillance Case Definition for HIV Infection Among Children Aged <18 Months**

The 2008 definition takes into account new available testing technologies. Because diagnostic laboratory testing for HIV infection among children aged <18 months might be unreliable, children in this age group with perinatal HIV exposure whose illness meets the AIDS case definition on the basis of clinical criteria are considered presumptively HIV infected when the mother has laboratory-confirmed HIV infection. The definitive or presumptive exclusion of HIV infection for surveillance purposes does not mean that

clinical HIV infection can be ruled out. For the purposes of calculating the exact timing of tests (e.g., when a specimen was obtained for laboratory testing) based on the surveillance case definition, 1 month corresponds to 30 days.

### **Criteria for Definitive or Presumptive HIV Infection**

A child aged <18 months is categorized for surveillance purposes as definitively or presumptively HIV infected if born to an HIV-infected mother and if the laboratory criterion or at least one of the other criteria is met.

#### **Laboratory Criterion for Definitive HIV Infection**

A child aged <18 months is categorized for surveillance purposes as definitively HIV infected if born to an HIV-infected mother and the following laboratory criterion is met.

Positive results on two separate specimens (not including cord blood) from one or more of the following HIV virologic (non-antibody) tests: -- HIV nucleic acid (DNA or RNA) detection -- HIV p24 antigen test, including neutralization assay, for a child aged  $\geq 1$  month -- HIV isolation (viral culture)

#### **Laboratory Criterion for Presumptive HIV Infection**

A child aged <18 months is categorized for surveillance purposes as presumptively HIV infected if 1) born to an HIV-infected mother, 2) the criterion for definitively HIV infected is not met, and 3) the following laboratory criterion is met.

Positive results on one specimen (not including cord blood) from the listed HIV virologic tests (HIV nucleic acid detection test; HIV p24 antigen test, including neutralization assay, for a child aged  $\geq 1$  month; or HIV isolation [viral culture] for definitively HIV infected) and no subsequent negative results from HIV virologic or HIV antibody tests.

#### **Other Criteria (for Cases that Do Not Meet Laboratory Criteria for Definitive or Presumptive HIV Infection)**

HIV infection diagnosed by a physician or qualified medical-care provider based on the laboratory criteria and documented in a medical record. Oral reports of prior laboratory test results are not acceptable.

OR

When test results regarding HIV infection status are not available, documentation of a condition that meets the criteria in the 1987 pediatric surveillance case definition for AIDS.

### **Criteria for Uninfected with HIV, Definitive or Presumptive**

A child aged <18 months born to an HIV-infected mother is categorized for surveillance purposes as either definitively or presumptively uninfected with HIV if 1) the criteria for definitive or presumptive HIV infection are not met and 2) at least one of the laboratory criteria or other criteria are met.

#### **Laboratory Criteria for Uninfected with HIV, Definitive**

A child aged <18 months born to an HIV-infected mother is categorized for surveillance purposes as definitively uninfected with HIV if 1) the criteria for definitive or presumptive HIV infection are not met and 2) at least one of the laboratory criteria or other criteria are met.

At least two negative HIV DNA or RNA virologic tests from separate specimens, both of which were obtained at age  $\geq 1$  month and one of which was obtained at age  $\geq 4$  months.

OR

At least two negative HIV antibody tests from separate specimens obtained at age  $\geq 6$  months.

AND

No other laboratory or clinical evidence of HIV infection (i.e., no positive results from virologic tests [if tests were performed] and no current or previous AIDS-defining condition).

#### **Laboratory Criteria for Uninfected with HIV, Presumptive**

A child aged <18 months born to an HIV-infected mother is categorized for surveillance purposes as presumptively uninfected with HIV if 1) the criteria for definitively uninfected with HIV are not met and 2) at least one of the laboratory criteria are met. Two negative RNA or DNA virologic tests, from separate specimens, both of which were obtained at age  $\geq 2$  weeks and one of which was obtained at age  $\geq 4$  weeks.<sup>§§</sup>

OR

One negative RNA or a DNA virologic test from a specimen obtained at age  $\geq 8$  weeks.

OR

One negative HIV antibody test from a specimen obtained at age  $\geq 6$  months.

OR



One positive HIV virologic test followed by at least two negative tests from separate specimens, one of which is a virologic test from a specimen obtained at age  $\geq 8$  weeks or an HIV antibody test from a specimen obtained at age  $\geq 6$  months.

AND

No other laboratory or clinical evidence of HIV infection (i.e., no subsequent positive results from virologic tests if tests were performed, and no AIDS-defining condition for which no other underlying condition indicative of immunosuppression exists).

**Other Criteria (for Cases that Do Not Meet Laboratory Criteria for Uninfected with HIV, Definitive or Presumptive)**

Determination of uninfected with HIV by a physician or qualified medical-care provider based on the laboratory criteria and who has noted the HIV diagnostic test results in the medical record. Oral reports of prior laboratory test results are not acceptable.

AND

No other laboratory or clinical evidence of HIV infection (i.e., no positive results from virologic tests [if tests were performed] and no AIDS-defining condition for which no other underlying condition indicative of immunosuppression exists).

**Criteria for Indeterminate HIV Infection**

A child aged  $<18$  months born to an HIV-infected mother is categorized as having perinatal exposure with an indeterminate HIV infection status if the criteria for infected with HIV and uninfected with HIV are not met.

The exclusion of HIV infection (definitive or presumptive) for surveillance purposes does not mean that clinical HIV infection can be ruled out. These categories are used for surveillance classification purposes and should not be used to guide clinical practice. A child with perinatal HIV exposure should continue to be monitored clinically according to nationally accepted treatment and care guidelines 1) monitor for potential complications of exposure to antiretroviral medications during the perinatal period and 2) confirm the absence of HIV infection with repeat clinical and laboratory evaluations.

**2008 Surveillance Case Definitions for HIV Infection and AIDS Among Children Aged 18 Months to  $<13$  Years**

The 2008 laboratory criteria for reportable HIV infection among persons aged 18 months to  $<13$  years exclude confirmation of HIV infection through the diagnosis of AIDS-defining conditions alone. Laboratory-confirmed evidence of HIV infection is now required for all reported cases of HIV infection among children aged 18 months to  $<13$  years.

### **Criteria for HIV Infection**

Children aged 18 months to <13 years are categorized as HIV infected for surveillance purposes if at least one of laboratory criteria or the other criterion is met.

#### **Laboratory Criteria**

Positive result from a screening test for HIV antibody (e.g., reactive EIA), confirmed by a positive result from a supplemental test for HIV antibody (e.g., Western blot or indirect immunofluorescence assay).

OR

Positive result or a detectable quantity by any of the following HIV virologic (non-antibody) tests: -- HIV nucleic acid (DNA or RNA) detection (e.g., PCR) -- HIV p24 antigen test, including neutralization assay -- HIV isolation (viral culture)

#### **Other Criterion (for Cases that Do Not Meet Laboratory Criteria)**

HIV infection diagnosed by a physician or qualified medical-care provider based on the laboratory criteria and documented in a medical record. Oral reports of prior laboratory test results are not acceptable.

### **Criteria for AIDS**

Children aged 18 months to <13 years are categorized for surveillance purposes as having AIDS if the criteria for HIV infection are met and at least one of the AIDS-defining conditions has been documented (see below).

The 2008 surveillance case definition for AIDS retains the 24 clinical conditions in the AIDS surveillance case definition published in 1987 and revised in 1994 for children aged <13 years (see below). Because the 2008 definition requires that all AIDS diagnoses have laboratory-confirmed evidence of HIV infection, the presence of any AIDS-defining condition listed below indicates a surveillance diagnosis of AIDS.

### **Clinical Categories for Staging of HIV Infection in the 1993 Revised Definition [421]**

CATEGORY A: Conditions listed in Categories B and C must not have occurred. A person is classified in Category A with one or more of the following conditions listed below with documented HIV infection:

- \* Asymptomatic HIV infection;
- \* Persistent generalized lymphadenopathy;
- \* Acute (primary) HIV infection with accompanying illness or a history of acute HIV infection.

**CATEGORY B:** For classification purposes, Category B conditions take precedence over those in Category A. Persons are included in Category B with symptomatic conditions not included among conditions listed in clinical Category C and that meet at least one of the following criteria: (a) the conditions are attributed to HIV infection or are indicative of a defect in cell-mediated immunity; or (b) the conditions are considered by physicians to have a clinical course or to require management that is complicated by HIV infection. Many Category B diseases are not life threatening. Examples of conditions in clinical Category B include, but are not limited to:

- \* Anorectal squamous epithelial dysplasia or carcinoma;
- \* Bacillary angiomatosis;
- \* Candidiasis, oropharyngeal (oral thrush);
- \* Candidiasis, vulvovaginal; persistent, frequent, or poorly responsive to therapy;
- \* Constitutional symptoms, such as fever (38.5<sup>0</sup> C) or diarrhea lasting >1 month;
- \* Hairy leukoplakia, oral;
- \* Varicella (herpes) zoster virus (shingles), involving at least two distinct episodes or more than one dermatome;
- \* Idiopathic thrombocytopenic purpura;
- \* Listeriosis;
- \* Nephropathy, HIV-related;
- \* Onychomycosis;
- \* Pelvic inflammatory disease, particularly if complicated by tubo-ovarian abscess;
- \* Peripheral neuropathy

**CATEGORY C:** For classification purposes, once a Category C condition has occurred, the person so classified will remain in Category C. Many Category C diseases are life threatening. Clinical conditions for inclusion of a person in Category C are:

- \* Candidiasis of bronchi, trachea, or lungs;
- \* Candidiasis, esophageal;
- \* Cervical cancer, invasive;
- \* Coccidioidomycosis, disseminated or extrapulmonary;
- \* Cryptococcosis, extrapulmonary;
- \* Cryptosporidiosis, chronic intestinal (>1 month's duration);
- \* Cytomegalovirus disease (other than liver, spleen, or lymph nodes);
- \* Cytomegalovirus retinitis (with loss of vision);
- \* Encephalopathy, HIV-related;
- \* Herpes simplex: chronic ulcer(s) (>1 month's duration); or bronchitis, pneumonitis, or esophagitis;
- \* Histoplasmosis, disseminated or extrapulmonary;
- \* Isosporiasis, chronic intestinal (>1 month's duration)
- \* Kaposi sarcoma;
- \* Lymphoma, Burkitt (or equivalent term);
- \* Lymphoma, immunoblastic (or equivalent term);
- \* Lymphoma, primary, of brain;

- \* *Mycobacterium avium* complex or *M. kansasii*, disseminated or extrapulmonary;
- \* *Mycobacterium tuberculosis*, any site (pulmonary or extrapulmonary)
- \* *Penicilliosis marneffei* infection, disseminated
- \* *Pneumocystis jiroveci* (*carinii*) pneumonia;
- \* Pneumonia, recurrent;
- \* Progressive multifocal leukoencephalopathy;
- \* *Salmonella* septicemia, recurrent;
- \* Toxoplasmosis of brain;
- \* Wasting syndrome due to HIV

The subdivisions of the above categories are made according to the CD4 counts as follows:

Categories A1, B1, C1:	CD4 $\geq 500$ cells/ $\mu$ L
Categories A2, B2, C2:	CD4 200 to 499 cells/ $\mu$ L
Categories A3, B3, C3:	CD4 <200 cells/ $\mu$ L, or <14% CD4 cells

**DIAGNOSIS OF AIDS:** All persons within Category C as well as all persons in subset 3 with a CD4 lymphocyte count <200/ $\mu$ L (or <14% CD4 cells) meet surveillance criteria for a definition of AIDS.

### **Clinical Staging of HIV Infection (WHO Criteria)**

The World Health Organization (WHO) has developed criteria for clinical staging of adolescents and adults >15 years of age with established HIV infection, but without additional laboratory testing for CD4 lymphocyte counts, HIV-1 RNA levels, or other laboratory measures of ongoing immunologic status. At least one clinical condition must be present for assignment to 1 of 4 clinical stages. Once assigned to a particular stage, persons remain at that stage even if recovery occurs from the condition that led to assignment. The clinical stage helps to determine antiretroviral treatment (ART) strategies.[424]

#### **Primary HIV Infection**

- Asymptomatic
- Acute retroviral syndrome

#### **Clinical Stage 1 (ART if CD4 $\leq 350$ / $\mu$ L):**

- Asymptomatic
- Persistent generalized lymphadenopathy (lymphadenopathy of at least two sites, not including inguinal, for longer than 6 months)

**Clinical Stage 2 (ART if CD4  $\leq$ 350/ $\mu$ L):**

- Moderate unexplained weight loss (<10% of presumed or measured body weight)
- Recurrent respiratory tract infections (sinusitis, bronchitis, otitis media, pharyngitis)
- Herpes zoster
- Angular cheilitis
- Recurrent oral ulcerations
- Papular pruritic eruptions
- Seborrheic dermatitis
- Fungal nail infections of fingers (onychomycosis)

**Clinical Stage 3 (Offer ART):**

- Severe weight loss (>10% of presumed or measured body weight)
- Unexplained chronic diarrhea for longer than one month
- Unexplained persistent fever (intermittent or constant for longer than one month)
- Oral candidiasis
- Oral hairy leukoplakia
- Pulmonary tuberculosis (TB) diagnosed in last two years
- Severe presumed bacterial infections (e.g. pneumonia, empyema, pyomyositis, bone or joint infection, meningitis, bacteremia)
- Acute necrotizing ulcerative stomatitis, gingivitis or periodontitis
- Unexplained anemia (<8 g/dl), and or neutropenia (<500/ $\mu$ L) and or thrombocytopenia (<50,000/ $\mu$ L) for more than one month

**Clinical Stage 4 (All AIDS-defining Illnesses, Offer ART):**

- HIV wasting syndrome
- *Pneumocystis jiroveci* pneumonia
- Recurrent severe bacterial pneumonia
- Chronic herpes simplex infection (orolabial, genital or anorectal of >1 month's duration or visceral at any site)
- Esophageal candidiasis (or candidiasis of trachea, bronchi or lungs)
- Extrapulmonary tuberculosis
- Kaposi sarcoma
- Cytomegalovirus disease (retinitis or infection of other organs, excluding liver, spleen and lymph nodes)
- Central nervous system toxoplasmosis
- HIV encephalopathy
- Extrapulmonary cryptococcosis including meningitis
- Disseminated nontuberculous mycobacterial infection
- Progressive multifocal leukoencephalopathy
- Chronic cryptosporidiosis
- Chronic isosporiasis
- Disseminated mycosis (histoplasmosis, coccidioidomycosis)
- Recurrent septicemia (including nontyphoidal *Salmonella*)

- Lymphoma (cerebral or B cell non-Hodgkin)
- Invasive cervical carcinoma
- Atypical disseminated leishmaniasis
- Symptomatic HIV-associated nephropathy or HIV-associated cardiomyopathy

For pediatric HIV infection (<15 years of age), the criteria for use of antiretroviral therapy (ART) by clinical staging and laboratory findings are as follows:

- Infants and children <2 years of age: Start ART immediately upon diagnosis
- Children  $\geq 2$  years and <5 years of age:  $\leq 25\%$  CD4 or CD4 count of  $\leq 750$  cells/ $\mu\text{L}$
- Children  $\geq 5$  years of age: CD4 count of  $\leq 350$  cells/ $\mu\text{L}$

## DEFINITIVE DIAGNOSTIC METHODS FOR DISEASES INDICATIVE OF AIDS

The conditions listed above under Category C may be diagnosed by a variety of methods, depending upon the nature of the disease and the diagnostic methods available. These conditions and the definitive methods are delineated below and in Table 4.

The following diseases are definitively diagnosed by microscopy (histology or cytology): cryptosporidiosis, isosporiasis, Kaposi sarcoma, lymphoma, lymphoid pneumonia (lymphocytic interstitial pneumonitis) or hyperplasia, *Pneumocystis jiroveci* (*carinii*) pneumonia, progressive multifocal leukoencephalopathy, toxoplasmosis, cervical cancer.

Candidiasis is definitively diagnosed by: Gross inspection by endoscopy or autopsy, or by microscopy (histology or cytology) on a specimen obtained directly from the tissues affected (including scrapings from the mucosal surface), not from a culture.

The following diseases are definitively diagnosed by microscopy (histology or cytology), culture, or detection of antigen in a specimen obtained directly from the tissues affected or a fluid from those areas: coccidioidomycosis, cryptococcosis, cytomegalovirus, herpes simplex virus, histoplasmosis.

The following diseases are diagnosed definitively by culture: tuberculosis, other mycobacteriosis, salmonellosis, and other bacterial infection.

HIV encephalopathy (AIDS dementia) is diagnosed by clinical findings of a disabling cognitive and/or motor dysfunction interfering with occupation or activities of daily living, or loss of behavioral developmental milestones affecting a child, progressing over weeks to months, in the absence of a concurrent illness or condition other than HIV infection that could explain the findings. Methods to rule out such concurrent illnesses and conditions must include cerebrospinal fluid examination, and either brain imaging (computerized tomography or magnetic resonance imaging) or autopsy.

HIV wasting syndrome ("slim disease") is diagnosed by findings of profound involuntary weight loss greater than 10% of baseline body weight plus either chronic diarrhea (2 or more loose stools per day for 30 or more days) or chronic weakness and documented fever (for 30 or more days, intermittent or constant) in the absence of a concurrent illness or condition other than HIV infection that could explain the findings (such as cancer, tuberculosis, cryptosporidiosis, or other specific enteritis).

Recurrent pneumonia is diagnosed definitively by the finding of recurrence (more than one episode of pneumonia in a 1 year period), acute onset (new radiographic evidence not present earlier) of pneumonia diagnosed by both a) culture (or other organism-specific diagnostic method) obtained from a clinically reliable specimen of a pathogen that typically causes pneumonia (other than *Pneumocystis jiroveci* (*carinii*) or *Mycobacterium tuberculosis*), and b) radiologic evidence of pneumonia; cases that do not have laboratory confirmation of a causative organism for one of the episodes of pneumonia will be considered to be presumptively diagnosed.

## PEDIATRIC HIV INFECTION AND AIDS

Most pediatric HIV infections are the result of perinatal transmission. There are two major patterns of pediatric HIV disease:[46]

- Acute infantile disease: rapid progression to AIDS with death by age 2 from opportunistic infection if untreated by antiretroviral therapy.
- Chronic infection: onset of AIDS-defining illness a decade or more later. Children may have neurodevelopmental delay along with cerebral atrophy and microcephaly because ongoing HIV infection damaged the developing brain. Outcomes may include corticospinal tract damage and a persistent vegetative state.

The diagnosis of HIV infection and of AIDS in children under 13 years of age varies slightly from that in an adult. Significantly, children under the age of 18 months may still retain passively acquired maternal HIV antibody, while those above 18 months rarely have residual maternal antibody, so standard immunologic tests alone for HIV infection (EIA and confirmatory Western blot) cannot be used to define HIV infection in this setting. Both HIV viral culture and polymerase chain reaction (PCR) assays for HIV RNA or proviral DNA, however, can be used to detect HIV infection in infants born to HIV-infected mothers with nearly 100% sensitivity by 3 to 6 months of age.[420]

If mother's HIV-1 status is unknown, then rapid HIV-1 antibody testing of a newborn can identify possible exposure so that antiretroviral prophylaxis can be initiated within the first 12 hours of life when serologic test results are positive. Those newborns identified with maternal HIV-1 antibody can undergo testing with HIV-1 DNA or RNA assays within the first 14 days of life, at 1 to 2 months of age, and at 3 to 6 months of age. If any of these test results are positive, repeat testing is recommended to confirm the diagnosis of HIV-1 infection. A diagnosis of HIV-1 infection can be made based on 2 positive HIV-1 DNA or RNA assay results.[425]

In non-breastfeeding children younger than 18 months with no prior positive HIV-1 virologic test results, presumptive exclusion of HIV-1 infection can be based on 2 negative virologic test results (1 obtained at  $\geq 2$  weeks and 1 obtained at  $\geq 4$  weeks of age); 1 negative virologic test result obtained at  $\geq 8$  weeks of age; or 1 negative HIV-1 antibody test result obtained at  $\geq 6$  months of age. Alternatively, presumptive exclusion of HIV-1 infection can be based on 1 positive HIV-1 virologic test with at least 2 subsequent negative virologic test results (at least 1 of which is performed at  $\geq 8$  weeks of age) or negative HIV-1 antibody test results (at least 1 of which is performed at  $\geq 6$  months of age).

Definitive exclusion of HIV-1 infection is based on 2 negative virologic test results, 1 obtained at  $\geq 1$  month of age and 1 obtained at  $\geq 4$  months of age, or 2 negative HIV-1 antibody test results from separate specimens obtained at  $\geq 6$  months of age. For both presumptive and definitive exclusion of infection, the child should have no other laboratory (e.g., no positive virologic test results) or clinical (e.g., no AIDS-defining conditions) evidence of HIV-1 infection. Confirmation of the absence of HIV-1 infection can be done with a negative HIV-1 antibody assay result at 12 to 18 months of age. For breastfeeding infants, a similar testing algorithm can be followed, with timing of testing starting from the date of complete cessation of breastfeeding instead of the date of birth.



The criteria for diagnosis of human immunodeficiency virus (HIV) infection in children was redefined by the Centers for Disease Control (CDC) in 1994 (establishing new criteria beyond the 1987 AIDS surveillance case definition[419]) and superseded by the 1997 definition.[422] Classification into mutually exclusive categories is made through assessment of: a) infection status, b) clinical status, and c) immunologic status. An HIV-infected child cannot be reclassified from a more severe to a less severe category.

The clinical categories for children with HIV infection are made by the 1994 CDC definition as follows:[420]

Category N: Not symptomatic. Children who have no signs or symptoms considered to be the result of HIV infection or who have only one of the conditions listed in Category A.

Category A: Mildly symptomatic. Children with two or more of the conditions listed below but none of the conditions listed in Category B and C.

- \* Lymphadenopathy ( $\geq 0.5$  cm at more than two sites; bilateral = one site)
- \* Hepatomegaly
- \* Splenomegaly
- \* Dermatitis
- \* Parotitis
- \* Recurrent or persistent upper respiratory infection, sinusitis, or otitis media

Category B: Moderately symptomatic. Children who have symptomatic conditions other than those listed for Category A or C that are attributed to HIV infection.

Examples of conditions in clinical Category B include but are not limited to:

- \* Anemia ( $< 8$  gm/dL), neutropenia ( $< 1000/\text{mm}^3$ ), or thrombocytopenia ( $< 100,000/\text{mm}^3$ ) persisting  $\geq 30$  days
- \* Bacterial meningitis, pneumonia, or sepsis (single episode)
- \* Candidiasis, oropharyngeal (thrush), persisting ( $> 2$  months) in children  $> 6$  months of age
- \* Cardiomyopathy
- \* Cytomegalovirus infection, with onset before one month of age
- \* Diarrhea, recurrent or chronic
- \* Hepatitis
- \* Herpes simplex virus (HSV) stomatitis, recurrent (more than 2 episodes within 1 year)
- \* Varicella (herpes) zoster virus (shingles) involving at least two distinct episodes of more than one dermatome
- \* Leiomyosarcoma
- \* Lymphoid interstitial pneumonitis (LIP) or pulmonary lymphoid hyperplasia complex
- \* Nephropathy
- \* Nocardiosis
- \* Persistent fever (lasting 1 month)
- \* Toxoplasmosis with onset before 1 month of age
- \* Varicella, disseminated (complicated chicken pox)

Category C: Severely symptomatic. Children who have any condition listed in the 1987 surveillance case definition for acquired immunodeficiency syndrome with the exception of LIP. Conditions included in clinical Category C for children infected with human immunodeficiency virus (HIV) include:

- \* Serious bacterial infections, multiple or recurrent (i.e., any combination of at least two culture-confirmed infections within a 2-year period), of the following types: septicemia, pneumonia, meningitis, bone or joint infection, or abscess of an internal organ or body cavity (excluding otitis media, superficial skin or mucosal abscesses, and indwelling catheter-related infections)
- \* Candidiasis, esophageal or pulmonary (bronchi, trachea, lungs)
- \* Coccidioidomycosis, disseminated (at a site other than or in addition to lungs or cervical or hilar lymph nodes)
- \* Cryptococcosis, extrapulmonary
- \* Cryptosporidiosis or isosporiasis with diarrhea persisting >1 month
- \* Cytomegalovirus disease with onset of symptoms at age >1 month (at a site other than liver, spleen, or lymph nodes)
- \* Encephalopathy (for criteria, see section in Central Nervous System Pathology in AIDS)
- \* Herpes simplex virus infection causing a mucocutaneous ulcer that persists for >1 month; or bronchitis, pneumonitis, or esophagitis for any duration affecting a child >1 month of age
- \* Histoplasmosis, disseminated (at a site other than or in addition to lungs or cervical or hilar lymph nodes)
- \* Kaposi sarcoma
- \* Lymphoma, primary, in brain
- \* Lymphoma, small, noncleaved (Burkitt), or immunoblastic or large cell lymphoma of B-cell or unknown immunologic phenotype
- \* *Mycobacterium tuberculosis*, disseminated or extrapulmonary
- \* *Mycobacterium*, other species or unidentified species, disseminated (at a site other than or in addition to lungs, skin, or cervical or hilar lymph nodes)
- \* *Mycobacterium avium* complex or *Mycobacterium kansasii*, disseminated (at a site other than or in addition to lungs, skin, or cervical or hilar lymph nodes)
- \* *Pneumocystis jiroveci* (*carinii*) pneumonia
- \* Progressive multifocal leukoencephalopathy
- \* Salmonella (non typhoid) septicemia, recurrent
- \* Toxoplasmosis of the brain with onset at >1 month of age
- \* Wasting syndrome in the absence of concurrent illness other than HIV infection that could explain the following findings:

a) persistent weight loss >10% of baseline

or:

b) downward crossing of at least two of the following percentile lines on the weight-for-age chart (e.g., 95th, 75th, 50th, 25th, 5th) in a child  $\geq 1$  year of age

or:

- c) <5th percentile on weight-for-height chart on two consecutive measurements,  $\geq 30$  days apart PLUS a) chronic diarrhea (i.e., at least two loose stools per day for  $\geq 30$  days) OR b) documented fever (for  $\geq 30$  days, intermittent or constant)

The immunologic categories for clinical classification of HIV infection in children is based on age-specific CD4 lymphocyte counts and the percent of total lymphocytes as follows:

Immunologic category 1:	No evidence of suppression
Immunologic category 2:	Evidence of moderate suppression
Immunologic category 3:	Severe suppression

Immunologic category	Age of child					
	< 12 months		1-5 years		6-12 years	
	CD4 / $\mu$ L	%	CD4 / $\mu$ L	%	CD4 / $\mu$ L	%
1:	$\geq 1500$	( $\geq 25$ )	$\geq 1000$	( $\geq 25$ )	$\geq 500$	( $\geq 25$ )
2:	750-1499	(15-24)	500-999	(15-24)	200-499	(15-24)
3:	<750	(<15)	<500	(<15)	<200	(<15)

Thus, the 1994 CDC classification system for HIV infection can be summarized as follows:

N = No signs or symptoms  
 A = Mild signs or symptoms  
 B = Moderate signs or symptoms  
 C = Severe signs or symptoms

Immunologic Categories		Clinical Categories			
		N	A	B	C
1.	No evidence of suppression	N1	A1	B1	C1
2.	Evidence of moderate suppression	N2	A2	B2	C2
3.	Severe suppression	N3	A3	B3	C3

## **CRITERIA FOR PERSISTANT GENERALIZED LYMPHADENOPATHY**

The original criteria for inclusion of patients into the condition of persistent generalized lymphadenopathy (PGL) are given below:

- \* Persistent generalized lymphadenopathy involving two or more extra inguinal sites lasting 3 months or more
- \* Absence of an intercurrent disease or illness causing the lymphadenopathy
- \* Reactive pattern on tissue biopsy

## **CRITERIA FOR AIDS-RELATED COMPLEX**

AIDS-related complex (ARC) was a category of HIV infection used early in the AIDS pandemic before more specific staging criteria were formulated. The term ARC is no longer widely used. The definition is given here for historical purposes and to allow correlation with earlier studies. AIDS-related complex is defined as a syndrome in which a person has laboratory evidence for HIV infection along with PGL, without other causes for immunodeficiency, and has at least two of the clinical and two of the laboratory findings listed below. Additional clinical disorders commonly found in patients with ARC include cutaneous and oral fungal infections, chronic diarrhea, idiopathic thrombocytopenic purpura, nephrotic syndrome, and in children failure to thrive with chronic and persistent infections. Often, further testing of the immune system is necessary before other causes of these disorders can be ruled out.

Clinical findings may include:

- \* Intermittent or continuous fever (greater than 38.5<sup>0</sup> C) not associated with infection
- \* Unexplained weight loss of > 10% of body weight
- \* Intermittent or continuous diarrhea (more than 3 stools per day) without an identifiable pathogen
- \* Unexplained excessive fatigue producing decreased physical or mental ability
- \* Intermittent or continuous night sweats without an infection.

Laboratory findings may include:

- \* Neutropenia, lymphopenia, thrombocytopenia, or anemia
- \* Decreased absolute T-helper cells
- \* Decreased T-helper/suppressor ratio
- \* Decreased blastogenesis
- \* Increased serum immunoglobulin
- \* Anergy to skin tests.

## OTHER CAUSES OF IMMUNOSUPPRESSION

Disease processes may occur in a population at risk for HIV infection that are neither caused by HIV, nor are potentiating factors, but which can lead to immunosuppression. These conditions may account for acquired immunodeficiency states. Lymphoreticular malignancies can occur in age groups in which HIV infection is prevalent, but such diseases have not been linked with AIDS by definition, except for the high grade lymphomas in persons within whom an HIV infection can be demonstrated. Among these are non-Hodgkin lymphomas, leukemias, and Hodgkin lymphoma. Persons undergoing cancer chemotherapy may also have immune system dysfunction and clinical findings similar to patients with AIDS. Patients undergoing organ transplantation and persons with collagen vascular diseases may also be treated with immunosuppressive regimens placing them at risk for opportunistic infections. Long-term corticosteroid therapy can produce lymphopenia and immune dysfunction. The extreme debilitation accompanying malnutrition, drug abuse, and dementia can also reduce immune function, though the infections in these persons are usually bacterial.

Primary immunodeficiency states must be considered in the differential diagnosis of AIDS, particularly in infants and children. Such conditions may include severe combined immunodeficiency (SCID), partial or complete DiGeorge syndrome, Wiskott-Aldrich syndrome, ataxia-telangiectasia, chronic granulomatous disease, and agammaglobulinemia or hypogammaglobulinemia with raised IgM. Common variable immunodeficiency (CVID) may occur at a variety of ages, including young to middle aged adults.

Appropriate laboratory testing, including tests for HIV when indicated, must be employed to distinguish immunodeficiency states. A thorough history and physical examination aids in this process. Immunodeficiency states can be multifactorial in origin. As always, to use the CDC definition for diagnosis of AIDS, it is necessary to determine HIV status with certainty. Without evidence for HIV infection, a search for other causes of immunosuppression should always be done, regardless of the age of the patient. Both inherited as well as acquired immunodeficiency states may occur.

## CHAPTER 3 - OPPORTUNISTIC INFECTIONS IN AIDS

The various infectious agents that are defined by the Centers for Disease Control (CDC) as diagnostic of AIDS when present in persons infected with HIV can produce a host of clinical and pathologic conditions. There may be regional, racial, age, or gender-associated variations in the incidences of opportunistic infections seen with AIDS. Table 5 depicts organ or organ system distribution of AIDS-defining diseases in a large metropolitan public hospital autopsy series. Table 6 indicates the extent of dissemination for those diseases. Table 7 outlines the various treatment modalities.[426]

### PNEUMOCYSTIS JIROVECI INFECTIONS

Prior to the AIDS pandemic, *Pneumocystis jiroveci*, formerly called *P carinii*, was known primarily as an opportunistic pathogen of severely debilitated or immunocompromised persons, including patients on chemotherapy, renal transplant recipients, patients with congenital immune deficiencies, and nutritionally deprived infants. Though still infecting these groups, *P jiroveci* today is most often seen in association with AIDS. Infection with *P jiroveci* is acquired via the respiratory tract and is primarily manifested as a severe pneumonia, called *Pneumocystis jiroveci* pneumonia (PJP). *P jiroveci* was originally classified as a protozoan, but now grouped with fungi based on genetic analysis. It is spread via an airborne route from person to person. Asymptomatic colonization may occur in immunocompetent hosts.[427]

This organism is widely distributed, with variants in many mammalian hosts, but *Pneumocystis* historically has complicated the course of AIDS more often in North America and Europe than in Africa and Asia. However, the numbers of cases of PJP in developed nations are dropping due to prophylaxis and antiretroviral therapy, while cases in developing nations are increasing, particularly in conjunction with concomitant *Mycobacterium tuberculosis* infection. When chemoprophylaxis for *Pneumocystis* is available along with antiretroviral therapy, then the number of cases of *Pneumocystis* pneumonia is low. When HIV-infected persons fail to receive such therapies, or are lost to follow up, then it is more likely that they will die from *Pneumocystis* pneumonia, as the mortality rate for persons hospitalized with this illness has not appreciably diminished.[428,429]

Serologic evidence suggests that most humans have become exposed to *P jiroveci* by age 2. However, there are no defined clinical syndromes for *P jiroveci* infection in immunocompetent persons. Molecular typing has identified over 50 different variants of *P jiroveci* (*carinii*). Most of the variations occur in the internal transcribed spacer (ITS) regions 1 and 2 of the nuclear rRNA operon. Analysis of these genotypes reveals that patients may become reinfected with new genotypes, or that a different genotype of the organism may be detected during a single episode of pneumonia. However, the clinical severity of infection is not affected by genotype.[430] Immunocompromised persons who develop PJP probably have reinfection rather than reactivation of prior infection.[431]

*P jiroveci* is a one-celled organism with a life cycle similar to that of protozoa such as *Toxoplasma gondii*. Ultrastructurally, *P jiroveci* organisms lack a complex organelle system but contain intracystic bodies, which is typical of protozoa. However, both argyrophilia of the *P jiroveci* cyst walls as well as ribosomal RNA sequence studies indicate that *P jiroveci* is a fungal organism most closely related to *Saccharomyces*. There is not as yet a routine culture method

available for this organism outside of research laboratories. Serologic testing is not often useful, for most people have some detectable antibodies. Diagnosis is routinely made histopathologically or through molecular analysis by obtaining tissue or cytologic specimens from the lung.[432,433]

Mature cyst forms of *P jiroveci* contain up to eight sporozoites. When the cysts rupture, the released sporozoites mature into trophozoites and repeat the cycle. In tissue sections, the cysts are identified by cell wall stains such as Gomori methenamine silver (GMS), cresyl violet, or toluidine blue. Gomori methenamine silver staining gives the best contrast for screening of a tissue section or cytologic smear because the red cell-sized *P jiroveci* organisms have a dark brown-black color. The 5 to 7 micron cysts usually occur in cohesive clusters. They are round to elliptical in shape with sharp but sometimes slightly folded edges resembling crushed ping-pong balls. Folding or rupture produces crescentic (parenthesis-shaped) or cup-shaped forms. The lightly stained folds of the *P jiroveci* cell membranes may appear as a central dark dot. Endothelial cell nuclei, in contrast, have a granular to stippled appearance. Red blood cells may be concave, folded, or crescentic, but they are smaller, do not typically appear clustered in alveoli, and have no central dot. Precipitated stains yield artifacts that are variably sized, have angular borders and are distributed haphazardly throughout the slide with no regard for tissue structures. [432]

The *P jiroveci* organisms are typically found within a foamy to granular pink exudate within alveoli. This foamy exudate is seen by electron microscopy to be composed of cysts and trophozoites with little or no fibrin. The organisms appear to be held together by slender membranotubular extensions growing from their surfaces. The uneven contours of the organisms lead to the formation of voids that contribute to the characteristic light microscopic appearance of the foamy exudate. *P jiroveci* cysts have a characteristic folded or crescentic appearance.[432]

The GMS stain is most frequently used for light microscopic diagnosis of *Pneumocystis jiroveci* (*carinii*). There are a variety of methods published for the performance of this stain, and some of them employ a microwave oven or pre-treatment with oxidizers to reduce the time needed for completion to under 20 minutes and improve recognition of organisms.[434,435] Regardless of which method is chosen, it is crucial that this stain be performed as consistently as possible to avoid both false positive and false negative diagnoses.

False negative methenamine silver stains result from under stained preparations in which the *P jiroveci* cysts are too faint to be recognized. Over-staining results in false negative results if there is so much black staining precipitate on the slide that it obscures the organisms. False positive preparations come from over staining so that red blood cells, endothelial cell nuclei, or precipitated stain that appear the same overall size and shape as *Pneumocystis* organisms are misinterpreted.[436]

Several methods are available in addition to GMS staining for identification of *P jiroveci* in smears. Giemsa or Diff-Quik staining identifies the small, delicate intracystic bodies, or sporozoites (up to 8), under oil immersion (1000X) arranged in a clock face to haphazard distribution within the cyst and appearing as 1 to 2 micron dark blue dots. Giemsa or Diff-Quik stains cannot demonstrate the organism's cell wall, so contrast is poor, limiting this technique primarily to cytologic material obtained from bronchoalveolar lavage or sputum specimens. This method is preferred by some pathologists because the appearance is quite characteristic, giving a high specificity, and the method is simple and quick.[437]

The calcofluor white stain can also be utilized to detect cysts of *P jiroveci* in pulmonary specimens.[439] With calcofluor white, a chemofluorescent stain, cysts of *P jiroveci* will appear under fluorescence microscopy with light peripheral staining along with a double-parenthesis-like structure near the center of the cysts.[438] The sensitivity of this stain is as good as GMS for detection of *P jiroveci* cysts.[438]

Both the direct fluorescence antibody (DFA) and immunohistochemical stains, as well as the polymerase chain reaction (PCR), are available for diagnosis of *Pneumocystis*. The direct fluorescent antibody (DFA) stains available for diagnosis of *Pneumocystis* in cytologic specimens are usually obtained from induced sputum or bronchoalveolar lavage. Sensitivity with the DFA technique is good, but specificity requires skill in interpretation.[439]

PCR may be performed on a variety of lower and upper respiratory tract specimens including bronchoalveolar lavage, sputum, and nasopharyngeal aspirates. In children, nasopharyngeal aspirates may be easier to obtain than lower respiratory tract specimens. The sensitivity of PCR for *P jiroveci* has is nearly 100% along with high specificity.[440] The use of PCR on specimens obtained without the need for bronchoscopy can be a cost effective way to provide a diagnosis of PJP.[441]

Fluorescence microscopy may aid in screening of Papanicolaou stained organisms that will demonstrate a bright yellow autofluorescence (from the eosin component of the stain) of the *P jiroveci* cell wall. Immunofluorescence procedures are not technically difficult and allow diagnosis in less than 1 hour.[442]

All of these methods can be highly sensitive and specific when performed routinely. Immunohistochemical staining is slightly more sensitive than GMS stains in tissues and fluids.[443] The DFA is more sensitive than the calcofluor white method in cytologic preparations.[439] The Diff-Quik and DFA are the most cost-effective.[444]

Serum markers have been sought for diagnosis of PJP. Beta-D-glucan (BDG) is the major fungal cell wall component and has a diagnostic sensitivity near 100% and specificity of 88% for PJP in HIV infection. BDG has also been used as a serologic marker for the diagnosis of candidiasis and aspergillosis. KL-6 antigen is a high-molecular-weight mucin-like glycoprotein antigen that is strongly expressed on type 2 alveolar pneumocytes and bronchiolar epithelial cells. KL-6 elevation has a sensitivity of 88% and specificity of 63% for PJP with HIV. Both of these tests do not perform as well for PJP detection when the patients do not have HIV infection.[445]

The clinical, gross, and microscopic appearances of *P jiroveci* pneumonia (PJP) are described fully in the section on respiratory tract pathology. Dissemination of *Pneumocystis* outside of the lungs is uncommon (less than 5% of cases). The use of aerosolized pentamidine isethionate, without systemic therapy, as a prophylaxis against *Pneumocystis* pneumonia has been suggested as a possible etiologic factor for this phenomenon. Only hilar lymph nodes, or another single organ, may be involved, while in rare cases multiple organs are affected (Table 5).[446]

The extrapulmonary microscopic appearance of *Pneumocystis* is often similar to that of the alveoli, with a foamy to granular pink exudate on hematoxylin-eosin stain. However, in widely disseminated cases, *P jiroveci* can produce numerous small 0.1 to 0.3 cm calcified granulomas that give cut surfaces of parenchymal organs the gross appearance of rough sandpaper. These calcifications can demonstrate a stippled appearance on roentgenography, as in the pointillist style of painting. In the spleen, multiple nonenhancing, low-density masses with necrosis, hemorrhage, or peripheral to punctate calcification may be seen with computed



tomographic scans. Ultrasound may reveal small echogenic foci in liver parenchyma. Microscopically, foamy to granular pink exudate may be present with extensive calcium deposition. *P. jiroveci* may coexist with other infectious agents, particularly mycobacteria, at disseminated sites. A Gomori methenamine silver stain reveals the organisms, even in densely calcified areas, but immunoperoxidase staining with monoclonal antibody to *P. jiroveci* can be helpful when cysts are not readily identified.[446,447]

Survival in persons with AIDS has been markedly increased through prophylaxis for PJP, primarily through use of trimethoprim-sulfamethoxazole (TMP-SMX), dapsone, or aerosolized pentamidine. Antipneumocystis medication is recommended for AIDS patients with CD4 lymphocyte counts  $<200/\mu\text{L}$ . Patients who receive antiretroviral therapy and who have a CD4 count that remains above  $200/\mu\text{L}$  for more than 3 months can safely discontinue PJP prophylaxis.[334] Pyrimethamine-sulfadoxine has also been used for PJP prophylaxis. Adverse drug reactions (skin rash, fever, leukopenia, hepatitis) occur in half of patients taking TMP-SMX, and may necessitate an alternative therapy, but the other agents are also associated with adverse reactions.[223] Patients with access to routine medical care may have multiple episodes of PJP diagnosed and treated successfully over months to years. However, patients with AIDS may still succumb to PJP in their terminal course.[448]

There is evidence that some *P. jiroveci* strains are developing resistance to sulfa drugs. This is mediated via mutations in the dihydropteroate synthase (DHPS) gene. Resistance is more commonly demonstrated in persons who have been receiving PJP prophylaxis. In the early 21<sup>st</sup> century, however, drug regimens still remain effective.[431]

## CYTOMEGALOVIRUS INFECTIONS

Cytomegalovirus (CMV) is a very frequent infection complicating AIDS. The seroprevalence of CMV is very high in patients infected with HIV. Venereal transmission appears to be the most common route of infection in adults, though CMV can also be spread through genital secretions, oropharyngeal sections, urine, breast milk, and blood. Asymptomatic persons who have primary infection or reactivation of latent infection can shed virus. Most patients with AIDS who develop clinical signs and symptoms of CMV infection probably have reactivation of previous infection rather than primary infection.[449]

CMV is the most widely distributed opportunistic agent seen with AIDS and, unlike *Pneumocystis jiroveci* (*carinii*), which nearly always involves only the lung, CMV can and does involve many organs. The most clinically significant sites of involvement are lung, gastrointestinal tract, brain, and eye. In a large autopsy series, CMV occurred most frequently in adrenal and respiratory tract, followed by the gastrointestinal tract, central nervous system, and eye, infrequently in spleen and genitourinary tract, and rarely in lymph node, skin, liver, bone marrow, or heart (Table 5).[449]

The diagnosis of CMV retinopathy, one of the most clinically debilitating complications of CMV infection, is made on fundoscopic examination because of the inability to obtain tissue from this site. Many patients with CMV retinopathy develop partial or complete blindness. Additional clinical manifestations of CMV infection can include altered mental status, pneumonitis with non-productive cough, colitis or esophagitis with or without gastrointestinal hemorrhage, adrenal insufficiency, hepatitis, or radiculitis.

Cytomegalovirus can be detected through culture of blood, fluids, or tissues containing the virus, but culture methods are expensive and time consuming, and the presence of CMV does not always correlate with infection causing disease. Serologic titers are not very useful to detect CMV infection, since at least 30% of persons without immunosuppression also have antibodies to CMV, and the seroprevalence is very high among immunosuppressed persons. Changing titers of antibodies may aid in the detection of response to therapy in some patients with CMV.[449]

Examination of tissue biopsies obtained from pulmonary or gastrointestinal endoscopy by routine light microscopy is often the simplest means for the diagnosis of CMV, but sensitivity is decreased by sampling error, for diagnostic inclusions can be widely scattered or infrequent. Immunofluorescent antibody staining of tissues may aid diagnostic screening in some cases. Techniques to detect cytomegaloviral DNA by *in situ* hybridization or polymerase chain reaction are more sensitive than light microscopy. The presence of CMV in bronchoalveolar lavage or sputum specimens does not necessarily indicate a clinically important infection. At autopsy, diagnosis is most often made histologically by finding characteristic CMV inclusions in the adrenal gland or lung (Table 5).[450]

Cytomegalovirus is a DNA virus of the herpesvirus group. It produces an enlargement of the infected cell, and microscopically with hematoxylin-eosin staining, a large 5 to 15 micron sized violaceous to dark red intranuclear inclusion surrounded by a thin clear halo can be seen. The nucleus of the infected cell is usually eccentrically positioned. More than one inclusion body may be present. Additionally, the cytoplasm of infected cells may contain coarse dark basophilic bodies 2 to 3 microns in size representing replication of virions in the cytoplasm. The cell border is not prominent. In tissue sections the cytomegalic cells are large and distinctive (30

to 100 microns) with rounded to oblong shapes. The plane of sectioning may not always reveal the intranuclear inclusion completely, so the finding of large cells alone should prompt a careful search for diagnostic inclusions elsewhere. Vascular endothelium, epithelial surfaces, adrenal medulla, and cortex near ependymal or meningeal surfaces of the brain are particularly good places to look for inclusions.

The tissue responses to CMV are quite varied. Often when there are infrequent and/or widely scattered inclusions, there is little appreciable inflammatory reaction accompanying the inclusions. In these cases, the presence of CMV may not be associated with clinical disease. In other cases, the cytomegalic cells are accompanied by the presence of small focal areas of inflammation, hemorrhage, or necrosis. In a few cases, there are large numbers of inclusions and the surrounding tissues are markedly inflamed, hemorrhagic, or necrotic. The inflammation can range from clusters of small lymphocytes to mixed infiltrates with lymphocytes and neutrophils to diffuse neutrophilic infiltrates. A granulomatous response is not seen and calcification does not occur.[450] In persons starting antiretroviral therapy (ART) there can be an immune restoration syndrome (IRS) marked by more florid inflammation, including an immune recovery uveitis with CMV infection.[310]

Cytomegalovirus-infected cells must be distinguished from macrophages and ganglion cells, which may also be large, have prominent nucleoli, and have basophilic stippling of the cytoplasm. Nucleoli of such cells are smaller and basophilic stippling is finer than in cytomegalic cells. *Toxoplasma gondii* pseudocysts have bradyzoites that resemble the basophilic inclusions of CMV, but the pseudocyst wall is thicker than the CMV cell membrane and the basophilic inclusions of CMV are coarser and more variable than bradyzoites. Both in situ hybridization and immunoperoxidase methods are useful for detection of cytomegalovirus, particularly when classic intranuclear inclusions are not present.[451]

Cytomegalovirus infection is the immediate cause of death in only 10% of AIDS cases overall and in 20% of cases in which CMV infection is present at autopsy. Usually, CMV is an indolent infection. Deaths from CMV infection result from pulmonary involvement in two thirds of cases, central nervous system involvement in one fourth, and gastrointestinal tract involvement in one eighth. Despite the high number of cases with adrenal involvement, death from adrenal failure is rare.[450]

Ganciclovir (9-[1,3-dihydroxy-2-propoxymethyl] guanine, abbreviated DHPG), the first drug of choice, and Foscavir (foscarnet, trisodium phosphonoformate) have been used to treat patients with CMV, particularly those with retinitis. Another agent is cidofovir, a nucleoside analogue of cytosine with potent activity against herpesviruses. Ganciclovir, foscarnet, or valganciclovir may provide symptomatic relief in AIDS patients with CMV, and the infection is often slowed or tissue destruction diminished and survival is increased. Prophylaxis with ganciclovir or cidofovir may be used in selected patients. In treated patients who later die, residual CMV infection can usually be found at autopsy in one or more organ sites.[223,450,223,452]

## MYCOBACTERIAL INFECTIONS

**MYCOBACTERIUM AVIUM COMPLEX.**-- *Mycobacterium avium* complex (MAC), also known as *Mycobacterium avium-intracellulare* (MAI), is considered a non-pathogen in non-immunocompromised persons. This complex can be further sub classified, but the clinical and pathologic findings are similar in AIDS, so that it remains useful to refer to these organisms collectively as MAC. Patients probably become colonized with MAC via the gastrointestinal or respiratory tract. The MAC organisms can penetrate the gastrointestinal mucosa and are taken up into submucosal macrophages. These macrophages are then transported to abdominal lymph nodes and from there to the bloodstream. Cases of MAC in immunocompromised persons probably represent reinfection rather than reactivation of prior infection.[453]

The risk for disseminated disease with MAC is increased with CD4 lymphocyte counts below 100/ $\mu$ L. Infections with MAC are common in persons with AIDS. The organ distribution of MAC is widespread, with lymph nodes, spleen and liver most frequent organs involved. Involvement of the gastrointestinal tract, bone marrow, respiratory tract, adrenal, or genitourinary tract is less frequent. *Mycobacterium avium* complex is rarely seen in the central nervous system, skin, and heart (Table 5).[454,455]

Clinical manifestations are primarily the result of cytokine elaboration. Typical features of MAC infection include persistent fever, night sweats, and anemia in about 80% of patients, diarrhea in about half, and weight loss, lymphadenopathy, abdominal pain, and nausea/vomiting in about one third of patients. *Mycobacterium avium* complex is unlikely to be an acute life-threatening infection, is often not suspected pre mortem, and most patients have a protracted course or die from another disease first. Though the number of AIDS patients with MAC is increasing with longer survival, the number of deaths from MAC has decreased significantly with the use of newer antimicrobial therapies.[448]

Blood culture is the best laboratory means of diagnosis of MAC, particularly when disseminated MAC infection is suspected.[456] Bone marrow or lymph node tissues may be cultured. The best tissue biopsy sites for histologic diagnosis of MAC are lymph node and liver. The diffuse organ involvement of MAC helps to minimize the sampling error with biopsy.[454,455]

*Mycobacterium avium* complex does not often produce typical grossly visible granulomas with one exception--the spleen. A classic miliary pattern of granulomas is present in spleen in about half of AIDS cases with MAC. Another distinctive gross pathologic finding with MAC is a tan-yellow to lemon-yellow cut surface of involved lymph nodes in one fourth of cases. MAC involvement of the gastrointestinal mucosa may produce diffuse or slightly raised plaque-like areas of yellowish discoloration. Visceral organomegaly, especially of liver and spleen, may result from MAC infection even though there are often no grossly visible lesions.[455]

Microscopically, MAC most often demonstrates a proliferation of small nests to extensive sheets of large round to elliptical striated pale blue macrophages (histiocytes) on hematoxylin-eosin stain. These macrophages can be up to 50 microns in size. The small, round to oval nuclei of these cells are often obscured by the sheer numbers of mycobacteria. The cell borders can also be indistinct because of many mycobacteria scattered in and around the cells. The cytoplasm of these cells is teeming with mycobacteria that can not only be identified by acid fast stain, but also by methenamine silver, PAS, Giemsa, or Brown-Hopps tissue gram stain. The

large numbers of closely packed mycobacteria produce the striated appearance with hematoxylin-eosin staining.[454]

The large macrophages are usually not accompanied by a typical granulomatous cellular reaction. There may be occasional lymphocytes and epithelioid cells, but Langhans giant cells, fibrosis, calcification, and caseous necrosis are quite uncommon. Rarely, the macrophages may take on a spindle shape and form a mass lesion, typically in lymph nodes, known as a mycobacterial "pseudotumor".[457] In many organs, the poorly formed MAC "granulomas" consist only of single or small groups of macrophages that cannot be seen grossly and may not be noticed until special stains are performed. Significant necrosis of surrounding tissues is uncommon.[453]

Acid-fast bacilli (AFB) staining along with culture remains the standard procedure for detection of MAC. The AFB stains commonly employed include the Ziehl-Neelsen and Kinyoun carbolfuchsin methods. On acid fast staining, MAC organisms are not completely distinctive from other mycobacteria, though they tend to be shorter than *M tuberculosis* and they tend to be numerous. Culture is necessary for definitive identification. Diagnosis at autopsy is aided by sampling several lymph node sites and by culture of enlarged nodes.[454]

Though MAC is often widespread throughout the body, few MAC-infected AIDS patients die from this disease.[448] Organ failure from MAC leading to the immediate cause of death most likely results from pulmonary involvement. Prophylaxis for MAC in both adults and children with either azithromycin or clarithromycin may be considered when the CD4 lymphocyte count is  $<50/\mu\text{L}$ , though persons with active tuberculosis should be excluded because of development of resistance to rifampin from treatment with rifabutin.[223]

In persons receiving antiretroviral therapy (ART) immune restoration disease (IRD) with atypical features of MAC infection can occur. IRD with vigorous delayed-type hypersensitivity, rather than anergy, results in more localized, rather than disseminated, disease. Lesions can include lymphadenitis, pulmonary infiltrates or masses, pyomyositis, and subcutaneous abscessing inflammation. Granulomatous to suppurative inflammatory responses are present. Lesions may produce pain.[310]

Drug therapy for MAC infection may include clarithromycin, azithromycin, or rifabutin and is most effective when combined with a second agent such as ethambutol, but a clinical response may take two to eight weeks (Table 7). Combination drug therapy with additional agents such as ciprofloxacin, clofazimine, amikacin, and rifampin show some effectiveness in cases with more severe symptoms. AIDS patients infected with MAC require life-long treatment. Resolution of mycobacteremia occurs more frequently and more rapidly with a three-drug regimen of rifabutin, ethambutol, and clarithromycin. Rifabutin is also useful for prophylaxis in patients with CD4 lymphocyte counts  $<100/\mu\text{L}$ . Many patients can still survive for months with disseminated disease.[223,454,455,458]

**MYCOBACTERIUM TUBERCULOSIS (MTB).**—MTB occurs commonly in many persons without AIDS, but the risk for MTB is substantially higher in persons infected with HIV. A third of HIV-infected persons are also infected with MTB. The relative risk for tuberculosis in persons with HIV infection is more than 20 to 37-fold that of the general population, and patients dually infected with HIV and latent MTB progress to active tuberculosis at greater rate.[459,460] Definitional criteria for AIDS require laboratory evidence for HIV infection for inclusion of MTB as a disease diagnostic of AIDS.[421] MTB is one of the most common causes of death in patients with AIDS in Africa.[428]

The incidence of tuberculosis among persons infected with HIV in the U.S. is increased when the CD4 lymphocyte count is less than 200/ $\mu$ L. Persons already tuberculin (PPD) positive at first testing during the course of HIV infection are much less likely to get tuberculosis than HIV-infected persons who convert to a positive PPD. HIV infection is the greatest known risk factor for progression from latent tuberculosis to active tuberculosis. In the U.S., after tuberculosis exposure and infection, HIV-infected persons who do not receive appropriate treatment progress to active tuberculosis over 5 years at a rate 10 times greater than that for persons not infected with HIV. HIV-infected persons who have negativity to mumps antigen by skin testing also have an increased risk for tuberculosis.[461]

Worldwide, prevalence of tuberculosis with HIV parallels prevalence of HIV and lack of health care resources. In 2008, there were 9.4 million new cases of TB and 1.78 million deaths from TB worldwide; of these, 1.4 million cases (15%) occurred in HIV-infected individuals, resulting in 0.5 million deaths (28% of total deaths from TB). Africa, and Southern Africa in particular, and Southeast Asia, particularly India, have the highest prevalence.[462]

The incidence of MTB as well as the number of deaths from MTB began increasing in the United States in the mid-1980's, in part due to the AIDS pandemic, but leveled off and decreased in the 1990's.[459,460] Accompanying this increase in MTB was the emergence in the 1990's of MTB strains exhibiting multiple drug resistance (MDR). Emergence of multidrug-resistant TB (MDR-TB) may be a function of inadequate control from poor surveillance, delayed diagnosis, inappropriate drug taking by patients, or inappropriate drug prescribing by physicians.[463] There is a continuing small but significant increased risk for MDR-TB in HIV-infected persons, particularly those with primary MTB infection. Persons with HIV infection tend to have more rapid disease progression with MDR-TB.[464] In the 21<sup>st</sup> century, there has been a further increase in MTB resistance, termed extensively drug-resistant TB (XDR-TB). The extent of this resistance encompasses both rifampin and isoniazid, as well as any fluoroquinolone and any of the injectable agents including amikacin, kanamycin, or capreomycin.[465]

The clinical presentation is similar to non-resistant strains, though the chest roentgenographic appearance is more often an alveolar infiltrate, and cavitation is more frequent than with non-resistant MTB. These resistant strains are also likely to result in pathologic lesions with poor granuloma formation, extensive necrosis, neutrophilic inflammation, and numerous acid-fast bacilli.[466] There is a higher fatality rate in persons with HIV infection. The Beijing genotype family of M tuberculosis organisms is associated with the greatest drug resistance.[467]

Active MTB infection in patients with AIDS probably results from reactivation of previous infection rather than primary infection. The incidence of clinically apparent MTB infection is highest in HIV-infected persons in the first months after beginning antiretroviral therapy, probably from immune restoration that unmasks a subclinical inflammatory response. Despite immunosuppression, pulmonary involvement by MTB in AIDS is still far more common than extrapulmonary spread. Not all AIDS patients have reactivation of prior MTB infection, because isolated fibrotic or calcified granulomas without evidence for active granulomatous disease can be found in some AIDS cases at autopsy.[468] Persons with HIV can have latent MTB infection, and the rate of progression to active tuberculosis disease is estimated to be 5 to 8% per year, compared with a 10% lifetime risk in the general population. HIV is also associated with higher rates of extrapulmonary and disseminated MTB.[462]

The risk for developing active MTB infection is greatest in the first 90 days following initiation of antiretroviral therapy. The incidence of MTB is highest for persons with greater immunosuppression upon starting antiretroviral therapy, particularly with CD4 lymphocyte counts below 50/ $\mu$ L. Additional risk factors include anemia and poor nutritional status.[467]

MTB infection may be more likely to occur in association with HIV infection through alterations in alveolar macrophage function. The macrophages in asymptomatic HIV-infected persons show increased phagocytosis of mycobacteria along with decreased release of cytokines and chemokines, and impaired phagosome maturation. There is also decreased apoptosis of alveolar macrophage in response to mycobacteria, reducing clearance of the organisms. Lung levels of IL-10 can be increased, leading to upregulation of the apoptosis inhibitor BCL3. When HIV infects macrophages, autophagy is inhibited, along with intracellular killing of mycobacteria.[462]

Unlike MAC, though, striated macrophages are not a common feature with multiple drug resistant MTB. Patients with multiple drug resistant MTB have extrapulmonary dissemination in a third of cases, and their survival from the time of diagnosis is two months or less. Despite therapy with multiple agents, most patients will continue to have intermittently or persistently positive sputum cultures, indicating that such resistant MTB pose a considerable risk to other patients and to health care workers.[147]

Yearly skin test screening with 5 TU of purified protein derivative (PPD) is recommended in previously PPD-negative persons. Only 10% of persons with a CD4 lymphocyte count >500/ $\mu$ L are likely to exhibit anergy, though a positive test in HIV-infected persons should be defined as any area of induration >0.5 cm (or >0.2 cm for injection drug users). Anergy may be detected by companion testing with *Candida*, mumps, or tetanus toxoid skin tests. Patients suspected of having tuberculosis should be evaluated further with a chest roentgenogram and have at least three sputum specimens collected to detect acid-fast bacilli.[223]

Rapid whole-blood tests have been developed that employ an ELISA or enzyme-linked immunosorbent spot assay to measure the interferon-gamma (IFN-gamma) release of sensitized T lymphocytes in response to previously encountered mycobacterial antigens. Such tests have shown cross-reactivity to *Mycobacterium marinum* and to *Mycobacterium kansasii* but not to *Mycobacterium avium*-complex or to bacille Calmette-Guérin (BCG). The sensitivity for active tuberculosis in HIV-infected persons has been reported as 91%.[469] IFN-gamma release assays do not help to distinguish latent from active TB.[462]

Mycobacterial infections can also be detected with tissues or cytologic material obtained via bronchoalveolar lavage, transbronchial biopsy, and fine needle aspiration. Acid-fast bacilli (AFB) staining along with culture remains the standard procedure for detection of MTB. The AFB stains commonly employed include the Ziehl-Neelsen and Kinyoun carbolfuchsin methods. False positive results can occur when the carbolfuchsin stain precipitates on short segments of cellular debris. Interpret as acid-fast bacilli only those structures that are uniformly and evenly stained throughout their length. Some morphologic variability exists among different species of mycobacteria. False negative results can be avoided by searching the slide carefully for many minutes. Using a positive control that does not have numerous organisms will help to avoid under staining and give an indication of how difficult the search can be.

Liquid culture is more sensitive and rapid than MTB culture on solid media. Culture requires a greater incubation time compared with that for non-HIV-infected patients, consistent with lower bacillary load of sputum specimens. Urine detection of the mycobacterial cell wall

component lipoarabinomannan may improve detection in smear-negative HIV-infected patients with advanced immunosuppression.[462]

The polymerase chain reaction (PCR) to mycobacterial DNA can be performed in selected cases. If disseminated tuberculosis is suspected, then cytologic or histologic material obtained from extrapulmonary sites should also be cultured for MTB.[223,460] Rapid, but expensive, tests for detection of MTB are available that are based upon the detection of DNA or ribosomal RNA from MTB organisms. These rapid tests yield results in less than a day, but do not replace acid fast staining, which can provide an index of contagiousness, or mycobacterial culture, which indicates drug susceptibility.[459]

Acid-fast smear microscopy is less frequently positive in patients infected with HIV and MTB. In people infected with HIV, a third sputum smear does not improve the diagnostic yield for MTB. Broth-based culture of three sputum specimens diagnoses most pulmonary MTB cases. Broth-based culture of sputum identified substantially more cases than microscopy or solid media culture. A single sputum cultured on broth yields as many positive results as three sputum samples cultured on solid media. Lymph node aspiration provides the highest incremental yield of any non-pulmonary specimen test for MTB.[470]

Microscopic detection of MTB is aided by fluorescence microscopy. The use of an auramine fluorescent stain for mycobacteria requires a microscope with fluorescence attachment. Newer epifluorescent microscopes are easier to set up and use. Most new fluorescence units employ filters that pass fluorescent light that only provides visualization for the auramine component of the stain, in contrast to the wide band filters of older units. The fluorescent stain is more sensitive than acid fast stains by light microscopy. False positive results can be avoided by careful interpretation.[462]

In persons converting to a positive skin test, a 12-month course of isoniazid is recommended, with use of rifampin for patients unable to tolerate isoniazid. HIV-infected persons who are close contacts of persons infected with tuberculosis may begin to receive prophylactic therapy, and a decision to continue therapy can be made after skin testing and follow up. For patients with newly diagnosed tuberculosis, a four-drug regimen consisting of isoniazid, rifampin, pyrazinamide, and either streptomycin or ethambutol is recommended, with therapy lasting at least 9 months (at least 6 months after sputum cultures are negative). For patients exposed to multiple-drug resistant MTB, therapy for 12 months with high dose ethambutol with pyrazinamide and ciprofloxacin is recommended. [223,460,463] The use of bacille Calmette-Guérin (BCG) vaccine in patients with HIV infection may not be recommended because of the risk for disseminated disease.[471]

The organ distribution of MTB in AIDS is widespread. Extrapulmonary MTB is found in 70% of patients with a CD4 lymphocyte count less than 100/ $\mu$ L and in 28% of those with a CD4 lymphocyte count greater than 300/ $\mu$ L. At autopsy, the respiratory tract is involved most frequently, followed by spleen, lymph node, liver and genitourinary tract. Bone marrow, gastrointestinal tract, and adrenal are less common sites of involvement. *Mycobacterium tuberculosis* is uncommonly identified in central nervous system, heart, and skin (Table 5).[448,460]

The clinical presentation of MTB in AIDS can resemble that of non-AIDS patients, and MTB can often be the first AIDS-defining illness, particularly in regions where the incidence of MTB is high in the general population. Tuberculosis should be suspected in patients with fever, cough, night sweats, and weight loss, regardless of chest roentgenogram findings. In patients with residual immune function, with a CD4 count >200/ $\mu$ L, MTB resembles reactivation



tuberculosis, with cavitation and upper lobe infiltrates on chest roentgenography, and tuberculin skin tests are often positive. With severe immunosuppression and CD4 counts below  $200/\mu\text{L}$ , hilar adenopathy, pleural effusions, lack of cavitation or consolidation but presence of a miliary pattern more typical of primary MTB infection appear.[459,472]

Tuberculin skin tests may be falsely negative. Pulmonary symptoms can also include hemoptysis, chest pain, and dyspnea. Differentiation from *P. jiroveci* or fungal infection can be difficult, but both sputum and blood cultures are useful for diagnosis. Extrapulmonary MTB often produces fever, weight loss, and lymphadenopathy, and the yield from lymph node aspiration biopsy is high.[459,460] Clinical features that help to distinguish disseminated MTB infections from disseminated *Mycobacterium avium* complex (MAC) infections include night sweats, extra-inguinal lymphadenopathy, acid fast bacilli in sputum smears, hilar enlargement on chest radiograph, miliary lesions, and pleural effusions. Hepatosplenomegaly, elevated serum alkaline phosphatase (twice normal), and leukopenia are more likely to suggest disseminated MAC.[473]

Grossly, MTB produces recognizable discrete tan to white, firm granulomas in most involved organs. Unlike MAC, the lesions will not show bright yellow coloration. Most of the granulomas are 0.1 to 0.5 cm, but larger granulomas can occur and demonstrate central caseation. Large cavitory lesions with AIDS are not common. A classic miliary pattern is not seen frequently because the granulomas of MTB in AIDS tend to be more variably sized and more widely scattered in distribution. A pneumonic pattern may occasionally be seen.

The microscopic appearance of MTB with AIDS can be typical of that seen in MTB infecting non-AIDS patients. The granulomas contain epithelioid cells, Langhans giant cells, lymphocytes, and fibroblasts with central caseation. In many cases, the inflammatory response is poor and the granulomas are ill defined, particularly in advanced AIDS. Acid-fast stains show variable numbers of mycobacteria, but usually there are more mycobacteria than are seen in non-AIDS patients. In some cases with few or small granulomas, mycobacteria are not numerous; in other cases with many larger caseating granulomas, they may be abundant. Large macrophages filled with mycobacteria similar to those seen in MAC are quite uncommon in MTB.[474]

Disseminated MTB infection is more likely to occur in HIV-infected persons with prior mycobacterial infection, ineffective cell-mediated immune response, and low CD4 lymphocyte counts, typically  $<75/\mu\text{L}$ . There may be concurrence of both reactivation and reinfection. Pulmonary disease may not be prominent and sputum smears may be negative for acid fast bacilli. However, 20 to 25% of patients may have mycobacteremia.[475] The mortality rate is high, with a third of co-infected persons dying from MTB.[7]

Persons on active MTB therapy starting antiretroviral therapy (ART) can develop immune restoration inflammatory syndrome (IRIS) with a vigorous delayed-type hypersensitivity reaction and more pronounced granulomatous inflammation from mycobacterial infection. There may be thoracic lymphadenitis in addition to active pulmonary disease. Extrathoracic disease, however, is unlikely to occur with IRD.[310] Risk factors for IRIS are disseminated MTB, low CD4 count and shorter interval from start of MTB therapy to beginning antiretroviral therapy. IRIS with MTB typically last 2 to 3 months.[476]

Persons with HIV infection and MTB are more likely to develop adverse antitubercular drug reactions and antitubercular drug resistance. Death from MTB is more common than with MAC from both an increase in the numbers of infections and death rate from infection. The rise in multiple drug resistant (MDR) strains of MTB has played a role in this increasing death rate.[459,466,476] Worldwide, about 5% of tuberculosis cases are MDR and it is likely half of

those occur in HIV-infected persons. The incidence of tuberculosis declines with the use of antiretroviral therapy.[462]

Treatment of mycobacterial illness in conjunction with HIV infection may require special consideration for use of drugs. Drug interactions between antiretrovirals and antituberculars are common because of induction or inhibition of hepatic enzymes cytochrome P450 (CYP450). The isoform CYP3A4 is primarily responsible for the metabolism of protease inhibitors (PI) and non-nucleoside reverse transcriptase inhibitor (NNRTI). Rifampicin is a potent inducer of CYP3A4.[476]

In general, for untreated patients, MTB therapy is initiated first. If both illnesses are treated simultaneously, then recommended regimens include use of the antiretroviral efavirenz with 2 nucleoside reverse transcriptase inhibitors plus 4 MTB drugs (isoniazid, rifampin, ethambutol, pyrazinamide) or a ritonavir-boosted protease inhibitor with 2 nucleoside reverse transcriptase inhibitors along with the MTB drugs (but rifabutin is substituted for rifampin). For atypical mycobacterial infection with HIV, the antimycobacterials employed along with antiretrovirals are rifabutin, clarithromycin, and ethambutol.[307]

At autopsy, about one third of AIDS patients with MTB are found to have succumbed to this infection, usually from extensive pulmonary involvement.[448] Prophylaxis against MTB infection can be considered for patients with a positive tuberculin skin test (induration >5 mm) who have never been treated for tuberculosis, and for patients with recent exposure to someone with active tuberculosis. Isoniazid plus pyridoxine, or rifampin plus pyrazinamide, administered for 9 months, are the regimens of choice.[223]

**MYCOBACTERIUM FORTUITUM.**-- *Mycobacterium fortuitum* occurs less commonly than either MTB or MAC in AIDS. This organism is widely found in the environment but is an infrequent human pathogen. In culture, *M fortuitum* is a rapid grower. In persons who are immunocompetent, infections of surgical sites, soft tissues, skin, and lung can occur but are typically not life threatening. In immunocompromised persons, *M fortuitum* infections are more disseminated and severe, with multiple skin lesions and deep organ involvement. In persons with HIV infection, *M fortuitum* occurs late in the course, with CD4 counts typically below 100/ $\mu$ L. Cervical lymphadenitis is the most common initial sign. Microscopically, a mixture of granulomatous and acute suppurative inflammation characterizes the lesions. The long, filamentous acid-fast bacilli may not be numerous and may stain poorly with standard special stains such as Ziehl-Neelsen, Kinyoun, or auramine. They may be confused with *Nocardia* species, though *M fortuitum* organisms tend to have shorter, blunter branches that extend at right angles from their origin, compared to *Nocardia*. A response to antibiotic therapy with agents such as amikacin and ciprofloxacin is generally seen.[477]

**MYCOBACTERIUM XENOPI.**-- *Mycobacterium xenopi* is most likely to be a colonizing agent in persons with AIDS in regions where this organism is endemic and considered to be a commensal or environmental contaminant where it can be recovered from water sources. In most cases, it does not require specific antimicrobial therapy.[478] However, in some cases it can cause pneumonia and/or septicemia in persons with AIDS. *M xenopi* infection may be accompanied by cough, chronic fever, and wasting syndrome. Disseminated infections are rare. *M xenopi* demonstrates reduced susceptibility to anti-tuberculous drugs, and the response to treatment is variable.[479]

OTHER MYCOBACTERIA.— As in tuberculosis, nontubercular infections require a  $T_H1$  immune response for effective control and clearance. Key cytokines involved in the immune response include interleukin-12, interferon-gamma, and tumor necrosis factor-alpha. Nontuberculous mycobacteria more likely to produce mainly pulmonary infection include *M xenopi* and *M malmoense*. Disseminated infections of multiple organ sites are more likely to occur with *M haemophilum*, *M marinum*, *M abscessus*, *M chelonae*, *M fortuitum*, and *M genavense*. Skin and soft tissue infections are likely to occur with *M marinum*, *M abscessus*, *M chelonae*, *M fortuitum*, *M mucogenicum*, and *M haemophilum*. [480]

Infections with *Mycobacterium africanum*, *Mycobacterium kansasii*, *Mycobacterium scrofulaceum*, or *Mycobacterium gordonae* are more likely to clinically and pathologically resemble MTB infection than MAC infection. [459,481] The specific diagnosis depends upon culture of tissues or body fluids, but morphologically *M kansasii* organisms have a long, curved or folded, and beaded appearance (barber pole) on acid fast stain. *M avium* complex (MAC) organisms are short, thick, and beaded. *M tuberculosis* organisms are not as thick or beaded as those of MAC. *Mycobacterium scrofulaceum* organisms are very short and delicate. [482]

*Mycobacterium haemophilum* infection produces disseminated lesions, most often as cutaneous lesions or as pulmonary infiltrates or nodules. HIV-infected persons are at risk when CD4 counts are below 100 cells/ $\mu$ L. The skin lesions begin as erythematous papules or nodules that become suppurative, with painful draining ulcers. Cysts, scaly plaques, or focal panniculitis occur less commonly. *M haemophilum* lesions typically occur on the extremities overlying the joints because of enhanced growth of the organisms at lower temperatures, typically 30 to 32 C. The organism is very fastidious and slow growing in culture media. Microscopic examination of tissues can show mixed suppurative and granulomatous inflammation. Other patterns include epithelioid granulomas, ulcerative necrosis, lichenoid dermatitis with granulomas, interface dermatitis, and necrotizing small-vessel vasculitis. Persons with AIDS may have impaired inflammatory responses so that granulomas and acid fast bacilli may not be detectable. Infected patients may respond to antibiotic therapy that may include macrolides and rifamycins. [483]

*Mycobacterium ulcerans* is an environmental, non-communicable agent that causes an indolent, necrotizing skin lesion known as Buruli ulcer (BU). *M. ulcerans* involving skin may spread to underlying bone producing reactive osteitis or osteomyelitis or spread via lymphatics or hematogenously to bone. This infection is most common in children living in West Africa. The risk for BU is increased with HIV infection, which also makes BU more aggressive. [484]

## CRYPTOCOCCUS NEOFORMANS INFECTIONS

Cryptococcosis is a leading cause for fungal disease in persons infected with HIV. There are four serotypes based on the capsular polysaccharide, glucuronoxylomannan (GXM): *C. neoformans* var. *grubii*, *C. neoformans* var. *gattii*, and *C. neoformans* var. *neoformans*. *C. gattii* has been classified as a separate species. The organism *C. neoformans* var. *neoformans* is cosmopolitan, and bird droppings tend to play a major role in its distribution to urban settings. In contrast, *C. neoformans* var. *gattii* tends to occur in tropical and subtropical locations and is found in decaying vegetation, particularly from eucalyptus trees. [485]

Non *neoformans* species of *Cryptococcus* are rarely reported as causes for infection, but can cause disease in immunocompromised hosts, and most cases are due to *Cryptococcus laurentii* and *Cryptococcus albidus*. Other occasional pathogens include *Cryptococcus curvatus*, *Cryptococcus humicolus*, and *Cryptococcus uniguttulatus*. Clinical manifestations resemble those of *C. neoformans* infections. The most common sites of infection are the bloodstream and CNS, followed by pulmonary sites and the skin, eyes, and gastrointestinal tract.[486]

*Cryptococcus* is a basidiomycetous yeast that exists in the environment in the sexual form and produces hyphae with terminal basidiospores (chains of unbudded yeast). When the 3 micron basidiospores break off they become aerosolized and may be inhaled into the alveoli. Less commonly, the portal of entry is the gastrointestinal tract or the skin. An infection is asymptomatic in most persons, but in persons with severe cell-mediated immunodeficiency, the organism may enter the circulation and survive *in vivo* in a haploid, asexual state, leading to disseminated disease. *Cryptococcus* may survive within human because of a polysaccharide capsule that allows it to evade phagocytosis. Capsular polysaccharides include galactoxylomannan as well as glucuronoxylomannan, and they impart resistance to phagocytosis. In addition, a phenol oxidase enzyme uses catecholamines as substrate to produce melanin, which accumulates in the cell wall, and synthesis of catecholamines for neurotransmitters may predispose to involvement of the central nervous system.[485,487]

About 6 to 10% of HIV-infected persons not on prophylactic therapy or antiretroviral therapy have been shown to develop cryptococcal meningitis in developed nations. More than three-fourths of cases occur when the CD4 count is less than 50/ $\mu$ L. Most infections are acquired via the respiratory tract, where the major host defense mechanism is complement-mediated phagocytosis by macrophages, with help from both CD4 and CD8 cells to inhibit proliferation of cryptococcal organisms. Cryptococcosis may represent either primary infection or reactivation of prior infection.[488] Though cryptococcosis is a major complication in adults with advanced HIV infection, cryptococcal infections in children are relatively uncommon, with a frequency of less than 1%.[489]

Involvement of the lung in nearly all cases and the central nervous system in two-thirds of cases by *Cryptococcus neoformans* in AIDS is similar to non-AIDS cases. In cases with dissemination, *C. neoformans* has a wide distribution, appearing in decreasing frequency in: lymph node, spleen, genitourinary tract, liver, adrenal, and bone marrow tissue. Cutaneous dissemination may be seen in about 10% of cases, appearing as molluscum-apparing skin lesions, mainly on the trunk and face. Osseous involvement occurs in approximately 5% of cases. *Cryptococcus neoformans* is infrequently identified in gastrointestinal tract (Table 5).[485,487]

The most common clinical presentation of cryptococcosis is meningitis, seen in two-thirds of infections. The onset and course of cryptococcal meningitis can be rapid and severe, though symptoms may be more insidious and develop over days to weeks. Sometimes only headache and altered mental status are present. One of the best clinical means of diagnosis is examination of cerebrospinal fluid (CSF) obtained from lumbar puncture with an India ink preparation that will highlight the budding nuclei. The CSF cell counts and chemistries can be abnormal, and cryptococcal antigen is positive in 90% of cases when the CSF culture is positive for *C neoformans*.<sup>[490]</sup>

In about a third to half of cryptococcal infections, there is a pneumonitis. Pulmonary involvement is usually seen along with dissemination, though isolated pulmonary disease may be present. Fever, cough, and dyspnea are non-specific manifestations of pulmonary cryptococcosis. Persistent prostatic infection, which is difficult to detect, may serve as a reservoir that is difficult to eradicate.<sup>[490]</sup>

If large numbers of cryptococci with capsules are present, a grossly apparent mucoid exudate may be seen in the cerebral ventricles or on the meningeal surfaces of the central nervous system. Sometimes variably sized pale soft granulomas are grossly visible in the lungs or elsewhere. In a few cases, the granulomas have surrounding hemorrhage. The lungs may show patchy areas of consolidation. In some cases, the only grossly identifiable pathologic change is organomegaly.

Microscopically, *C neoformans* organisms are pale narrow-based budding yeasts that average 2 to 7 microns in size, with a prominent surrounding capsule. With the capsule, the organisms are 5 to 20 microns. The yeast cells appear pale blue and ovoid while the capsule is round and clear with routine hematoxylin-eosin-stained tissue sections or on Papanicolaou-stained cytologic material. Pale or clear areas at low power magnification in examined tissues may be found at high power to contain large numbers of cryptococci. The accompanying scanty inflammation contains a few small, scattered lymphocytes or macrophages with phagocytized organisms.

The capsule, when present, can be stained in tissue sections or cytologic smears with most mucin stains. Gomori methenamine silver (GMS) and PAS stains readily demonstrate the nuclei of the organisms. In many cryptococcal infections with AIDS, there are present only very poorly or non-encapsulated cryptococci. The presence of these poorly encapsulated forms may explain the paucity of gross pathologic findings. This appearance is similar to subcultures of cryptococci on growth media in the laboratory. Such capsule-deficient forms may be difficult to distinguish from *Candida* and *Histoplasma capsulatum*. The cellular pleomorphism of *Cryptococcus*, larger cell size, and lack of pseudohyphae help to distinguish it from *Candida*. The football-shaped *C neoformans* yeasts are much larger than the small round cells of *H capsulatum* organisms.<sup>[491]</sup>

Cryptococcal organisms can also be distinguished by the presence of a melanin-like pigment that is identified with the Fontana-Masson stain. The Alcian blue stain will help to distinguish the capsule of *C neoformans* (if present) as well as the wall of *Blastomyces dermatitidis*. The PAS stain will highlight the cell walls of each of these latter two organisms.<sup>[492]</sup> This pigment production is a feature of growth on Niger agar. On standard Sabouraud agar the organisms grow at 25° to 37°C and identified by carbohydrate utilization test.<sup>[487]</sup>

When antiretroviral therapy (ART) is begun, within 2 months there may be immune restoration disease (IRD), loss of anergy, and development of more florid inflammatory

responses from delayed-type hypersensitivity restoration. With cryptococcal infections, IRD is most often manifested by lymphadenitis, particularly within the mediastinum.[310]

Antifungal therapies with amphotericin B, flucytosine, and triazoles (fluconazole, itraconazole), are successful in many cases. Fluconazole or itraconazole are the drugs most often used for secondary prophylaxis, since many patients with treated *C neoformans* infections will have a recurrence without continued suppressive therapy. About half of AIDS patients infected with *Cryptococcus* are found to have died of their cryptococcal disease, most often from CNS involvement.[223,448]

## HERPESVIRUS INFECTIONS

The human herpesvirus (HHV) family (Herpesviridae) includes the following:

Species	HHV designation
Herpes simplex virus type 1 (HSV-1)	HHV-1
Herpes simplex virus type 2 (HSV-2)	HHV-2
Varicella zoster virus (VZV)	HHV-3
Epstein-Barr virus (EBV)	HHV-4
Cytomegalovirus (CMV)	HHV-5
Human herpesvirus 6	HHV-6
Human herpesvirus 7	HHV-7
Kaposi sarcoma-associated herpesvirus (KSHV)	HHV-8

These agents may appear in the course of HIV infection and produce a variety of clinically significant manifestations either as self-limited or non-resolving opportunistic infections.[493] Cytomegalovirus produces the greatest morbidity as well as resultant mortality and has been discussed separately above. Epstein-Barr virus plays a role in development of both oral hairy leukoplakia and malignant lymphomas in AIDS.[494] HHV-6 has been found to replicate in a variety of cell types, including CD4+ lymphocytes, and has been implicated as a cause for roseola. HHV-6 may act as a cofactor in the acceleration of HIV infection to AIDS in patients who are infected with both viruses. However, evidence of any pathogenic role of HHV-6 in enhancing the progression to AIDS has been indefinite. The association of HHV-7 with human disease has not been recognized.[495]

Herpes simplex types 1 and 2 are sexually transmissible agents of importance in patients both with and without HIV infection. Recurrent mucocutaneous herpes simplex virus infections of more than one month's duration satisfy definitional criteria for diagnosis of AIDS in patients proven to have HIV infection.[421] Clinically, the recurrent herpetic lesions of AIDS patients are more of a chronic nuisance than a life-threatening condition. Ulcerated or excoriated lesions may subsequently become secondarily infected. However, coinfection with HSV-2 has been associated with an increased HIV viral load and more rapid disease progression.[496]

Both HSV types 1 (HSV-1) and 2 (HSV-2) primarily infect skin and mucus membranes to produce inflammation, often vesicular, progressing to sharply demarcated ulcerations. Herpes simplex type 1 involves predominantly the oral cavity while HSV-2 more often involves the genital region. However, either body region may be infected by either subtype to produce clinically and histologically indistinguishable disease.[497]

Varicella zoster virus (VZV) infections typically begin as childhood chickenpox, and the virus becomes latent in dorsal root ganglia. VZV may reactivate years later in adults who are immunocompromised, including those with AIDS. However, children with HIV infection are also at risk for VZV infection. The classic presentation in reactivation is "shingles" with painful skin vesicles appearing in a dermatomal distribution, most commonly thoracic, lumbar, or cervical. The vesicles may develop into blisters within 2 weeks to a month. VZV is not a disseminated disease involving multiple organ systems and does not cause death, but is a debilitating nuisance for persons who have it. Skin dissemination can occur in the form of

multiple dermatomal distributions. Persons who have VZV involvement of the ophthalmic division of the trigeminal nerve may also have ocular involvement in the form of acute retinal necrosis, progressive outer retinal necrosis, or progressive herpetic retinal necrosis. About 8 to 15% of patients, particularly elderly persons, may develop post-herpetic neuralgia. Central nervous system involvement by VZV can lead to encephalitis, ventriculitis, periventriculitis, vasculopathy, and myelitis.[498]

All herpesviruses exhibit latency following initial infection. Either HSV or VZV infection initially occurs through mucosal surfaces or through abraded skin via contact with a person who is excreting virus through active, usually ulcerative, lesions. Viral replication begins within epithelium and underlying dermis or within submucosa. From these initial sites, HSV or VZV spreads to nerve endings and is transported intra-axonally to neurons in ganglia, from which spread is then via peripheral sensory nerves back to other, usually adjacent, skin and mucosal sites.[497]

Thus, vesicular HSV or VZV lesions may later appear or recur away from the initial site of involvement. After an initial host response in which both cell-mediated and humoral mechanisms take part, the infection usually becomes latent, with HSV or VZV present but not actively replicating within ganglia. It is unclear just how reactivation of HSV, or VZV as VZV, occurs but lack of cell-mediated immunity in immunocompromised patients may be implicated.[497]

The typical patient with HSV or VZV has a grouped vesicular skin eruption that ruptures, crusts, and heals in seven to ten days. Infection may be associated with a history of severe pain, often persisting for months after the skin lesions resolve. Scarring also occurs. Reactivation of VSV as shingles may often occur as an early manifestation of immune impairment with HIV infection as the CD4 cell count diminishes below 500/ $\mu$ L, though development of VZV does not appear to be associated with duration of HIV infection. VZV is less likely to occur with antiretroviral therapy, but may still occur in a fourth of HIV-infected persons during their course.[499] The incidence of VZV may increase as a consequence of immune restoration disease (IRD) in the months following the start of successful antiretroviral therapy (ART).[310]

In persons with HIV infection, as with immunocompetent individuals, recurrent lesions of HSV predominantly involve skin and mucus membranes, while the lesions of VZV are typically limited to skin. Internal organ involvement has been reported less frequently, and disseminated infections are uncommon, but the clinical course of recurrence is similar to that seen in other immunocompromised patients or even immunocompetent persons. The upper gastrointestinal tract including tongue, oropharynx, and esophagus may occasionally have herpetic lesions, and the central nervous system is less commonly involved (Table 5). Herpetic mucocutaneous lesions of immunocompromised patients, including those with AIDS, have been reported to be more extensive, more severe, and longer-lasting, with more ulceration, necrosis, and pain than in immunocompetent patients.[493,497,500]

HIV-1 infection may predispose to HSV infection and reactivation. HSV infection with reactivation can disrupt the genital mucosal barrier, can recruit inflammatory cells, and can elaborate proteins that transactivate HIV replication. Treatment to suppress HSV reduces HIV-1 genital and systemic excretion.[501]

In addition to typical VZV findings, the patient with HIV infection can have chronic VZV, particularly when CD4 lymphocyte counts are low. The clinical appearance of the chronic, verrucous VZV lesions is that of single or multiple pox-like or wart-like hyperkeratotic and well-demarcated lesions, which vary from 4 mm to 10 cm in diameter at any skin site.



Lesions often persist from weeks to months, including extension or regression without healing. Healing may occur within 2 to 3 weeks following therapy, often with residual scarring. Chronic VZV may follow initial varicella infection, often in children, or it may develop directly from shingles, or may arise without apparent classic lesions from direct hematogenous dissemination from reactivated virus in dorsal root ganglia. Treatment with acyclovir may be effective at first, but thymidine kinase-dependent drug resistance can develop. Then a DNA polymerase inhibitor such as foscarnet may be employed. Cidofovir has been used when resistance occurs.[502]

Pathologic findings with chronic VZV include hyperkeratosis and parakeratosis of the verrucous lesions with papillomatous to pseudoepitheliomatous epidermal hyperplasia. Cowdry type A inclusions and keratinocyte necrosis can be present, as well as swollen keratinocytes without cytolysis. Though there can be an underlying dermal inflammatory infiltrates of lymphocytes and/or neutrophils, it is usually minimal or absent.[502]

Although cytologic or histologic diagnosis is simple and cost-effective, viral culture remains the most sensitive clinical method for HSV or VZV diagnosis; methods for antigen detection are less sensitive. Culture sensitivity is higher when the herpetic vesicular lesions first appear and before they ulcerate. Later ulcerative lesions may have no detectable virus. Serologic testing is mainly of value for detection of past infection, but not acute infection, for immunocompromised patients are unlikely to mount a significant (fourfold or greater) rise in anti-HSV titer between acute and convalescent samples.[497]

Microscopically, lesions of HSV and VZV both in tissue biopsies and from cytologic preparations (Tzanck or Pap smears) demonstrate characteristic acantholytic epithelial or discohesive parenchymal cells, often multinucleated or in clusters, with mauve to pink to steel-gray ground glass intranuclear (Cowdry type A) inclusions and nuclear chromatin margination. The cytoplasm of infected cells is not prominent and, unlike CMV, does not contain inclusion bodies of any kind. With ulceration, such cells may be infrequent or autolyzed. Epithelial cells of the skin adnexa (sweat ducts and hair follicles with sebaceous apparatus) may also be involved.[503]

On average, cells infected with herpes simplex and varicella zoster virus groups do not reach the size of those with cytomegalovirus, but the larger cells with herpes simplex or varicella zoster and the smaller cells with cytomegalovirus may be of similar size. The intranuclear inclusions of cytomegalovirus tend to be darker and larger. Also, in squamous epithelium with herpetic lesions, ballooning degeneration is common, and CMV is unlikely to be associated with vesicle formation in mucosal tissues.

For VZV, typical cytologic features most often occur in cells between papillae and dermal adnexa. Cells infected with HSV or VZV do not often reach the size of cells infected with CMV, and the intranuclear inclusions of CMV tend to be darker and larger, and intracytoplasmic inclusions may accompany CMV. Immunoperoxidase staining with primary antibody against HSV-1, HSV-2, and VZV will help to exclude other viral etiologies such as CMV, EBV, and HPV.

Acyclovir has been found to be effective therapy for treating most mucocutaneous and visceral herpetic infections and may be useful prophylactically in persons with frequent recurrences.[223,497] However, both HSV and VZV infections that are resistant to acyclovir are found in increasing numbers in immunocompromised patients.[504] The cyclical nature of herpetic infections means that they may at times regress without therapy, or in spite of it.[493] Death from either herpes simplex or varicella-zoster viruses is quite rare, and usually results from central nervous system involvement.[448]

Human herpesvirus 6 (HHV-6) is highly seroprevalent, with a worldwide distribution. Most persons are infected by the age of two; the probable mode of transmission is through saliva. In infants, it may cause roseola, and a mononucleosis-like syndrome. This virus is predominantly tropic to CD4 lymphocytes. HHV-6 infection can coexist with HIV infection, and may be involved with progression to AIDS, since HHV-6 upregulates CD4 expression and can, therefore, increase HIV replication to deplete CD4 lymphocytes. Active HHV-6 infection can be present before the stage of clinical AIDS is reached.[495,505]

Human herpesvirus 7 (HHV-7) is a lymphocytotropic agent for CD4 cells that typically infects most persons during childhood and may cause skin rashes such as pityriasis rosea. Both HHV-7 and HIV use CD4 receptors and can interfere with each other. The immunosuppression accompanying HIV infection may lead to reactivation from latency and increased replication of HHV-7 in lymph nodes.[506,507]

Human herpesvirus 8 (HHV-8) is also known as Kaposi sarcoma-associated herpes virus (KSHV) is associated with a variety of neoplastic and proliferative lesions seen with AIDS. This is a gamma 2 herpesvirus. The gamma herpesviruses establish persistent viral infections, and evade viral clearance by actively suppressing cellular apoptosis and by escaping immune detection. By their persistence, these viral infections drive host cell transformation and neoplasia, most often in the setting of immunodeficiency. KSHV is endemic in sub-Saharan African populations, with seroprevalence of over 50% in adults. Seroprevalence is 6 to 20% in Europe, 1 to 7% in the U.S., and 1 to 4% in Southeast Asia and the Caribbean. Transmission of KSHV in endemic regions usually occurs during childhood, from parent to child or between children. In non-endemic regions it is often a sexually transmitted agent. The seroprevalence is high in men having sex with men. An additional risk factor for transmission of HHV-8 is injection drug use, but the transmission of HHV-8 by needle sharing is less efficient than for HIV. HHV-8 is present in all cases of AIDS-associated Kaposi sarcoma, and is invariably present in primary effusion lymphoma of body cavities. It has been detected in multicentric Castleman disease and in plasmablastic lymphomas.[508,509,510]

## CANDIDA INFECTIONS

*Candida* as a commensal organism is so ubiquitous in both healthy and ill persons that it is often difficult to determine just how important it really is when identified in patient specimens. *Candida* organisms found on the skin or within the oral cavity are not always presumed to be pathogens at these sites. Likewise, in AIDS, finding *Candida* does not always mean that a pathologic condition is present. In HIV-infected persons, binding of viral gp160 and gp41 envelope proteins enhances the virulence of *Candida*. [511]

AIDS patients often receive a clinical diagnosis of "oral candidiasis" or "oral candidosis" or "oral thrush" as a result of finding white creamy patches or plaques on oral mucosal surfaces. Such mucous membrane involvement is seen in most HIV-infected persons at some point in their course. [490,511] Oropharyngeal candidiasis is most likely to occur when the CD4 lymphocyte count is  $<200/\mu\text{L}$  but can occur when the count is  $>500/\mu\text{L}$ . [512]

Most *Candida* infections are due to *Candida albicans*, but non-*albicans* infections are increasing. The second most common species isolated *Candida glabrata*, followed by *Candida tropicalis*, and *Candida parapsilosis*. Much less common species include *Candida guilliermondii*, *Candida pelliculosa*, *Candida kefyr*, *Candida rugosa*, and *Candida famata*. [486]

The progressive depletion and dysregulation of mucosal Langerhans cells from HIV infection reduces normal processing of *Candida* antigens, and this, coupled with progressive loss of CD4 lymphocytes, reduces adaptive immunity to *Candida*. Depletion of CD4 cells and a shift in expression from  $T_H1$  to  $T_H2$  cytokines may reduce anti-candidal activity of phagocytic cells including macrophages and neutrophils. MHC expression of class I antigens on Langerhans cells may be partially preserved to allow recruitment of a compensatory protective CD8+ T-cell response. Innate immune defenses, including intact keratinocytes, intraepithelial T cells, neutrophils, and calprotectin, remain so that dissemination of *Candida* is uncommon, but may appear with bone marrow suppression. [513] There are no specific clinical findings with disseminated candidiasis, and this manifestation is unlikely to be diagnosed pre mortem. [421]

The most common species isolated in microbiologic cultures include *Candida albicans*, *Candida tropicalis*, and *Candida parapsilosis*. *Candida* (formerly *Torulopsis*) *glabrata* may appear clinically and histologically similar to *Candida*, though they are often of very small 1 to 2 microns size. Except for epidemiologic purposes or antifungal resistance, most of these fungal species with budding cells are clinically or histologically grouped as "*Candida*" or "yeast." Patients are usually colonized with a single strain, and recurrences are usually due to the same strain. [511] Diagnosis of *Candida* fungemia may be aided by detection of  $\beta$ -D-glucan (BG), a unique cell-wall component of many fungi, including *Aspergillus*, *Fusarium*, *Trichosporon*, *Saccharomyces*, and *Acremonium*, but not *Cryptococcus* or Zygomycetes. [486]

In order to fulfill the definitional criteria for diagnosis of AIDS, *Candida* must be found to satisfy specific requirements: there must be *invasive* esophageal or respiratory tract (trachea, bronchi, or lungs) candidiasis. [421] Merely finding budding yeasts upon a mucosal surface without any tissue reaction is not sufficient for diagnosis of AIDS. *Candida* is seen in the upper gastrointestinal tract, primarily the esophagus, in many cases in which it is present. The lung is often involved at autopsy. In a few cases, *Candida* may be disseminated beyond the respiratory or gastrointestinal tracts. Other organs are infrequently involved, and in bone marrow, *Candida* is rarely identified in AIDS (Table 5). Drug therapies that lead to bone marrow suppression,

corticosteroid therapy, or other immunosuppressive agents may enhance dissemination of *Candida*.

There are characteristic gross findings on mucosal surfaces as seen in the oral cavity, pharynx, trachea, bronchi, esophagus, or vagina. These findings include four appearances: pseudomembranous candidosis, erythematous candidosis, angular cheilitis, and hyperplastic candidosis. The most common pseudomembranous form has white, elevated mucosal plaques that often have a cottage cheese like appearance. Other gross findings include the erythematous (atrophic) form with flat red patches, the hyperplastic form with partially removable white plaques, and angular cheilitis with erythema and fissuring at the corners of the mouth. Other superficial forms of *Candida* involvement can be seen as paronychia or onychomycosis.[490,511]

If dissemination occurs to visceral organs, *Candida* is most likely to produce a pattern similar to bacterial microabscesses, with small pinpoint to 0.3 cm diameter soft yellow foci, sometimes surrounded by a small hemorrhagic zone. Organomegaly is infrequent with such lesions.

Microscopically, *Candida* microabscesses contain more polymorphonuclear leukocytes than lymphocytes or macrophages. If the degree of immunosuppression is marked, there may be little inflammatory reaction, and the pseudohyphae will grow haphazardly throughout the tissues. In fact, a typical hyphal or pseudohyphal growth pattern exhibits extension across mesothelial-lined surfaces or into blood vessel walls. Vascular invasion may lead to hemorrhage, thrombosis, or infarction.

*Candida* organisms are identified histologically by their 3 to 5 micron size, budding, and pseudohyphae. The pseudohyphae can be distinguished from *Aspergillus* hyphae by the lack of branching, the smaller size, and the frequent absence of true septations in the former. Sometimes *Candida* species may also have septate hyphae that can be long, but often of uneven caliber, with bulbous or pinched portions along their length. Budding cells of *Candida* are larger than *Histoplasma capsulatum* and lack a defined "capsule" with inner nucleus. *Candida* is smaller than *Cryptococcus neoformans* and generally not as pleomorphic. A mucin stain will be negative with *Candida*, since there is no surrounding capsule as in *C. neoformans*. Methenamine silver and PAS stains are most helpful to identify *Candida*.

Even though *Candida* occurs in about 40 to 90% of patients with AIDS, death from *Candida* infection occurs in less than 5% of cases even when it is present, most often when the disease is widely disseminated, and usually from pulmonary involvement. In a small number of AIDS cases, *Candida* can produce a fatal septicemia. Though disseminated candidiasis and candidemia are rare in adults with HIV infection, children are more prone to develop these complications during prolonged hospitalization. Candidemia is more likely to develop as a community acquired complication in children who are receiving total parenteral nutrition and intravenous therapy via indwelling central venous lines. The prolonged presence of a central venous catheter is the most important risk factor for fungemia. Diagnosis of fungemia can be aided by use of PCR-based assays.[489]

Primary prophylaxis for candidiasis, most often involving oropharynx, esophagus, or vagina, is usually not indicated, unless recurrences are severe or frequent, since most of these infections respond well to administered topical or oral antifungal agents, including fluconazole, ketoconazole or clotrimazole. Fluconazole is more effective for curing oral candidiasis. Resistance to fluconazole therapy is more frequent when the CD4 lymphocyte count is low. Though antiretroviral protease inhibitors have theoretical activity against secreted aspartyl

proteinases (SAPs) of *Candida*, the anti-candidal effect of PIs in vivo has not been uniformly observed.[511]

In some patients, recurrences of yeast infections are common and secondary prophylaxis with topical clotrimazole troches or nystatin is used for oral candidiasis. Systemic fluconazole therapy is recommended for recurrent esophageal candidiasis, with ketoconazole therapy also available; rarely, amphotericin B therapy is required (Table 7).[223,426]

## TOXOPLASMA GONDII INFECTIONS

Toxoplasmosis is an uncommon infection that, before the AIDS pandemic, was rarely seen in adults. It is more common in warm humid climates, and this distribution may influence its appearance in AIDS. Toxoplasmosis can occur perinatally as a congenital infection in the absence of HIV infection.[514] Ingestion of poorly cooked meat (usually pork) is a principle form of transmission in adults, though ingestion of food or water contaminated with *T gondii* oocysts is also an important route of infection.[515]

*T gondii* can invade virtually all tissues of the body, but in AIDS patients, the organ system distribution of *T gondii* infection is generally not widespread. The central nervous system is involved in most cases. Extracerebral toxoplasmosis is more likely to occur later in the course of AIDS with a greater degree of immunosuppression when the CD4 lymphocyte count is low. Extracerebral sites for *T gondii* in AIDS are most often eye and lung, with heart and gastrointestinal tract involved much less often. Other organs are infrequently involved, with reticuloendothelial tissues occasionally affected (Table 5).[516]

The clinical appearance of toxoplasmosis is typically that of altered mental status from central nervous system involvement. The most common manifestations include fever, lymphadenopathy, splenomegaly, hepatomegaly, and mucocutaneous symptoms. Pulmonary symptoms in half of cases include cough, dyspnea, chest pain, and hemoptysis. CNS involvement in 5 to 10% of cases may manifest as headaches and focal neurologic deficits. Laboratory findings can include pancytopenia, elevated alkaline phosphatase, increased lactate dehydrogenase, and hypoalbuminemia. Diagnosis may be suggested by elevated serologic titers, but many persons have antibodies to *T gondii* because of subclinical infection. Serologic titers give no indication of dissemination. The presentation of cerebral toxoplasmosis may appear quite similar to that for non-Hodgkin lymphoma, and stereotaxic brain biopsy may be useful for diagnosis. Extracerebral toxoplasmosis may sometimes be diagnosed by bronchoalveolar lavage or endoscopic biopsy.[516,518]

The gross appearance of toxoplasmosis is not distinctive. In the brain, the diagnosis is suggested by finding multiple small areas of necrosis or cystic change, while in the heart, a patchy parenchymal myocarditis with tan to white irregular infiltrates may occur in severe cases. In other organs, there are no specific features and grossly visible lesions may not be apparent.

In biopsy material, diagnosis is best made by finding characteristic cysts filled with the organisms--dubbed bradyzoites in this location. The cysts may be "true" cysts formed only by the *T gondii*, or they may be "pseudocysts" that form within an existing cell and use the cell wall as a cyst wall. Cysts average 50 microns in size. Free *T gondii* organisms, called tachyzoites, are 2 to 3 microns wide and are often difficult to distinguish, with hematoxylin-eosin staining, from background cellular debris.[432] The sexual cycle of *T gondii* occurs in the definitive host, the cat, where oocysts form in the intestine and are excreted into the environment to be ingested by other animals or man.[515]

Encysted *T gondii* usually produce no or minimal inflammatory reaction, but serologic titers may increase. However, rupture of the cysts with release of *T gondii* as free tachyzoites does produce a host response. The tachyzoites are too small to be morphologically distinctive by hematoxylin-eosin staining in most tissue sections. Immunohistochemical staining may aid in finding not only the cysts, but also in identifying free tachyzoites.[514]

The inflammation that accompanies the cysts and free tachyzoites is usually mixed, with neutrophils, lymphocytes, macrophages, and plasma cells in varying proportions. These mixed inflammatory cell infiltrates occur in a patchy pattern within involved organs. Even though inflammation may be extensive, finding cysts is still difficult, though the greater the degree of inflammation, the greater the likelihood of finding cysts. Larger areas of inflammation are usually accompanied by some cellular necrosis.[514]

Sometimes, cysts may be difficult to distinguish from cytomegalic cells that have intracytoplasmic basophilic inclusions in which the plane of sectioning has missed the nucleus. Cytomegalovirus basophilic bodies tend to be more pleomorphic than bradyzoites, and *T gondii* cyst walls are thicker than cytomegalic cell borders. Macrophages containing *Histoplasma capsulatum* tend to be more irregular in outline with fewer yeasts than the rounded pseudocysts of toxoplasmosis with many small bradyzoites.

Patients with HIV infection who lack antibody to *Toxoplasma* may avoid infection by not eating raw or undercooked meat, by hand washing after contact with raw meat or soil, by washing raw fruits and vegetables before eating them, and by reducing or avoiding contact with cat litter boxes. In the advanced stages of AIDS when the CD4 lymphocyte count is  $<100/\mu\text{L}$  and when there is serologic evidence for *Toxoplasma* infection, patients may receive prophylaxis. Trimethoprim-sulfamethoxazole (TMP-SMZ) used for prophylaxis against *Pneumocystis jiroveci* pneumonia (PJP) is also effective for prevention of toxoplasmosis and should be considered for patients with anti-toxoplasma antibodies who have a CD4 count  $<100/\text{microliter}$ . The alternative prophylactic regimen consists of sulfadiazine plus pyrimethamine and leucovorin.[223]

Pyrimethamine-sulfadiazine with folinic acid therapy for cerebral toxoplasmosis is often successful for treating diagnosed infections. A response to therapy occurs in about two thirds of cases.[516] Death from toxoplasmosis occurs in slightly less than half of AIDS patients infected with *T gondii* at autopsy. Of these, central nervous system involvement is responsible for death in virtually all instances. *Toxoplasma* myocarditis causing patient demise occurs sporadically.[426,515]

## HISTOPLASMA CAPSULATUM INFECTIONS

Most cases of histoplasmosis are caused by *Histoplasma capsulatum* var. *capsulatum* and are traditionally seen in areas in which this particular fungus is highly endemic--mainly the Mississippi and Ohio River valleys of the United States. Infections may also occur over a wider geographic area encompassing the St. Lawrence River valley to the north, Florida, Central and South America, Southeast Asia, India, and Africa. In the western and central regions of sub-Saharan Africa and Madagascar, *H capsulatum* var. *capsulatum* coexists with another species, *H capsulatum* var. *duboisii*, which can also cause histoplasmosis (so-called "African histoplasmosis"). Up to 80-90% of persons living in endemic areas may have skin test positivity. Infections reported in non-endemic areas are probably the result of reactivation of infections acquired earlier in endemic areas. HIV-infected persons who have lived or traveled in endemic areas may have reactivation of long latent *H capsulatum* infection with the onset of clinical AIDS.[517,518]

*H capsulatum* grows in a mycelial form in soils, particularly those enriched by bird or bat excrement. Persons infected with HIV should avoid bird roosting sites (particularly chicken coops) and caves in regions where *H capsulatum* is endemic. Inhalation of sporulating mycelial fragments (microconidia) into lung is followed by phagocytosis into macrophages and rapid intracellular conversion to the yeast form. These organisms can evade the usual T<sub>H</sub>1 immune response by expressing  $\alpha$ -1,3-glucan in their outer cell walls. Histoplasmosis tends to be a widely disseminated infection when the immune system is compromised, with predominant T<sub>H</sub>2 response, and can involve multiple organs, particularly reticuloendothelial tissues, as progressive disseminated histoplasmosis (Table 5).[490,518]

Widespread organ involvement is seen in 95% of cases in patients with AIDS infected with *H capsulatum*, and it results in protean manifestations. Fever, sepsis, hepatosplenomegaly, lymphadenopathy, weight loss, skin lesions, and respiratory complaints including shortness of breath and cough are common. Skin and mucosal manifestations such as maculopapular lesions and ulcerations can occur in up to 80% of patients with disseminated histoplasmosis. Up to 10% of disseminated cases have CNS involvement with meningitis and/or encephalitis. Adrenal insufficiency may affect 7% of patients with disseminated disease. Elevations in lactate dehydrogenase are common, as well as cytopenias. Additional frequent clinical findings include an interstitial pattern on chest x-ray, pancytopenia, and CD4 count <100/ $\mu$ L.[487,519]

There are several methods for diagnosis. Skin testing with histoplasmin is not predictive of histoplasmosis, because of widespread positivity in endemic areas coupled with anergy in the majority of patients with HIV infection. The use of serologic methods including PCR and complement fixation for *Histoplasma* antigen may be useful in identifying persons with histoplasmosis, but false positives can occur with infection from other fungal agents, particularly *Blastomyces dermatitidis*. There can be a false positive *Aspergillus* galactomannan assay. *H capsulatum* polysaccharide antigen can be detected in urine and serum.[518,487]

Regardless of immune status, persons infected or reinfected with *H capsulatum* will seroconvert within 4 weeks, with seroreversion within 5 years. A CD4 lymphocyte count <300/ $\mu$ L also indicates an increased risk for infection. Cultures of bone marrow and blood are positive in 70 to 90% of cases, but *H capsulatum* can be slow growing, requiring from 1 to 6 weeks for positive culture results. Serologic testing will demonstrate antibodies in 50 to 70% of



cases. Antigen can be detected in urine, serum, fluid from bronchoalveolar lavage, and in cerebrospinal fluid in most cases.[490,520,521]

Infections with *H capsulatum* in AIDS typically involve multiple organs in a diffuse pattern. There are no specific gross pathologic findings. Sometimes histoplasmosis will produce visible granulomas that are variably sized, discrete, white to tan, firm, and indistinguishable from those of other dimorphic fungi or *Mycobacterium tuberculosis*.

The organisms are small 2 to 4 micron yeasts that may show budding. The yeasts are usually found within the cytoplasm of macrophages that tend to have irregular outlines with indistinct cell membranes on hematoxylin-eosin staining. These macrophages may cluster to form small granulomas that rarely have an accompanying pronounced or distinctive inflammatory response. The yeasts of *H capsulatum* are difficult to see with routine hematoxylin-eosin staining, appearing only as small faint bluish dots or circles.

Special stains should be used to identify the presence of *H capsulatum* in tissue biopsies or cytologic material. Methenamine silver staining provides the best contrast and is the easiest to screen, but the yeasts may be confused with the slightly larger budding cells of *Candida* when pseudohyphae are lacking in the latter. In regions with prevalent *Leishmania* infections, there may be difficulty in distinguishing *H capsulatum* by hematoxylin-eosin staining alone. Giemsa staining is helpful in bone marrow samples and in material obtained from the respiratory tract.[487]

A PAS stain helps to define the thin cell membrane or "capsule" of *H capsulatum* and the central dot-like cell contents that form with artefactual shrinkage during fixation. Clusters of such organisms are quite characteristic of *H capsulatum*. However, immunoglobulin inclusions (Russell bodies) within plasma cells (Mott cells) must be distinguished from yeasts on PAS staining by the homogeneity of staining, greater pleomorphism, and lack of a capsule in the former. Immunohistochemical staining for *H capsulatum* will aid in diagnosing difficult cases. Microbiologic culture will provide a definitive--though delayed--answer.[519]

Prophylaxis for *H capsulatum* using antifungal agents has not been shown to prevent histoplasmosis. Treatment resulting in prolonged survival may include induction with amphotericin B followed by long-term maintenance on itraconazole or fluconazole. Histoplasmosis responds well to therapy, but relapses in the absence of chronic suppressive antifungal therapy. When death occurs from histoplasmosis, organ involvement is frequently so widespread that it is difficult to determine a specific organ failure as a cause of death.[223,519,520]

*H duboisii* infection has some similarities to that caused by *H capsulatum*. The portal of entry is probably the respiratory tract, and less likely direct inoculation. *H duboisii* exists in soils. It can cause disseminated infection involving any organ, but classically is associated with nodular and ulcerative skin lesions and osteolytic bone lesions, particularly affecting the skull, ribs, and vertebrae. Microscopic examination shows granuloma formation with necrosis and suppuration. The yeasts of *H duboisii* are large, 7–15  $\mu\text{m}$  in size, and appear globose to ovoid, thick-walled, and typically lemon-shaped with a narrow budding. They are often seen in the cytoplasm of giant cells. There is serologic cross-reactivity between *H capsulatum* and *H duboisii*. The treatment for *H duboisii* is similar to that for *H capsulatum*. [517]

## COCCIDIOIDES IMMITIS INFECTIONS

Coccidioidomycosis is included in the definitional criteria for AIDS because it may appear in HIV-infected persons who have lived in endemic areas--arid plains of the Southwestern United States, Mexico, and Central and South America.[421] *C immitis* exists in a mycelial form (septated alternating arthrospores) in soils and is released into the air as arthroconidia that are inhaled.[490] The organisms are taken up into macrophages and can be lysed with a T<sub>H</sub>1 immune response. Once infection is established, *C immitis* grows as a yeast form in tissues, with large spherules containing endospores. In areas endemic for *C immitis*, HIV-infected persons may prevent infection by avoiding exposure to dusty environments or areas where soil is disturbed.[223] Coccidioidomycosis in AIDS probably represents a reactivation of a previous infection rather than recent infection.[487,522]

Coccidioidomycosis in association with AIDS tends to be a widely disseminated infection involving numerous organs (Table 5). The lung serves as the portal of entry for *Coccidioides immitis*. There are several clinical patterns of involvement, including focal pulmonary disease, diffuse pulmonary disease, cutaneous disease, meningitis, and wide dissemination. Grossly visible granulomas similar to other dimorphic fungi and to *Mycobacterium tuberculosis* may be present in lung, but often are not seen in other organs. Serologic tests for antibody to *C immitis* are positive in about two thirds of cases.[490,522] Widespread use of antiretroviral therapy decreases the incidence and the severity of coccidioidomycosis.[523]

The most frequent symptoms are fever with chills, weight loss, and night sweats. The clinical presentation is most often as pulmonary disease in 80%, followed by meningitis in 15% of cases. A fourth of patients have lymphadenopathy. The skin may be involved with plaques and ulcerations. A chest radiograph will demonstrate a diffuse reticulonodular infiltrate in over half of cases, but negative findings may occur in 16% of cases.[522] Diagnosis can be made by several methods. Skin testing with spherulin or coccidioidin may not be reliable due to anergy in HIV-infected persons. Serologic testing with PCR may be positive in up to three-fourths of cases; most of the false negative serologic tests are found when diffuse pulmonary disease is present. Blood cultures will be positive in about 12% of cases. Cultures of cerebrospinal fluid are positive in half of cases of *C immitis* meningitis.[487,490]

Microscopic diagnosis is made by finding large 10 to 80 micron thick spherules with doubly refractile walls and containing endospores in tissue biopsies. Spherules may also be identified in sputum and bronchoalveolar lavage fluid. Ruptured spherules may be partially collapsed with small 2 to 5 micron endospores close by. Once the endospores are released, they begin to grow into spherules with endospores, completing the life cycle. Thus, variably sized spherules are often present and only the larger ones will have well-defined endospores. Both Gomori methenamine silver (GMS) and periodic acid-Schiff (PAS) stains are helpful in identifying the organisms. An inflammatory reaction accompanying *C immitis* spherules tends to be quite sparse, consisting of only scattered lymphocytes, neutrophils, and macrophages producing a poor granulomatous reaction.[487]

Treatment with amphotericin B may be useful for acute and/or chronic infections. Secondary prophylaxis with itraconazole, fluconazole, or ketoconazole may be employed. Response to interferon gamma has been reported. Death occurs from coccidioidomycosis in two thirds of patients who have *C immitis* infection at autopsy. The mortality rate is highest when

diffuse pulmonary disease is present and/or the CD4 lymphocyte count is  $<50/\mu\text{L}$ . One important etiologic differential diagnosis in disseminated coccidioidomycosis should be made: a disseminated form of this infection can also occur in anabolic steroid abusers or corticosteroid users, who may also be young males. Thus, testing to confirm or exclude HIV status is essential.[426,487,522]

## GASTROINTESTINAL PROTOZOAL INFECTIONS

These infections occur from such organisms as *Entamoeba histolytica*, *Entamoeba coli*, *Giardia lamblia*, *Cryptosporidium* sp, *Microsporidium* sp, and *Isospora belli*. Only *Cryptosporidium* and *Isospora* are part of definitional criteria for AIDS, though one or more of these agents may be identified in the GI tract by stool examination at some point in the course of AIDS.[421] *Cryptosporidium* is far more frequently identified than *Microsporidium* or *Isospora*, at least in developed nations, while the others are more sporadic in occurrence. In the U.S. less than 5% of HIV infected persons develop cryptosporidiosis, with an increased risk for infection when the CD4 lymphocyte count is less than 100/ $\mu$ L.[524] Appearance of these protozoa may explain clinically significant diarrheas, though patients with such organisms diagnosed may be asymptomatic. These protozoal infections are more common in places where antiretroviral therapy is not as widely available.[432,525,526] Acid fast staining is useful for identification of *Cryptosporidium* and *Microsporidium* in stool specimens.[527]

Cryptosporidiosis in immunocompromised hosts can be the cause for diarrhea that is refractory to therapy. The species that most often infect humans include *Cryptosporidium parvum*, *C hominis*, and *C andersoni*, though the former is more often identified in immunocompromised hosts. There are no specific gross pathologic features of cryptosporidiosis, and infection is usually unaccompanied by inflammation, hemorrhage, or ulceration. Diagnosis is usually made from stool specimen examination, either by microscopy or aided by PCR analysis. After ingesting infective oocysts, there is asexual multiplication of the organisms in host intestinal epithelial cells within a vacuole so that the organisms are intracellular but extra cytoplasmic located on the brush border. Gametogeny follows next, leading to production of oocysts that are either thin-walled and auto infective or thick-walled and passed in feces to become infective to others. More thin-walled oocysts are present in immunocompromised hosts, leading to the persistence with greater severity of the disease. The incubation period is 2 to 14 days.[432,526,526]

The cryptosporidia appear histologically as quite small 2  $\mu$ m uniform rounded shapes; they develop outside of human cells but within a vacuole derived from the host cell. Thus, in tissue sections stained with hematoxylin-eosin, these organisms are small pale blue dots found lined along the mucosal brush border of the intestine. They can be highlighted with acid fast staining. Unfortunately, they may also resemble tissue fragments or karyorrhectic nuclei in tissue biopsies, so care must be taken in diagnosis. They are recognizable as 4-6 micron oocysts that are most distinctive from background in stool specimens with an acid-fast stain. Cryptosporidia are more easily recovered from diarrheal stools than from formed stools.[432] Cryptosporidia may rarely be found outside of the GI tract in the biliary tree or respiratory tract.[448] An immunohistochemical stain may aid in detecting them.[528]

Since the major route for infection with *Cryptosporidium* is through fecal-oral contamination and through contaminated water, HIV-infected persons should avoid drinking untreated water, avoid contact with either human or animal feces, and wash hands after contact with pets, soils, and fecal material.[223] Death from cryptosporidiosis may occur rarely in AIDS patients because of intractable diarrhea with fluid loss and electrolyte imbalance. The cachectic state and concomitant infection with other opportunistic agents in many AIDS patients potentiates the effects of the severe diarrhea. Therapy with spiramycin or eflornithine has shown very limited success.[426]

*Isospora belli* infections occur less frequently than cryptosporidial infections in AIDS, but produce an indistinguishable clinical appearance. Immunocompetent persons have mild symptoms lasting only days to weeks, but AIDS patients have a chronic intermittent diarrhea lasting for months. After ingestion, infective oocysts release sporozoites that invade intestinal epithelium where they develop into trophozoites, then schizonts. The schizonts may then release merozoites, which invade other epithelial cells and become either schizonts or gametocytes, which form zygotes and transform into infective oocysts passed with feces. By light microscopy, the small intestinal mucosa (and less frequently the colon in severe infections) shows shortening and flattening of villi, along with acute and chronic inflammation. *Isospora* organisms develop within vacuoles 3-15 microns in size on histologic section in the intestinal epithelial cells, and sometimes merozoites are visible. The infective oocysts of *Isospora* average 20-30 microns and can be seen easily in concentrated stool specimens with acid-fast staining. Identification may be aided by PCR analysis.[432,526,526]

Microsporidiosis is produced by spore-forming intracellular protozoan parasites identified in two genera: *Enterocytozoon* and *Encephalitozoon* (*Septata*). In the genus *Enterocytozoon* several species have been identified in persons with AIDS: *E. bienersi*, *E. cuniculi*, and *E. hellum*. *Encephalitozoon* (*Septata*) *intestinalis* has also been identified. The clinical features of GI infection with microsporidiosis mimic cryptosporidiosis. Microsporidia may also be found outside of the intestine in biliary tract, urinary tract, and eye, while more uncommon locations for involvement include nasal sinuses, respiratory tract, and central nervous system.[525,529,530]

Microsporidial infection in man occurs when ingested spores invade intestinal epithelial cells. The spores proliferate by fission to produce meronts. From meronts, sporonts develop and divide into sporoblasts which then undergo metamorphosis to spores that are passed into feces.[432,526] Diagnosis is made by small intestinal biopsy with characteristic transmission electron microscopic appearance in villous epithelial cells of clusters of supranuclear intracytoplasmic 4 to 5 micron sized meronts and sporonts or 1 to 2 micron acid fast spores.[531] Microsporidiosis can also be diagnosed by light microscopy in tissue sections with Giemsa stain, modified trichrome, or fluorescence staining of direct smears of unconcentrated stool or duodenal aspirate specimens fixed with formalin.[526,525]

A modified trichrome stain can be useful for diagnosis of microsporidia in direct smears of stool and duodenal aspirates that are unconcentrated and have been formalin-fixed.[530] In addition, fluorescence methods can be utilized for detection of microsporidia (*Enterocytozoon* and *Septata* species). The Fungifluor, Calcofluor white, and Fungiquel A fluorochrome stains can be applied to stool specimens, enteric fluids, and tissue biopsies. Spores of these organisms are best detected either in unfixed or in formalin-fixed specimens. These methods can be applied to paraffin-embedded tissues.[532] Use of PCR can also aid in identification of microsporidial organisms.[525]

*Cyclospora cayentanensis* is another organism that can cause a diarrhea lasting for weeks to months leading to fatigue and weight loss similar clinically to cryptosporidial diarrhea. Cyclosporiasis is a cause for traveler's diarrhea in both immunocompetent as well as immunocompromised persons. Diarrhea may not be more severe in persons with HIV infection, but has a high recurrence rate.[533] The causative agent is a small coccidian protozoa, originally described as a blue-green algae or cyanobacterium, that can be detected in stool by acid fast staining. The acid fast stained organisms demonstrate orange autofluorescence with blue (450 to 490 nm) fluorescent light microscopy. The organisms resemble a large cryptosporidium; they

are 8 to 10 microns in size, with a double cyst wall and a central morula. Small intestinal biopsy reveals mild to moderate acute and chronic inflammation of lamina propria with prominent plasma cells along with focal vacuolization of the brush border and mild to moderate partial villous atrophy and crypt hyperplasia.[432,526,530]

*Giardia lamblia* is a common intestinal protozoan infection in many parts of the world. It is occasionally seen in persons with AIDS and can produce bloating, diarrhea, and malabsorption. The organisms are found tightly adherent to the duodenal mucosa and appear either as 10 micron round to oval, pale-staining trophozoites or as cysts that are slightly larger and darker staining with long axonemes and curved median bodies. These organisms may be difficult to recover in stool and require duodenal aspirate and biopsy for diagnosis.[432,526]

Additional infectious protozoal agents include *Sarcocystis* spp, *Blastocystis hominis*, and *Entamoeba* spp. Amebiasis has been reported with increased frequency in persons infected with HIV who live in endemic regions. In the U.S., the incidence remains low. The seroprevalence appears to be greatest in men having sex with men. [526,534,535]

## BACTERIAL INFECTIONS SEEN WITH AIDS

Bacterial infections can be frequent and clinically significant in persons with HIV infection because of the defects in both humoral as well as cell-mediated immunity late in the course of AIDS. Recurrent bacterial infections in children and recurrent pneumonia in adults may be used to define AIDS by CDC criteria.[418,419,420,421] The chronically debilitating course of AIDS along with multiple drug therapies, including the use of indwelling catheters, and the potential for superinfection of existing lesions all enhance susceptibility to bacterial infection. In fact, during the course of infection with HIV, bacterial infections can be more common than parasitic, viral, or fungal infections. Bacterial bronchopneumonia is second only to *Pneumocystis jiroveci* (carinii) pneumonia in frequency as a cause of death from pulmonary infections in persons with AIDS.[448] The neutropenia that may occur with AIDS, either as a consequence of HIV infection or as a complication of drug therapy, significantly increases the risk for bacterial infections when the absolute neutrophil count diminishes below  $750/\mu\text{L}$ , and particularly when the count is below  $500/\mu\text{L}$ . [536]

Risk factors for bacterial pneumonias include smoking, injection drug usage, older age, detectable HIV-1 RNA, and prior recurrent pneumonia. The bacterial species most often responsible for pulmonary infections are *Streptococcus pneumoniae*, *Haemophilus influenzae*, *Staphylococcus aureus*, *Pseudomonas aeruginosa*, *Legionella pneumophila*, and gram negative bacilli. Community acquired pneumonias may be caused by *Staphylococcus aureus* and *Pseudomonas aeruginosa* as well as *Streptococcus pneumoniae*. Prophylactic vaccination for *S pneumoniae* and *H influenzae* may reduce the incidence of these infections. The host response to infection with these agents is mainly neutrophilic, but is blunted late in the course of AIDS by the generalized failure of the immune system. Diagnosis is made by gram stain and culture of body fluids and tissues.[537,538]

Bacterial organisms in persons with AIDS most often produce respiratory disease, particularly bronchopneumonia that can be life-threatening, but such infections can become disseminated as well, and recurrence is common. The bronchopneumonias seen with AIDS can be extensive and bilateral. Mortality is higher than in non-HIV-infected patients. Critically ill HIV/AIDS patients with sepsis have greatly increased risk for mortality.[539] Bacterial septicemias are the immediate cause of death in about 5% of AIDS patients.[448] Indwelling catheters may predispose to infection, particularly with *Staphylococcus* organisms.[537,538] Nosocomial infections are more common in patients with AIDS from immunosuppression, prior antibiotic treatment, and greater exposure to invasive devices such as indwelling catheters. The incidence of nosocomial infection seen with AIDS ranges from 7.9 to 15 per 100 admissions, with bloodstream infections the most frequent, mainly due to intravascular catheters, followed by urinary and respiratory tract infections.[540]

Two bacterial agents found in soils that can infect patients with HIV infection are *Listeria* and *Rhodococcus*. *Listeria monocytogenes*, which appears as a short gram-positive bacillus, occurs occasionally in HIV-infected patients, usually as meningitis, septicemia, or gastrointestinal infection. Listeriosis may not be frequent because *Listeria* is inhibited in vivo by tumor necrosis factor (TNF), and patients with AIDS typically have increased levels of TNF. However, the incidence of listeriosis in persons with HIV infection and with AIDS is about 10 and 100 times respectively that of the population as a whole. *Rhodococcus equi* is a weakly acid-fast pleomorphic gram-positive coccobacillary agent. The persistence of *Rhodococcus* in

macrophages makes its eradication in patients with a poor cellular immune response difficult and leads to chronic relapsing infections, typically pneumonias and septicemias.[538,541,542] This persistence can also manifest in malakoplakia, or the appearance of macrophages containing target-like calcospherites called Michaelis-Gutman bodies.[543]

Vaccination against *Pneumococcus* in adults and *H influenzae* type b in children and adults is a useful prevention strategy against these bacterial infections in adults with HIV infection.[544] Trimethoprim-sulfamethoxazole used for *Pneumocystis jiroveci* (*carinii*) pneumonia prophylaxis has been shown to also reduce the risk for bacterial infections. In children, the use of intravenous IgG can help to prevent recurrent bacterial infections.[223]

Gastrointestinal bacterial infections can include *Salmonella*, *Campylobacter*, and enteropathogenic *E. coli* involving the small intestine or *Shigella*, *Campylobacter*, *Clostridium difficile*, *Vibrio parahaemolyticus*, *Yersinia*, and *Aeromonas hydrophilia* involving the colon. Small intestinal infections are generally associated with large volumes of watery stool, malabsorption, and wasting syndrome but no fever, occult blood, or fecal leukocytosis. Colonic infections are characterized by frequent but small volume stools that may contain blood, have abundant leukocytes, and be associated with painful bowel movements. Diagnosis is made via microbiologic culture of stool or blood.[545]



## OTHER INFECTIONS

**BARTONELLA INFECTIONS.**-- Bacillary angiomatosis (epithelioid angiomatosis), peliosis of liver and spleen, osteolytic bone lesions, and persistent fever with bacteremia in HIV-infected persons are caused by fastidious, facultative intracellular gram negative organisms known as *Bartonella henselae* (formerly *Rochalimaea henselae*) or as *Bartonella quintana*. The natural reservoir for *B. henselae* is the cat. Reservoirs for *B. quintana* include lice and fleas.[546]

*Bartonella* organisms evade the innate immune system because their surface molecules are not recognized by Toll-like receptor 4 on dendritic cells and macrophages. Once phagocytized, the organisms can avoid lysosomal fusion and acidification. When the organisms persist within periendothelial extracellular matrix there is sustained, localized bacterial replication within collagen that facilitates an antiapoptotic state in endothelial cells by secreting effector proteins that bind to the endothelial membrane receptor. The ensuing transmembrane signal transduction results in high cytoplasmic cAMP levels that upregulate cAMP responsive genes and induce an antiapoptotic state in the endothelial cells, resulting in their proliferation, driving the appearance of vascular lesions.[546]

The lesions appear as cutaneous nodular vascular lesions but may also be found as vascular proliferations in a variety of organs including the GI-tract where they may cause hematemesis. This agent appears to be *Rickettsia*-like, and it can be identified in tissue sections with Warthin-Starry staining, by immunocytochemical methods, or by culture with confirmation via polymerase chain reaction. *Bartonella* serology has a 50 to 95% sensitivity but has cross-reactivity with *Bartonella*, *Coxiella*, and *Chlamydia*. Tissue cultures are not always positive and take a long time given the fastidious nature of the bacterium. PCR is a faster, sensitive, and specific diagnostic test.[546,547,548]

**LYMPHOGRANULOMA VENEREUM (LGV).**-- A sexually transmitted disease most commonly seen in tropical and subtropical regions, LGV with HIV infection is caused by serovar L2 of *Chlamydia trachomatis*. This infection develops in three stages. There is a primary stage with a transient and often insignificant genital ulcer. The secondary stage is characterized by inguinal adenitis, and bubo formation. Proctitis with purulent anorectal discharge, pain and bleeding also occurs, with microscopic pathologic findings of mucosal ulceration, heavy lymphocytic infiltrates in the lamina propria, cryptitis, crypt abscesses and granuloma formation. The third stage produces chronic granulomatous inflammation, lymphedema, elephantiasis, and often-irreversible rectal stricture. It is most likely to occur in the setting of HIV infection among men having sex with men. Most cases respond to doxycycline therapy.[549]

**LEISHMANIA INFECTIONS.**-- Leishmaniasis is present in about 12 million persons worldwide, with at least 1.5 million new cutaneous cases and 0.5 million visceral cases each year. Most reported cases of leishmaniasis in persons with HIV infection are visceral leishmaniasis, known also as kala azar, from endemic areas for *Leishmania donovani*, but these infections may also be seen outside of endemic areas because of increased travel. Increasing numbers of cases have been observed in Southwestern Europe. The CD4 count is <200/ $\mu$ L in over 90% of cases. AIDS appears to increase the risk for leishmaniasis by 100 to 1000 fold. The major risk factor for HIV infection in coinfecting patients is injection drug use in more than 70% of cases. The major surface molecule of *L. donovani* is lipophosphoglycan which induces HIV transcription in CD4 cells; thus, leishmaniasis may promote HIV infection.[550]

*L donovani* is a protozoan parasite transmitted via sand fly bite. The bite introduces promastigotes into the skin, where they are then engulfed by macrophages. The organisms become amastigotes and, after proliferating, peripheral blood mononuclear cells can become infected and spread the infection through tissues of the mononuclear phagocyte system and elsewhere. Overt disease is likely to occur when a  $T_H2$  immune response occurs instead of the more effective  $T_H1$  response. In addition to immune response, nutritional status and organism virulence contribute to disease severity. Clinical manifestations include fever and hepatosplenomegaly. In addition to pancytopenia, laboratory findings can include elevated C-reactive protein, hypergammaglobulinemia, and antinuclear antibodies.[551]

The mononuclear phagocyte system, including liver, spleen, lymph nodes, and bone marrow, are most often involved, but the gastrointestinal tract and respiratory tract may also be affected in immunocompromised hosts, and unusual sites of involvement such as the heart, skin, and adrenal may occur, particularly when the CD4 count is less than  $50/\mu\text{L}$ . In the small bowel, biopsies will demonstrate mucosal infiltration by macrophages that lead to shortening and widening of villi. Liver biopsies will reveal the amastigotes in Kupffer cells, macrophages, or vessels accompanied by a portal chronic inflammatory cell infiltrate. Bone marrow biopsies show organisms within macrophages or in vessels. Skin biopsies show the amastigotes in dermal macrophages, connective tissue, or vessels.[552]

Visceral leishmaniasis in Brazil, with infection by *L chagasi*, occurs at a rate 10 to 100 times greater in HIV-infected persons. The most common findings include splenomegaly, weight loss, cough, fever, asthenia, and diarrhea. The viral load was usually  $>50,000$  copies/mL. Most patients recovered with therapy.[553]

Leishmaniasis in persons with HIV infection in endemic areas outside of Southern Europe, including cases caused by *L tropica* and *L braziliensis*, is likely more prevalent. Up to 30% of patients with visceral leishmaniasis in some parts of Ethiopia may also be HIV-infected. India and Brazil also have experienced increasing prevalence of leishmaniasis with HIV.[554]

Cutaneous and mucocutaneous leishmaniasis may also occur. The forms of this disease include localized cutaneous leishmaniasis (LCL), diffuse cutaneous leishmaniasis (DCL), disseminated leishmaniasis, leishmaniasis recidiva cutis (LR), and mucosal leishmaniasis (ML). Cutaneous disease marked by numerous nodular lesions filled with parasites is typical for patients with anergy. Associated organisms include *L donovani* / *infantum*, *L major*, and *L tropica*. [551,555]

Diagnosis of *L donovani* infection has been made primarily through bone marrow biopsy with culture or by identification of typical amastigotes in smears. Histologically, the amastigotes appear as round to oval 2 to 5 micron basophilic structures in the cytoplasm of macrophages with H&E stain. The organisms are positive with Giemsa stain. In some cases, the organisms can appear extracellularly in connective tissues or in vascular lumens. The macrophages may demonstrate organisms with a “double dot” appearance due to staining of both amastigote nucleus and kinetoplast with hematoxylin-eosin and Giemsa stains. Accompanying inflammation is typically minimal. By electron microscopy, the amastigotes are characterized by the presence within a cell membrane of a kinetoplast, large vacuole, microtubules, flagellar root, and eccentric nucleus with clumped chromatin.[556]

Additional diagnostic methods include serology, which is more likely to be positive in disseminated forms of leishmaniasis. Serum enzyme immunoassay, direct agglutination tests, and amastigote antigen tests have high sensitivity and specificity. PCR is also available for diagnosis and has high sensitivity and specificity. The leishmanin skin test does not distinguish

recent and remote infection and is best employed in epidemiologic studies. Microbiologic culture has 100% specificity, but only half to two-thirds of specimens may be positive.[555,557]

In some cases, leishmaniasis is the first severe infectious disease complicating HIV infection. Serologic titers indicative of *L donovani* infection are present in less than half of cases. Antimonial therapy may show an initial response followed by a chronic course with relapses, but a complete response is observed in a minority of cases. The presence of additional opportunistic infections during active leishmanial infections complicates diagnosis. In most cases, the stage of AIDS is late and the prognosis poor. Treatment is typically amphotericin B.[551]

**BRUCELLOSIS.--** Contact with animals or animal products such as unpasteurized milk may transmit *Brucella* organisms, which are small non-motile coccobacillary gram negative bacteria. *Brucella* mainly infects tissues of the mononuclear phagocyte system. Most infected persons are seropositive but asymptomatic. Symptomatic disease may become more aggressive in immunocompromised persons. Bone marrow involvement can lead to cytopenias, mainly anemia and leukopenia. Persons with HIV infection in endemic areas for brucellosis are more likely to be seropositive. Though they are no more likely to be anemic than HIV positive persons seronegative for brucellosis, they are more likely to have leukopenia.[558] The serologic evidence for *Brucella* infection along with HIV is more likely to occur in endemic areas for brucellosis, but symptomatic infection (0.1%) is still infrequent.[559]

**CHAGAS' DISEASE.--** In endemic locations from Mexico to South America, Chagas disease is caused by the protozoan parasite *Trypanosoma cruzi* spread via the reduviid bug. Patients with AIDS may also be at risk for infection with *T cruzi* or reactivation of remote *T cruzi* infections. Neurological involvement occurs in 70–85% of cases as a space-occupying lesion, encephalitis, or meningoencephalitis. The second most common manifestation is cardiovascular involvement in 10–55% of cases and characterized by myocarditis, which can be clinically silent. Neuroimaging studies may show space-occupying lesions similar to those described for *Toxoplasma* encephalitis, which is more likely to cause cortical or basal ganglia lesions, while chagasic encephalitis more often leads to white matter or subcortical lesions.[560]

Serological studies may indicate recent or remote parasite infections but cannot confirm disease reactivation and may be negative. Thick smears can be made from concentration of CSF to provide direct visualization of the flagellated and elongated trypomastigote stage of the parasite. Identification of the trypomastigotes in CSF is sufficient criteria for a definitive diagnosis of chagasic encephalitis. The diagnosis can be confirmed by lumbar puncture or intracranial biopsy. Microscopic examination shows multifocal, extensive, hemorrhagic necrotic encephalitis, with prominent obliterative angiitis. The amastigote forms of *T cruzi* can be present within glial cells, macrophages, and endothelial cells. Myocardial involvement with acute and/or chronic myocarditis may also be present. Treatment may include use of benznidazole or nifurtimox.[560,561]

**PARACOCCIDIOIDOMYCOSIS.--** The dimorphic fungus *Paracoccidioides brasiliensis* is endemic to South America, where it is found in the mycelial form in soil. It is acquired as an infection by inhalation of mycelial conidia. In tissues there is granulomatous inflammation in which the yeast cells have a double membrane and multiple budding forming a

"steering wheel" shape. Estrogen in women past puberty has a protective effect in preventing transformation to the invasive yeast form of this fungus. Infected persons may become asymptomatic carriers. The acute or subacute form is more common among children and young adults, and manifested by generalized lymphadenopathy and hematogenous dissemination with hepatosplenomegaly, skin, intestinal, and bone lesions. Adults more than 30 years of age typically have the chronic form, which manifests as pulmonary lesions, often associated with ulcerations in the oral, nasal, or laryngeal mucosa, as well as skin and visceral lesions.[562,563]

Persons infected with HIV are more likely to have reactivation of an infection with *P brasiliensis*, rather than a new infection. Such persons are less likely to have a history of living in rural areas or working in agriculture than non-HIV infected persons. The CD4 lymphocyte count is typically below 200/ $\mu$ L. The incidence of co-infection with HIV and *P brasiliensis* is estimated to be 1.4%. Such co-infections are more likely to predict rapid progression of disease.[562]

HIV infected persons are likely to develop a form of the disease that has elements of both acute and chronic paracoccidioidomycosis. In particular, they are more likely than HIV negative persons to develop cutaneous lesions, particularly ulcerated papular lesions that may have a necrotic center. Lymph nodes are most often involved, followed by respiratory tract, with pulmonary interstitial infiltrates. Ulcerated oral lesions can be present as well. Seronegativity for the fungus occurs in about half of cases, making identification of the yeast in tissue biopsies and sputum samples the best diagnostic method. Tissue involvement is characterized by poorly formed granulomas with prominent necrosis and numerous yeasts. Serologic testing may aid in diagnosis.[562,564]

Amphotericin B appears to be the most efficacious pharmacologic therapy for infections with acute features, while itraconazole may have usefulness in more chronic forms of this disease. The prevalence of *P brasiliensis* in HIV infected persons may be lower than expected because the use of trimethoprim-sulfamethoxazole as prophylaxis against *Pneumocystis* pneumonia is also effective against paracoccidioidomycosis.[564]

**STRONGYLOIDIASIS.**-- The parasite *Strongyloides stercoralis* has a worldwide distribution and is transmitted when infective larvae in contaminated soil penetrate the skin, but fecal-oral and sexual transmission are also possible. In immunocompromised hosts, it is possible for an uncontrolled autoinfection cycle to occur in which rhabditiform larvae in the intestine molt into filariform larvae that invade the intestinal wall and disseminate, producing a hyperinfection syndrome called disseminated strongyloidiasis which has high morbidity and mortality. The most frequent sites of involvement are the gastrointestinal tract, respiratory tract, skin, and central nervous system. The enteropathy that can occur with HIV infection may predispose to strongyloidiasis. Clinical findings include fever, cachexia, diarrhea, melena, abdominal pain, cough, and dyspnea. A complication is sepsis with enteric organisms. Mesenteric lymph node involvement may produce intestinal pseudo-obstruction. Chest radiographs often reveal bilateral interstitial infiltrates. Diagnosis is best made by identifying the larvae on stool examination, or by finding larvae in sputum or bronchoalveolar lavage specimens. Serologic testing by enzyme immunoassay can also be performed, and can be useful in patients with unexplained eosinophilia, though eosinophilia is often absent in AIDS patients. A prolonged course of thiabendazole may be useful therapy, but treatment failures are common. Hyperinfection may respond to ivermectin therapy.[565,566,567]

**SCHISTOSOMIASIS.**-- The parasites of the genus *Schistosoma*, particularly *S. mansoni* and *S. japonicum*, may co-infect persons with HIV. Schistosomiasis may exacerbate HIV infection via activation of a TH2 immune response. Parasites traversing the gut may reactivate viral replication in latently infected mast cells through multiple Toll-like receptor (TLR) signaling pathways. *S. hematobium* involving the urinary tract may spread to the genital tract where female genital schistosomiasis leads to ulceration of vulva, vagina, and cervix that increase the risk for sexual transmission of HIV.[568,569]

**MYCOPLASMA INFECTIONS AND AIDS.**-- In vitro, several *Mycoplasma* species have been observed to act synergistically with HIV to increase single-cell lysis of HIV-infected cells. It is not clear what role *Mycoplasma* infections play in vivo to produce pathogenic effects. Urogenital *Mycoplasma* infections may contribute to the mucosal disruption that facilitates sexual transmission of HIV. Both *M fermentans* and *M pirium* have been found in the peripheral blood of HIV-infected persons. Both *M fermentans* and *M penetrans* have been found in the urine of patients with AIDS, and *M fermentans* has been found in association with HIV nephropathy. The strain of *M fermentans* associated with HIV infection has sometimes been labeled the *incognitus* strain. In addition, *M fermentans* has been detected in tissues of the mononuclear phagocyte system (thymus, liver, spleen, lymph node) and in brain. Some cases of respiratory failure have been linked to *M fermentans*. *Mycoplasma genitalium* infection has been found in up to 10% of HIV infected women, often in association with *Neisseria gonorrhoeae* and *Chlamydia trachomatis* co-infections. Detection of mycoplasmas is made primarily with molecular probes to DNA.[570,571]

**ZYGOMYCOSIS (MUCORMYCOSIS) AND AIDS.**-- Infections with the Zygomycetes, more commonly seen patients with diabetes mellitus, are infrequent in association with AIDS, though they can be the initial opportunistic infection. This infection is usually acquired through inhalation of spores, though direct inoculation via injection drug use is possible, particularly in cases of dissemination. Sites of involvement are typically the skin, respiratory tract, and intracranial cavity. One of the most common forms of involvement is rhinocerebral. Most reported cases have occurred in AIDS patients whose risk factor is injection drug use. The predisposing factor for zygomycosis of ketoacidosis seen in patients with diabetes mellitus is absent with AIDS, but the predisposing factor of neutropenia seen in other immunocompromised patients may be present with AIDS. The CD4 count is usually low. The clinical course can range from acute fulminant progression over days to an insidious infection persisting for years.[572]

Diagnosis is best made by biopsy to identify the broad, short, branching non-septate hyphae that stain poorly with special stains such as Periodic acid-Schiff (PAS) and Gomori methenamine silver (GMS). The hyphae average 5 to 20 µm in width, and their very low cellular protein content gives hyphae an empty or hollow appearance on routine hematoxylin and eosin stain. The hyphae have rare septations and few branchings at random nonacute angles. Culture can be performed, but the yield is not great, and speciation does not influence therapy. Treatment includes surgical debridement of involved areas where accessible and administration of amphotericin B.[572]

**PENICILLIOSIS.**-- Infections with *Penicillium marneffei* are seen in HIV-infected persons living in Southeast Asia, the southern part of China, the Philippines, and Indonesia.

Most infected persons will have a CD4 lymphocyte count below  $100/\mu\text{L}$ . Exposure to soils, particularly in the rainy season, appears to be a risk factor. Infections tend to be disseminated. Clinical findings may include intermittent fever with or without chills, skin lesions, malaise, chronic productive cough, pulmonary infiltrates, anemia, hepatosplenomegaly, generalized lymphadenopathy, diarrhea, and weight loss. About two-thirds of patients will have skin lesions that may be the first sign of infection. The lesions are most frequent on the face, upper trunk, and extremities. The lesions may occur as papules, a generalized papular rash, necrotic papules, or nodules. Papules with central necrotic umbilication may resemble lesions of molluscum contagiosum. The skin lesions may resemble those of disseminated mycobacterial or fungal diseases.[489,573,574]

Diagnosis can be made via culture of blood. About half of patients will have a septicemia. Culture of tissues from affected sites can be performed, with the best yield from bone marrow, skin scraping, or lymph node biopsy. At autopsy, the most common sites of involvement are lymph nodes, liver, lung, kidney, and bone marrow.[573,574,575]

*P. marneffei* is found in the mycelial form in the environment, but it grows as a small spherical to oval 3 to 8 micron yeast form in tissues and appears very similar to, but slightly larger than, *H. capsulatum*, and slightly smaller than *P. jiroveci* in size with the Gomori methenamine silver (GMS) and periodic acid-Schiff (PAS) stains. Organisms are often abundant both intracellularly and extracellularly. The yeast form of the organism may be found both intracellularly within macrophages, and also in the extracellular environment. However, the small size of the organisms may cause confusion with cellular debris. The yeast cells resemble the spores of *H. capsulatum* but the distinctive central transverse septum is unique to *P. marneffei*. In addition, *H. capsulatum* undergoes division by budding while *P. marneffei* uses a process of "fission" to generate a septum and produce daughter cells. *Toxoplasma* tachyzoites do not bud or produce septae.[576]

Microscopically in immunocompetent hosts, there is typically a granulomatous reaction or a localized abscess. However, in immunocompromised hosts the tissue reaction includes necrosis without granuloma formation, and the predominant cell present is a macrophage engorged with the yeasts. Treatment may consist of itraconazole, ketoconazole, flucytosine, or amphotericin B. Most patients respond to initial therapy, but the relapse rate approaches 50%. [490,573,575]

**SPOROTRICHOSIS.**-- Infection with the dimorphic fungus *Sporothrix schenckii*, which has a worldwide distribution, is most commonly cutaneous from traumatic inoculation, with lesions that appear most often on the face, trunk, and extremities. Exposure to cats, with biting and scratching, is a risk factor. The lymphocutaneous form of the disease accounts for over 75% of all cases and is characterized by the emergence of a 2 to 4 cm indurated papule that develops about 7 to 30 days after inoculation of the fungus into the skin. Progressive induration leads to nodule formation with subsequent ulceration and crusting. Additional nodules appear in the lymphatic drainage from the site of inoculation. The lesions may soften and produce cutaneous fistulae. On microscopic examination, the lesions show granulomatous inflammation with epithelial hyperplasia and a round cell infiltrate of macrophages and plasma cells. Asteroid corpuscles with the yeasts are surrounded by eosinophilic proteinaceous material. Gomori methenamine silver staining can demonstrate the yeasts, which may be multiply present in macrophages, a pattern mimicking histoplasmosis.[577,578,579]

Inhalation of spores may lead to pulmonary disease from which dissemination can occur. Dissemination is uncommon, except in the setting of immunosuppression. Persons with AIDS can have widespread dissemination with more severe forms of sporotrichosis that include lymphocutaneous, pulmonary, meningeal, and osteoarticular involvement that is difficult to eradicate, even with lifelong antifungal therapy with amphotericin B. In HIV-positive patients, disseminated or meningeal sporotrichosis occurs when the CD4 lymphocyte count is  $<200/\mu\text{L}$ . [577,578]

In tissues and in blood agar culture medium at 37°C, the organisms form shell or cigar-shaped unicellular yeasts. Definitive diagnosis is made by fungal culture. The mycelia phase occurs in the environment and in microbiologic cultures at 28°C. In culture there are rapidly growing gray-colored colonies with short aerial hyphae. Microscopic examination shows thin, branched, hyaline, septated mycelia with formation of asexual spores (conidia) that are located on both sides of the hyphae forming rosettes at the end of unbranched sporophores. Dimorphism can be demonstrated by conversion of organisms to the yeast-like form on brain heart infusion (BHI) agar medium. [578,579]

**UNUSUAL YEAST PATHOGENS.**-- Adult patients with HIV infection may present with a variety of uncommon yeast infections including *Saccharomyces cerevisiae*, *Hansenula anomala*, and *Malassezia furfur*. *M. furfur* can produce tinea versicolor, infectious folliculitis, and catheter-associated fungemia. A fungemia most often develops in children receiving total parenteral nutrition via indwelling central venous catheters. [489]

*Trichosporon* spp., most often *T. beigeli* and *T. asahii*, can cause invasive infection in persons with AIDS. Infections may start on the skin of the head and neck. They may start in the gastrointestinal tract or at sites of vascular catheters and may cause fatal disseminated infections in immunocompromised patients, with findings of septicemia, renal failure, pulmonary infiltrates, multiple cutaneous lesions, and chorioretinitis. The organisms appear as small yeasts in tissues with Gomori methenamine silver stain. *T. beigeli* is typically resistant to amphotericin B but not to fluconazole. A mortality rate of 33% has been reported despite therapy. [580]

*Rhodotorula* organisms are noncandidal yeasts that can be found in soil, fresh water, fruit juice, and milk, or on shower curtains and toothbrushes. *Rhodotorula* is a basidiomycetous yeast with yellow to red pigments, multilateral budding cells, rudimentary pseudohyphae, and an occasional faint capsule. In culture the individual colonies are usually pink or coral in color, yeast-like, smooth, and sometimes mucoid in appearance. These organisms may cause fungemia in immunocompromised hosts. Most cases of *Rhodotorula* fungemia are associated with catheters, endocarditis, and meningitis. *Rhodotorula mucilaginosa* (also known as *Rhodotorula rubra*) is the most common cause of *Rhodotorula* species fungemia, followed by *Rhodotorula glutinis* and *Rhodotorula minuta*. Overall mortality from *Rhodotorula* fungemia is 15%. Amphotericin is used for treatment of *Rhodotorula* infections. [486]

**ACANTHAMEBIASIS.**-- Disseminated infections with free-living amoeba found in water have been rarely seen in association with AIDS. Amoebae of the *Acanthamoeba* and *Leptomyxida* forms have been identified. Ordinarily in non-immunocompromised persons, such organisms can produce slowly progressive granulomatous encephalitis that is nearly always fatal. However, only about half of such infections seen in AIDS patients have had neurologic manifestations. Instead, the most striking finding is skin involvement with pustules, indurated papules and plaques, cellulitis, and ulcers, most often on extremities and less frequently on the



face (nose) or torso. Involvement of the nose and nasal sinuses in many cases suggests that these sites may be portals of entry. Histologically, granulomatous, suppurative, or vasculitis-like inflammation may be present, but the similarity of ameba to macrophages makes diagnosis difficult. The organisms show vacuolated cytoplasm, an eccentric nucleus, and karyosome. Other organs may be involved, though less frequently. Skin involvement in patients with AIDS may be the only manifestation of acanthamebiasis, or it may precede additional organ involvement by weeks or months.[581]

**MALARIA.**-- Malaria is endemic to regions, including parts of Africa and Asia, where the prevalence of HIV infection is 1% or more of the population. There are 300 to 600 million malaria infections per year on earth, with 1 to 2 million deaths, making *Plasmodium* infection the most lethal parasitic infection. HIV infection can increase the risk and severity of malaria infection. *Plasmodium* organisms can cause CD4 T-cell activation and cytokine release that can stimulate HIV replication. Levels of HIV-1 RNA are higher in the blood of HIV-infected persons with concomitant malarial infection.[582,583]

The presence of HIV infection appears to increase the incidence of parasitemia with *Plasmodium falciparum* infection, which can lead to more clinically evident malaria and severe malaria. Advanced immunosuppression may increase the risk of malaria treatment failure. Malaria infection is more frequent and often more severe in HIV-positive pregnant women. Placental malaria may increase the risk for pregnancy loss, premature birth, and growth retardation. Placental macrophages upregulate CCR5 expression when malaria is present. HIV-infected patients have higher rates of malaria treatment failures.[582,583]

**PARVOVIRUS 4.**-- Parvovirus 4 (PARV4) is a *Parvoviridae* DNA virus that is likely transmitted parenterally. It is most often found in association with injection drug usage. There is often co-infection with hepatitis C virus. There are no specific pathologic findings associated with PARV4, but it may modify co-infections.[584]

**ZOONOTIC DISEASE.**-- There are a number of infections that occur in patients with HIV that can potentially be transmitted from animal sources. The agents include *Cryptosporidium*, *Microsporidium*, *Campylobacter jejuni*, *Giardia lamblia*, *Salmonella* species (not *typhi*), *Rhodococcus equi*, *Bartonella henselae*, and *Listeria monocytogenes*. Of these, only *Bartonella* appears to be acquired in patients with HIV infection mainly from an animal source (cat). Even so, the risk for zoonotic transmission of any infection to an HIV-infected person is small. The benefits of animal companionship outweigh the risks to patients and prohibition of pet ownership by HIV-infected persons is not warranted.[585]



## CHAPTER 4 - NEOPLASMS ASSOCIATED WITH AIDS

### KAPOSI SARCOMA

Several forms of Kaposi sarcoma (KS) exist: classic, endemic, immunosuppression or transplantation-associated, and epidemic. The classic form of KS most often appears in persons of Eastern European or Mediterranean ancestry, has a male: female ratio of 15:1, and has a median age of 64 years. Classic KS typically appears on skin of hands and feet and progresses up arms and legs. Lymphedema occurs in some cases. Visceral or mucosal involvement appears in 10% of cases. The endemic form of KS is seen in sub-Saharan Africa and typically appears on the skin of limbs in adults. An aggressive lymphadenopathic form of KS can be seen in children. The immunosuppressive or transplantation-associated form of KS is most likely to be seen in persons with ancestry from areas in which classic KS occurs. It appears on average 2.5 years after transplantation. The male: female ratio is 2 to 4:1. In half of cases there is mucosal, nodal, or visceral involvement. The epidemic form of KS is associated with HIV infection.[586]

Kaposi sarcoma (KS) was rarely seen prior to the AIDS pandemic but became one of the most common diagnostic diseases seen with AIDS (Table 5). The incidence of KS is about 1 in 100,000 in the general population. Prior to antiretroviral therapy, the incidence of KS with AIDS was about 1 in 20, and up to 1 in 3 for men having sex with men.[587] Kaposi sarcoma occurs most frequently in homosexual and bisexual males. Kaposi sarcoma is infrequently seen in children and in persons whose risk for AIDS is parenteral exposure to HIV. Kaposi sarcoma remains less common in women than men.[510]

The incidence of KS appears to have declined by 10% per year in the U.S. in the decade of the 1990's. The increasing use of antiretroviral therapy regimens appears to have made the greatest difference. In places where antiretroviral therapy is widely available, the reduction in the incidence of KS has ranged from 33 to 95%.[510]

A gamma human herpesvirus called human herpesvirus 8, (HHV-8) has been identified in skin and visceral lesions in 90% of all forms of KS, including classical, iatrogenic, endemic, and AIDS-associated forms. Thus, it has been called Kaposi sarcoma-associated herpes virus (KSHV). KSHV appears to be restricted to infection of cord blood mononuclear cells, adult CD19 positive B cells, macrophages, and endothelial cells.[588]

KSHV infection has a latent and lytic phase. KSHV first attaches to receptors on circulating endothelial cells. Viral particles are then released into endothelial cell cytoplasm, where they are transported to the cell nucleus. It remains there as a circular episomal DNA copies that can segregate during mitosis similar to host cell chromosomes. KSHV can remain latent, expressing few genes, and without release of virions. Deterioration of the host antiviral response can trigger a lytic phase with release of virions to infect multiple target cells. KSHV also downregulates  $T_H1$  immune responses while hyperactivating  $T_H2$  responses. The inflammatory  $T_H2$  response releases cytokines that promote growth of spindle cells. Inflammatory cells release VEGF and IL-6 that promote angiogenesis.[589]

KSHV has also been detected in the KS lesions of HIV negative homosexual males. It is phylogenetically similar to human herpesviruses 6 and 7.[590] KSHV can be identified in the progressive stages of KS as well, but it can also be found in about a third of tissues of AIDS patients without KS, suggesting that it is disseminated and plays a permissive role in

development of KS. This agent may rarely be found in tissues of patients with AIDS who do not yet have a diagnosis of KS.[591]

KS is therefore an angioproliferative disorder resulting from immune dysregulation. The early lesions of KS are thought to be reactive and, theoretically, reversible. Most KS lesions are polyclonal. However, the continued immune system activation with KSHV infection drives the cellular proliferative process to true neoplasia, with evolution from polyclonal proliferation to monoclonal neoplasm. Cellular oncogenic alterations including mutations in p53, KRAS, or BCL-2 overexpression, or gene amplification, occur only in late-stage advanced disease.[587] The HIV Tat protein also appears to play a role by stimulating growth and angiogenesis.[592]

In non-endemic areas the HHV-8 agent (KSHV) is seen as a sexually transmissible disease that can occur independently of HIV infection, and it accounts for the increased incidence of KS in homosexual males. The prevalence of HHV-8 can be more than 30% among homosexual males and correlates with the number of sexual partners. In Africa, KSHV is also spread as a congenital infection and in childhood. Primary infection with KSHV is asymptomatic.[586] KSHV can be identified in peripheral blood mononuclear cells with a higher frequency in persons with KS than without KS. It can be detected in saliva and semen. This agent can still be detected despite therapy with anti-herpesvirus drugs. However, the incidence of KS decreases with antiretroviral therapy.[593]

Neither cytomegalovirus (CMV) nor human herpesvirus-6 (HHV-6) infection appears to be associated with development of KS.[594] The increased prevalence of KS in men, typical those whose risk factor for HIV infection is sexual intercourse with other males, over women is explained by the lower prevalence of HHV-8 seropositivity in HIV-infected women.[595]

Though the skin is involved in over three fourths of cases and is often the site of initial clinical presentation, skin is usually not the sole site of involvement. Visceral KS (involving one or more internal organs sites) is also present in three fourths of cases, but may not be diagnosed prior to autopsy. Visceral involvement frequently includes the lung, lymph nodes, and gastrointestinal tract. In fewer cases, KS appears in the liver or genitourinary system. Kaposi sarcoma is infrequent in adrenal, heart, and spleen; KS is rare elsewhere (Table 5). Though multifocal, KS appears to be monoclonal in origin, typical of a true neoplasm.[596]

Bronchoscopic and gastrointestinal endoscopic biopsy may yield a diagnosis of KS, but these methods are hampered by sampling error from the focal nature of KS lesions. Though it is common for KS to become widely disseminated, some patients may have only one site or focus of involvement, not necessarily skin. The natural history of KS, however, is progression over time to involve multiple sites in multiple organs.

A complete description of gross and microscopic appearances of KS is given in the section of organ system pathology on skin. To summarize, KS lesions grossly are red to red-purple. The lesions range from a flat patch to slightly raised plaques to nodules. Lesions larger than 0.5 cm are usually nodular. Microscopically, KS is characterized by atypical large spindle to fusiform cells that line slit-like vascular spaces. Red blood cell extravasation, hemosiderin pigmentation, and hyaline globules usually accompany the spindle cell proliferation. The lesions have irregular, infiltrating margins. Sometimes the vascular spaces are dilated and sometimes sheets of KS spindle cells have inapparent vascularity. Kaposi sarcoma has a propensity to infiltrate around large vascular structures, near epithelial or mesothelial surfaces, or near the capsules of organs.[586]

Small, early KS lesions or KS that is ulcerated or inflamed can be difficult to diagnose. Granulation tissue can have a strikingly similar appearance. Hemangiomas may grossly--and

sometimes microscopically--resemble KS. When uncertain of the diagnosis, it is best to be conservative. If the lesions really are KS, they will progress over time.

A variety of chemotherapeutic regimens have been employed against KS. It is a systemic disease that can be partly controlled, but not cured. Local resection of limited lesions may be undertaken for cosmetic reasons. Nodular lesions may respond to injection of vincristine. Radiotherapy to cutaneous lesions may be employed to control lesions causing pain, bleeding, and edema, with response rate over 90% and remission rate over 70%. Systemic chemotherapy has been used to control KS that advances despite antiretroviral therapy and causes life-threatening visceral involvement. Partial response rates of 30 to 70% have been observed for single agents such as vincristine. First line therapy to induce remission can include pegylated liposomal doxorubicin or daunorubicin citrate liposome. Patients failing first line therapy may be treated with paclitaxel. Valgancyclovir may be useful in reducing KSHV viral load and may help prevent KS.[510] The use of antiretroviral therapy (ART) may slow progression of KS.[589]

Treated KS lesions may show absence of atypical spindle cells with only a focus of collagenous connective tissue remaining. More often, treatment leads to only partial regression, with decreased numbers of atypical spindle or epithelioid cells, along with fibrosis, round cell infiltrates, hemosiderin, and irregular vascular spaces. Diagnosis of such lesions is difficult and is suggested at low power by the presence of a localized nodule or infiltrate.[597]

The presence of KS appears to accelerate the clinical course of HIV infection. Opportunistic infections develop earlier and more often in patients with KS, with significantly shorter survival. However, death directly related to lesions of KS occurs in a minority of persons with AIDS carrying a diagnosis of KS, usually as a result of massive pulmonary involvement (Table 5).[598,448] KS exhibits a less aggressive presentation in patients already receiving antiretroviral therapy (ART) compared to patients who are not receiving ART at the time KS is diagnosed. The natural history and outcome do not appear to be influenced by the initiation of ART before the development of KS.[599]

## MALIGNANT LYMPHOMAS

As in other immunodeficiency diseases, the risk for malignant lymphoma is increased with AIDS. The incidence of non-Hodgkin lymphoma (NHL) with AIDS is 72.8-fold (relative risk >100), while the risk for Hodgkin lymphoma (HL) is 11.5 fold (relative risk 8). There appears to be a 5-fold risk for multiple myeloma with AIDS.[600] The organ system involvement of AIDS-associated malignant lymphomas occurs in two major patterns: (1) systemic lymphomas comprising a heterogeneous group of cell types and organ involvement and (2) central nervous system lymphomas. In the former group, more than one organ may be involved at a time, and extranodal involvement is common (Table 5). The typical variety of lymphomatous neoplasm seen with AIDS is an intermediate to high grade NHL of B-cell origin.[421,601]

**NON-HODGKIN LYMPHOMAS.**-- Persons infected with HIV develop non-Hodgkin lymphoma (NHL) more frequently than the general population. The presence of the chemokine receptor variant CCR5 delta32 appears to significantly lower the risk in persons with HIV-1 infection while presence of the SDF1-3'A chemokine receptor variant doubled the risk when heterozygous and led to a fourfold increase in NHL in homozygotes.[602] The use of antiretroviral therapy (ART) results in a reduction in the incidence of NHL in HIV infected persons.[603]

AIDS-related lymphomas are thought to arise when a variety of predisposing factors promote polyclonal B-cell proliferation. These factors include: diminished immunosurveillance with decreasing CD4 lymphocyte counts, destruction of follicular dendritic cells leading to interference with apoptosis and allowing B-cell clonal proliferation, chronic antigen stimulation marked by polyclonal hypergammaglobulinemia, and cytokine deregulation. This B-cell proliferation is best characterized clinically as persistent generalized lymphadenopathy (PGL). Over time, B-cell oligoclonal expansions arise within this PGL pattern. A monoclonal proliferation eventually arises from a single clone that has accumulated sufficient genetic abnormalities.[601,604]

Viral infections with Epstein-Barr virus (EBV) and/or Kaposi sarcoma-associated herpesvirus (KSHV) commonly contribute to pathogenesis of most HIV-associated lymphomas. During latent infection, EBV and KSHV express proteins and non-coding RNAs that alter the cell cycle, promote cell proliferation, and inhibit apoptosis. Such effects aid in viral survival in host cells, and in persons with an intact immune system, the proliferative viral effects are curtailed, but with immunodeficiency viral-induced cell proliferation promotes development of malignancies, including diffuse large B-cell lymphomas and most Burkitt lymphomas, primary effusion lymphomas, extracavitary solid primary effusion lymphomas, plasmablastic lymphomas of the oral cavity type, and most Hodgkin lymphomas are associated with EBV infection. All primary effusion lymphomas and extracavitary solid primary effusion lymphomas occur with KSHV. All large B-cell lymphomas associated with multicentric Castleman disease occur with KSHV.[605,606]

The clinical characteristics of non-Hodgkin lymphomas vary somewhat. About 80% of NHL's in AIDS arise systemically, either nodally or extranodally, while 20% arise in the central nervous system. AIDS patients with systemic lymphomas are likely to have had previous opportunistic infections and be severely immunosuppressed with low CD4 lymphocyte counts at

the time of presentation. For persons with CNS lymphomas, presenting symptoms are often non-localizing and include confusion, lethargy, and memory loss. Less frequent findings include hemiparesis, aphasia, seizures, cranial nerve palsies, and headache. Radiographic findings with either magnetic resonance imaging (MRI) or computed tomographic (CT) scans include single or multiple discrete ring-enhancing lesions very similar to those seen with toxoplasmosis. In contrast, patients presenting with systemic lymphomas are generally not as immunosuppressed, but typically have widespread extranodal disease.[601,604]

Grossly, non-Hodgkin lymphomas with AIDS may appear as small infiltrates, focal nodular lesions, or larger tumor masses. Multicentric lesions may appear in the same organ. Smaller lymphomatous lesions appear white to tan with irregular borders, while larger masses with definable margins are accompanied by necrosis and hemorrhage leading to appearance of a variegated (red to brown-black to white) cut surface resembling a strawberry or chocolate sundae.

Microscopically, systemic non-Hodgkin lymphomas with AIDS fall into two broad categories, both of B-cell origin. About 30% are high-grade B-cell (small non-cleaved) Burkitt-like lymphomas (in the REAL classification), called intermediate grade and classified as small noncleaved-cell (SNCLL) lymphomas (Burkitt or Burkitt-like lymphomas) in working formulation classification, and called Burkitt lymphoma with or without plasmablastic differentiation (in Kiel classification). They may also be called AIDS-related Burkitt lymphomas. The second broad category of non-Hodgkin lymphoma includes virtually all of primary CNS lymphomas seen with AIDS and about 70% of systemic lymphomas in AIDS. This category is composed of large cells that are best described as diffuse large B cell lymphoma (in the REAL classification), which can be either large cell immunoblastic lymphomas in working formulation classification (immunoblastic with or without plasmacytic differentiation in Kiel classification) or large noncleaved-cell lymphomas in working formulation classification (centroblastic diffuse in Kiel classification).[601,607]

The high grade nature of most AIDS associated lymphomas helps in diagnosis, which can be difficult because of routinely employed biopsy procedures that may yield a small amount of tissue. Whether the tissue is obtained by stereotaxic brain biopsy, bronchoscopic lung biopsy, or endoscopic gastrointestinal biopsy, small tissue samples are usually obtained. Immunohistochemical staining may aid in defining a monoclonal cell population consistent with a neoplastic proliferation. Staining with common leukocyte antigen (CLA) may be useful in identifying the nature of lymphomatous infiltrates when necrosis is extensive.

Malignant non-Hodgkin lymphomas lead to the death of adult AIDS patients in over half of cases when this neoplasm is present at autopsy. Organ involvement leading to death is divided almost evenly among the central nervous system, gastrointestinal tract, and respiratory system. Chemotherapy protocols usually do not significantly alter the course of malignant lymphomas in patients with AIDS. There may be a short initial response, but virtually all lymphomas relapse, with an average time from diagnosis to death of less than a year.[448,607]

**BURKITT LYMPHOMA (BL).--** The BLS consist of cells having round nuclei with one or more prominent nucleoli and scant cytoplasm. The cells comprise diffuse sheets that form a discrete mass or irregularly intersect and infiltrate normal tissues without significant necrosis. Within the sheets of lymphomatous cells, uniformly distributed macrophages containing phagocytized debris are present, and occasional mitoses are seen. Plasmablastic features including eccentric nuclei and well-defined Golgi zone may occur. Cytologic features of BL

include monotonous, intermediate-sized lymphocytes that lie singly. Their nuclei are similar or smaller than those of macrophages, round-to-oval with well-defined nuclear borders, with coarse chromatin, and 2–5 small but conspicuous nucleoli per nucleus. The BL cells contain scant to moderate amounts of blue, vacuolated cytoplasm. The cytoplasmic vacuoles contain a neutral lipid best seen with Romanowsky stain. Tingible body macrophages, mitotic figures, and apoptosis are often seen. Aspirates of BL are usually cellular. [609,607]

The AIDS-related BLS can occur when the CD4 lymphocyte count is low but sustained and can even be the initial manifestation of AIDS. Nearly all have a t(8;14) bringing the *MYC* locus in approximation with the immunoglobulin heavy chain (IgH) locus. *TP53* tumor suppressor gene loss occurs in 60% of them, while about 30% of these lymphomas demonstrate Epstein-Barr virus (EBV). Though none demonstrate *BCL-6* gene rearrangements, small mutations in of the *bcl-6* gene can be found in 60% of cases. These intermediate grade lymphomas tend to occur at a younger age than the DLBCLs. [600,606]

**DIFFUSE LARGE B-CELL LYMPHOMA (DLBCL).**-- The DLBCLs in AIDS are mainly of the immunoblastic type, consisting of cells having moderate to large amounts of cytoplasm with or without plasmacytic features of eccentric nuclei and basophilic cytoplasm, large round to oval nuclei, and prominent single nucleoli. These large cell types have less cytoplasm along with one or more peripheral nucleoli within a nucleus with finely dispersed chromatin. Necrosis is often a prominent feature, and mitoses are frequent. Most are EBV positive.[601,606,607]

The AIDS-related DLBCLs typically occur later in the course of AIDS, and the risk increases markedly as the immune system fails and the CD4 count is low and declining. Infection with EBV can be demonstrated in 70 to 80% of cases. Many have molecular alterations of the *bcl-6* proto-oncogene, including mutations of the 5' regulatory sequences. Rearrangements of the *c-myc* proto-oncogene may be seen in about 20% of AIDS-related DLBCLs, when mutations of *p53* are rarely seen.[601,604]

The 20% of NHL's seen in the central nervous system are of the DLBCL variety. They typically occur late in the course of AIDS when the CD4 count is low and declining. Virtually all of them arise in the setting of EBV infection and they are essentially an expansion of EBV-infected B-lymphocytes. Mutations in *bcl-6* regulatory regions may also be present.[601,604]

**HODGKIN LYMPHOMA.**-- Hodgkin lymphoma (HL) may be seen with increased frequency in persons infected with HIV, but HL is not part of definitional criteria for diagnosis of AIDS. There is a 10-fold risk for HL with HIV. Most are males, with a median age of 34 years. HL tends to have a more aggressive course in patients infected with HIV. Injection drug users constitute the risk group most frequently affected. Hodgkin lymphoma with HIV infection is more likely to be stage III or IV at presentation (74 to 92%), to have a mixed cellularity subtype, to have bone marrow involvement, to have noncontiguous spread of tumor, to have numerous Reed-Sternberg cells, and to show an association with Epstein-Barr virus (EBV) infection. There is often a prominent fibrohistiocytoid stromal cell proliferation in the involved lymph nodes. Patients with HIV-associated HL are more likely (70 to 96%) to have "B" symptoms including fever, night sweats, and/or weight loss >10% of normal body weight. HL in HIV infected persons is more likely to be accompanied by anemia, leukopenia, or thrombocytopenia. Extranodal involvement, including bone marrow, liver and spleen, is more likely to occur.[608]

Cytologic features of classic HL include the presence of a minority of Reed-Sternberg cells and their variants, which are the true neoplastic cells. The majority of the lesion consists of an inflammatory background of varying numbers of small lymphocytes, plasma cells, neutrophils, eosinophils and macrophages. In EBV-associated cases, the macrophages may exhibit prominent epithelioid features and may form granulomas, but necrosis is rare. The classic Reed-Sternberg cell is binucleate (mirror images) and the enlarged nuclei have pale, finely granular chromatin, prominent red macronucleoli and a moderate amount of cytoplasm. Mononuclear variants of Reed-Sternberg cells have a large, irregular or polylobated nucleus with a very prominent, single red macronucleolus. The lymphocytic and histiocytic (L&H) variants, called ‘popcorn cells’, have vesicular, polylobulated nuclei and distinct, small, usually peripheral nucleoli without perinucleolar halos. Aspirates may be hypo- or hypercellular based upon the amount of associated sclerosis.[609]

HL in HIV infected persons is more likely to present earlier in the course of infection, when the CD4 lymphocyte count is higher, than in persons with non-Hodgkin lymphomas. Generalized lymphadenopathy is likely to be present, and the clinical picture may resemble persistent generalized lymphadenopathy (PGL). However, mediastinal lymphadenopathy is less frequent in HIV infected patients with HL. Response to therapy and survival with HL is lessened when HIV infection is present. Predictors of longer survival with HL in HIV infected persons include absence of prior AIDS diagnosis (20 versus 7 months) and a CD4 count  $>250/\mu\text{L}$  (38 versus 11 months). The use of antiretroviral therapy (ART) can improve control of infection and allow for more aggressive chemotherapy.[608,610]

**PRIMARY BODY CAVITY-BASED LYMPHOMAS.**-- A small number of AIDS-associated NHL's may appear only as malignant cells within body cavity effusions without evidence for a mass lesion, organomegaly, or lymphadenopathy. These primary body cavity-based lymphomas (BCBLs), also known as primary effusion lymphoma (PEL), have occurred in pleural effusions, pericardial effusions, or ascites. The prognosis is poor. They are associated with the same herpesvirus-like agent, known as Kaposi sarcoma-associated herpesvirus (KSHV) as lesions of Kaposi sarcoma. About 90% of PELs contain both EBV and KSHV. However, there is no associated *c-myc* gene rearrangement, similar to the high-grade non-Hodgkin lymphomas seen elsewhere.[606]

The primary body cavity based lymphomas are of a large cell variety, often with some features of plasma cell differentiation. The large cells have round to irregular nuclei, prominent nucleoli, and varying amounts of deeply basophilic cytoplasm with occasional vacuolated cells. The cells may appear immunoblastic to plasmablastic to anaplastic. The anaplastic cells may resemble Reed-Sternberg cells found in Hodgkin lymphoma. PEL cells appear less pleomorphic in histologic sections than in cytopsin preparations. The proliferation rate is high as indicated by the presence of numerous mitotic figures. There may be a “starry-sky” pattern. Immunohistochemical features of PEL cells include a “null” lymphocyte phenotype: CD45 is expressed, but not BCL-6 or the typical B or T lymphocyte markers. Lymphocyte activation markers CD30, CD38, CD71, epithelial membrane antigen, and plasma cell differentiation (CD138) are often present. Definitive diagnosis requires demonstration of HHV-8 in the neoplastic cells. The prognosis for PEL is poor.[611,612] Some high grade B cell non-Hodgkin lymphomas that are HHV-8 positive occur as solid masses, and their morphologic and immunophenotypic characteristics and prognosis are similar to PEL. They may be termed extracavitary PELs.[613]

**MALT LESIONS.**-- Mucosa-associated lymphoid tissue (MALT) lesions are lymphoid proliferations that typically occur at extranodal sites such as the gastrointestinal tract, bronchi, and salivary glands. Such MALT lesions have been described in association with both adult and pediatric AIDS. The spectrum of lesions has included myoepithelial sialadenitis (MESA) with low-grade MALT lymphoma, low-grade MALT lymphoma, diffuse large cell lymphoma, and atypical pulmonary lymphoid hyperplasia and lymphoid interstitial pneumonitis complex. These lesions appear to follow an indolent course in children. Unlike the MALT lesions seen in other immunocompromised adults that regress when immune suppression is reduced, as in transplant recipients, those in adults with AIDS have an aggressive course with poor prognosis.[614,615]

**ANAPLASTIC LARGE CELL LYMPHOMAS.**-- Several peripheral T-cell lymphoma (PTCL) subtypes have been described in association with HIV infection, most often PTCL-not otherwise specified, and anaplastic large cell lymphoma (ALCL). Such HIV-associated ALCLs tend to occur in young males, arise at extranodal sites, and have an aggressive course, particularly with lack of anaplastic lymphoma kinase (ALK) expression and with low CD4 cell count. The most common tissue sites of involvement are lung, soft tissue, liver, spleen, skin, and bone marrow. Positive immunohistochemical markers in cells of ALCL include CD30 in all cases and the following in 60% or more of cases: CD2, CD3, CD4, CD5, CD43, CD45, and CD45RO. All cases have TCR gene rearrangement. Though there is often an initial good response to chemotherapy, the prognosis is poor, with median survival of 5 months.[616]

**CUTANEOUS LYMPHOMAS.**-- Cutaneous non-Hodgkin lymphomas may be seen in patients with AIDS. Though mycosis fungoides is the most common primary cutaneous lymphoma in immunocompetent persons, such lesions are rarely seen in association with AIDS. Two types of cutaneous lymphoma are seen with AIDS: CD30+ T-cell lymphomas and high grade B-cell lymphomas. The cutaneous T-cell lymphomas with AIDS are similar to those in non-HIV-infected persons and frequently present as localized nodules that demonstrate occasional spontaneous regression. Microscopically, they are anaplastic large cell lymphomas that mark with Ki-1 (CD30); they may appear in soft tissues and visceral sites as well. The diffuse large B-cell cutaneous lymphomas with AIDS may remain localized for months without extra cutaneous spread, but do not regress. AIDS patients present with either T- or B-cell cutaneous lymphomas at an advanced stage and typically die from opportunistic infections.[617,618]

**PLASMABLASTIC LYMPHOMA (PBL).**-- THIS distinctive type of non-Hodgkin lymphoma is typically found in persons infected with HIV at sites including oral cavity, liver/spleen, lymph nodes, gastrointestinal tract, nose or paranasal sinuses, skin, anal canal, lungs, bone and bone marrow, gonads, CNS, and mediastinum. Half of cases are found in the oral cavity and the lesions typically involve the mucosa or gingiva and may spread to underlying structures. PBL is an aggressive, diffuse, B-cell derived lesion that often leads to death within a year of diagnosis despite aggressive therapy.[619,620]

Immunohistochemical staining shows minimal or absent expression of the leukocyte common antigen and CD20, the B-cell antigen, while there is diffuse and strong positivity with the plasma cell markers CD38 and CD138, as well as monotypic cytoplasmic immunoglobulin. Epstein-Barr virus can often be identified in the tumor cells. *MYC* gene rearrangements can be



found in nearly half of cases, and are associated with worse outcome. Most cases present as stage I or stage IV lesions. Complete response to chemotherapy is observed in over half of cases. Cytologically there are large monomorphic cells resembling plasmablasts or immunoblasts with fairly abundant basophilic cytoplasm, eccentrically situated nuclei with single or multiple nucleoli, and a perinuclear hof. Lesions are usually cellular with apoptosis, tingible body macrophages, and increased mitotic figures. Tingible body macrophages impart a “starry-sky” appearance. The malignant lymphocytes are usually larger and more pleomorphic than plasma cells of myeloma.[606,609]

**DIFFUSE INFILTRATIVE LYMPHOCYTOSIS SYNDROME.--** Although not a lymphoma, about 3% of HIV positive patients have visceral organ lymphocytic infiltrates that may mimic lymphoma. This condition, called diffuse infiltrative lymphocytosis syndrome (DILS) is seen more frequently in Blacks and in persons with risk factor of homosexuality. DILS is characterized by a persistent CD8 lymphocytosis and multivisceral CD8 lymphocyte infiltration. The most common site of involvement is the parotid gland, leading to bilateral facial swelling and xerostomia. Less commonly involved are lung, muscle, and liver. Some patients may also manifest either a peripheral neuropathy or polymyositis. The prevalence of DILS appears to be decreasing with use of antiretroviral (ART) therapy.[621,622,623]

**MULTIPLE MYELOMA.--** Although hypergammaglobulinemia is a common finding in persons with AIDS, monoclonal gammopathy is not. Both transient and persistent paraproteinemias have been observed in HIV-infected patients. The paraproteins have high-titer anti-HIV activity. The same molecular mechanisms that give rise to non-Hodgkin lymphomas of B-cell lineage can also give rise to myelomas, though the reduced T-cell function with HIV infection may diminish the stimulus to plasma cell differentiation.[624] There is a 5-fold risk for myeloma with AIDS (relative risk of 5).[600]

## OTHER NEOPLASMS

In adults, the only neoplasms that are part of definitional criteria for AIDS are Kaposi sarcoma, non-Hodgkin lymphomas, and cervical squamous cell carcinomas.[421] Overall, the incidence for other malignant neoplasms with AIDS is 2.7 times that of the general population.[587] Persons who are HIV infected have a younger age at diagnosis (47 years) for malignant neoplasms that are not AIDS-defining, compared with non-HIV infected persons with the same neoplasms (60 years), and immunosuppression with loss of immune regulation may play a role in this phenomenon.[625] In the era of antiretroviral therapy (ART) with increasingly prolonged survival of persons infected with HIV, malignancies now account for over a fourth of all deaths.[626]

An epidemiologic study of over 50,000 HIV-infected persons followed from 1992 to 2003 indicated the incidence of the following cancers was significantly higher (using standardized rate ratios, or SRRs) than the general population: anal 42.9, vaginal 21.0, Hodgkin lymphoma 14.7, liver 7.7, lung 3.3, melanoma 2.6, oropharyngeal 2.6, leukemia 2.5, colorectal 2.3, and renal 1.8. The incidence of prostate cancer was significantly lower among HIV-infected persons than the general population (SRR, 0.6). Only the relative incidence of anal cancer increased over time.[627]

Smooth muscle tumors, known as AIDS-associated myoid tumors (AIDS-MTs), may be seen in children and adults. They are most often seen in children with HIV infection, where they are a frequent type of neoplasm. The most common locations for childhood smooth muscle neoplasms include central nervous system, soft tissues, liver, lung, and adrenal. In adults, the most common locations for EBV associated smooth muscle tumors are brain, liver, spinal cord and adrenal gland, with multifocality and slow disease progression the typical characteristics. Other locations in adults include the head and neck region, as well as soft tissues of leg and back. [628,629] In children, leiomyosarcomas are part of definitional criteria for AIDS.[420] The relative risk for leiomyosarcoma in children with AIDS is 10,000.[600]

AIDS-MTs are variably aggressive but not often directly a cause of death. Many of these lesions are associated with Epstein-Barr virus (EBV) infection, as demonstrated by the appearance of EBV-encoded RNA (EBER) within the neoplastic cells. Histologic types associated with EBV positivity include leiomyoma, smooth muscle tumor of uncertain malignant potential (STUMP), leiomyosarcomas, and myopericytoma (MPCT). The EBV-negative types include leiomyosarcoma, angioleiomyoma, leiomyoma, and STUMP. Malignancy in AIDS-MTs is characterized by hypercellularity, pleomorphism, increased mitoses and necrosis. Leiomyosarcomas that are EBV-positive show a fascicular architecture, while EBV-negative leiomyosarcomas show marked pleomorphism. All AIDS-MTs are desmin, muscle-specific actin, smooth muscle actin, and h-caldesmon positive by immunohistochemical staining, though EBV-positive MPCTs and some EBV-positive leiomyosarcomas have aggregates of desmin-negative round and oval cells.[629,630]

Squamous epithelial lesions including dysplasias and carcinomas can be observed in persons with HIV infection. The relative risk for cervical cancer is 3 and for anal cancer 30 with AIDS.[600] One in five HIV-infected women coinfectd with HPV, without evidence for cervical lesions, may develop a squamous intraepithelial lesion within three years, which emphasizes the importance of Pap smear screening in this population. Cervical dysplasias in women with HIV infection are more common than in non-HIV-infected women.[631]

Particularly among males having anal intercourse, there is an increased incidence of anorectal epithelial dysplasias and anorectal squamous carcinomas. The relative risk for anal carcinoma with HIV infection is 14.9 to 60.9 overall, and 80.3 in men having sex with men. Penile cancer is more frequent in AIDS, but the association is not strong.[587] Human papillomavirus (HPV) infection plays a major role in development of these lesions in males and females. Squamous epithelial carcinomas in AIDS are more likely to be multifocal and extensive and more difficult to treat.[632,633]

The risk for development of skin cancers appears to be increased in HIV-infected individuals. Persons with AIDS tend to have a higher risk for development of the non-melanoma skin cancers squamous cell and basal cell carcinoma than the general population, with relative risk of 2.1 to 3.5 compared with HIV-uninfected persons. These cancers may be more aggressive. The degree of immunosuppression does not appear to play a role in the appearance of these neoplasms. The relative risk for Merkel cell carcinoma is 13 with HIV infection.

Dysplastic nevi and melanoma have been reported in HIV-infected patients with no prior family history of melanocytic lesions. The median age appears to be lower, and there is a greater tendency for thicker lesions with early metastasis, compared to non-HIV-infected persons, particularly when the CD4 lymphocyte count is lower.[632,633]

Lung cancers are seen with increased frequency in association with HIV infection, accounting for 5% of all deaths, and 15% of cancer-related deaths. The relative risk is 1.4 to 2.6 compared with HIV-negative persons. HIV-infected persons get lung cancers at a younger median age, and they are most likely to have an adenocarcinoma, and overall non-small cell carcinomas account for 67 to 86% of cases, while small cell anaplastic carcinomas in this population are much less common than in the general population. The most important risk factor is smoking, but lung cancer risk does not appear to be associated with a reduction in CD4 lymphocyte count or antiretroviral therapy. Over 80% of HIV-infected patients with lung cancer present with advanced stage III or IV lesions that are inoperable.[633,634] Chronic and recurrent pulmonary infections, including those with *Mycobacterium* and *Pneumocystis*, may contribute to lung carcinogenesis.[635]

Oropharyngeal carcinoma in persons with HIV infection has a relative risk of 1.9 to 4.1 compared with non-infected persons. Risks include human papillomavirus (HPV) infection, tobacco, alcohol, and men with male sexual partners. The HPV-related cancers tend to be less aggressive than those associated with smoking.[633]

Colonic adenocarcinoma in HIV-infected persons tends to be more aggressive. The average age at diagnosis is 43 years (range 25-67). Most of these cancers arose in males and most involved the right colon. Half were TNM stage 4. Half of affected persons died within 1-26 months.[636]

The risk for gastric and esophageal carcinomas is increased with HIV infection. The standardized incidence ratio is 1.69 for esophageal and 1.44 for gastric carcinomas. Both squamous cell and adenocarcinoma types of esophageal cancers appeared with increased frequency; gastric carcinomas were of both diffuse and intestinal types.[637]

As expected, there is a 2.6 to 5.6 relative risk for hepatocellular carcinoma in HIV-infected persons, since both hepatitis B and hepatitis C virus infections are more frequent in such persons. Vaccination against hepatitis B, and treatment of chronic hepatitis, can reduce the risk.[633]

The relative preponderance of young males infected with HIV increases the likelihood for appearance of testicular neoplasms, since this is the most common solid malignant neoplasm in

young males. There is a relative risk of 2 in HIV-infected males compared with matched controls.[587] Most cases of testicular cancer occur before the stage of clinical AIDS has been reached. The stage at diagnosis is similar to non-HIV-infected persons, and response to therapy is also similar.[633,638].

Non-AIDS malignancies seen in association with HIV infection are likely to be coincidental, and longer survival of HIV-infected patients increases the likelihood for appearance of neoplasms. Benign neoplasms are not seen with increased frequency in patients with AIDS. The overall incidence of non-AIDS-defining neoplasms (those not part of criteria for AIDS) does not appear to be high, with an incidence of 2% in a study of over 11,000 patients followed from 1996. About half are related to infections. No significant effect of viremia was seen. Cumulative exposure to CD4+ cell counts <200 cells/ $\mu$ L during antiretroviral therapy was associated with an increased risk of infection-related non-AIDS-defining malignancies.[639]

## CHAPTER 5 - ORGAN SYSTEM PATHOLOGY IN AIDS

### RESPIRATORY TRACT PATHOLOGY IN AIDS

Patients with HIV infection frequently present with a wide spectrum of pulmonary complications from opportunistic infections and neoplasms that may be associated with a high mortality rate. Diseases of the respiratory tract account for many deaths from AIDS.[448] The response to therapy in AIDS can be slower and complicated by a greater number of adverse reactions to therapeutic agents than with other immunocompromised states. Cigarette smoking increases the risk for colonization by infectious agents, and smoke decreases alveolar macrophage function, leading to increased numbers of infections or more severe infections.[640] Cigarette smoking has been shown to be an independent risk factor for non-AIDS related mortality in persons infected with HIV. Cigarette smoking has also been reported to reduce the quality of life in this population as well.[641] The clinical features of many pulmonary diseases in AIDS are similar, necessitating serologic, culture, tissue, or cytologic diagnosis. Table 5 indicates the distribution of AIDS-diagnostic diseases in the respiratory tract seen at autopsy. Table 8 details the typical patterns of involvement.

*PNEUMOCYSTIS JIROVECI (CARINII) PNEUMONIA (PJP).*-- PJP is one of the most frequent and severe opportunistic infections in patients with AIDS.[433] Many AIDS patients will have at least one episode of PJP at some point during their clinical course, with mortality from a single episode ranging from 10 to 30%. However, use of antipneumocystis therapy and prophylaxis, either with trimethoprim-sulfamethoxazole, dapsone, or aerosolized pentamidine, can greatly diminish the incidence of PJP and increase survival.[223] The more extensive use of these therapies has increased survival for AIDS patients in places where it has been applied, both in the short term following a bout of PJP and in the first two years following diagnosis of AIDS.[642] Smoking increases the risk for PJP.[643]

Clinical features that suggest a high risk for PJP include oral thrush or unexplained fever. Clinical features with PJP that predict a poor prognosis include long duration of symptoms (weeks), prior episodes of PJP, prior therapy with antibiotics other than trimethoprim-sulfamethoxazole, older age, and presence of cytomegalovirus.[644,645]

Clinical features of PJP typically include the classic triad of fever, non-productive cough, and dyspnea, each of which may be present in 3/4 to 2/3 of cases, but together in less than half of cases. These findings may be subtle and may persist for weeks. The  $\text{PaO}_2$  is  $<80$  mm Hg in over 80% of cases, and desaturation with exercise is common. Findings in children with severe PJP include cyanosis, nasal flaring, and intercostal retractions. A pleuritic type of chest pain may also be present. A pleural effusion may accompany PJP. Spontaneous pneumothorax is an uncommon complication that can recur and be difficult to treat. Hemoptysis is unlikely to occur. Purulent sputum suggests bacterial infection. When PJP findings are present when the CD4 lymphocyte count is high, then immune reconstitution inflammatory syndrome (IRIS) associated with initiation of antiretroviral therapy should be considered.[428,646]

In general, the duration of PJP symptoms in a patient with AIDS is longer than that for patients without AIDS. Elevation of the serum lactate dehydrogenase (LDH) is highly sensitive for the diagnosis of PJP, but not specific because other pulmonary diseases such as tuberculosis

and bacterial pneumonia may also have an elevated LDH, as well as extrapulmonary disorders. An elevated beta-D-glucan level in the serum suggests the diagnosis of PJP.[640,647]

*Pneumocystis jiroveci* typically produces a pneumonia that is widespread throughout the lungs. *P. jiroveci* pneumonia is a chronic disease that may initially have subtle findings and then progress over several weeks to a florid pneumonia. The initial physical examination may be normal, but inspiratory crackles are usually the first manifestation. Though it often responds well to drug treatment, there can also be rapid progression leading to adult respiratory distress syndrome (ARDS). *P. jiroveci* pneumonia can be a presumptive clinical diagnosis to define AIDS using the following suggested guidelines:[421,647]

- A history of dyspnea on exertion or nonproductive cough with onset in the previous three months; AND
- Chest roentgenogram evidence of diffuse bilateral interstitial infiltrates or gallium scan evidence of diffuse bilateral pulmonary disease; AND
- Arterial blood gas analysis showing an arterial pO<sub>2</sub> of less than 70 mm Hg or a low respiratory diffusing capacity (less than 80% of predicted values or an increase in the alveolar-arterial oxygen tension gradient; AND
- No evidence of a bacterial pneumonia

The chest radiograph can appear normal in up to 10% of cases. Typical findings including bilateral, symmetric, reticular (interstitial), or granular opacities extending from perihilar regions. Although uncommon, a pneumothorax or bilateral pneumothoraces may occur. Chest high resolution CT imaging often shows patchy areas of ground glass opacity in 90% of cases. There is central distribution of ground-glass opacity with relative peripheral sparing in 41% of patients, a mosaic pattern in 29%, and a diffuse distribution in 24%. These opacities represent accumulation of intraalveolar fibrin, debris, and organisms. Though these opacities are nonspecific for PJP, their absence has a high negative predictive value. As the inflammatory infiltrates begin to organize, there can be foci of consolidation and septal thickening. Variably sized multiple and bilateral cysts can be found in up to a third of cases and may remain up to 3 years following resolution of the infection. Cysts can be associated with an increased frequency of spontaneous pneumothorax, although spontaneous pneumothorax can occur in the absence of definable lung cysts. Pneumothorax requires chest tube placement. Cysts may resolve after treatment and clearing of infection. [647,648,649]

Atypical findings on chest radiograph in up to 10% of cases can include isolated focal or asymmetrical dense consolidation and adenopathy. Rare findings include pleural effusions. Granulomatous inflammation may occur in 5% of patients, usually early in the course of HIV infection while immunodeficiency is more limited, and may appear as a solitary nodule or mass mimicking lung carcinoma or as multiple nodules ranging from a few millimeters to more than 1 cm. Small nodules and tree-in-bud opacities are uncommon and usually indicate the presence of infectious bronchiolitis from other organisms.[648,649]

When *Pneumocystis* pneumonia becomes chronic, septal lines with or without intralobular lines superimposed on ground-glass opacity (crazy paving) and consolidation may develop. There may be residual interstitial fibrosis.[649]

Use of aerosolized pentamidine for prophylaxis against PJP may lead to the appearance of localized upper lobe disease because this drug is preferentially deposited in middle and lower

lobes.[644] In children, PJP may manifest radiographically as a rapidly progressive increase in air space opacity with air bronchograms.[650]

Therapies can include trimethoprim-sulfamethoxazole (oral or parenteral), pentamidine isethionate (parenteral or in aerosolized form), prednisone, trimethoprim-dapsone, dapsone, trimetrexate, pyrimethamine-sulfadoxine, or clindamycin-primaquine. Prednisone may be added as an adjunctive agent to lessen hypoxemia. Trimethoprim-sulfamethoxazole (TMP-SMZ), if tolerated, is the first choice for either prophylaxis or therapy in both adults and children. If TMP-SMZ cannot be tolerated, then alternative therapy for prophylaxis may consist of dapsone with or without pyrimethamine and leucovorin, atovaquone suspension, and aerosolized pentamidine. Regimens containing dapsone and pyrimethamine are also effective prophylaxis against toxoplasmosis. Prophylactic therapy to prevent PJP is also recommended in pregnancy. PJP prophylaxis is recommended for life, though discontinuation may be considered in adolescents and adults who are receiving antiretroviral therapy and have a CD4 cell count above 200 cells/ $\mu$ L.[223,647]

Resistance to TMP-SMZ and dapsone may result from mutations in the dihydrofolate reductase (DHFR) and dihydropteroate synthase (DHPS) genes, the enzymatic targets of trimethoprim and sulfa (sulfamethoxazole and dapsone) medications. However, there is no strong evidence that therapeutic options should be modified because of potential mutations.[427,647]

Drug allergy or toxicity may develop in over half of treated patients and these reactions may also interfere with concomitant zidovudine therapy. Adverse reactions with trimethoprim-sulfamethoxazole occur in half of patients and include fever, skin rash (rarely Stevens-Johnson syndrome), nausea, vomiting, nephritis, leukopenia, hepatitis with elevated liver enzymes, and bone marrow suppression. Adverse reactions with pentamidine may include nausea, vomiting, rash, hypotension, serum glucose alterations, pancreatitis, hepatotoxicity, nephrotoxicity, and leukopenia. Aerosolized pentamidine, which is preferentially deposited in middle and lower lobes, is often accompanied by bronchoconstriction that must be alleviated with concomitant use of an inhaled beta-adrenergic agent. Dapsone may cause rash, nausea, and hemolysis. Untreated, or with poor response to therapy, the terminal hospital course with PJP can be as short as a few days.[223,651]

*Pneumocystis* is more likely to have a diffuse involvement of lung than other opportunistic infectious agents or neoplasms with AIDS. *Pneumocystis* typically involves alveolar spaces, giving the gross appearance of pneumonic consolidation. *P. jiroveci* pneumonia tends to be more confluent throughout the lungs than bacterial pneumonias. Cut surfaces of lung with early PJP show a prominent "poached salmon" or pale pink appearance when in the fresh state, and the markedly consolidated lung is firm to friable with a definable lobular pattern. There may be scattered areas of hemorrhage or congestion. The weight of each lung can exceed 1 kg.[644] Laboratory diagnosis is accomplished by staining of the organisms in fluids and tissues recovered from the patient.[652]

An uncommon gross appearance of PJP is a "granulomatous" pattern resembling *Mycobacterium tuberculosis* infection. This pattern is more likely to be present when a chest radiograph shows parenchymal nodules, but diffuse infiltrates or a solitary nodule may also occur. The granulomas range from 0.1 to 2.5 cm, averaging 0.5 cm in size. Microscopically they all contain epithelioid macrophages and lymphocytes, but slightly more than half have giant cells. Foamy eosinophilic exudate typical for PJP may be present within a granuloma in a fourth of cases, but associated intra-alveolar foamy exudates in only 5% of cases. Non-necrotizing

granulomas are found in 20% of cases.[653] A "pneumocystoma" pattern with one or more ill-defined pale pink to tan masses is also uncommonly seen.[654,655] Another pattern is the appearance of multiple thin-walled bi-apical cystic spaces with a subtle ground-glass pattern surrounding the cysts.[656]

As PJP progresses, the lung texture becomes rubbery and the cut surfaces are often slimy, typical of diffuse alveolar damage (clinically defined as adult respiratory distress syndrome or "shock" lung). Severe infections poorly responsive to therapy may go on to produce diffuse alveolar damage that can organize to "honeycomb" lung with type II cell hyperplasia and interstitial fibrosis. Lymphocytic or plasma cell interstitial infiltrates can be prominent, though this is more common with PJP in children than in adults. A pattern of bronchiolitis obliterans may be apparent. The greater the degree of organization, the fewer and smaller the alveolar exudates become, and the harder the organisms are to identify within the tissue histologically. Concomitant therapy of PJP with intubation and ventilation utilizing high oxygen tensions may lead to oxygen toxicity that also promotes diffuse alveolar damage.[644]

The inflammatory reaction to *P jiroveci* is primarily mediated by macrophages, and impairment of macrophage function in immunocompromised hosts leads to risk for establishment of infection. The diminished CD4 lymphocyte count contributes to development of PJP, because tumor necrosis factor and interleukin-1 released by macrophages aid in activation of CD4 cells, and activated CD4 cells release interferon-gamma that stimulates macrophage function to clear the organisms.[427]

In hematoxylin-eosin-stained transbronchial biopsy specimens, PJP is suggested by the presence of a characteristic intra-alveolar exudate consisting of refractile, foamy to granular to honeycomb eosinophilic material composed mainly of the *Pneumocystis* organisms (both trophozoites and cysts) held together by intertwined slender membranotubular extensions. The exudate contains little fibrin, and scanty admixed cellular elements or debris may consist of lymphocytes, macrophages, pneumonocytes.[432] Early infections may lack the foamy exudate, though *P jiroveci* cysts and trophozoites can be demonstrated on alveolar septae. An inflammatory component is not a striking feature in most cases, though in some cases macrophages, polymorphonuclear leukocytes, or lymphocytes may be seen. Diagnosis is made by finding the 5 to 7 micron cysts with special stains in biopsy or cytologic specimens.[644]

Most PJP cases are "typical" in that pink foamy to granular alveolar exudate is present and interstitial or inflammatory changes are minimal to absent. This exudate is found in most alveoli throughout the lung, though it may be more pronounced in some. A patchy pattern of alveolar involvement is seen in a few cases. However, one or more "atypical" features may be found in over half of PJP cases and can include: a plasma cell interstitial pneumonitis with round cells--including many plasma cells; a necrotizing granulomatous pattern of inflammation with giant cells, epithelioid macrophages, and caseation; prominent microcalcifications; absence of foamy exudate; interstitial or intraluminal fibrosis; bronchiolitis obliterans; or desquamation of type II pneumonocytes. A "pneumocystoma" may develop and consist of a localized mass lesion containing sheets of foamy to granular pink exudate without an intervening alveolar framework.[645,651,654,655]

Pulmonary cavitation may occur in association with PJP in less than 5% of cases, either alone or within an area of pulmonary consolidation, mass, or nodule. Patients with cavitation may present with hemoptysis. Cavitation may be promoted by vascular invasion by *P jiroveci* and subsequent vasculitis and necrosis or by alveolar septal invasion and necrosis.[644,657]



Pneumomediastinum is an uncommon complication of PJP, and rarely other infectious agents seen with AIDS. Subsequent pneumothorax may occur. Treatment consists of antimicrobial agents.[658]

Extrapulmonary spread of *P jiroveci* occurs in less than 5% of cases of AIDS in which *P jiroveci* infection is diagnosed. The most common site is hilar lymph nodes, followed by spleen and liver.[448] The microscopic appearance is often similar to that of the alveoli, but in widely disseminated cases, *P jiroveci* can produce numerous small 0.1 to 0.3 cm calcified granulomas that give cut surfaces of parenchymal organs the gross appearance of rough sandpaper. A GMS stain reveals the organisms, even in densely calcified areas. Immunohistochemical staining for *P jiroveci* in extrapulmonary sites is very useful.[446] In the rare cases of PJP accompanied by pleural effusion, typically in association with aerosolized pentamidine therapy, pleural fluid cytologic examination with GMS stain helps to reveal the organisms.[659]

**CYTOMEGALOVIRUS.**-- Cytomegalovirus (CMV) involvement of lung varies from an insignificant and incidental microscopic finding without extensive gross or microscopic changes to a florid pneumonitis with numerous inclusion bodies. Cytomegalovirus may not always be diagnosed pre mortem either because a long latent incubation period is present without characteristic morphologic changes, infection develops agonally, or there is sampling error with tissue biopsy or cytologic methods caused by the patchy distribution of cells with characteristic CMV inclusions.[660]

The finding of CMV in bronchoalveolar lavage or sputum specimens or by culture may not necessarily indicate that a pneumonitis is present.[449] Cytomegalovirus can frequently be detected in bronchoalveolar lavage fluid from HIV-infected patients and does not necessarily correlate with pulmonary symptoms nor predict outcome.[661] Cytomegalovirus inclusions in tissue biopsy specimens, along with the absence of other pathogens, may represent pneumonitis that can be treated with ganciclovir. Though CMV is the most common viral infection of lung in AIDS, it occurs frequently in conjunction with other opportunistic infections, so CMV is rarely the sole cause for a symptomatic pneumonitis.

In cases of CMV pneumonitis, the most frequent clinical findings are fever, dyspnea, and non-productive cough. Concomitant extrapulmonary evidence for CMV accompanies half of cases. Hypoxemia suggests a poor prognosis, and the overall mortality is about 40%. Treatment with ganciclovir may be useful in the setting of a diffuse interstitial pneumonia with hypoxemia and histologic evidence for CMV in the absence of other pathogens.[449,662]

Radiographic features of CMV pneumonia overlap those of other opportunistic infections with AIDS such as PJP. These features may be present in two thirds of cases. There can be ground glass opacifications, nodules ranging from miliary to 3 cm, perihilar and lower lung field interstitial infiltrates, small airway disease, and pleural effusions.[648]

There are no specific gross pathologic changes attributable to CMV. The findings may resemble PJP, though extrapulmonary disease more strongly suggests CMV. The distribution of CMV in the lung may be alveolar, interstitial, or tracheobronchial. Characteristic inclusion bodies are more often seen within epithelial cells of the lung. Occasionally, inclusions are seen in vascular endothelium, more often in the tracheobronchial tree. The patterns of involvement include focal interstitial pneumonitis and acute necrotizing tracheobronchitis, though vasculitis may also be seen. More florid cases of CMV pneumonitis may present with areas of patchy to confluent red or tan consolidation. This can progress to diffuse alveolar damage. Areas of hemorrhage may be present.[662]

Microscopic presence of cytomegalic cells with intranuclear inclusions is necessary for light microscopic diagnosis with hematoxylin-eosin staining. Inclusions may be scant to numerous. Cytomegalic cells may line alveolar spaces, appear within the lumens of air spaces, or involve endothelium. When CMV infection is florid, two or more inclusions may be seen within a cytomegalic cell. Since inclusions may be difficult to find in tissue biopsy or cytologic material, direct fluorescence antibody staining, culture, and use of immunohistochemistry or *in situ* hybridization may be very helpful ancillary techniques. Accompanying inflammation may not always be present, but in florid cases consists of many polymorphonuclear leukocytes and/or lymphocytes. Inflammatory infiltrates are primarily within interstitium, but can be alveolar in florid cases. A search should be made for additional opportunistic infectious agents, particularly *P jiroveci* (*carinii*).[662]

**CRYPTOCOCCAL PNEUMONITIS.**-- Infection with *Cryptococcus neoformans* probably occurs after inhalation of an aerosol containing the unencapsulated yeast, but there is no known environmental factor that consistently increases the risk for infection. *C neoformans* can be found throughout the world. Colonization of the tracheobronchial tree, followed by pulmonary infection, whether silent or symptomatic, probably precedes dissemination to other organs. There are no specific clinical signs or symptoms of cryptococcal pneumonia; patients may have fever, night sweats, fatigue, and headache for days to months. About a third of patients with cryptococcosis have respiratory symptoms including cough and dyspnea. Diagnosis of disseminated cryptococcal infection can initially be made by the sensitive and specific cryptococcal antigen test that can be run on serum, cerebrospinal fluid, or pleural fluid. However, this antigen test may be negative with isolated pulmonary disease.[640,656]

Radiographic findings with cryptococcal pneumonia include patchy irregular or mass-like airspace opacities as well as lobar or segmental consolidation, without a lobar predilection. Nodules or masses are common, including tiny subpleural or peripheral interstitial nodules with adjacent interstitial thickening or pleural thickening. Widespread interstitial disease and effusions are not common. Lymphadenopathy is seen in more than a third of patients, is usually not pronounced (<1.5 cm), and always present with other findings. A combination of findings is more frequent than a single abnormality.[663]

Pulmonary involvement by *C neoformans* is second only to central nervous system involvement in frequency in AIDS (Table 5). Cryptococcosis tends to be a disseminated disease, though death with *C neoformans* often results from pulmonary involvement. The gross patterns of *C neoformans* involvement within the pulmonary parenchyma include a bronchopneumonia-like pattern with either diffuse or patchy consolidation, interstitial infiltrates, or a mixture of these two patterns. Solitary or multiple nodules, which are granulomas, may appear similar to those seen with mycobacterial infection or other fungi, and they typically have a soft, mucoid appearance. When well-defined masses or nodules are seen, they are often gelatinous because numerous organisms with minimal inflammatory infiltrates are present.[489,490]

Microscopically, the 4 to 7 micron pale cryptococci are found filling the alveoli or infiltrating the alveolar septae. Often, poorly encapsulated or non-encapsulated cryptococci are present that are only 2 to 5 microns in size that may be difficult to distinguish from *Candida* and *Histoplasma capsulatum*. [485] Granulomas, if present, tend to be small and poorly formed. The interstitium or alveoli may show only a minimal inflammatory response consisting mainly of scattered macrophages with few lymphocytes or neutrophils. The more common pattern of

involvement consists of focal small lesions. A pneumonic pattern of numerous cryptococci in alveolar spaces along with mixed inflammatory infiltrates is seen less frequently.[490]

Both cellular pleomorphism of *C neoformans* and its lack of hyphae help to distinguish this organism from *Candida*. Gomori methenamine silver (GMS) and PAS stains readily demonstrate the organisms. Cryptococci can also be distinguished from other fungi from the presence in *C neoformans* of a melanin-like pigment seen with Fontana-Masson staining.[491]

**HISTOPLASMOSIS.**-- *Histoplasma capsulatum* infection with AIDS often produces a disseminated infection, and pulmonary involvement is frequent. Clinically the onset of disease is insidious, with weight loss and fever the most common symptoms. A chest roentgenogram shows diffuse interstitial infiltrates in about half of all patients, and in these patients, cough and dyspnea are often present as well, but only one-sixth of AIDS patients with histoplasmosis present with respiratory problems. The *Histoplasma* polysaccharide antigen (HPA) test can be performed on serum, urine, cerebrospinal fluid, or bronchoalveolar lavage fluid for initial diagnosis of disseminated histoplasmosis. Although the urine and serum HPA test is sensitive in disseminated histoplasmosis, it is often negative in isolated pulmonary disease. Blood culture or tissue biopsy with culture are the main means for confirming the diagnosis.[519,640]

The initial response to infection is neutrophilic, but soon shifts to mononuclear phagocytes. Grossly visible small tan to white granulomas may be present in lung tissue, but often they are not. The organisms consist of small, oval 2 to 4 micron budding yeasts that are most often identified within macrophages in the interstitium, but they may also be free in the alveolar spaces. Intracellular organisms may be seen in routine hematoxylin-eosin-stained sections due to a small artefactual clear zone surrounding them, though they are best seen by either Gomori methenamine silver (GMS) or periodic acid-Schiff (PAS) stains. In older fibrotic or calcified granulomas, *H capsulatum* may be visible only with methenamine silver stain.

Histological confirmation of *H capsulatum* infection can sometimes be difficult, since the yeasts are small and can sometimes resemble *Candida*, *Pneumocystis jiroveci* (*carinii*), *Leishmania*, or poorly encapsulated *Cryptococcus neoformans* organisms. Immunohistochemical staining of smears and tissue sections with anti-histoplasma antibody can be utilized to specifically diagnose pulmonary histoplasmosis. Microbiologic culture can aid in confirming the diagnosis of *Histoplasma* pneumonitis.

**MYCOBACTERIOSIS.**-- Mycobacterial pulmonary infections in AIDS are most commonly caused by *Mycobacterium tuberculosis*, followed by *Mycobacterium avium* complex (MAC). Other mycobacteria, including *Mycobacterium kansasii* and *Mycobacterium fortuitum*, are seen infrequently. A presumptive diagnosis of pulmonary tuberculosis to satisfy definitional criteria for AIDS can be made as follows:[421]

When bacteriologic confirmation is not available, other reports may verify cases of pulmonary tuberculosis if the criteria of the Division of Tuberculosis Elimination, National Center for Prevention Services, CDC, are used. A clinical case is defined when the following criteria are met:

- \* A positive tuberculin skin test

- \* Other signs and symptoms compatible with tuberculosis, such as an abnormal, unstable (worsening or improving) chest roentgenogram, or clinical evidence of current disease
- \* Treatment with two or more antituberculous medications
- \* Completed diagnostic criteria

Laboratory criteria for diagnosis include:

- \* Isolation of *M tuberculosis* from a clinical specimen, or
- \* Demonstration of *M tuberculosis* from a clinical specimen by DNA probe or mycolic acid pattern on high-pressure liquid chromatography, or
- \* Demonstration of acid-fast bacilli in a clinical specimen when a culture has not been or cannot be obtained

Laboratory diagnosis of pulmonary tuberculosis in HIV-infected persons can be most easily made with serum obtained for interferon-gamma release assay (IGRA). Sputum samples can be obtained for detection of acid-fast bacilli under fluorescence microscopy with the auramine stain. Specificity is high but sensitivity is not. Radiographic findings can aid in diagnosis.[476] Other specimens may include bronchoalveolar lavage fluid, bronchial brushings, and biopsies. The auramine stain can also be applied to tissue sections and viewed with fluorescence microscopy and is more sensitive than the standard Ziehl-Neelsen acid-fast stain viewed by light microscopy. Fine needle aspiration cytology can be employed and can detect MTB in half of cases.[664]

Radiographically, the findings of tuberculosis in AIDS patients with CD4 lymphocyte counts above 200/ $\mu$ L are often similar to those of non-immunocompromised patients, with a reactivation pattern that includes predominantly pulmonary involvement with nodular densities and cavitation of larger nodules, but often in lower lobes, along with adenopathy and effusions. In patients with CD4 lymphocyte counts below 200/ $\mu$ L there is likely to be a pattern of primary tuberculosis with focal unilateral, often lower lobe, consolidation along with adenopathy, but without cavitation. However, the chest radiograph may be normal in up to 15% of cases. The lower the CD4 count, the more likely a miliary pattern may be present. An asymmetric reticulonodular pattern on chest radiograph correlates with high resolution CT imaging that shows adenopathy and a “tree-in-bud” pattern similar to bacterial bronchiolitis. When antitubercular therapy is begun along with antiretroviral therapy, there is often a worsening of findings in the first month from increased inflammatory response with improved host immune function. However, as immune status declines, the radiographic findings can also worsen.[648]

*Mycobacterium tuberculosis* will usually produce grossly recognizable tan to white firm granulomas, often with caseation. Sometimes, the granulomas involve the pleura and are associated with a hemorrhagic exudate or effusion. Microscopically, the classical features of caseation with Langhans giant cells, fibrosis, and lymphocytic infiltration are present but not pronounced. On acid fast stains, mycobacteria are scattered singly or in small clusters and can be numerous and easy to demonstrate.[459,460]

Nontuberculous mycobacteria may produce variable findings. MAC is more likely to have significant extrapulmonary disease and produces pronounced chest radiographic findings in about 5% of cases. If findings are present with imaging, they are most likely to resemble those of MTB with areas of airspace consolidation and diffuse patchy infiltrates with predominantly

upper lobe involvement, along with mediastinal lymphadenopathy. In immune restoration following antiretroviral therapy, mediastinal lymphadenopathy may become prominent.[647,648]

Grossly visible granulomas are uncommon with MAC. The organisms are often found in an interstitial distribution. Microscopically, granulomas are ill defined and consist primarily of a single macrophage or small macrophage clusters. Both necrotizing and non-necrotizing granulomatous inflammation can occur. The macrophages have cytoplasm with a striated pale blue appearance with hematoxylin-eosin staining. Acid-fast stains demonstrate abundant mycobacteria within these macrophages.[454] Another pattern of lung involvement is bronchiectasis. The inflammation may obliterate bronchi. Cavitory change may be present. Miliary and pneumonic patterns may also occur.[665]

*Mycobacterium fortuitum* produces gross and microscopic patterns of pulmonary involvement similar to *M tuberculosis*. *Mycobacterium xenopi* infections are not common but may produce significant pulmonary disease late in the course of HIV infection.[479]

Infections with *M kansasii* tend to occur late in the course of AIDS, and radiographic findings include interstitial and/or lobar infiltrates, with cavitation present in about 20% of cases. Most patients present with fever, cough, chills, chest pain, weight loss, and dyspnea. Pulmonary disease occurs in over 90% of cases, while disseminated disease is seen in a fifth of cases. Thoracic lymph node involvement is common. Grossly there are variably sized granulomas consisting of a large central area of noncaseating necrosis. Microscopically the granulomas have extensive nuclear debris and neutrophils with a rim of epithelioid cells admixed with large histiocytes with foamy cytoplasm or of fibrosis, but no multinucleated giant cells. Acid-fast bacilli (AFB) are numerous, both within necrotic regions and within epithelioid cells. The long, folded, beaded rod-shaped organisms are easily seen with Ziehl-Neelsen stain, but stain more intensely and in greater numbers with the Fite stain. Most patients respond to therapy.[482,666]

**COCCIDIOIDOMYCOSIS.**-- *Coccidioides immitis* infection of the lungs is due to inhalation of infective arthrospores with the subsequent development of proliferating thick-walled spherules containing endospores. In AIDS, coccidioidomycosis is a rare cause of pulmonary disease, even in endemic areas of the Southwestern United States. Pulmonary infection in these patients probably results from reactivation of a previous, latent infection rather than a *de novo* opportunistic infection. Clinical features are non-specific and include fever and weight loss. An abnormal chest radiograph with diffuse infiltrates, single or multiple nodules, cavitation, or hilar lymphadenopathy can be seen in about three-fourths of cases. Diagnosis requires histologic examination with culture of bronchoalveolar lavage or lung biopsy.[663]

Grossly, small granulomas or patchy pneumonic consolidation may be seen. Microscopically, the organisms are found in focal areas of interstitium. Large, thick-walled, variably sized spherules measuring 50 to 100 microns contain numerous refractile endospores from 2 to 5 microns in size. The inflammatory response is poor. Occasionally, persons taking anabolic steroids or corticosteroids can develop disseminated coccidioidomycosis almost identical to that seen in AIDS.[522]

**TOXOPLASMOSIS.**-- In AIDS, toxoplasmosis is usually associated with disseminated infection and secondary pulmonary involvement. The most common clinical finding is a cough, either productive or non-productive. An abnormal chest roentgenogram marked by bilateral interstitial infiltrates may appear in only half of cases. Diagnosis can be made by bronchoalveolar lavage in most cases.[516]

Histologically, there may be focal necrosis with vague granuloma formation and/or diffuse interstitial mixed inflammatory cell infiltrates with alveolar lining cell hyperplasia. Diagnosis depends upon finding *Toxoplasma gondii* pseudocysts filled with bradyzoites, but these are infrequent--even in severe infections. Free tachyzoites are small and difficult to distinguish from debris or cell fragments with hematoxylin-eosin staining. *T gondii* pseudocysts must be distinguished from cytomegalovirus cells lacking a visible nucleus but containing intracytoplasmic virions. Cytomegalovirus tends to have a thinner wall, and the cytoplasmic basophilic bodies of CMV are coarser than bradyzoites.[514]

**ASPERGILLOSIS.**-- Pulmonary aspergillosis does not occur commonly with AIDS, but may appear late in the course when the CD4 lymphocyte count is  $<100/\mu\text{L}$ . Aspergillosis may often occur in association with other infections such as cytomegalovirus and *P jiroveci* (in over half of cases), bacterial, or fungal pneumonias. Over 80% of cases are accompanied by neutropenia (which can complicate antiretroviral therapy). In 15% of cases there is a history of corticosteroid therapy or broad-spectrum antibiotic therapy.[667,668] Marijuana smoking may also be a risk because marijuana is an excellent fungal growth medium.

The major clinical findings with pulmonary aspergillosis in AIDS are fever, cough, and dyspnea in over half of cases. Other findings may include pleuritic chest pain, malaise, and weight loss. The two clinical patterns of pulmonary aspergillosis in AIDS are: (1) acute invasive pulmonary aspergillosis with prolonged cough and fever, and (2) obstructing-bronchial aspergillosis with dyspnea, cough (sometimes productive of bronchial casts containing the fungal hyphae), and chest pain. Dissemination of infection occurs in a few cases, with the central nervous system, kidney, and heart most likely to be affected. Bronchoalveolar lavage may yield a diagnosis in 67% of cases, though finding *Aspergillus* in BAL specimens does not always indicate a true infection, but rather upper respiratory tract colonization. A transbronchial biopsy is diagnostic in 27% of cases.[667,668] A serum galactomannan assay can be helpful in diagnosing invasive aspergillosis, but there is cross-reactivity with other fungi.[669]

Radiographically, there may be unilateral or bilateral infiltrates with angioinvasion and thick-walled, cavitary, upper lobe disease that may be complicated by hemoptysis. On computed tomographic scans, parenchymal nodules with surrounding peripheral halo of ground glass attenuation and variable cavitation from focal infarction may be seen. An uncommon variant known as obstructing bronchial aspergillosis may produce bilateral diffuse lower lobe consolidation on chest radiograph because of post-obstructive atelectasis. Airway impaction produces a "finger-in-glove" pattern.[648]

Histologically, the hyphae of *Aspergillus* are best identified in bronchoalveolar lavage specimens, but they can also be readily identified in biopsied tissues. The lungs grossly may show either focal or diffuse involvement, with geographic areas of firm orange to yellow-tan necrosis, hemorrhage, and edema. *Aspergillus* is readily demonstrated in Gomori methenamine silver (GMS) and periodic acid-Schiff (PAS) stains by the appearance of 3 to 5 micron diameter branching Y-shaped septate hyphae of nearly uniform caliber which commonly invade bronchial walls and blood vessels. Vascular invasion can produce thrombosis and infarction. A poorly formed granulomatous response at the periphery of the lesions is uncommon.

*Aspergillus* fungal hyphae can be readily distinguished from *Candida* by the absence of budding cells and pseudohyphae in the latter. *Aspergillus* can be distinguished from Zygomycetes such as *Mucor* by the smaller diameter of hyphae and presence of septation in the former. Hyphae of *Mucor* are non-septate, short, broad, and have irregular shapes, while

pseudohyphae of *Candida* are smaller than the branching, finger-like hyphae of *Aspergillus*. The various species of *Aspergillus* can be distinguished by culture, but they all have similar morphologic appearances in tissue sections as well as similar clinical courses. Amphotericin B and/or itraconazole are variably effective treatments.[663,668]

**NOCARDIOSIS.**-- *Nocardia*, a genus of aerobic actinomycetes, can produce both localized and disseminated disease, usually late in the course of AIDS. The lung is the most common site for infection and *N asteroides* is the most frequent species isolated. Additional clinical presentations include subacute sinusitis, chronic localized abdominal abscess, and acute disseminated nocardiosis. There are no specific clinical findings, though fever, productive cough, and weight loss are the most frequent findings. On chest radiograph, an alveolar pattern of pulmonary infiltrates is the most common feature, with reticulonodular patterns seen in fewer patients. The nodules may be spiculated and cavitated on chest CT, with an associated pleural reaction. Gross pathologic features may include pneumonic consolidation, abscess formation, cavitation, and pleural effusions. Microscopically, *Nocardia* produces an acute inflammatory response in which the gram-positive filamentous organisms can be identified. The disease may remain localized or become disseminated to involve such sites as subcutaneous tissues, central nervous system, and kidney, with resultant high mortality rate. Early diagnosis from culture and treatment with sulfonamides or minocycline leads to better response and outcome.[670,671]

**BLASTOMYCOSIS.**-- *Blastomyces dermatitidis* is an uncommon opportunistic infectious agent, even in endemic areas of the Midwestern and south-central United States and southern Canada. Infection occurs from inhalation of infective conidia derived from the mycelial form of the organism that grows in soils with high organic content in humid climates, often in autumn and winter. In the environment it grows in a mycelial form at 25°C, and as yeast in tissues at 37°C. Blastomycosis is most often seen when the CD4 lymphocyte count is less than 200/ $\mu$ L. Infection usually involves the lung. Blastomycosis with HIV infection can manifest as pulmonary, disseminated, and cutaneous disease. It may cause localized pulmonary disease, but disseminated infection occurs just as frequently and most often involves the central nervous system, though a wide variety of tissue sites can be affected. Cutaneous involvement with deep ulcers is less frequent in association with HIV infection than in non-immunocompromised hosts. Oral lesions are rare, but may occur in disseminated disease as single or multiple ulcerations, as well as sessile projections, and verrucous or granulomatous lesions. The inflammatory reaction can be either neutrophilic or lymphocytic, and with microabscesses and noncaseating granulomas.[490,579]

Patients have usually developed a prior AIDS-defining illness, and blastomycosis occurs as a late or terminal event. Typical presenting symptoms include fever, cough, pleuritic chest pain, dyspnea, and weight loss. Radiographs are often abnormal with lobar infiltrates, nodules, miliary pattern, or diffuse interstitial changes. Diagnosis can be made by finding thick-walled, double-contoured 8 to 20 micron sized yeasts with single broad-based buds in cytologic specimens or tissue biopsies and by confirmatory culture. Serologic testing includes enzyme immune assay using serum or urine, with good sensitivity in the context of severe or widespread illness, though cross-reactions with other endemic fungal infections can occur. Cultures of bronchopulmonary lavage material, skin, cerebrospinal fluid, and blood are positive in 90% of cases. Initial therapy with amphotericin B can be curative or can prolong survival, with

ketoconazole or itraconazole administered for the remainder of life, but half of infected AIDS patients die.[490,579,672]

**CANDIDIASIS.**-- *Candida* infections in the respiratory tract with AIDS primarily involve the trachea and bronchi.[663] Infection can be either mucocutaneous or invasive. Only the invasive form is included in the definitional criteria for diagnosis of AIDS.[421] In bronchoalveolar lavage and sputum specimens, the recovery of *Candida* in the absence of tissue invasion is frequent and supports the diagnosis of mucocutaneous infection, but oropharyngeal contamination must be excluded.

Many budding yeasts with pseudohyphae can often be found growing on mucous membranes of the oral cavity, pharynx, larynx, and tracheobronchial tree, but in histologic sections of these sites, the organism is also often identified on the mucosal surfaces without invasion into deeper tissues. With invasion, there can be acute ulceration with underlying submucosal chronic inflammation. The clinical appearance of oral candidiasis in patients with declining CD4 lymphocyte counts may herald the progression of HIV infection to AIDS.[663]

Invasive pulmonary parenchymal *Candida* infections occur infrequently in terminally ill patients, with the diagnosis sometimes recognized only at autopsy. Both *C. albicans* and non-*albicans* infections may occur.[673] The lungs grossly may show small microabscesses to focal consolidation, sometimes with hemorrhage and necrosis. Granuloma formation is uncommon. Microscopically, 3 to 4 micron budding yeasts are seen along with pseudohyphae that invade bronchial walls, blood vessels, and pulmonary parenchyma. These yeasts typically produce necrotizing microabscesses with prominent neutrophilic infiltrates. The pseudohyphae can produce aggregates which must be differentiated from the mycelial forms of *Aspergillus* species that have branching, septated hyphae. *Aspergillus* hyphae are septate and usually broader than *Candida* pseudohyphae.

**BACTERIAL PNEUMONITIS.**-- Bacterial pneumonias in AIDS can lead to significant morbidity and mortality and are second only to *Pneumocystis jiroveci* (*carinii*) pneumonia as an immediate cause of death.[448] Overall, bacterial organisms account for more pulmonary infections than other infectious agents in persons with AIDS. The defects in B-cell as well as T-cell mediated immunity in with HIV infection result in pneumonia caused by any of a large group of bacterial organisms, both gram positive and gram negative. Bacterial pneumonias are more frequent in persons infected with HIV than in seronegative persons. The risk for HIV-infected persons is highest when the CD4 lymphocyte count is  $<200/\mu\text{L}$  and viral loads are higher. Among risk groups, injection-drug users are most likely to develop bacterial pneumonias.[674] Smoking increases the risk for community acquire pneumonias in persons with HIV infection.[643]

Acute bronchopneumonia may be suggested by bronchoalveolar lavage or transbronchial biopsies in which neutrophilic exudate is present and gram stain reveals bacteria. The clinical signs and symptoms may be subtle, and a peripheral blood neutrophilia may not be present or prominent. Tissues or fluids should be sent for routine microbiologic culture. When microbiologic cultures are performed, the most common etiologic agent for bacterial pneumonias is *Streptococcus pneumoniae*, followed by *Haemophilus influenzae*, and *Staphylococcus aureus*. Gram-negative organisms are less commonly implicated and can include *Pseudomonas aeruginosa* and *Klebsiella pneumoniae*. Bacterial bronchopneumonias may also be present along



with other opportunistic infections. Patients are more likely to be female, younger, and present with respiratory symptoms than patients who are not infected with HIV.[537,675]

Recurrent pneumonia as a criterion for AIDS may be diagnosed presumptively as follows:[421]

Recurrent (more than one episode in a 1-year period), acute (new symptoms, signs, or roentgenographic evidence not present earlier) pneumonia diagnosed on clinical or radiologic grounds by the patient's physician.

Grossly and radiographically bacterial pneumonias in patients with AIDS resemble those seen in other patients. Focal or multifocal areas of consolidation appear on chest x-ray, in either a lobar or a segmental pattern, which helps in distinguishing bacterial pneumonia from PJP. Infections with *H influenzae* may sometimes resemble PJP. Cavitation may be a feature of infection with *P aeruginosa*, *S aureus*, and *R equi*. Complications of parapneumonic effusion, empyema, and abscess formation are frequent. Sepsis, particularly with septic emboli and with gram-negative organisms, can lead to cavitation. The most common pattern, particularly in hospitalized and terminally ill patients, is that of bronchopneumonia with patchy bilateral infiltrates. Accompanying the areas of patchy consolidation can be seen changes in small airways, with centrilobular micronodularity and branching structures or a “tree-in-bud” pattern from mucus impaction within bronchioles. Best observed with computed tomographic scans, small airway disease may consist of dilation and thickening of bronchial walls or bronchiolitis marked by small densities.[648,675]

Microscopically, alveolar neutrophilic exudates with accompanying parenchymal congestion and edema are seen in varying amounts. These bronchopneumonias can be bilateral and extensive. Staphylococcal pneumonias can be abscessing and/or hemorrhagic. Pneumococcal pneumonia may present with a lobar pattern that produces a disease clinically indistinguishable from that in HIV negative patients, including complications of abscess, empyema, and pleural effusions.[676]

Laboratory testing can include sputum gram stain and culture for bacterial organisms. Pneumococcal organisms can be detected by PCR for DNA in fluids and by immunochromatographic analysis for C-polysaccharide antigen in urine.[675]

Since persons with HIV are at increased risk for *Streptococcus pneumoniae* and *Haemophilus influenzae* pulmonary infections, it is recommended that vaccination against pneumococcus be given in patients newly diagnosed with HIV infection.[640] In children, and possibly adults, the vaccine for *H influenzae* type b can help reduce *Haemophilus* infections, though the variety of serotypes may mitigate somewhat against effectiveness of *H influenzae* type b vaccination.[223, 537]

Recurrent infections with these and other bacterial agents, principally *Pseudomonas* and *Staphylococcus* species, increase the risk for chronic bronchitis. In patients with increased survival, chronic bronchitis can lead to bronchiectasis. Such complications typically are manifested in patients with CD4 lymphocyte counts below 200/ $\mu$ L.[677] Other streptococcal species and enteric bacterial organisms such as *E. coli* and *Enterobacteriaceae* are seen with AIDS. Less frequent organisms reported in association with AIDS include *Legionella* and *Moraxella*.[537,538]

*Legionella pneumophila* infection can occur with HIV infection, but not frequently. Smoking is a significant risk factor. Clinical features of infection include fever, myalgia,

headache, pleuritic chest pain and nonproductive cough. Diagnosis by sputum analysis is hindered by lack of sputum production in many infected patients. This organism most often produces an acute consolidating pneumonia. If cytologic or biopsy material is obtained, Dieterle or fluorescent antibody staining of sputum or bronchoscopic specimens can be helpful for diagnosis. Urine serologic titers for *L pneumophila* antigen are 90% sensitive and 99% specific for diagnosis.[678]

*Rhodococcus equi* has been recognized as a pathogen in persons with HIV infection, and it can be missed because it sometimes stains weakly acid fast or resembles contaminant diphtheroids on gram stain. It is a facultative intracellular bacterium that proliferates within macrophages.[679] HIV-infected patients with *R equi* have a mean CD4 lymphocyte count of 50/ $\mu$ L. The most common symptoms are fever and cough. Pathologic findings include pneumonia in 82%, cavitory lesions in 69%, lung abscess in 9%, pleural effusion in 6.5% and empyema in 2.3%. Extrapulmonary lesions may be found in 20% of cases, including brain abscess, soft tissue infection, septicemia, lymphadenitis, and pericarditis. Radiologic findings most often include a localized pneumonia with consolidation and cavitation. The persistence of *R equi* in macrophages can also lead to the appearance of pulmonary malakoplakia. Malakoplakia is a form of granulomatous inflammation marked by the appearance of Michaelis-Gutman bodies, which are target-like calcospherites, within macrophage cytoplasm. [538,543,680]

Septic emboli involving the lungs are typically caused by bacterial organisms. The radiographic appearance includes a peripheral or subpleural distribution of 1 to 2 cm nodules. Cavitation within nodules or wedge-shaped opacifications from infarction can occur.[675]

**VIRAL PNEUMONITIS.**-- Aside from cytomegalovirus, other viral infections of lung are less frequently diagnosed, though the true incidence remains unknown. Viruses may be recovered from bronchoalveolar lavage fluid. Viral pneumonitis may be difficult to distinguish from non-specific interstitial pneumonitis or lymphoid interstitial pneumonitis without specific viral cultures or serologies. Bacterial infections often complicate viral pneumonitis and may be indistinguishable clinically, though a viral pathogen may be the only infectious agent present in some cases. Viral pneumonias most frequently are due to herpes simplex, rhinovirus, influenza, parainfluenza, and adenovirus in adults, with respiratory syncytial virus more frequent in children. *Mycoplasma* species, though not viruses, can produce a similar clinical picture with infection, and can also be recovered with bronchoalveolar lavage.[681] Vaccination against influenza is recommended for all HIV-infected persons.[223,682]

Human metapneumovirus (hMPV) infection in HIV-infected persons is similar to that seen in immunocompetent persons. The CD4 lymphocyte count is typically above 200/ $\mu$ L. A febrile period of less than a week precedes presentation with elevated respiratory rate. CT imaging may show ground glass opacities, ground glass consolidation, bronchial wall thickening, and "tree in bud" changes. Hilar lymphadenopathy may be present. Patients typically recover.[683]

Human herpesvirus 6 (HHV-6) infects at least 90% of all persons by two years of age and can reactivate in immunocompromised hosts to produce a severe pneumonitis. Such reactivation of latent infection in persons with AIDS may be the cause for a fatal pneumonitis. HHV-6 can be found in other tissues as well, and lymphoid tissues are the reservoir for HHV-6 infection. HHV-6 can be demonstrated in tissues by immunohistochemical staining.[684]

**KAPOSI SARCOMA (KS).**-- The clinical diagnosis of pulmonary KS can be difficult because KS is difficult to distinguish from opportunistic infections. The diagnosis is made more likely when a previous skin biopsy has demonstrated KS. However, up to 1 in 5 persons with pulmonary KS may not have skin involvement. Most patients with pulmonary KS will present with fever, non-productive cough, and dyspnea. Hemoptysis and chest pain are additional common findings. Hoarseness and stridor may suggest upper airway involvement of larynx and trachea.[685]

Radiographic findings are not specific and may include bilateral perihilar and lower lobe reticulonodular, interstitial, or alveolar infiltrates in over half of cases. The presence on chest radiograph of abnormal hilar densities with perivascular or peribronchial extension into adjacent pulmonary parenchyma is suggestive of KS. Also, a bronchocentric pattern of bronchial wall thickening, nodules, Kerley B lines, and pleural effusion can be additional findings seen in association with pulmonary KS. Chest CT scans can demonstrate “flame shaped” nodules with a halo of ground glass attenuation, bronchial wall thickening and spiculated lesions with poorly marginated nodular infiltrates radiating out from the hilum and from bronchovascular structures into interlobular septae, and endobronchial lesions. Interlobular septal thickening can occur with tumor invasion and lymphatic obstruction. Hilar lymphadenopathy tends to be seen as a late finding. Gallium scans may help to distinguish KS from infections[648,685]

A diagnosis of KS is suggested by the finding on fiberoptic bronchoscopy of raised, cherry-red to violaceous macular to papular endobronchial lesions averaging several millimeters in size. This finding is often regarded by experienced bronchoscopists as diagnostic, even in the absence of histological support, and the vascular nature of KS can produce copious bleeding with biopsy. Transbronchial biopsy is often nondiagnostic, because of the focal distribution of the lesions, lack of endobronchial lesions, distal lesions, and the predominantly submucosal location with subsequent sampling error, and because of the sparse amount of tissue obtained. Pleural biopsy and pleural fluid cytology have a very poor yield for diagnosis of KS. The non-specific finding of increased hemosiderin-laden macrophages in bronchoalveolar lavage fluid is suggestive of KS. Open lung biopsy has a diagnostic yield of only 50% and is rarely performed due to potential complications.[660]

Grossly at autopsy, KS lesions of lung appear as firm dark red to purple nodular areas, most often surrounding large bronchi or blood vessels for a distance of 1 to 5 mm, or as subpleural nodules. Up to 10% of lesions can be white or tan rather than red or purple. With extensive involvement, the lesions may become almost confluent. Nodules of KS may also appear on bronchial or tracheal mucosal surfaces.

Microscopically, KS in lung shows infiltrates of atypical spindle cells with endothelial-lined, slit-like spaces containing red blood cells. The pattern of KS is infiltrative into the lung parenchyma, and the lesions of KS also tend to surround blood vessels and bronchioles or form subpleural nodules. Extravasated red blood cells, hemosiderin, plasma cells, and lymphocytes may also be present. When accompanied by organizing pneumonia or diffuse alveolar damage, KS may be difficult to diagnose, and cellular atypia helps to distinguish the lesions of KS from inflammatory or reparative changes.

**MALIGNANT LYMPHOMAS.**-- Pulmonary non-Hodgkin lymphoma (NHL) in patients with AIDS will have a similar gross and microscopic appearance as elsewhere. In most cases, the lung is secondarily involved due to widespread dissemination. NHL limited to the lung in AIDS is very uncommon, only 6% of NHL cases, and the number of cases has diminished with

increasing use of antiretroviral therapy. Primary pulmonary NHLs are diagnosed when there is absence of mediastinal and/or hilar lymphadenopathy and absence of extrathoracic extension. Cough and dyspnea with tachypnea are the usual clinical findings.[686]

Such primary NHL's of lung are typically of a high grade B cell histologic type with demonstrable Epstein-Barr virus in tumor cells. They are not usually accompanied by pleural effusions, but they may cavitate. Thus, in the absence of an infectious cause, the presence of multiple peripheral pulmonary nodules and/or masses without hilar or mediastinal adenopathy and without pleural effusion suggests a primary pulmonary NHL. The best diagnostic yield comes from use of percutaneous transthoracic needle biopsy.[686]

Malignant lymphomas can have a bronchovascular distribution (where lymphatic vessels are found), or less commonly they may present as one or more definable mass lesions. Rarely, they may appear only as malignant effusions (primary body cavity-based lymphomas), without a definable mass lesion.[611]

Radiographically, pulmonary NHLs can appear as well-defined large, solitary or multiple nodular opacities. The most common findings include lobular consolidation, nodules, reticular infiltrates, and masses. Hilar adenopathy is not common, but a pleural effusion may be present along with parenchymal involvement. Unilateral or bilateral moderate to large effusions can occur.[646,648,686]

**LYMPHOID INTERSTITIAL PNEUMONITIS.**-- Lymphoid interstitial pneumonitis (LIP) is associated with, but no longer considered a defining disease for AIDS in childhood.[420,421] LIP is neither diagnostic of, nor frequently seen with, AIDS in the adult. It must be differentiated from other infiltrative and interstitial pulmonary diseases. Tissue diagnosis of LIP is usually made with an open lung biopsy, because bronchoscopic biopsies are frequently nondiagnostic. Peripheral blood may show plasmacytosis and eosinophilia. A presumptive clinical diagnosis of LIP for definition of AIDS requires that bilateral reticulonodular interstitial pulmonary infiltrates must be present on chest roentgenogram for  $\geq 2$  months with no pathogen identified and no response to antibiotic treatment.[687]

Lymphoid interstitial pneumonitis may present with progressive dyspnea and dry cough, along with systemic symptoms such as fever, night sweats, and weight loss. LIP cannot be distinguished grossly. The radiographic pattern in children as seen on plain radiographs and with computed tomography most often reveals a bilateral diffuse, symmetric, reticulonodular or nodular pattern that is occasionally associated with hilar adenopathy.[650,688] The radiographic appearance in adults, best seen with high-resolution CT imaging, can resemble *Pneumocystis jiroveci* (*carinii*) pneumonia and include thickened bronchovascular bundles, variably sized nodules in either centrilobular or subpleural locations, cysts ranging from 1 to 30 mm, and bilateral ground glass opacities.[689]

The earliest microscopic pathologic finding is hyperplasia of bronchial associated lymphoid tissue with aggregates of lymphocytes and plasma cells in a bronchovascular distribution with minimal interstitial inflammation. In more advanced lesions, all lung fields demonstrate a diffuse interstitial infiltrate of lymphocytes, plasma cells, and macrophages. Additional features can include lymphoid aggregates with germinal centers, intraluminal fibrosis, increased alveolar macrophages, and type II pneumocyte hyperplasia. Advanced cases may demonstrate confluent pulmonary nodules several centimeters in size. Rarely, poorly formed granulomas may be present.[644,690]

Unlike chronic or nonspecific interstitial pneumonitis, LIP is more florid and extensive and has a tendency to infiltrate alveolar septae. LIP, unlike malignant lymphomas, has a predominance of small lymphocytes along with a mixture of inflammatory cell types. Immunohistochemical staining of questionable infiltrates will demonstrate a polyclonal cellular proliferation with LIP.[687] Lymphoid interstitial pneumonitis rarely results in progressive pulmonary interstitial fibrosis.[644,690] Progression to lymphoma is possible but not common. Many cases of LIP are accompanied by detectable Epstein-Barr virus (EBV) in lung tissue.[689] There is a variable response to corticosteroid therapy. From a third to half of patients with LIP die within 5 years of diagnosis and about 5% transform to lymphoma.[689]

Accompanying LIP may be a pattern of pulmonary lymphoid hyperplasia (PLH) that is characterized by lymphoid follicles with or without germinal centers that often surround bronchioles. The most florid form of lymphoid hyperplasia involving lung is seen in HIV-infected children and is known as polyclonal B-cell lymphoproliferative disorder (PBLD). With PBLD there are nodular infiltrates of polyclonal B-lymphocytes and CD8+ T-lymphocytes. Other organs may also be involved by PBLD.[691]

**NONSPECIFIC INTERSTITIAL PNEUMONITIS (NSIP).**-- Some bronchoscopic biopsies in adult AIDS patients reveals the presence of an interstitial pneumonitis with lymphocytic infiltrates, but no identifiable organisms. It is a subacute to chronic interstitial pneumonitis, but lacking features more diagnostic of idiopathic pulmonary fibrosis (IPF), desquamative interstitial pneumonia, or bronchiolitis obliterans. NSIP may represent a *Mycoplasma* or viral pneumonitis, such as influenza, without diagnostic pathologic features. A careful search for viral inclusions should be made, in addition to performance of histologic stains for fungi, mycobacteria, and *Pneumocystis jiroveci* (*carinii*). Sometimes, only multinucleated cells suggestive of viral effect are found. Multiple viral serologic studies are often not useful. Clinically, non-specific interstitial pneumonitis mimics *Pneumocystis* pneumonia or lymphocytic interstitial pneumonitis. Thus, not all cases of pneumonitis in AIDS have a definable cause despite an extensive search for etiologies. Though lymphoid aggregates may be present, the lymphocytic infiltrates of NSIP tend to be less extensive than those of lymphoid interstitial pneumonitis and restricted to peribronchiolar, perivascular, paraseptal, and pleural regions. Clinically, patients with nonspecific interstitial pneumonitis often have a normal chest roentgenogram; high-resolution CT imaging may show bibasilar ground glass attenuation. Unlike IPF, there may be a response to corticosteroid therapy.[690,692]

**MISCELLANEOUS PULMONARY LESIONS IN AIDS.**-- The pulmonary interstitium may show small foreign body granulomata with needle-shaped crystalline material that is birefringent under polarized light in patients with a history of injection drug use. Only rarely are these granulomata visible as 0.1 to 0.3 cm pale tan nodules. Rarely are they accompanied by extensive interstitial fibrosis.[693]

When patients with AIDS receive antiretroviral therapy and are diagnosed and treated for opportunistic infections of the lungs, their survival is increased. However, increasing survival with multiple, recurrent, and prolonged bouts of infections results in a greater incidence of bronchiectasis. Bronchiectasis in association with HIV infection is most often seen following recurrent pyogenic infections, tuberculosis, and lymphoid interstitial pneumonitis, typical when the CD4 lymphocyte count is below 100/ $\mu$ L.[648,694]

Pulmonary arterial hypertension (PAH), with mean arterial pressure >25 mm Hg at rest and normal pulmonary wedge pressure of 15 mm Hg or less, has appeared with increased frequency with longer survival in association with HIV infection and AIDS. The prevalence is now estimated at 0.5%. Clinically HIV-PAH resembles cases of primary or idiopathic pulmonary hypertension in non-HIV-infected patients. Unlike familial PAH, it is not associated with mutations in the bone morphogenetic protein type 2 receptor (*BMPR2*). Reported risk factors include intravenous drug abuse, viral hepatitis, atrial septal defect, splenectomy, and portal hypertension. Most patients have a CD4 lymphocyte count above 200/ $\mu$ L and an undetectable viral load in peripheral blood. Patient findings can include progressive shortness of breath, pedal edema, dry cough, fatigue, syncope, and chest pain. Chest x-ray may show cardiomegaly and prominent pulmonary arteries. An electrocardiogram may show right ventricular hypertrophy. On cardiac catheterization the pulmonary arterial systolic pressure, diastolic pressure and pulmonary vascular resistance are increased. Sildenafil has been utilized in treatment.[695,696]

The histopathologic findings in HIV-PAH include pulmonary arteriopathy with medial hypertrophy, intimal thickening and/or plexiform lesions (89%), with veno-occlusive disease in 7% and thrombotic pulmonary arteriopathy in 4%. Treatment regimens may include use of epoprostenol, bosentan, iloprost, and sildenafil. The course is slightly more fulminant than in patients with primary PAH, with a third of patients dying in within 5 years.[695,696]

Chronic obstructive pulmonary disease (COPD), including pulmonary emphysema and chronic bronchitis, are found with increased prevalence because HIV-infected persons are more likely to have been smokers or to be current smokers than non-infected persons. However, COPD occurs in association with HIV infection independently of other risk factors such as smoking.. The pathogenesis of parenchymal destruction of distal airways may begin with cytotoxic lymphocyte (CTL) activation, followed by capillary endothelial cell injury, then CTL-induced apoptosis. HIV proteins tat and nef enhance endothelial cell apoptosis. Small airway hyperreactivity, sphingolipid imbalance and oxidative stress may also contribute to ongoing lung injury. *Pneumocystis jiroveci* infection and colonization may also be implicated in development of COPD. The initiation of antiretroviral therapy can lead to immune reconstitution inflammatory syndrome that enhances pulmonary injury.[697,698]

Pleural effusions are relatively common in association with a variety of infectious pulmonary complications of HIV infection. The most common infectious cause of AIDS-associated pleural effusions is bacterial pneumonia. Sometimes, the pneumonia may be severe enough to result in empyema. *Mycobacterium tuberculosis* is another frequent cause for pleural effusion. Of neoplasms seen with AIDS, Kaposi sarcoma is most likely to result in the finding of pleural effusion, particularly with bilateral effusions. Though *P. jiroveci* is frequent in AIDS, it is less likely to result in effusions; however, it is the most likely cause for spontaneous pneumothorax, which complicates the course in 1 to 2% of hospitalized patients with HIV infection. Radiographic evidence for cysts, bulla, or pneumatoceles suggests a risk for pneumothorax. A third of these patients may die.[699,700]

There is an increased risk for development of chronic obstructive pulmonary disease in HIV-positive patients (odds ratio 1.47). Thus, COPD will increase as persons with HIV live longer. The cause for this association is unclear.[701]

UPPER RESPIRATORY TRACT IN AIDS.-- The epiglottis, pharynx, larynx, and trachea can also be affected by AIDS-diagnostic diseases. The commonest are invasive

candidiasis and Kaposi sarcoma. Kaposi sarcoma has a predilection for the epiglottis. Clinical findings of stridor and hoarseness may suggest KS involvement of the upper airway. Biopsy can be done, but granulation tissue formed with long-standing intubation or ulceration from infectious agents may be difficult to distinguish from KS. In order for the presence of *Candida* to be diagnostic of AIDS, it must be demonstrably invasive (most commonly in trachea) and not be found just in secretions.[685]

**CLINICAL DIAGNOSTIC TECHNIQUES.**-- Roentgenographic imaging procedures are often employed. Contrast enhanced CT imaging provides the best sensitivity, including disease-specific sensitivity, for diagnosis of HIV-related conditions.[702] with Gallium scintigraphy may be performed to aid pulmonary diagnosis. Diffuse bilateral parenchymal uptake is most often associated with PJP, particularly if uptake is intense and heterogenous. A negative Gallium scan in a patient with Kaposi sarcoma and an abnormal chest radiograph suggests respiratory disease due to Kaposi sarcoma. Lymph node uptake of Gallium is typically associated with mycobacterial infection (MAC or MTB) and lymphoma. Gallium positive with thallium negative studies suggest mycobacterial disease.[703]

The alveolar exudate of PJP is generally adherent to alveolar walls so that routine sputum samples are insensitive for diagnosis. Use of induced sputum can increase sensitivity to 70% for PJP, but repeat testing does not increase this sensitivity.[704] Bronchoalveolar lavage (BAL) is the most useful technique for diagnosis and can detect PJP in over 90% of cases, compared with a tissue biopsy yield of 56%. The diagnostic yield can be increased to 95% with multiple lung lobe sampling, particularly the upper lobes. BAL is the most useful technique for diagnosis of opportunistic pulmonary infections in AIDS, particularly cytomegalovirus and cryptococcosis.[664]

Fiberoptic bronchoscopy is an excellent method for diagnosis of pulmonary complications and enables sampling by transbronchial biopsy (TBB), bronchial brushings (BB), and bronchoalveolar lavage (BAL). With TBB, obtaining a larger number and/or size of specimens provides a greater chance of making a specific diagnosis through reduction of sampling error. The greatest diagnostic sensitivity (when the biopsy contains alveoli) is for *Pneumocystis jiroveci* (*carinii*), between 60% to 100% for most reported series. Overall, the diagnostic yield of TBB in AIDS is good. The complication rate for TBB is low.[705]

Fine needle aspiration (FNA) cytology can be useful for diagnosis. In cases of *Mycobacterium tuberculosis*, FNA has a sensitivity of 46% with a specificity of 100%. Use of PCR can increase the sensitivity to 84%.[664]

Bronchoscopy with BAL samples a large number of alveoli and the diagnostic sensitivity exceeds that for induced sputum or TBB for diagnosis of PJP. Thus, BAL is the procedure of choice for diagnosis of PJP.[706] Yield can be enhanced by sampling two areas of the lung and/or by directing lavage to the area of lung with the most radiographic infiltrate, particularly upper lobes. The overall diagnostic yield of BAL in patients with AIDS that present with respiratory symptoms is greater than 50%. The most common agent found with BAL in this setting is *P. jiroveci* (*carinii*). Culture of BAL material for *Mycobacterium tuberculosis* (MTB) can be useful, with a yield of 95%. Direct fluorescence antigen detection with culture for CMV can be done, but a positive result does not always correlate with the presence of CMV pneumonia, and CMV may be identified by BAL in half of HIV-infected persons. A BAL procedure is useful when biopsy is contraindicated in patients with a coagulopathy or on mechanical ventilators.[682,705]

By combining TBB and BAL, the diagnostic sensitivity for PJP and MTB approaches 100%, when adequate samples are collected. The high diagnostic sensitivity of TBB and/or BAL for PJP has virtually eliminated the need for open lung biopsy. The sensitivity of BAL for PJP in patients receiving aerosolized pentamidine is increased when BAL includes upper lobes.[651]

Unfortunately, TBB or BAL is less sensitive for diagnosing other pulmonary complications of AIDS. Organisms such as *Aspergillus*, and *Candida* may be frequently identified in BAL specimens, but may not necessarily be pathogens in some cases.[663,682,705] The diagnostic yield of BAL is also reduced in HIV-infected patients who have received empiric treatments for suspected infections prior to the performance of bronchoscopy with BAL, and the results of BAL may lead to a change in treatment following definitive diagnosis.[707]

Kaposi sarcoma (KS) may be difficult to identify on bronchoscopy because the bulk of the tumor mass is below the mucosa. The low yield coupled with the risk for bleeding from highly vascular KS lesions often precludes a biopsy diagnosis by bronchoscopy. A high-grade lymphoma may involve the lungs in AIDS, but open lung biopsy is required for diagnosis. Interstitial pneumonitis, either non-specific interstitial pneumonitis or lymphoid interstitial pneumonitis, requires open lung biopsy for histologic diagnosis, but these conditions are more often diagnosed on clinical features.[705]

Routine hematoxylin-eosin, methenamine silver, and acid fast stains should be performed on histologic sections or smears of samples obtained.



## GASTROINTESTINAL TRACT PATHOLOGY IN AIDS

The gastrointestinal (GI) tract is the second most common organ system site for opportunistic infections or neoplasms associated with AIDS. The GI tract and its abundant lymphoid tissue serve as a reservoir for ongoing HIV proliferation. Chronic HIV infection of the GI tract depletes protective CD4 cells and T<sub>H</sub>17 lymphocytes while increasing inflammatory cytokines that disrupt the epithelial barrier from damage to cellular tight junctions as well as translocation of luminal bacteria.[50,89]

HIV has been demonstrated to infect gastric epithelial cells. How HIV enters gastric epithelium is unknown. The extent of this infection correlates with plasma viral load and advancing stage of HIV infection. Gastric involvement by HIV may explain gastropathy and increased risk for opportunistic infections.[708]

The most frequent clinical symptom resulting from GI involvement is diarrhea, and the etiologies for this symptom are numerous. Diarrhea may appear with acute HIV infection, but typically it is manifested in patients with clinical AIDS.[525,709] In a few cases this diarrhea may be severe and life threatening. In patients receiving antiretroviral therapy (ART), the frequency of gastrointestinal involvement with opportunistic infections is greatly diminished.[710]

In general, pathogens that involve the small intestine produce signs and symptoms that include large volume watery stools (up to 10 L/day), abdominal cramping, bloating, gas, and weight loss with wasting syndrome. Malabsorption can lead to vitamin and other nutrient deficiencies. Bacterial pathogens involving the colon most often produce frequent but small volume stools with painful defecation. Fever is often present. The stools can be bloody or mucoid with leukocytosis, typical for colitis. Stool culture provides a definitive diagnosis. Septicemias in association with infections of the gastrointestinal tract are uncommon.[538]

When the CD4 lymphocyte count is below 200/ $\mu$ L, the likelihood of finding an infection in association with diarrheal illness is increased, and is low with CD4 counts above 500/ $\mu$ L.[711] In many cases, examination of stool for ova and parasites, stool culture, and tissues from endoscopic biopsy procedures may reveal an etiologic agent for the diarrhea. Sometimes no specific cause can be identified, and only chronic nonspecific inflammation with small intestinal villous atrophy and crypt hyperplasia is seen on biopsy.[709]

A cost-effective strategy for clinical management of diarrhea employs initial use of stool culture and direct microscopy of stool specimens, with additional diagnostic testing for non-respondents to symptomatic treatment. Esophagogastroduodenoscopy (EGD), or colonoscopy with biopsy, comprises the second phase of this evaluation. The use of EGD in cases where esophageal symptoms are refractory to antifungal therapy, or when gastrointestinal bleeding is present, is more likely to generate findings that influence subsequent patient management. EGD is less useful for evaluation of abdominal pain, nausea, and vomiting. Small intestinal biopsies, particularly those from the jejunum, are useful for histopathologic diagnosis, but small intestinal aspirates are of little value.[525,712] The distribution of AIDS-diagnostic diseases in GI tract is shown in Table 5. About 7% of deaths in AIDS patients result from diseases of the gastrointestinal tract.[448]

**FUNGAL INFECTIONS.**-- Oral candidiasis in the form of thrush is a frequent finding in patients with HIV infection that presages development of clinical AIDS or occurs in association

with AIDS.[511] The risk for development of oral thrush is increased with smoking.[233] Persons who have a T-helper 2 (HT-2) type of cytokine response to HIV infection have an increased susceptibility to mucosal candidiasis.[713]

*Candida* esophagitis is one of the most common GI tract manifestation of AIDS in both adults and children, and patients with oral and esophageal candidiasis usually present with odynophagia and/or dysphagia. For use of candidiasis as a presumptive clinical diagnosis for definition of AIDS, there must be:[421]

- a. Recent onset of retrosternal pain on swallowing; AND
- b. Oral candidiasis diagnosed by the gross appearance of white patches or plaques on an erythematous base or by the microscopic appearance of fungal mycelial filaments in an uncultured specimen scraped from the oral mucosa.

Oral candidiasis can appear in multiple sites or on large areas of oral mucosa. There are four clinical variants. Thrush, or pseudomembranous candidiasis (PC), is characterized by yellow-white plaques that can be removed by scraping. Removal leaves an erythematous and slightly hemorrhagic surface. This variant most often affects the tongue. Angular cheilosis (AC) is the next most common form and characterized by erythematous fissuring at one or both corners of the mouth, and other organisms such as staphylococci or streptococci may contribute to the findings. Erythematous candidiasis (EC) is marked by erythematous macular mucosal patches due to increased vascularity with or without epithelial atrophy. The number of CD4 cells in the inflammatory response appears diminished in both PC and EC. Hyperplastic candidiasis (HC) is the least common variant and is marked by hyperkeratotic white plaques that cannot be removed by scraping, and it is located most often on the buccal mucosa. These variants have no significance in terms of patient prognosis.[511,714]

Diagnosis of oral candidiasis may be made microscopically by finding typical budding yeasts with pseudohyphae. A scraping with smear stained with potassium hydroxide (KOH) may aid in finding the organisms. Acute inflammatory cells are often present. On biopsy, the organisms may invade superficially. Though visible with routine H&E staining, the periodic acid-Schiff (PAS) stain aids in demonstrating the organisms, particularly when extensive inflammation and necrosis is present. An overlying pseudomembrane of neutrophils, fibrin, and parakeratotic debris can be present. The squamous epithelium often shows acanthosis, though in the hyperplastic pattern there may also be hyperkeratosis with dysplastic changes.[715]

The esophageal plaques of *Candida* are often adherent to the underlying mucosa and may bleed when removed. Biopsy (or scraping of oral mucosa for cytologic examination) may show budding yeasts and pseudohyphae on the epithelial surface. There may be superficial invasion of the submucosa. Invasive, inflamed lesions may have irregular ulceration, but deeply invasive lesions with perforation do not occur. *Candida* is typically not a cause for diarrhea in persons with AIDS.[511,525]

Radiologic findings in association with esophageal candidiasis include discrete linear or irregular longitudinally oriented filling defects that represent the heaped-up mucosal plaques. Esophagography may reveal a markedly irregular, shaggy mucosal appearance with more advanced esophageal disease.[447]

Though no primary prophylaxis is indicated, persons with frequent oral candidiasis may benefit from clotrimazole troches or topical nystatin to prevent progression to esophageal infection. For further treatment of recurrent oral or for esophageal candidiasis, fluconazole or

ketoconazole are given.[223] Treatment of dental caries may be useful to help control oral candidiasis, since dentinal carious lesions provide a location for *Candida* colonization.[716]

The fungi *Cryptococcus neoformans*, *Histoplasma capsulatum*, and *Coccidioides immitis* may produce focal inflammation. The GI tract is usually involved only when there is widespread dissemination. These organisms are most likely to be found in the submucosa or on the mucosa. Grossly visible features of gastrointestinal histoplasmosis include mucosal ulceration, nodules, and hemorrhage. Obstructing masses are not common. The mucosa can appear normal even when involved. Microscopic findings include diffuse lymphohistiocytic infiltration and ulceration. Often a minimal inflammatory reaction is present. Well-formed granulomas are not common.[717] Radiographic features of colonic histoplasmosis include segmental colonic inflammation, apple-core lesions that may mimic primary adenocarcinomas, and stricture.[447]

Cryptococcal infection is most likely to affect the colon and esophagus. Stomach and terminal ileum are rarely involved. Histoplasmosis is most likely to involve the ileocecal region, and complications such as bleeding, ulceration, obstruction, and strictures are rare.[718]

**PROTOZOAL INFECTIONS.**-- Gastrointestinal protozoal infections in patients with AIDS are frequent. They can be asymptomatic, but the most common symptom is diarrhea. They are transmitted via a fecal-oral route, typically from contaminated food or water containing the infective spores (oocysts), from person to person. Infection from inhalation of spores has also been postulated. In persons who remain relatively healthy, the diarrhea is usually self-limited, but in the later stages of AIDS, particularly when the CD4 count is  $<100/\mu\text{L}$ , protozoal infections are more frequent and patients can have protracted diarrhea, though death from protozoal infections alone is not common.[525] Combination antiretroviral therapy, including a protease inhibitor, has been shown to be effective in improving immune function to lessen the effects of these pathogens.[719]

Endoscopic features that suggest protozoal infection include irregular, fused, widely-spaced, shortened villi that result in an erythematous, granular, friable appearance.[718]

*Cryptosporidium parvum* infection can produce enteritis with significant diarrhea in patients with AIDS. Cryptosporidiosis can occur in both immunocompetent and immunocompromised hosts, but in the former it is mainly a cause for self-limited diarrhea of 1 to 2 weeks duration in children. In immunocompromised hosts cryptosporidiosis can be the cause for a life-long, protracted diarrhea that is refractory to therapy. Cryptosporidiosis is a chronic infection in about half of affected AIDS patients, while it is transient in about one fourth, and fulminant in less than 10%. It is estimated to afflict 10 to 20% of patients with AIDS and diarrhea in the U.S., and half of such patients in developing nations. Cryptosporidiosis produces a voluminous, watery diarrhea with 6 to 25 bowel movements per day with a maximum stool volume of 1 to 17 liters.[526] It is often accompanied by abdominal cramps, low-grade fever, anorexia, electrolyte imbalance, dehydration, and weight loss, though it rarely leads to death.[448,525] No effective treatment has been developed. *Cryptosporidium* organisms may also be found in biliary tract, pancreas, and lung.[526,525,709,720,721]

Radiographic features of cryptosporidiosis in the small intestine include thickened mucosal folds when inflammation is present, or effacement of folds with villous atrophy. There can also be blunting, fusion, or loss of villi. Increased fluid secretion can lead to dilution of barium.[447]

*Cryptosporidium* does not usually produce grossly visible lesions such as erosions, ulcers, or masses, though there may be mild erythema and granularity. Microscopically on small

intestinal biopsy samples, cryptosporidia are small 2 to 4 micron sized round organisms that occur singly or in rows along the mucosal brush border from villi to crypts, sometimes accompanied by acute inflammation and crypt abscesses. They are best diagnosed by examination of stool specimens with acid fast stain under oil immersion.[432] Giemsa and PAS stains may also demonstrate these organisms. On electron microscopy, the organisms appear embedded in a cytoplasmic vacuole on the microvillus border.[526,715] Postmortem diagnosis may be precluded by autolysis. Therapy for chronic *Cryptosporidium* infection consists of paronomycin.[525]

*Isospora belli* is more common in tropical regions than in temperate climates. It may produce a protracted watery diarrhea lasting for months, along with steatorrhea and abdominal pain, similar to *Cryptosporidium* in patients with AIDS, and extraintestinal dissemination has been documented to colon and regional lymph nodes. Diagnosis is typically made by finding large 20 to 30 micron oval oocysts in stool, aided by acid fast staining. Eosinophilia may be present, and this suggests additional helminthic infection. Biopsy of small intestine may show *Isospora* organisms within the intestinal lumen or within cytoplasmic vacuoles in mucosal cells in mucosa with mild inflammation and atrophy. Oocysts may appear in stool samples; merozoites require electron microscopy for diagnosis.[432,526,525,718,722] *Isospora* can be treated with trimethoprim-sulfamethoxazole.[525]

Microsporidial infections (caused by *Enterocytozoon* species including *E bienersi*, *E cuniculi*, and *E hellum*, and by *Encephalitozoon (Septata) intestinalis*) have a similar clinical presentation to *Cryptosporidium*. However, microsporidiosis is characterized by fewer watery stools per day, a more gradual weight loss, maintenance of appetite, and lack of fever. Microsporidial infections can be more frequent than cryptosporidial infections in AIDS when diagnostic techniques are available and can best be diagnosed on small intestinal biopsy samples using light microscopy with Giemsa staining or by transmission electron microscopy. Stool examination can be more sensitive than intestinal biopsy for diagnosis. The organisms are most numerous in the jejunum, but they have also been reported as a cause for cholangitis. [526,525,715]

Grossly, microsporidial infections do not produce striking changes, though mucosal erythema and granularity may be seen on endoscopy. By light microscopy, there may be partial villous atrophy with blunted villous tips from mucosal cell destruction. Crypt hyperplasia and lamina propria inflammation are variable. The 4 to 5 micron meronts and sporonts are clustered in the supranuclear intracytoplasmic region of villous mucosal cells. The 1 to 2 micron spores are acid fast, and can also be seen by light microscopy in smears of stool or duodenal aspirates by use of a modified trichrome stain.[530,533,715] Treatment with albendazole has been recommended for *Septata* infections, while no effective therapy exists for *Enterocytozoon* infections.[525]

Infection with the small coccidian organism *Cyclospora cayetansis* produces an appearance clinically similar to cryptosporidiosis.[533] Stool examination provides the diagnosis with acid fast staining for organisms that resemble a large cryptosporidium; they are 8 to 10 micron with a double cyst wall and a central morula.[526] On small intestinal biopsy there can be mild to moderate acute and chronic inflammation of lamina propria with prominent plasma cells along with focal vacuolization of the brush border and mild to moderate partial villous atrophy and crypt hyperplasia. Cyclosporiasis has a high recurrence rate. Treatment with trimethoprim-sulfamethoxazole appears to be effective both for acute infections as well as for prophylaxis.[525,530,533]

*Giardia lamblia* infections may occur with or without diarrhea, casting doubt about the pathogenicity of this organism. In addition to diarrhea there may be abdominal cramps, bloating, and flatulence. Chronic infections can cause malabsorption and steatorrhea. By endoscopy, the small intestinal mucosa may appear mildly erythematous. On biopsy, the mucosa often demonstrates no significant changes, and the organisms are mainly intraluminal, sometimes attached to epithelium, and appearing as 3 by 8 micron amphophilic to eosinophilic pear-shaped flagellated trophozoites with two indistinct nuclei. Stool examination can demonstrate cysts of *G lamblia* for diagnosis. Metronidazole is an effective treatment.[715,718]

Infections with other intestinal protozoa, such as *Blastocystis hominis* have also occurred in patients with AIDS, but not to a significant degree. They may cause diarrhea, often mild and similar to that seen in immunocompetent hosts, but they are usually enteric commensals.[525,709,723]

Infection with *Entamoeba histolytica* is not common, but may occur in endemic areas. More severe cases can lead to bowel perforation and amebic peritonitis. The features of amebiasis with HIV infection are similar to those in immunocompetent hosts, with acute necrotizing inflammation causing flask-shaped mucosal ulceration. The amoebae in the necrotic debris exhibit erythrophagocytosis, as well as a “washed out” nuclear appearance and strong PAS-positive cytoplasmic staining.[724]

Visceral leishmaniasis, caused by *L donovani*, may affect the gastrointestinal tract, and the amastigotes may be seen in macrophages scattered in the lamina propria with hematoxylin-eosin or Giemsa stains.[556]

Coccidian infections are common in animals such as dogs, producing the disease known as sarcocystis, which is predominantly a gastrointestinal infection, though dissemination to other internal organs or to muscle is possible. Diarrheal illness from sarcocystis has been reported with AIDS. Intestinal biopsies may demonstrate the microgametocyte and macrogametocyte stages of sarcocystis in the lamina propria, and the schizont stage may be seen in liver, by light microscopy. Sporulated oocysts may be found in stool.[725]

**BACTERIAL ENTERIC INFECTIONS.**-- Besides the usual opportunistic infections, bacterial infections can occur in association with HIV infection. Enteric bacterial pathogens may produce more severe, recurrent, or persistent disease in HIV-infected persons, or be more likely to produce extraintestinal disease. Enteric bacterial infections usually produce stools that do not contain occult blood or leukocytes. Definitive diagnosis is made by stool culture.[538,726] Endoscopic features include epithelial necrosis, abscesses, erosions, ulceration, and focal hemorrhages. Biopsy microscopic findings can include epithelial degeneration and regeneration, necrosis, fissuring, and cellular atypia.[718]

*Salmonella* species (not *typhi*) can occur in persons at risk for HIV infection, but most often after clinical AIDS is apparent. Gastrointestinal *Salmonella* infections have a propensity to result in septicemia and to relapse, particularly when CD4 lymphocyte counts are low. Recurrent *Salmonella* infection is a criterion for diagnosis of AIDS in adults and children, and when suspected blood culture should be performed.[420,421] Fever is common. Recurrence or failure to respond to antibiotic therapy may occur, though amoxicillin, trimethoprim-sulfamethoxazole, or ciprofloxacin appear to be appropriate therapeutic choices for *Salmonella* or *Shigella* infections. Patients taking zidovudine have a lower risk for development of salmonellosis. Typhoid fever has been infrequently reported in men having sex with men, and in association with AIDS.[538,709,726]

*Campylobacter jejuni* infections often appear after development of clinical AIDS and are more frequent and severe than in patients without AIDS. *Campylobacter jejuni* infections are best treated with either erythromycin or ciprofloxacin.[709] Enteropathogenic *E. coli* are seen with HIV infection, most often in association with persistent diarrhea in children of developing nations.[538,709,726] *Helicobacter pylori* infection can appear in HIV-infected persons with chronic gastritis, with a similar histologic appearance of inflammation, erosions, or ulcers, but with a lower incidence than that for non-HIV-infected persons.[727] HIV-infected patients with *H. pylori* have a higher mean CD4 count than persons infected with HIV who do not have *H. pylori*. The gastritis associated with *H. pylori* is more severe in persons with HIV infection.[728] Occasionally, a low-grade small intestinal bacterial overgrowth of mostly aerobic bacteria may lead to malabsorption and diarrhea.[709]

*Clostridium difficile* infection (CDI) may occur in AIDS patients treated with broad-spectrum antibiotics such as trimethoprim-sulfamethoxazole, macrolides, cephalosporins, penicillins, and clindamycin and may produce a pattern of pseudomembranous colitis. CDI is the presence of diarrhea or ileus in association with *C. difficile* or its toxins. Risk factors for CDI with HIV-infection include CD4 count below 50/ $\mu$ L, exposure to a health care setting in the prior 12 weeks, onset while in hospital, and use of broad spectrum antibiotics. The most common presentations were diarrhea in over 80% and bloody stools in over 23% of cases. Recurrence of CDI was 17% and more likely to occur when the CD4 lymphocyte count was at or below 350/ $\mu$ L. The incidence of CDI is unlikely to diminish despite antiretroviral therapy.[729]

CDI may account for 10% to 50% of episodes diarrhea in hospitalized HIV-infected patients, while 6% to 34% are colonized and asymptomatic. The presentation of CDI with HIV infection is similar to CDI in general with diarrhea, abdominal pain, and fever. Additional features of severe CDI include high fever, hypotension and renal impairment, ascites, toxic megacolon and markedly elevated alkaline phosphatase. With advanced immunosuppression there may be a protein losing enteropathy. Radiological findings with severe colitis include colonic dilation, mural thickening, or thumb printing. Endoscopy shows findings that may include erythema, severe colitis with evidence of pseudomembranes, and atypical polypoid lesions. Culture or PCR can identify the organism; tissue culture cytotoxin B assay or enzyme immunoassay for TcdA or TcdB can detect the toxin. Gross or microscopic evidence of pseudomembranous colitis can be seen at endoscopy or with colectomy.[730]

The epidemiology of CDI in the general population since 2000 has changed, with increased incidence, then emergence and then decline of the NAP1/027 epidemic strain, and greater failure rates with metronidazole treatment. *C. difficile* strains may be associated with higher rates of antimicrobial resistance than isolates from persons without HIV. CDI recurrence in HIV-seropositive individuals appears to be similar to the 15–35% rates in the general population, even with low CD4 counts.[730]

Diarrhea producing (enteropathogenic) strains of *E. coli* are important worldwide as causes for diarrhea in travelers and in infants, but also can cause diarrhea in immunocompromised patients. Such strains can most often be identified by assay specifically for enteropathogenic *E. coli*. They may also be known as enteroadherent bacteria. Histopathologic findings are those of "non-specific" colitis with little crypt distortion or cryptitis, but with focal epithelial cell necrosis or degeneration, breaks or gaps in the surface epithelium, aggregates or tufts of epithelial cells, and cellular debris. The inflammatory reaction consists of a few neutrophils and a moderate increase in lymphocytes. The bacteria are most often seen along the epithelial surface or brush border and are rarely invasive. Identification methods for

these strains are not commonly available, so empiric antibacterial therapy with response may suggest *E. coli* as a cause for AIDS enteropathy.[731]

*Shigella* infections tend to occur early with HIV infection, and half may be accompanied by a bacteremia. For men having sex with men, shigellosis is predominantly a sexually transmitted disease, with the greatest risk from direct oral-anal contact and HIV infection contributing to increased host susceptibility.[732] *Campylobacter jejuni* can produce a proctocolitis, and patients often do not have fever. *Vibrio parahaemolyticus*, which can lead to colitis following ingestion of poorly cooked seafood, should be considered in the differential diagnosis. Other bacterial pathogens to be considered in cases of colitis include: enteropathogenic *E. coli*, *Yersinia*, and *Aeromonas hydrophila*. [538,726]

**MYCOBACTERIOSIS.**-- Both *Mycobacterium avium*-complex (MAC) and *Mycobacterium tuberculosis* (MTB) in the GI tract are usually found in the small intestine, particularly the duodenum, but can also be found in the colon and stomach (Table 5).[454,733] Mycobacteria can be cultured from stool in about 10% of HIV-infected patients with diarrhea, but the majority of these infections are due to MAC in developed nations of Europe and North America, while most are due to MTB in Africa.[734]

With MAC infection, there can be diffuse abdominal pain and mesenteric lymphadenitis. The mucosa on endoscopy may show multiple raised nodules, but may appear normal. There may also be small pinpoint yellow foci, fine white nodules, diffuse yellow patches, or raised yellow plaques. Erythema, edema, friability, and ulceration are uncommon. This yellow color is explained by the microscopic appearance of numerous striated blue macrophages distending the intestinal mucosal villi. Acid-fast stain shows the macrophages to be filled with numerous mycobacteria. Even the PAS stain may reveal the organisms and give an appearance that resembles Whipple disease.[718,735] A common radiographic finding is diffuse thickening of jejunal folds without ulceration.[447]

*Mycobacterium tuberculosis* in the GI tract may not be accompanied by apparent pulmonary disease in 40% of cases. Any part of the GI tract may be involved, but the ileocecal area is most often affected, and the endoscopic appearance is that of transverse ulcerations, often with strictures. Other gross appearances include polyps and nodules. Ulcerative lesions in the stomach and proximal small bowel may mimic carcinomas. Microscopically in persons without significant immunosuppression, the lesions are often well-formed granulomas with focal necrosis and few acid-fast bacilli; as the CD4 lymphocyte count decreases, the granulomas are more poorly formed and exhibit numerous neutrophils and macrophages with more numerous acid-fast bacilli, sometimes filling macrophages similar to the pattern with MAC. The presence of large confluent granulomas >400 µm with disproportionate submucosal inflammation, prominent caseation, macrophages palisading at the base of ulcers, and absence of chronic inflammatory changes suggests tuberculosis, not Crohn disease. Tuberculosis is distinguished from yersinosis that lacks caseation and acid-fast organisms.[724]

Colonic lesions are seen radiographically to consist of segmental ulceration, inflammatory strictures, or hypertrophic lesions resembling polyps.[447]

A presumptive diagnosis of mycobacteriosis for definitional criteria for a diagnosis of AIDS may be made as follows:[421]

Microscopy of a specimen from stool or normally sterile body fluids or tissue from a site other than lungs, skin, or cervical or hilar lymph nodes that shows acid-fast bacilli of a species not identified by culture.

**CYTOMEGALOVIRUS.**-- Cytomegalovirus (CMV) is capable of infecting all parts of the gastrointestinal tract, but the most common clinical manifestations include colitis and esophagitis. At least 20% of patients with AIDS have gastrointestinal involvement with CMV. Clinically, there may be diarrhea, fever, abdominal pain, hematochezia, weight loss, or anorexia.[449,724] Odynophagia would suggest esophageal involvement.[525] There is no typical grossly identifiable pattern of involvement. Gross lesions may not be present, but anything from mucosal erythema to small mucosal ulcers to plaques may occur. Endoscopic findings may include edema, subepithelial hemorrhage, ulceration, or aggregates of discrete ulcers from 5 mm to 2 cm in size.[718]

Gastrointestinal perforation is an uncommon complication of CMV infection with AIDS, but the most common cause for it is CMV infection. Patients can present with severe abdominal pain, nausea, vomiting, fever, and leukocytosis. An abdominal radiograph will demonstrate pneumoperitoneum. The most common locations for perforation are the ascending and transverse colon, distal ileum, and appendix.[525,529] CMV can cause painful anorectal ulcerations.[736]

A wide range of radiologic findings occurs with gastrointestinal CMV infection. There may be single or multiple large superficial esophageal ulcerations. Small bowel wall thickening with thickened, irregular mucosal folds can be seen. Extensive ulceration with involvement of the muscularis can lead to the appearance of a "CMV pseudotumor" ranging in size from a small nodule to a large mass that can mimic a neoplastic lesion of Kaposi sarcoma or non-Hodgkin lymphoma, though the inflammation associated with CMV typically leads to the finding of infiltrative changes in adjacent mesenteric adipose tissue by computed tomographic scan.[447]

Cytomegalovirus may be diagnosed by endoscopic biopsy in which the characteristic large cells with prominent homogeneously staining violet intranuclear inclusion bodies (Cowdry type A) are seen--most often in mucosal epithelial cells and occasionally in submucosal endothelial cells, stromal cells, and macrophages. Cells with inclusions are often widely scattered and not numerous, and atypical CMV inclusions may be more frequent. In severely immunosuppressed patients the inclusions may be numerous. The cytomegalic cells may be accompanied by small foci of chronic inflammation, necrosis, hemorrhage, or vasculitis.[718,724] Viral culture may be performed, but is generally not useful because, in the absence of histologic evidence for infection, detection of CMV is of uncertain significance.[138] Use of immunohistochemical staining can help in identification of CMV in difficult cases.[737]

**VIRAL ENTERIC (NON-CMV) INFECTIONS.**-- Viruses other than cytomegalovirus may account for a third of cases of diarrhea in HIV-infected persons, but detection and diagnosis is more difficult than for the gastrointestinal protozoa. Most involve the small intestine. Viruses detected have included adenoviruses, rotaviruses, astroviruses, picobirnaviruses, and caliciviruses. Enzyme immunoassays may detect adenoviruses, rotaviruses, and astroviruses. Polymerase chain reaction methods with reverse transcription and polyacrylamide gel electrophoresis can be used to detect picobirnaviruses, which are RNA viruses. Electron microscopy aids in detection of caliciviruses.[738]



Adenoviruses, similar to the other enteric viruses seen in HIV-infected persons with weight loss, can account for a chronic, watery, nonbloody, non-mucoid diarrhea. Grossly, adenoviral lesions may appear discrete, sometimes raised, erythematous lesions several millimeters in diameter. Adenovirus most often involves the colon, but other areas of the GI tract may also be affected. Light microscopic features include involvement only of epithelial cells, and mainly surface goblet cell involvement. The mucosa may demonstrate disorder with loss of orientation, degeneration, and vacuolization. The inclusions are only located in the nucleus and appear amphophilic or eosinophilic. The inclusions typically involve the entire nucleus and may have a crescent or sickle shape, but are rarely targetoid.[739]

Children infected with HIV are more likely to have enterovirus or astrovirus infection of the gastrointestinal tract, as detected by stool culture, than non-HIV infected children, but they were no more likely to have rotavirus infection. Rates of virus-associated diarrhea are similar in the two groups.[740]

Electron microscopic examination helps to confirm light microscopic features of adenovirus with amphophilic intranuclear inclusions in mucosal cells (usually goblet cells) surrounded by focal mucosal necrosis and chronic inflammation. Unlike CMV, adenovirus rarely involves the submucosa.[525,739] Rotavirus infections may produce a watery diarrhea and are seen more frequently with AIDS outside of the U.S.[525]

**TOXOPLASMOSIS.**-- Toxoplasmosis may rarely produce mucosal erosions in the colon, but is typically not associated with gross lesions. Microscopically, it is characterized by mixed inflammatory cell infiltrates of mucosa and submucosa in a haphazard pattern, and with little cellular necrosis. Unless *Toxoplasma gondii* cysts or tachyzoites are found, the diagnosis cannot be made with certainty.[514]

**HERPES SIMPLEX VIRUSES.**-- Herpetic lesions of the GI tract typically involve the perianal region and the esophagus. Involvement of the lower GI tract may be produced by extension of lesions from perianal skin to the anorectal junction and to rectum with clinical findings of anorectal pruritus, burning pain, tenesmus, constipation, and tender inguinal lymphadenopathy. Diarrhea may occasionally complicate proctitis. After initial HSV infection, 1 to 3 weeks later, small single or grouped vesicles surrounded by erythema appear. These vesicles may coalesce to form aphthous ulcers.[718]

Herpetic esophagitis is second in frequency to candidiasis as a cause for odynophagia, and dysphagia may also occur. The oral cavity and esophagus may also be involved with small discrete "punched-out" ulcerations. Anorectal ulcerations can be caused by herpetic infection.[736] Grossly, crops of clear vesicles can evolve to chronic ulceration and induration. A common radiologic manifestation is the appearance of multiple small discrete ulcers in a normal background mucosa.[447] Microscopic diagnosis is made by finding ground glass, mauve to pink, intranuclear inclusions in cells that are clustered or multinucleate. Surrounding squamous epithelium may show ballooning degeneration. Acyclovir, or foscarnet if resistance develops, may be helpful for therapy.[426,525,529]

**SPIROCHETOSIS.**-- Intestinal spirochetosis with the organisms *Brachyspira aalborgi* or *Brachyspira pilosicoli* can lead to chronic diarrhea in HIV-infected persons, most often in men having sex with men and who have not reached the stage of AIDS. The most common findings are abdominal pain, diarrhea, and rectal bleeding. Colonoscopy often reveals a normal

appearing mucosa because most cases do not have inflammatory changes despite the presence of spirochetosis. Biopsies may show a relative increase in intra-epithelial lymphocytes, but no acute colitis or architectural distortion. Biopsies examined microscopically with Warthin-Starry staining are more likely to detect the spirochetes. There is a characteristic fuzzy thin layer of entangled organisms attached to the apical colonic epithelial surface. Treatment with metronidazole or penicillin is effective.[724,741,742]

**BACILLARY ANGIOMATOSIS.**-- The organisms *Bartonella henselae* and *Bartonella quintana* may produce GI tract lesions resembling Kaposi sarcoma. They appear endoscopically as nodular, friable vascular lesions. In the esophagus polyposis may appear. Microscopically the lesions resemble granulation tissue with scattered nuclear debris and aggregates of extracellular amphophilic granular bacterial deposits. With Warthin-Starry staining, the organisms appear as coccobacilli.[724]

**PNEUMOCYSTOSIS.**-- An inflammatory, obstructing pseudotumor of the intestine may be a complication of disseminated *Pneumocystis jiroveci* infection. There may be no evidence for pre-existing pulmonary infection. Grossly, the lesions may appear as a cluster of multiple masses. Microscopically, the presence of multinucleated cells and foamy exudate without significant inflammatory infiltrates suggests pneumocystosis. With Gomori methenamine silver stain the cysts have the characteristic rounded, folded, partly crushed, non-budding appearance.[743]

**MALIGNANT LYMPHOMAS AND LYMPHOID LESIONS.**-- The GI tract is one of the most common sites of involvement by non-Hodgkin lymphomas (NHL) in patients with AIDS. These lymphomas occur most frequently in the stomach, small intestine, and colon (Table 5). Unlike Kaposi sarcoma, gastrointestinal lymphomas may be symptomatic from complications of obstruction, perforation, or bleeding.[715] The high grade NHL's seen in the anorectal region, particularly when the risk factor for HIV infection is sex with other males, are typically associated with Epstein-Barr virus (EBV) infection, which promotes clonal proliferation of lymphoid cells.[744]

They usually appear grossly as irregular areas of nodularity of the mucosa that on sectioning have a firm white appearance extending into the submucosa. Superficial ulceration can occur. Large masses that can obstruct the lumen of small intestine or colon are not common. One pattern of abdominal involvement with NHL in AIDS is marked omental and/or mesenteric infiltration, often with a malignant effusion. Rarely, NHL may appear only as malignant cells in an effusion, without a definable mass lesion (a primary body cavity-based lymphoma).

Radiographically, gastric NHL features include circumferential or focal thickening of the gastric wall and mural masses with or without ulceration. In the small intestine, features include diffuse or focal bowel wall thickening and excavated masses.[447]

Microscopically, the bulk of most lymphomatous infiltrates are submucosal, but small infiltrates of neoplastic lymphocytes may extend into the lamina propria or mucosa, making endoscopic biopsy diagnosis possible. The appearance of a monomorphous population of large cells, aided by identification of monoclonality by immunohistochemical staining, helps to distinguish malignant lymphomas from chronic inflammatory infiltrates.[601,607] The most common types are diffuse large cell and immunoblastic, with a smaller number of small non-cleaved lymphomas.

The incidence of GI tract lymphomas has decreased since widespread use of antiretroviral therapy, but not as much as Kaposi sarcoma. Most AIDS patients with gastrointestinal lymphomas will respond to chemotherapy, but the rate of complications such as bleeding, obstruction, and intestinal perforation is significantly higher than in immunocompetent patients and may occur in up to half of cases.[745]

Other common lymphoid lesions of the GI tract include chronic non-specific colitis with or without an identifiable infectious agent. These lesions are characterized by diffuse or focal mucosal and submucosal collections of small lymphocytes, with minimal or no accompanying necrosis. More pronounced lymphoid collections characterized as nodular lymphoid hyperplasia may be related to persistent generalized lymphadenopathy (PGL) in persons at this stage of HIV infection. Mucosa-associated lymphoid tissue (MALT) lesions are lymphoid proliferations that may occur at extranodal sites such as the gastrointestinal tract.[614,615]

**KAPOSI SARCOMA.**-- The gastrointestinal tract is the second most common site for KS following skin, and the commonest visceral site, for KS in AIDS patients. In most cases, the GI tract is involved in addition to the skin and/or lymph nodes. Lesions may occur anywhere from the oral cavity to the anus. Grossly, the lesions are raised dark red nodules averaging 0.5 to 1.5 cm in diameter. They are often widely scattered, but they may also involve large areas of the mucosal surface. Though the lesions are vascular, large hemorrhages are uncommon. The lesions are usually asymptomatic, but occasional problems may include diarrhea, obstruction, or protein losing enteropathy. Perforation is an uncommon complication. Radiographically, KS most often produces multiple submucosal masses, with or without central ulceration that gives a target-like lesion, though plaque-like lesions or small nodules may also be seen. The microscopic appearance is similar to that seen elsewhere, but diagnosis can sometimes be difficult due to: a submucosal distribution pattern, the microscopic similarity to granulation tissue, or the small amount of tissue available from endoscopic biopsies.[447,715]

**AIDS-ASSOCIATED MYOID TUMORS (AIDS-MTs).**-- The GI tract is one of the more common sites for the uncommon AIDS-MTs, smooth muscle tumors that are associated with Epstein-Barr virus (EBV) infection. They are most likely to occur in children, but may be seen in adolescents and adults. They produce a nodular mass lesion with ulceration. Microscopically they can have a benign appearance resembling a leiomyoma, or may have atypia, or may demonstrate primitive smooth muscle round cells and T lymphocyte infiltrates.[746]

**ORAL CAVITY CHANGES.**-- A fourth to half of all persons infected with HIV will have one or more oral lesions during the course of their infection, and in 10% an oral lesion will be the first manifestation of their illness. The most common lesions are: oral candidiasis, hairy leukoplakia, periodontitis, gingivitis, aphthous ulcers, and Kaposi sarcoma. Oral candidiasis is discussed above. Symptoms may include xerostomia and burning mouth syndrome. Oral papules and ulcers may appear on buccal mucosa with *Histoplasma capsulatum* and *Penicillium marneffeii* infections.[715,747]

Necrotizing gingivitis is seen in HIV positive patients and is characterized by marginal gingival necrosis, bleeding and pain. When this process extends into the periodontal attachment apparatus, it is known as necrotizing periodontitis. These two conditions are collectively known as necrotizing periodontal diseases, and they are similar with regard to the spectrum of

periodontopathic bacteria, the clinical manifestations, the natural course and the response to treatment compared to persons not infected with HIV. Cases of acute necrotizing gingivitis usually appear prior to the onset of clinical AIDS. Chronic gingivitis may present with band-like or punctate erythema, though biopsy reveals only increased vascularity without inflammation, and most are associated with *Candida* infection. Gingivostomatitis with Herpes simplex virus infection is typically severe with multiple vesicles that can rupture, coalesce, and leave painful irregular ulcers. The HIV-associated periodontitis may or may not have necrosis, but produces severe pain in the jaw.[511,748,749]

Aphthous oral ulcers, though seen in non-immunocompromised persons, are more likely to be severe and prolonged in patients with HIV infection. Aphthous oral ulcers can appear as a complication of saquinavir therapy.[283,286] Recurrent aphthous stomatitis is more likely to occur with declining immunologic status and be associated with nutritional deficiencies.[750] Aphthous ulcers most commonly appear as painful lesions in the floor of the mouth, tonsillar fossa, and epiglottis, particularly in patients with low CD4 lymphocyte counts, that lead to weight loss from decreased oral intake. They may also occur in esophagus and colon. Histologically, these ulcers demonstrate submucosal lymphocytic infiltration with overlying acute inflammation, including eosinophils. Special stains are needed to exclude possible infectious agents.[715] Oral analgesics for minor lesions and intralesional injection of corticosteroids for major lesions may be helpful for pain relief, healing of the ulcers, and weight gain.[751] The drug thalidomide has shown effectiveness in the treatment of oral aphthous ulcers.[752] Drug therapy with foscarnet, interferon, and ddC may also be complicated by oral ulceration.[753]

Oral Kaposi sarcoma (KS) may be the initial site of KS involvement in 20% of HIV-infected patients, and eventually may be involved in 70% of cases. An increased amount of human herpesvirus-8 in saliva may suggest why oral cavity is a preferred site for KS. The lesions can begin as small, well-delineated macular lesions that histologically have inconspicuous patches of spindle cells containing ill-defined vascular spaces and scattered lymphocytes. These may progress to larger, infiltrative, nodular lesions that have spindle cells lining vascular slits and bizarre-shaped vessels. Early lesions may resemble hemangiomas while later lesions can mimic bacillary angiomatosis and pyogenic granuloma. Early lesions may be asymptomatic, but larger lesions may ulcerate, become secondarily infected, cause dysphagia, and interfere with speech or mastication. Gingival lesions may cause periodontal disease. Rapid growth of KS lesions may cause lymphedema. Most lesions regress with antiretroviral therapy.[754]

Oral Kaposi sarcoma (KS) most frequently involves the hard palate, soft palate, gingiva, and dorsal tongue. Lesions may be single or multifocal. Larger exophytic lesions can be complicated by ulceration, hemorrhage, and infection. Larger lesions may also erode alveolar bone or cause tooth displacement. Active antiretroviral therapy may help to control the lesions. Larger lesions may respond to intralesional injection of vinblastine. The lesions are also radiosensitive.[755]

A variant of a diffuse large cell non-Hodgkin lymphoma known as plasmablastic lymphoma has been reported in the oral cavity.[619]

Oral squamous cell carcinomas in HIV-infected persons tend to occur at a younger age than in HIV-negative persons. They tend to have a higher stage of III or IV. They tend to be poorly differentiated.[756]

Oral hairy leukoplakia, (OHL) also known as oral condyloma planum, produces a white lesion usually found on the lateral border of the tongue that is slightly raised, poorly demarcated and variable in size. The mucosal surface is grossly corrugated or "hairy." Unlike the exudate of oral thrush, the lesion of OHL cannot be scraped off. Epstein-Barr virus (EBV) has been identified in epithelial cells with OHL. Microscopically, the squamous epithelium shows marked acanthosis (which produces the grossly "hairy" appearance) with parakeratosis, koilocytosis, and herpetic type intranuclear inclusions. Candidiasis is often present overlying the lesion. However, fungal infections alone, or mechanical irritation, may produce gross and microscopic appearances similar to OHL. OHL is not premalignant. The presence of OHL in an HIV-infected person may presage development of AIDS.[757,758] Liquid based cytology can reliably diagnose OHL.[759] The appearance of high grade T-cell non-Hodgkin lymphomas has been reported in the oral cavity of patients with EBV infection and OHL.[760] Though OHL is clinically apparent in only 2% of pediatric HIV-infected patients, it can be detected cytologically in up to 17% of these patients.[761]

Oral condylomata can appear in several forms and may occur on any oral mucosal surface and are associated with human papillomavirus infection (HPV). Oral HPV infection occurs in approximately 1% of persons with HIV infection. Lesions that are flat, sessile, and firm are associated with HPV genotypes 1, 2, and 7 similar to cutaneous warts. The spiked, soft, or cauliflower-like lesions are associated with HPV genotypes 6 and 11 similar to genital warts. Lesions with epithelial hyperplasia in small, flat papules on the lower lip are associated with HPV genotypes 13 and 32. Microscopically, both acanthosis and koilocytosis are present. Treatment of larger lesions is difficult, with surgical excision and laser ablation being applied with some success. Treatment is difficult because of the extent of disease and the likelihood for recurrences.[715,762]

Herpetic gingivostomatitis can be accompanied by systemic flu-like symptoms along with painful gingival inflammation and multiple oral ulcers. Most commonly, this is manifested as herpes labialis which is characterized by a prodrome of itching and burning followed by the development of a crop of vesicles that crusts and then heals spontaneously in a week to 10 days. Herpes labialis typically occurs along the vermilion border of the lips. With HIV infection, herpes viral infections can be more extensive and severe and difficult to treat.[763]

Human papillomavirus (HPV) may cause the appearance of exophytic, papillary oral lesions. With HIV infection, these lesions are often multiple and difficult to treat because of a high rate of recurrence. Excision and cauterization or topical podophyllin have been used as therapies.[763]

Bacillary angiomatosis, which produces proliferative vascular lesions, can rarely involve the oral cavity. The lesions can resemble oral Kaposi sarcoma. Grossly, they are most often bluish to purplish macules, but papules and nodules may also be seen, and there can be ulceration and exudation. Histologically, lesions of bacillary angiomatosis may have similarities to pyogenic granuloma and epithelioid hemangioma. A characteristic feature is vascular proliferation with epithelioid-like endothelial cells that project into vessel lumens to give a tombstone-like appearance.[764]

Noma, or cancrum oris, can be seen in association with HIV infection. Noma is an opportunistic infection by anaerobic bacteria, staphylococci, streptococci, coliforms, and *Borrelia* organisms. It often begins as a necrotizing gingivitis and progresses rapidly to orofacial gangrene that requires antibiotic therapy and facial reconstruction. Though it has a worldwide distribution, it is most common in sub-Saharan Africa, with a peak age incidence of 1-4 years.

Noma is most likely to occur in persons who are immunocompromised and who live in areas with poverty, malnutrition, and poor environmental sanitation.[765]

Patients receiving antiretroviral therapy (ART) may develop a variety of exfoliative cheilitis characterized by exfoliation, crater formation, fissuring, erosions and/or the formation of papules, vesicles and blisters associated with erythema and edema. Microscopically, the lesions consist of ulcerations with adjacent hyperkeratosis and suprabasal vacuolization accompanied by a dense lymphocyte infiltrate.[766]

Lesions involving the tongue, which is easily accessible for examination, are common in advanced HIV infection. Hairy leukoplakia and candidiasis are present in over a third of patients, and can occur concomitantly. Non-specific glossitis can appear in a third of patients. Disseminated infections, including mycobacteriosis, histoplasmosis, cryptococcosis, and cytomegalovirus can involve the tongue.[767]

Tooth extraction is the dental treatment most commonly carried out in HIV infected patients. The most frequent post extraction complications are delay in wound healing, alveolitis, and wound infection. These complications are uncommon and not too severe.[768]

**ANORECTAL SQUAMOUS INTRAEPITHELIAL LESIONS (ASIL).**— This condition is also known as anal intraepithelial neoplasia (AIN). Persons with HIV infection may develop ASIL that can progress to high-grade squamous intraepithelial lesions (HSIL) that can progress to invasive carcinomas. The relative risk for anal intraepithelial lesions is 60 in men and 7.8 in women, compared with persons not infected with HIV.[769] Anorectal squamous cell dysplasia, carcinoma, and condyloma acuminatum all have a higher incidence in young men having sex with men than in the general population, and this incidence is even greater (36%) in those who also have HIV infection. There is a strong association between the appearance of these lesions and a history of receptive anal intercourse, particularly with multiple sexual partners, but human papillomavirus (HPV) can be acquired without anal intercourse. The concomitant presence of anal HPV is a risk for ASIL, and the risk for development of ASIL increases when the CD4 lymphocyte count is lower, with smoking, and with increasing numbers of sexual partners, though ASIL can occur even with CD4 counts which are less than 500/ $\mu$ L.[762,770,771]

High-grade squamous intraepithelial lesion (HSIL) may occur in HIV-infected persons of heterosexual orientation. In a study of HIV-positive persons undergoing anal cytologic screening, 35% had abnormal findings, and of these, 71% were men having sex with men (MSM), 23% women, and 6% heterosexual men. HSIL/cancer was found in 32% of MSM, 26% of women, and 23% of heterosexual men. The risk was lower in persons whose CD4 lymphocyte count was greater than 500/ $\mu$ L.[772]

The prevalence of anal HPV and anal dysplasia in men having sex with men (MSM) greatly exceeds that in the cervix. In contrast with the pattern seen in women, the prevalence of anal HPV and anal dysplasia in MSM seems not to decrease with increasing age and probably explained by differences in sexual behavior, with men having more sexual partners than heterosexual women. However, progression from anal dysplasia to carcinoma occurs less frequently in men with HIV than in cervical lesions in women.[773]

There is a high prevalence of high-risk HPV types in the anus (78%), penis (36%), and mouth (30%) in HIV-infected men, including both men who have sex with men as well as heterosexual men.[774] The most common subtypes are HPV 16 (38%), 18 (19%), 45 (22%), and 52 (19%). The HPV subtypes 16, 18, 31, 52, 59, and 68 are most likely to be associated with high-grade ASIL.[775] The use of antiretroviral therapy (ART) increases survival in HIV

infected persons and appears to increase the risk for anal cancer, since HSIL does not appear to regress with ART.[772]

Progression of ASIL to HSIL can occur in 17% of HIV-infected males, and this may occur in less than a year. Risks for progression include coinfection with multiple HPV types, specifically HPV 16, and a CD4 count  $<200/\mu\text{L}$ . Most persons with ASIL do not have regression of the lesions while receiving antiretroviral therapy (ART). Thus, longer survival of persons receiving ART may actually allow progression of ASIL to HSIL and invasive lesions.[771] In such a setting, screening of HIV-infected persons, with risk factor of anal receptive intercourse, by anal Pap smears can be useful.[776] Risks for the presence of HSIL include high-risk HPV subtypes and severity of cytologic findings. Anoscopy may assist in identifying lesions.[777]

HSIL can, on occasion, regress. In one study, 23.5% of men per year with high-grade anal intraepithelial neoplasia had spontaneous regression to a lower grade lesion, while 1.2% per year progressed to cancer.[778]

Carcinomas may occur in either the anal canal or the anal margin. Anal carcinomas are usually squamous cell carcinomas, but some are adenocarcinomas. Those that occur at the anal margin are less likely to be associated with HPV infection, but surgical excision alone is typically curative. Surgery combined with chemotherapy and radiotherapy is employed in treatment of carcinomas of the anal canal, but there is a high recurrence rate along with high chemotherapy toxicity, and high mortality.[771]

Human papillomavirus (HPV) related anorectal condylomata are found in about 1 in 5 HIV-infected men. Other grossly apparent anal lesions can include hemorrhoids and fissures. Receptive anal intercourse is the major risk factor for these lesions.[779]

Women with HIV infection are more likely to have anal HPV than non-HIV-infected women, and they are more likely to have cytologic abnormalities of the anorectal mucosa. In this setting, the risk for ASIL, HSIL, and invasive lesions is increased. In women, anal intercourse is associated with risk for anorectal neoplasia.[780]

The transformation zone separating the rectal columnar mucosa from the anal keratinizing squamous epithelium above the dentate line is the region where most intraepithelial neoplasms arise. Histologic changes can include atypia, condyloma, and intraepithelial neoplasia. More than two thirds of the squamous epithelial thickness is involved with HSIL, and microinvasion may be present.[769]

Clinical features of anal intraepithelial neoplasia may include pain, pruritus, bleeding, discharge, or tenesmus. The grossly visible anoscopic appearance may be normal. Anal cytology may be useful for screening, because the positive predictive value for any anal cytologic abnormality to predict any degree of anal dysplasia is 95%.[781] Lesions are treated with excision.[769]

An epidermodysplasia verruciformis-like (AEV) syndrome occurs in HIV-infected persons co-infected with HPV. AEV is characterized by hypopigmented macules or erythematous flat-topped papules on the face, trunk, and arms. AEV most commonly occurs with HPV types 5, 8, 17, and 20.[782]

**AIDS ENTEROPATHY.**-- Despite extensive clinical workup and laboratory testing, up to 20% of AIDS patients with chronic diarrhea, weight loss, and/or malabsorption cannot be found to have an infection or etiologic factor that can explain the symptomatology, even after biopsy. Endoscopic biopsies in such cases may show prominent villus atrophy, crypt cell hyperplasia, crypt architectural distortion, decrease in crypt/villus ratio, epithelial apoptosis,

nonspecific inflammation, and increased IgM containing but decreased IgA lymphocytes within the lamina propria. However, AIDS patients without diarrhea may also have endoscopic biopsies that show villous atrophy. The term "AIDS enteropathy" has been used to describe this condition.[746,783]

The malabsorption is out of proportion to the degree of pathologic changes present. Octreotide and nutritional support, and antiretroviral therapy leads to statistically significant improvements in gastrointestinal symptoms. Several theories have been postulated to explain this enteropathy. HIV may have an effect upon mucosal ion flux that is cytokine mediated to alter transepithelial resistance by changes in transcellular or intercellular (paracellular) permeability. A decreased staining of acetylated tubulin has been observed in small bowel and colonic epithelial cells from HIV-infected subjects, implying microtubular depolymerization and cytoskeletal alterations. Incubation of the intestinal cell line, HT-29, with gp120, applied to the basolateral side, led to an increase in cytosolic calcium, which was associated with both tubulin depolymerization and decreased epithelial resistance, suggesting that HIV enteropathy is a pathophysiological consequence of gp120 exposure, and is independent of epithelial cell HIV infection.[783]

Antiretroviral therapy has been shown to ameliorate AIDS enteropathy. ART reduces crypt stem cell proliferation that drives the hyperplasia. The reduction in circulating retroviral Tat protein may play a role. Once this proliferative process is reduced, then the crypt architecture is restored.[784]

**HIV WASTING SYNDROME.**-- Progressive, involuntary weight loss is a common accompaniment to HIV infection. Poor diet from lack of sufficient care or economic resources certainly plays a role, as well as malabsorption from concomitant AIDS-associated infections or neoplasms, particularly those affecting the GI tract. However, there are persons with HIV infection and AIDS who do not have a concurrent illness or condition other than HIV infection that explains a weight loss of >10% of baseline body weight plus either chronic diarrhea or chronic weakness and fever, which are the CDC criteria for HIV wasting syndrome that satisfy definitional criteria for a diagnosis of AIDS.[421] Additional criteria that adjust for changes in baseline weight with advancing HIV illness include unintentional loss of >10% body weight, a body mass index decreasing to <20, or unintentional loss of 15% body weight in 6 months that persists for at least 1 year. About a third of HIV-infected persons may be affected by this wasting syndrome.[785]

Several causative factors probably contribute to the development of wasting syndrome. These can include hypermetabolic or altered metabolic states, production of cytokines such as tumor necrosis factor and interleukin-1 because of macrophage infection by HIV, and endocrine dysfunction. Also, progression of HIV infection may play a role in the appearance of wasting syndrome, since the degree of weight loss correlates with increasing HIV-1 RNA levels and with decreasing CD4 lymphocyte counts.[785]

Decreased oral intake of food is also a very important etiology for weight loss in HIV infection and highlights the need for good nutrition. Good nutrition may be needed to counteract the effects of malabsorption that can contribute to wasting syndrome. Sometimes a specific intestinal pathogen can be identified, but not in all cases. Up to half of HIV-infected patients may have abnormal d-xylose absorption tests.[785]

Varieties of therapies have been utilized to counteract wasting syndrome. These include the use of megestrol acetate as an appetite stimulant, thalidomide as a cytokine inhibitor, and



recombinant human growth hormone or testosterone as anabolic agents. Controlling diarrhea, nausea, and fever as well as providing nutritional support can diminish the impact of wasting syndrome.[785]

In the U.S., HIV wasting syndrome alone as an indicator disease once accounted for up to 7% of all newly reported AIDS cases, and was reported along with additional indicator diseases in another 10% of cases. In a large study in the U.S., the incidence of wasting syndrome declined from 1992 through 1999, with the most marked rate of decline occurring after 1995. The incidence of AIDS and non-AIDS-defining illnesses was generally high at or after a diagnosis of wasting syndrome. Factors significantly associated with improved survival included a CD4+ count of  $\geq 200$  cells/ $\mu$ L during the interval of the wasting syndrome diagnosis and antiretroviral therapy with two or more drugs at or after the diagnosis of wasting syndrome.[786]

**HIV LIPODYSTROPHY.**-- Persons with HIV infection may develop lipodystrophy (lipoatrophy) with lipid abnormalities, insulin resistance, and lactic acidosis. Half of HIV-infected persons receiving antiretroviral therapy (ART) may have one or more features of lipodystrophy. The term protease inhibitor-associated lipodystrophy (PIAL) has been employed with a protease inhibitor is part of ART. Despite the abdominal distension, there may be a normal to decreased body mass index. [289] Lipodystrophy, however, appears to be associated with multiple ART regimens and not specific drugs.[787]

The mechanisms for PIAL are not known, but may be related to a number of factors. The nucleoside analogues most associated with lipoatrophy are zalcitabine, didanosine and stavudine, due to toxicity towards mitochondria. The protease inhibitors (PIs) may alter pro-inflammatory cytokines such as TNF-alpha and IL-6 and lead to increased adipocyte apoptosis, reduced lipid accumulation in adipocytes, and reduced insulin-stimulated GLUT-4 mediated glucose uptake. Of the PIs lopinavir, ritonavir, saquinavir and nelfinavir are the worst. Inhibition of the sterol regulatory enhancer-binding protein 1 (SREBP-1) that mediates activation of adipocyte retinoid X receptor and peroxisome proliferator-activated receptor-gamma (PPAR-gamma) can occur.[788] Protease inhibitors may impair adipocyte differentiation via interactions with adipocyte proteasomal gene expression systems, down-regulation of cellular retinoic acid binding protein, dysregulation of cortisol stimulation, activation of adipocyte renin-angiotensin, and adipokine effects.[789]

There is evidence that an adipocytokine, adiponectin, a protein product of the *apM1* gene, which is expressed exclusively in adipocytes, plays a role in development of lipodystrophy with HIV infection. *In vitro* and animal studies and cross-sectional studies in humans have shown that adiponectin is inversely correlated with features of this metabolic syndrome including obesity, insulin resistance, type 2 diabetes, and coronary heart disease, as well as congenital and acquired lipodystrophies in non-HIV infected subjects. Thiazolidinediones that act as agonists for the nuclear receptor transcription factor PPAR-gamma, a subtype of the nuclear receptor superfamily found in adipose tissue, influence the expression of genes involved in adipocyte differentiation, lipid metabolism and insulin action. Pioglitazone has been shown to improve insulin resistance in persons with HIV infection.[790]

Typical physical findings include central fat accumulation in an abdominal or dorsocervical distribution ("buffalo hump"), peripheral lipoatrophy with fat atrophy of limbs, face, and buttocks, and lipomata. Another specific finding seen in a subset of patients with lipodystrophy is a "pubic lipoma" or pronounced suprapubic fat pad. Pubic lipoma is more likely to occur in association with coexisting dorsocervical fat pads. This accumulation of

suprapubic fat is more common among women, obese individuals, and those with a shorter duration of HIV infection.[791]

Measurement of body composition by dual-energy X-ray absorptiometry has been utilized to define lipodystrophy. The fat mass ratio (FMR) is computed as the ratio between the percentage of truncal fat mass and the percentage of lower limb fat mass. In one study, the sensitivity was 58% for men and 51% for women, with specificity of 84% for men and 95% for women.[792]

Metabolic consequences of lipodystrophy include: increased insulin resistance with increased plasma insulin and decreased oral glucose tolerance, decreased cortisol, increased total serum cholesterol > 240 mg/dL, HDL cholesterol <35 mg/dL, and increased serum triglyceride >200 mg/dL. Diabetes mellitus may be seen in 7% of patients with lipodystrophy.[788] In fact, the serum triglyceride may be over 1000 mg/dL and even approach 9000 mg/dL. Dyslipidemia is most marked with ritonavir. Up to two thirds of persons taking protease inhibitors may develop features of lipodystrophy. The rate of development of moderate to severe lipodystrophy is 20% for those persons on antiretroviral therapy, 8% among those taking less potent antiretroviral therapy, and 1-2% for antiretroviral-naïve persons. The mean time to appearance of findings is 10 months after starting protease inhibitor therapy. The prevalence of lipodystrophy rises for the first two years after initiating antiretroviral therapy but appears to stabilize thereafter.[793,794]

Treatment for lipodystrophy includes lifestyle modifications with cessation of smoking, increased exercise, and dietary modifications. Insulin resistance may be treated with metformin. Surgical management with liposuction has been employed, and appears most efficacious in decreasing the size of the cervicodorsal fat pad. In addition, gynecomastia may be treated with subcutaneous mastectomy. Facial wasting may be addressed with facial fillers. Cystic parotid enlargement can be treated with parotidectomy.[795] Alteration of antiretroviral therapy may be done. A hydroxymethylglutaryl-coenzyme A (HMG CoA) reductase inhibitor (statin) can be used for hypercholesterolemia and a fibrate for hypertriglyceridemia.[788] However, there are significant drug interaction among statins and antiretroviral drugs.[789] The drug tesamorelin, an analogue form of human growth hormone-releasing hormone (GHRH) has shown effectiveness in treatment of lipodystrophy. This analogue resists deactivation in vivo to increase levels of growth hormone and insulin-like growth factor 1 (IGF1), reducing abdominal fat and decreasing serum triglyceride and LDL cholesterol.[796]

**MISCELLANEOUS FINDINGS.**-- Intussusception has been reported to occur in association with AIDS. This can occur with cytomegalovirus infection or bowel wall involvement by Kaposi sarcoma or non-Hodgkin lymphoma. The diagnosis is suggested by intermittent cramping abdominal pain in a young to middle-aged adult. Computed tomographic (CT) scans aid in confirmation of this diagnosis. The many opportunistic infections and neoplasms affecting the gastrointestinal tract in patients with AIDS can predispose to intussusception.[447,797] Intussusception in pediatric AIDS can be life-threatening and associated with Kaposi sarcoma in the absence of cutaneous lesions.[798]

The toxic side effects of antiretroviral therapy with either antiretroviral drugs may lead to nausea, vomiting, and diarrhea. Such adverse reactions are most likely to occur within the first 3 months of starting therapy, are typically mild, and usually transient. The combination most likely to require a switch in therapy is lopinavir and ritonavir. The single drugs most likely to cause GI disturbances are nevirapine and saquinavir.[282]

Pill esophagitis has been reported, most often associated with ingestion of the antiretroviral drugs zidovudine and zalcitabine, and the antibiotic doxycycline. It may be exacerbated by malnutrition. Microscopically, there is ulceration with numerous eosinophils in the ulcer base.[746]

Idiopathic esophageal ulceration, also termed HIV-associated esophageal ulceration, is most likely to occur in persons with a CD4 lymphocyte count  $<100/\mu\text{L}$ , but may also occur soon after infection with acute antiretroviral syndrome. On endoscopy there are usually one or more well-circumscribed, variably penetrating, mid to distal esophageal ulcers.[746]

## CENTRAL NERVOUS SYSTEM PATHOLOGY IN AIDS

Clinical features of central nervous system (CNS) lesions with AIDS can be similar and often require radiologic or laboratory differentiation. Neurologic examination helps establish the presence of CNS lesions and to document their progression or response to therapy. Besides organic disease, there are serious functional disorders resulting from the multitude of emotional and psychosocial problems created by the devastating effect of HIV infection on the lives of its victims. CNS lesions are typically identified in over 80% of autopsied AIDS patients. Of AIDS-diagnostic diseases, cryptococcosis, cytomegalovirus, malignant lymphomas, and toxoplasmosis are the most frequent (Table 5). About one-fifth of AIDS patients die from CNS diseases.[448] The use of antiretroviral therapy (ART) alters the CNS complications with prolonged survival so that progressive multifocal leukoencephalopathy (PML), toxoplasmosis, and cytomegalovirus are less frequent complications, while stroke and CNS lymphoma increase.[799]

Diagnostic imaging including computerized tomography (CT) and magnetic resonance imaging (MRI) are insensitive for early lesions and cannot detect small microglial nodules, perivascular lesions, or granulomas. A clinical diagnosis of encephalopathy is often made before a radiologic diagnosis, in which the only early change seen with MR imaging is atrophy.[800] Stereotaxic biopsy following radiologic imaging can be useful for diagnosis, with a diagnostic yield around 90%.[801] Cytologic examination of stereotaxic specimens can increase diagnostic sensitivity, particularly for infectious conditions.[802]

**HIV ENTRY INTO THE CNS.--** HIV can be carried to the CNS early following initial infection. Entry probably occurs through breaches in the blood-brain barrier. The HIV Tat protein can induce oxidative stress, compromise cellular viability, induce apoptosis, and disrupt tight junctions in endothelial cells to produce HIV entry as well as ongoing cellular damage. The HIV envelope protein gp160, cleaved into gp120 and gp41, has been shown to be neurotoxic. Both the GSK3 $\beta$  and CDK5 signaling cascades mediate some of the neurotoxic effects of HIV proteins. HIV resides within microglial cells, astrocytes, or perivascular macrophages, and these infected cells can constitute the reservoir of infection from which the effects of ongoing HIV replication lead to disease in the brain. The ongoing cellular damage appears clinically as an encephalopathy or encephalitis.[91,803,804]

Monocytes transform to macrophages in tissues such as brain and mediate many effects of HIV infection via their activation. Early antiretroviral therapy has been shown to reduce monocyte/macrophage activation and reduce neurologic decline. Chronic immune activation, metabolic syndrome, elaboration of acute phase proteins, cardiovascular disease, and diseases involving the CNS all potentiate the activation of monocytes/macrophages.[805]

**PRIMARY HIV INFECTION AND THE CNS.--** Though viral RNA may be detected in as few as 8 days following acute HIV infection, few persons will have neurologic findings other than headache associated with initial HIV infection. Those findings may include aseptic meningitis, Bell's palsy, and inflammatory neuropathy. The aseptic meningitis is similar to that caused by other viruses and presents with fever, headache, stiff neck, and photophobia. Examination of cerebrospinal fluid may reveal a lymphocytic pleocytosis, normal to slightly elevated protein, and normal glucose. Most persons recover, but a few have recurrent meningitis.[806,807]

**HIV-ASSOCIATED NEUROCOGNITIVE DISORDER.**-- A clinical syndrome described loosely as "HIV encephalopathy" is often associated with a progressive debilitating dementia, called HIV-associated dementia, or previously "AIDS dementia complex" (ADC), and encompassed in HIV-associated neurocognitive disorder (HAND). This often begins with impaired memory and concentration along with psychomotor slowing. It is progressive and continues to include motor deficits such as ataxia and tremor. Behavioral disturbances range from apathy or withdrawal to frank psychosis. One sixth of persons with AIDS are affected, with an annual incidence of 7%. It is rare to have both cognitive and functional impairment without associated neurologic and/or behavioral deficits. Functional impairment in isolation is also rare. The criteria for HIV-1-associated neurocognitive disorder (HAND) are as follows:[808]

Category	Neurocognitive Status	Functional Status
Asymptomatic neurocognitive impairment	1 SD below mean in 2 cognitive domains	No impairment in activities of daily living
Mild neurocognitive impairment	1 SD below mean in 2 cognitive domains	Impairment in activities of daily living
HIV-associated dementia	2 SD below mean in 2 cognitive domains	Notable impairment in activities of daily living

SD = standard deviation

Cognitive domains include: attention-information processing; language; abstraction-executive; complex perceptual motor skills; memory (including learning and recall); simple motor skills or sensory perceptual skills.

Clinical neurologic features of HIV-associated dementia (HAD) early symptoms of apathy, depression, poor concentration, poor short-term memory, agitation, mania, and clumsiness. Early signs include tremor, hyperreflexia, impaired fine finger movements, and impaired saccadic eye movements. Late features include global dementia, frontal release signs, cerebellar signs, myelopathy, neuropathy, seizures, myoclonus, and parkinsonism.[809]

Patients who are on antiretroviral therapy are unlikely to develop HAD. Prior to the introduction of antiretroviral therapy, the prevalence of dementia was about 16%, with an annual incidence of 7%. Risk factors for HAD include: low CD4 count, increasing age, anemia, low BMI, substance abuse, the E4 allele of apoprotein E, and coinfection with other viruses.[809]

Even when antiretroviral therapy controls HIV infection, half of HIV-infected persons may still exhibit neurocognitive impairment (NCI). Moreover, even in persons reporting no cognitive complaint, over half had NCI on testing. Over half of these NCI cases are mild, and a third are detected only with neurologic testing. Most of those impaired persons have conditions

that are unrelated to HIV, including risk factors of low level of education, prior brain damage, anxiety, and depression.[810]

A pathologic study of HIV-infected persons who had been exposed to antiretroviral therapy (ART) showed that both mild and moderate to severe cerebral small vessel disease (CSVD) were associated with protease inhibitor-based ART regimens. The features of CSVD include concentric intramural hyalinization of small arteries and arterioles. Such vascular changes can be seen in association with diabetes mellitus, hypertension, and aging. However, after excluding these conditions, a mild degree of HAND is associated with CSVD. Thus, use of ART with protease inhibitors may contribute to neurocognitive impairment in HIV-infected adults. The mechanism may be drug toxicity to vascular endothelium and smooth muscle cells.[811]

**HIV-ASSOCIATED DEMENTIA (HAD).**-- Of adults with HIV infection, HAD (also termed AIDS dementia complex or ADC) is infrequently the first manifestation of AIDS. During the late stages of AIDS, when CD4 lymphocyte counts drop and HIV-1 RNA levels increase, more patients may be affected with frank dementia. In patients receiving antiretroviral therapy (ART) the incidence declines. The disease often progresses insidiously, particularly in patients receiving antiretroviral therapy, but the onset can be more rapid over weeks in patients who have never received antiretroviral therapy. Persons with CD4 counts below 100/ $\mu$ L progress more rapidly. The mean survival in untreated persons is about 6 months. Other significant predictors of progression to dementia are the presence of an anemia, weight loss, and constitutional symptoms.[808,812,813]

The diagnosis is one of exclusion. Opportunistic infections involving the CNS in AIDS tend to have a more rapid onset and course. Clinical features of HAD suggest early and predominantly subcortical brain involvement. These features include increasing forgetfulness, difficulty with concentration, loss of libido, apathy, inertia, and waning interest in work and hobbies. HAD is characterized by social withdrawal and a blunting of emotional responsiveness. Short-term memory is impaired. Motor problems are often mild and include poor handwriting, poor balance, gait difficulties, and a tendency to drop things easily. As the dementia progresses, learning and memory deteriorate. There is a reduced output of spontaneous speech. Eventually, late in the course of the disease there is global impairment with severe psychomotor retardation and mutism.[812]

The neurologic examination is often normal early in the course of HAD. Focal neurologic deficits are more likely to be found with CNS opportunistic infections. Subtle findings can include impairments of rapid eye and limb movements and diffuse hyperreflexia. Progression of the disease results in an increased muscle tone, particularly of the lower extremities. This is usually associated with tremor, clonus, frontal release signs, and hyperactive reflexes. In some cases, myelopathy may be more severe than cognitive impairment. There can be spastic paraparesis with variable sensory ataxia and bladder involvement. Retinal cotton-wool spots may be found on funduscopy in 60% of cases. Generalized seizures may occur.[812]

Encephalopathy results from direct infection by HIV of microglial cells, monocytes, and macrophages, which then produce indirect immunopathologic effects upon the CNS via release of neurotoxins or elaboration of cytokines that promote inflammation and glial proliferation. Neurons are not directly infected by HIV. Instead, cytokines and viral factors lead to neuronal damage and dropout. The neurotoxin quinolinic acid is produced by macrophages. The highest concentrations of HIV occur in basal ganglia, subcortical regions, and frontal cortex. There is

wide variability HIV genotype, viral production by macrophages, and toxin production in AIDS patients, which may explain the variability in neuropathologic findings between individuals and even between different areas of the brain in the same individual.[813,814]

Though the severity of AIDS dementia does not correlate with neuronal loss, viral load, or CD4 cell count, dementia has a significant correlation with greater numbers of macrophages present within the brain, but there is only a borderline correlation with the numbers of HIV-infected cells (by immunohistochemical staining with antibody to gp41) in the brain.[813,815] A possible mechanism of injury to the brain may result from increased nitric oxide (NO) production. The presence of HIV has been shown to increase the amount of inducible nitric oxide synthetase (iNOS) in cell cultures with macrophages and with astrocytes. The number of astrocytes infected with HIV appears to be increased with HIV-associated dementia. A prolonged, high-level production of NO may account for the neurologic damage seen in HIV-infected persons.[816,817]

Examination of body fluids, including cerebrospinal fluid (CSF), reveals no specific findings for ADC. The CSF is usually acellular or demonstrates a mild lymphocytic pleocytosis. The total protein is elevated in about two thirds of cases. The IgG is increased in up to 80% of cases. Oligoclonal bands may be found in the CSF in a third of cases, but the myelin basic protein is usually not elevated. Although the levels of HIV-1 RNA in the CSF are not useful for diagnosis of ADC, the levels are predictive of the severity of dementia when it is present. In some cases, the HIV-1 RNA is high in the CSF even when the plasma level has been suppressed, and this is known as “CNS escape.” This may be due to prolonged use of antiretroviral therapy, poor compliance, and viral sequestration in the CNS.[812]

Radiologic features of ADC include diffuse cortical atrophy as well as periventricular and deep white matter abnormalities, with confluent areas of high signal intensity and sparing of subcortical U fibers. In contrast, lesions of opportunistic infections are more likely to be focal and have a mass effect. In children, calcifications of the basal ganglia can be seen with computed tomographic (CT) scans. The degree of cerebral atrophy may not correlate with the severity of disease. White matter hyperintensities that are small and ill-defined are seen with magnetic resonance imaging (MRI) scans, or attenuation can be seen on CT scans, and these findings suggest that HIV leukoencephalopathy may be present. Other findings with MRI include focal caudate nucleus atrophy and diffuse grey matter atrophy. Positron emission tomography (PET) scans show subcortical hypermetabolism in the early stages of ADC.[812,813,818]

Gross examination of the brain and spinal cord at autopsy rarely reveals specific lesions with ADC. Subcortical lesions are most prominent in lobar white matter and deep gray nuclei such as the thalamus, and atrophy can be mild to marked, with hydrocephalus ex vacuo. Therefore, multiple areas must be sampled for histologic examination.[812]

Microscopic findings with ADC may demonstrate increased macrophages and multinucleated giant cells. Diffuse myelin pallor may also be seen. However, up to half of patients with a history of ADC may have no histopathologic findings.[808,812] Areas of active HIV encephalitis contain abundant HIV RNA and DNA localized to macrophages and microglia, but not neurons. Areas with minimal or no inflammation have minimal proviral HIV.[819]

The differential diagnosis for ADC depends upon many factors. Injection drug users may have infarcts from previous bouts of endocarditis with embolization of thrombi. Patients with bacterial infections may show a purulent meningitis or localized vasculitis producing hemorrhage. Cryptococcosis may also produce meningitis. Toxoplasmosis may produce

abscesses. However, lesions from most opportunistic agents are subtle in appearance and may be characterized only by focal demyelination or hemorrhage. Malignant lymphomas can present as mass lesions that are grey to white, but they may also be diffuse or metastasize within the ventricles or along the meninges.[808]

The onset and severity of ADC may be increased with drugs of abuse, including cocaine, marijuana, and methamphetamine. Exposure to most drugs of abuse can increase brain levels of dopamine, which has been implicated in the pathogenesis of HIV-associated neurologic damage. HIV-infected macrophages and microglial cells within the CNS leads to release of HIV proteins such as gp120 and Tat that can bind to and impair dopamine transporter functions, leading to elevated levels of dopamine in the dopaminergic synapses in the early asymptomatic stage of HIV infection. Use of cocaine and methamphetamine further increases synaptic levels of dopamine. The synaptic dopamine can diffuse out and activate microglia through binding to dopamine receptors. The activation of microglia may result in increased HIV replication as well as increased production of inflammatory cytokines including tumor necrosis factor-alpha. The combination of increased viral load and cytokine release can cause apoptosis of dopaminergic neurons, leading to a dopamine deficit that may exacerbate ADC.[820]

No specific therapy is available for ADC. However, antiretroviral therapy has been shown to be effective in delaying onset or even restoring cognitive function. Patients treated with antiretroviral therapy are less likely to develop ADC and have fewer CNS lesions at autopsy. Since ADC is more common in the late stages of AIDS, survival from the time of diagnosis may be limited.[808,812] The N-methyl-D-aspartate receptor antagonist memantine may help protect against excitotoxic injury.[813]

Other CNS lesions may demonstrate a specific opportunistic infectious agent or neoplasm associated with AIDS, while others may result from immunologic or hypersensitivity phenomena as a result of HIV infection of CNS cells directly. Microglial and glial cell activation by HIV infection can lead to cytokine production, oxidative stress, and resultant neuronal apoptosis. The infection of monocyte/macrophage/microglial cells by HIV is the mechanism by which the pathologic changes are mediated in the CNS.[821,822,823]

**HIV ENCEPHALITIS.**-- Microscopic examination of the brain at autopsy in AIDS may reveal a subacute encephalitis consisting of multiple foci with mononuclear cells typical of small macrophages, microglia, and multinucleated giant cells in 5 to 10% of cases.[824] These are often seen near small blood vessels, most often in the basal ganglia, in deep cerebral white matter, and brainstem. They appear less commonly scattered in the grey matter or leptomeninges. The multinucleated giant cells are the hallmark of HIV infection involving the CNS. HIV can be demonstrated in their cytoplasm. Thus, the central nervous system remains an important reservoir for HIV infection, even with aggressive antiretroviral therapy.[330] Sometimes multinucleated cells can be quite numerous. Cerebral atrophy with multinucleated giant cells has been reported with HIV-associated subacute encephalitis in over 25% of AIDS patients. In some cases of HIV encephalitis, multinucleated giant cells are not found, but large amounts of HIV antigen may be found in macrophages and microglia.[821,822]

Radiologic MR imaging may show multiple sclerosis-like plaques from demyelination and gliosis accompanying more florid HIV encephalitis. The white matter plaques are typically nonenhancing, hypodense foci on CT imaging, compared with periventricular high signal areas on T2 weighting and FLAIR MRI.[825]



Laboratory methods are available to aid in diagnosis of HIV encephalitis. In tissues, immunohistochemical methods for detection of HIV with antibody to p24, gp41, or gp120 can be performed.[826] The occurrence of HIV encephalitis appears to be unrelated to the stage of AIDS. Perivascular or leptomeningeal lymphocytic infiltration may be seen even in persons with asymptomatic HIV infection.[827] In cerebrospinal fluid samples, an increasing level of HIV-1 RNA correlates with the presence of HIV encephalitis, though plasma HIV-1 RNA levels may not.[828]

**HIV LEUKOENCEPHALOPATHY.**-- HIV leukoencephalopathy may be seen in about 5% of AIDS patients at autopsy.[824] It produces diffuse bilateral damage to cerebral white matter that can be seen on magnetic resonance imaging (MRI). Occasionally the cerebellum is also involved. There is myelin loss involving mainly the deep white matter, with a tendency to spare the subcortical U fibers and the more compact myelin bundles of corpus callosum, internal capsules, optic radiations, and descending tracts in the brainstem. Grossly, the lesions are similar to multiple sclerosis plaques. By light microscopy, the predominantly perivascular lesions demonstrate myelin debris in macrophages, reactive astrocytosis, hemosiderin in macrophages, multinucleated giant cells, and little or no inflammation. Vacuolar myelin swellings can appear, as well as axonal damage. Oligodendroglial cells appear normal. Without the presence of multinucleated giant cells, the diagnosis depends upon the finding of HIV antigen in macrophages.[813]

The pathologic findings of HIV leukoencephalopathy and HIV encephalitis may overlap in a third of cases. A multifocal pontine leukoencephalopathy may rarely be seen in AIDS patients in which necrosis involves corticospinal tracts and crossing fibers. In one third of AIDS patients with dementia, histologic findings are minimal.[821] Pediatric AIDS encephalopathy (progressive neurologic disease) has similar findings, except that fewer cells can be demonstrated to contain HIV antigen and multinucleated giant cells are difficult to find.[418,813]

**MICROGLIAL NODULES.**-- Microglial nodules may be seen in both grey and white matter. About half of AIDS cases at autopsy will show these small focal areas, and there is a propensity for these lesions to involve the brainstem, though they can be seen anywhere. Microglial nodules are collections of cells, thought to arise from glial cells, that are mixed with inflammatory cells, including plump reactive astrocytes and lymphocytes, though a variety of inflammatory cell types may be present. They are often located near small capillaries that may have plump endothelial cells with nearby hemosiderin-laden macrophages. Sometimes the macrophages can give rise to multinucleated cells up to 25 microns in diameter with irregular nuclei and scant cytoplasm. Most of the astroglial cells in the nodules have round to oblong nuclei with scant cytoplasm. Small foci of necrosis may be seen in or near these nodules.

Microglial nodules are not specific for HIV infection and may be present with neoplasia, traumatic focal necrosis, or infection from viral, protozoal or bacterial organisms.[822] HIV and/or other infectious agents may be found. Specific etiologic agents in microglial nodules demonstrated in routine tissue sections with hematoxylin-eosin staining most often include cytomegalovirus and *Toxoplasma gondii*. Some microglial nodules have cells with immunoreactivity for HIV by immunohistochemical staining. In a few cases, no infectious agent can be demonstrated. Microglial nodules may be found in persons with asymptomatic HIV infection as well as patients with AIDS at all stages.[827,829]

**CD8 ENCEPHALITIS WITH IRIS.**-- Patients receiving antiretroviral therapy (ART) may develop a subacute encephalitis distinguished by a high proportion of CD8+ lymphocytes in the inflammatory infiltrates. This is one form of immune reconstitution inflammatory syndrome (IRIS). Patients develop encephalopathy with rapid onset. The CD8 cell response can be beneficial in fighting infection, but harmful when florid and with imbalance in CD4 / CD8 cell ratio. Pathologic findings include a diffuse infiltration by CD8+ lymphocytes, and variable numbers of CD4+ lymphocytes, but few B lymphocytes. Perivascular infiltrates predominate, but there is also intraparenchymal involvement. Lymphoid aggregation may be massive and reach pseudolymphomatous proportions. There is reactive astrocytosis as well as microglial activation and occasional microglial nodules, but without multinucleated giant cells. In some cases there is demyelination resembling multiple sclerosis; in other cases, features of acute demyelinating encephalomyelitis (ADEM) may be present. Some patients showed improvement with corticosteroid therapy, while continuing the ART.[830]

**PROGRESSIVE MULTIFOCAL LEUKOENCEPHALOPATHY (PML).**-- PML results from human polyomavirus infection (designated JC virus, from John Cunningham virus) affecting primarily the white matter of the brain. PML is seen most frequently in patients with AIDS, though it also occurs in other immune compromised patients. PML is diagnosed in about 5% of AIDS patients at autopsy.[824] The most frequent clinical presentation is characterized by motor deficits, altered consciousness, gait ataxia and visual symptoms. Cerebrospinal fluid analysis is typically normal, though some patients may have mild protein elevations along with mononuclear cell pleocytosis. Oligoclonal bands may be found as well. Diagnosis can be established definitively by brain biopsy, but less invasive techniques include PCR can detect JC virus DNA in CSF.[831,832]

Computerized tomographic imaging studies of the brain show asymmetric focal zones of low attenuation that involve the periventricular and subcortical white matter, compared with more symmetric areas seen in HIV encephalopathy. There is typically no hemorrhage or mass effect. The lesions tend to progress in number, size and lowered density over weeks to months. Magnetic resonance imaging (MRI) scans are more sensitive than CT for detection of small PML lesions, with extensive asymmetric white matter high signal areas on T2 (and low signal on T1) with sparing of the overlying cortical grey matter. The involvement of the "U" fibers creates a sharp border with the cortex. Lesions can be unilateral, bilateral, single, or multiple. In the early stages of PML, MR imaging shows multifocal, bilateral, asymmetrical lesions involving supratentorial regions, particularly frontal and parietal-occipital lobes. Lesions appear first in subcortical white matter, then spread to deep periventricular white matter. PML may eventually involve deep white matter in a periventricular distribution and corpus callosum. Infratentorial lesions may be located in middle cerebellar peduncles and adjacent pons and mid-cerebellum.[800,818]

Oligodendrocytes are targeted by the virus, leading to focal areas of white matter granularity a few millimeters in size that may coalesce. Abnormalities of white matter range from pallor to demyelination to necrosis. The grey-white matter junction is typically involved, and adjacent cortical grey matter may be involved. White matter tracts in cerebellum, brain stem, and cervical spinal cord may also be involved. The lesions are usually centered around capillaries.[831]

Microscopically, PML involves mainly the myelin-producing oligodendrocytes of white matter. The resulting cell lysis results in PML lesions that demonstrate demyelination with

perivascular monocytes, astrocytosis with bizarre or enlarged astrocytes (with occasional mitotic figures), and central lipid-laden macrophages. At the periphery of the lesions there are large "ballooned" oligodendrocytes infected with JC virus that have enlarged "ground glass" nuclei containing viral antigen. The presence of JC virus can be confirmed by immunohistochemical staining or *in situ* hybridization methods. Multinucleated giant cells containing HIV may also be present. A marked perivascular mononuclear infiltrate composed predominantly of T-lymphocytes may be present in some lesions. The JC virus can also be detected within peripheral blood lymphocytes in most AIDS patients with PML.[812,831] JC virus can be detected using PCR. In addition, bone marrow serves as a site of latency and of neurotropic transformation of JC virus.[833]

The prognosis with PML is not good, with a mortality of 30 to 50% within 3 months for most AIDS patients. A CD4 lymphocyte count above 100/ $\mu$ L is a favorable prognostic factor. Overall mortality is reduced with higher CD4 counts and when patients receive antiretroviral therapy.[834]

In some patients beginning antiretroviral therapy (ART), an immune reconstitution inflammatory syndrome (IRIS) can occur in the CNS within 3 to 6 months following initiation of ART, but may occur 2 years later. The most severe cases involve reactivation of JC virus with PML, with up to 42% mortality and neurologic impairment often requiring long term care in survivors. Up to 1 in 5 HIV-infected persons with a history of PML will develop PML-IRIS. With MR imaging, PML-IRIS is marked by absence of contrast enhancement, compared with PML. Not only CD4 cells, but also CD8 cells are found in the inflammatory infiltrates. Other viruses associated with CNS-IRIS include varicella-zoster virus, Epstein-Barr virus, cytomegalovirus, herpes simplex virus, and BK polyoma virus. The most common fungal pathogen associated with CNS-IRIS is *Cryptococcus neoformans*. In the absence of defined infection, fulminant HIV encephalitis may be the only manifestation of IRIS. MR imaging may reveal diffuse multifocal white matter changes with associated cerebral edema. Microscopically there are many CD8 lymphocytes with fewer macrophages, CD4 cells, and B cells diffusely infiltrating white and gray matter, leptomeninges, and blood vessels. Corticosteroid therapy may be of benefit.[835]

**SPINAL CORD.**-- HIV infection producing a myelitis is present in only about 8% of AIDS cases. Vacuolar myelopathy of the spinal cord may be seen in one third of AIDS cases, and though it is probably a consequence of HIV infection, it is not usually associated with HIV myelitis. Vacuolar myelopathy is manifested only when vacuolization is severe, and it presents with slowly progressive spastic paraparesis accompanied by loss of vibratory and position sense and urinary frequency and urgency. In males, erectile dysfunction can be an early manifestation.[836]

Vacuolar myelopathy is characterized mainly by vacuolar intramyelinic swellings of white matter, but also by infiltration with macrophages. Some vacuoles may appear in macrophages and axons. The vacuoles, 10 to 50 microns in size, usually appear in the posterior and lateral columns in a pattern similar to subacute combined degeneration. The disease starts in the mid to low thoracic cord and extends rostrally as it becomes more severe. The most severe lesions can also have clearing of macrophages from the centers of foci of involvement. Wallerian degeneration does not result from vacuolar myelopathy. The degree of gliosis does not correlate with the severity or duration of disease.[837] This myelopathy is not characteristic of pediatric cases, but decreased corticospinal tract axons and myelin does occur in

children.[838] T2-weighted MRI scans of the cord show bilateral, symmetrical regions of high signal intensity in the posterior columns, especially in the gracile tracts.[839]

Opportunistic infections of the spinal cord are uncommon. Toxoplasmosis is often disseminated, and can involve the cord as well as brain. Clinical findings with cord involvement, seen in half or more of cases, can include limb weakness, sensory loss, bowel / bladder sphincter involvement, and abnormal deep tendon reflexes. Cerebrospinal fluid findings include moderately elevated protein, mild mononuclear pleocytosis, and normal glucose level. MR imaging can show T2-weighted hyperintense areas or T1-weighted isointense lesions. Ring enhancement can occur. The thoracic spinal region is most often involved, and *Toxoplasma gondii* tachyzoites can be identified microscopically.[840]

**OPPORTUNISTIC INFECTIONS AND NEOPLASMS.**-- Toxoplasmosis, malignant lymphomas, cryptococcosis, and cytomegalovirus are the most commonly identified opportunistic infections and neoplasms in the CNS in patients with AIDS (Table 5).[448] Clinical use of Indium-111 WBC scintigraphy may aid in the detection of CNS inflammatory changes before either computerized tomography (CT) or magnetic resonance imaging (MRI) show structural changes.[703] A syndrome of inappropriate antidiuretic hormone (SIADH) may occur with central nervous system lesions.[841]

**CYTOMEGALOVIRUS (CMV).**—The prevalence of CMV in AIDS patients at autopsy has been declining from use of prophylaxis and therapy for CMV lesions outside the CNS, so that about 10% of cases show evidence of CMV.[824] There are no specific clinical findings seen with CMV in the brain. Nonspecific findings of disorientation, confusion, cognitive dysfunction, focal neurologic deficits, and impaired memory may be present, but these findings are similar to those of HIV dementia. Half of AIDS patients with CMV involving the CNS have no neurologic problems. There is usually widespread dissemination of CMV when the CNS is involved, though isolated CMV infection of the CNS is also possible. Concomitant CMV retinitis may provide a clue to diagnosis. The abrupt onset of mental status changes, along with radiologic findings of hydrocephalus and periventricular or meningeal enhancement, may also suggest CMV meningoencephalitis.[812, 842]

Examination of cerebrospinal fluid (CSF) may reveal increased protein and a mild lymphocytic pleocytosis. Cells with inclusions are generally not seen in the CSF. There is a poor correlation between the appearance and degree of neurologic problems and the pathologic findings with CMV infection of brain. The most common pattern of involvement is an encephalitis, which tends to be progressive with advancement in the course of AIDS. Grossly, there are no specific lesions to be seen.[842]

Radiographic studies of CMV infection in the CNS are nonspecific and in many cases do not reveal any abnormality. Radiographic imaging with CT may show diffuse white matter hypodensities, ependymal enhancement, and focal ring enhancing or nodular-enhancing lesions. MR imaging is more sensitive for detection of lesions of CMV infection and may include findings of increased signal with T2 weighting, particularly in periventricular regions. Necrotic ventriculitis may cause periventricular subependymal enhancement around the lateral ventricles, septum pellucidum, corpus callosum, and fornices, or demyelination may result in diffuse white matter abnormalities. Additional MR imaging findings can include ring- or nodular-enhancing lesions after gadolinium administration, or ependymal enhancement. Spinal cord and spinal

nerve root involvement leads to diffuse enhancement of the cord parenchyma, nerve roots and meninges with contrast-enhanced MRI.[800,825]

Microscopically, CMV can be the cause for a meningoencephalomyelitis. The most common locations for lesions are brainstem (pons or medulla most often), periventricular, basal ganglia, cerebrum (with cortex and white matter equally involved) and cerebellum. Lesions may also appear in the meninges or beneath the pia mater on gyral surfaces. Histologic patterns include ventriculitis, necrotizing vasculitis (which may be extensive), and microglial nodules. Large violaceous intranuclear and small basophilic intracytoplasmic inclusions can be present in ependymal cells, astrocytes, or even neurons. However, CMV inclusions can be difficult to find, even in the most common feature of microglial nodules.[449,822,842]

**TOXOPLASMA GONDII.**-- Toxoplasmosis is the most common etiology for focal brain lesions in AIDS, and it occurs in 3% to 40% of AIDS patients, most often in the advanced stages of HIV infection. The prevalence of toxoplasmosis seen at autopsy has been decreasing with the use of prophylaxis, and now appears in <10% of cases.[824] In most cases, toxoplasmosis is probably the result of reactivation of latent infection, since IgM antibodies are lacking. Toxoplasmosis involving the brain is probably the result of hematogenous dissemination from other organs, since the CNS lesions are typically multiple.[812]

Toxoplasmosis involving the brain can be a clinical presumptive diagnosis to define AIDS using the following CDC criteria:[421]

- Recent onset of a focal neurologic abnormality consistent with intracranial disease or a reduced level of consciousness; AND
- Evidence by brain imaging (computed tomography or nuclear magnetic resonance) of a lesion having a mass effect or the radiologic appearance of which is enhanced by injection of contrast media; AND
- Serum antibody to toxoplasmosis or successful response to therapy for toxoplasmosis.

Clinically, the most common presenting symptoms are fever, headache, and confusion or altered consciousness. These non-specific findings occur in about half of cases, while specific neurologic deficits occur in about two-thirds of patients with CNS toxoplasmosis. The most common focal neurologic signs include hemiparesis, ataxia, and cranial nerve palsies. Seizures are less frequent.[812,843,844]

The lesions of toxoplasmosis on computed tomographic (CT) scans may resemble the findings of either abscesses or neoplasms. Unenhanced CT findings include multiple lesions or focal lesions that appear as isodense masses compared to grey matter, but hyperdense if hemorrhagic. Lesions appear most often in basal ganglia, thalamus, and corticomedullary junctions. With contrast-enhanced CT imaging the lesions are usually ring-enhancing with surrounding vasogenic edema and mass effect.[825] The radiologic lesions progress as enhancing nodules, and they may be distinguished from lymphoma by presence of hemorrhage as well as their increased number and decreased size. On T2-weighted MR images, the majority of the lesions are iso- or hypointense surrounded by high signal intensity vasogenic edema. Cerebral toxoplasmosis appears as hypointense on T1 weighted scans; there is moderate to intense ring enhancement with contrast enhancement on MRI. Thallium-201(Tl-201) brain spectral emission computed tomography (SPECT) has been utilized to differentiate toxoplasmosis from lymphoma. In patients with toxoplasmosis, no uptake of Tl-201 is identified

in CNS lesions in contrast to lymphoma, where an abnormal increased uptake is usually found.[800,703,818, 845]

Diagnosis of toxoplasmosis cannot be routinely made by CSF examination, and serum antitoxoplasma antibodies, though usually present, may be absent. However, if *Toxoplasma* serologic tests are positive and the CD4 lymphocyte count is  $<200/\mu\text{L}$ , then prophylaxis with trimethoprim-sulfamethoxazole may be useful.[223]

*Toxoplasma gondii* encephalitis produces necrotizing abscesses with acute and chronic inflammation, macrophage infiltration, and vascular proliferation. These lesions can be large and widespread; they usually are found in cerebral cortex, subcortical white matter, and deep gray nuclei. The numerous free tachyzoites at the periphery of necrotizing lesions are very destructive, and there is a significant inflammatory response with a variety of inflammatory cell types to them. True cysts or pseudocysts containing *T. gondii* bradyzoites may not have accompanying inflammation until the wall of the cyst ruptures. Cysts may not be numerous. Often there is vasculitis, thought to be an allergic response, and endothelial proliferation in some blood vessels has been observed.

*Toxoplasma gondii* lesions may organize and contain numerous lipid-laden macrophages. A fibrous capsule with collagen, typical for brain abscess, can often be identified in surgical biopsies, along with a lymphoplasmacytic infiltrate. At autopsy, a fibrous capsule is less commonly seen and inflammation may be sparse, with scattered neutrophils. Healing may continue to form small less than 0.5 cm cystic lesions with macrophages and surrounding gliosis. Organizing and cystic lesions contain few detectable organisms. Immunohistochemical staining with antibody to *T. gondii* helps to reveal the tachyzoites.[846]

Therapy with a combination of oral pyrimethamine and sulfadiazine results in a response for most patients with cerebral toxoplasmosis. Complications of skin rash and nephrotoxicity, usually from the sulfadiazine, occur in less than half of patients. Bone marrow toxicity of pyrimethamine can be ameliorated by concomitant folinic acid therapy. An alternative therapy consists of clindamycin with pyrimethamine. Treatment with leucovorin is often effective. Clindamycin and clarithromycin have also been used. Relapses are common, and mean survival is less than a year.[843,844] Life-long maintenance of pyrimethamine therapy (with or without sulfadiazine) is needed to prevent relapses. The lack of a response to antitoxoplasma therapy in 1 to 2 weeks may suggest the need to search for another diagnosis.[812]

**FUNGAL INFECTIONS.**— Though *Cryptococcus neoformans* is the most common fungal agent infecting the CNS in patients with AIDS, other organisms can include *Coccidioides immitis*, *Histoplasma capsulatum*, and *Blastomyces dermatitidis*.

Cryptococcal leptomeningitis and encephalitis are seen in less than 5% of patients with AIDS at autopsy.[824] The lack of extensive inflammatory cell reactions to *C. neoformans* from the immunocompromised status of AIDS patients may be the reason for lack of meningeal signs. The most common presenting features of CMV meningitis in AIDS include malaise, fever, nausea, vomiting, and headache. Encephalopathic features of lethargy, altered mentation, personality changes, and memory loss may occur.[488] Cranial nerve palsies, psychiatric abnormalities, and seizures are less frequent findings.[812] A subgroup of patients infected with *C. neoformans* var *gattii* have multiple enhancing lesions by computed tomography, high cryptococcal antigen titers, papilledema, and a worse prognosis, though this variant is more likely to be seen in patients who are not immunocompromised.[847]

By computed tomographic (CT) imaging, cerebral cryptococcosis may have high or low attenuated lesions with or without contrast enhancement. By magnetic resonance imaging (MRI) scans, lesions appear hypointense and discrete when T1 weighted, but they appear as hyperintense “soap bubbles” most often in the basal ganglia and thalamus that are well-circumscribed without edema when T2 weighted. The lesions are non-enhancing with contrast by MRI. Meningeal involvement may produce T2 hyperintensity, but the lack of a marked inflammatory response may make leptomeningeal involvement difficult to detect, but meningitis may be accompanied by mild dilatation of the ventricular system or (rarely) nodular meningeal enhancement on post contrast images. Dilated perivascular Virchow-Robin spaces filled with fungi result in the formation of nonenhancing cystic lesions of low density on CT scan, or low signal intensity on T1-weighted MR images, and high signal intensity on T2-weighted MR images. A mass effect from a “cryptococcoma” is rare and may be seen in ependyma or choroid plexus.[800,818,825,831]

Cerebrospinal fluid (CSF) examination is most helpful for diagnosis of cryptococcal meningitis by latex agglutination test for the antigen. Antigen may also be detected in serum. The India ink preparation is usually positive. Typical CSF findings include a mildly elevated protein, normal or slightly low glucose, and a lymphocytic pleocytosis. White blood cells and red blood cells may not be numerous in the CSF in patients with AIDS because of the poor inflammatory response to cryptococci. CSF findings may be normal in a fourth of cases. Changes in serum titers of cryptococcal antigen during treatment for acute meningitis or during suppressive therapy do not correlate with outcome of therapy.[488,848,849]

Gross pathologic involvement of meninges is difficult to detect due to paucity of inflammation. Involvement of brain parenchyma most often occurs in basal ganglia, midbrain, and cerebellum. Small gelatinous pseudocysts may often be found in the region of the Virchow-Robin spaces and superficial neocortex. Larger cysts may occur in basal ganglia and thalamus. Microscopically, numerous poorly encapsulated organisms are found in lesions with minimal inflammatory infiltrate of lymphocytes and plasma cells.[850]

The *C neoformans* organisms may be poorly encapsulated, and they are usually accompanied by a sparse inflammatory reaction with only a few lymphocytes or macrophages. Thus, a grossly apparent gelatinous exudate may not be present, though the patient may have clinical signs and symptoms of meningitis. A methenamine silver stain may be necessary to identify the organisms clearly in tissues.

For patients with CD4 lymphocytes counts  $<100/\mu\text{L}$ , prophylaxis with fluconazole or ketoconazole may be useful. Fluconazole is most often used for secondary prophylaxis, since many patients with treated *C neoformans* infections will have a recurrence without continued suppressive therapy. Treatment with amphotericin B, flucytosine, and triazoles (fluconazole, itraconazole) can be effective, though up to 30% of cases fail to respond to therapy.[223,426] For acute infections, intravenous amphotericin B followed by oral fluconazole has shown effectiveness. In some cases, institution of antiretroviral therapy has resulted in immune reconstitution with exuberant inflammation around established foci of infection and onset of more severe symptoms.[488]

Coccidioidomycosis involving the meninges may lead to headache and meningismus. Pulmonary disease is often present. CSF findings may include a WBC count, mainly lymphocytic, as high as  $10,000/\mu\text{L}$ . Though eosinophils are rare, they are highly suggestive of the diagnosis when present. Complications of obstructive hydrocephalus and vasculitis infarction can occur. Serum serology is more sensitive than CSF. Findings with histoplasmosis

are not distinctive; urine serology has high sensitivity and specificity. Blastomycosis involving the meninges may lead to a predominance of neutrophils as seen on CSF analysis. Diagnosis by CSF or urine antigen serology has a high sensitivity.[849]

**MALIGNANT LYMPHOMA.**-- Most CNS non-Hodgkin lymphomas seen with AIDS are primary neoplasms. CNS involvement by systemic lymphomas is more often meningeal. Overall, about 10% of patients with AIDS have CNS lymphoma at autopsy.[824] CNS lymphomas are of the diffuse large cell variety, high grade, and of B-lymphocyte origin. They are essentially an expansion of EBV-infected B-lymphocytes.[604] Patients may present with non-localizing symptoms which include confusion, lethargy, and memory loss. Less frequent findings include hemiparesis, aphasia, seizures, cranial nerve palsies, and headache.

Primary CNS lymphomas may be diagnosed clinically by radiographic findings. By computed tomographic (CT) scans, the single or multiple lesions are hyperdense with solid or ring enhancement. When they appear as multiple discrete ring-enhancing lesions, they are very similar to those seen with toxoplasmosis. CT scans may show the distribution of the lesions to be near a ventricle, in the basal ganglia, or near subarachnoid space. Mass effect and edema are frequently present.[601] By magnetic resonance imaging (MRI) the lesions are hyperintense with T1 weighting and isointense to hyperintense masses with moderate edema and mass effect with T2 weighting, and there is homogenous or ring enhancement with contrast.[846] Features that suggest malignant lymphoma, rather than toxoplasmosis, include: periventricular location (particularly in deep white matter), solitary lesion, homogenous enhancement of a lesion greater than 2 cm in size, and limited edema or mass effect.[825]

Grossly, the most common pattern for CNS lymphomas is that of widespread infiltration without a discrete mass lesion, whether unifocal or multifocal. Most occur above the tentorium. Microscopically, they are often difficult to classify, particularly in small biopsies with extensive necrosis, though all are high grade and most are of an immunoblastic or large cell type. Almost all demonstrate *BCL-2* gene expression.[851] Whether a prominent mass is seen or not, there is generally extensive perivascular spread in the brain or spinal cord. Necrosis may also be extensive. In about one fourth of AIDS patients with lymphoma, only the CNS is involved. Prognosis is poor, with survival of only a few months despite treatment.[812,821,822]

**KAPOSI SARCOMA.**-- Kaposi sarcoma involvement of the CNS is extremely rare. It may represent widespread involvement.[852]

**HERPES VIRUSES.**-- Herpes simplex virus type 1 (HSV-1) is occasionally reported in the central nervous system in AIDS. Varicella-zoster virus (VZV) and even HSV-2 have been identified in the brain lesions of AIDS patients who have had a clinical and radiologic picture corresponding to that of progressive multifocal leukoencephalopathy (PML). Although these cases may mimic PML very closely, computed tomographic or magnetic resonance imaging scans can show evidence of hemorrhage, a mass effect, or gray matter involvement.[821,822] Grossly, areas of necrosis may appear most commonly in temporal lobe, inferior frontal lobe, insula, or cingulate gyrus. Microscopically, the lesions can have petechiae with fibrinoid necrosis, perivascular mononuclear inflammatory cell infiltrates, and Cowdry type A inclusions in either neurons or glial cells. Immunohistochemical staining for HSV is helpful.

Herpes simplex virus infection of the CNS can have a varied clinical presentation, including confusion, fever, headache, anxiety, depression, and memory loss. The diagnosis can



be made in most, but not all, cases by PCR performed on CSF. Most patients respond to therapy with acyclovir or valacyclovir.[853]

Varicella-zoster virus (VSV) involvement of the central nervous system with AIDS can have several patterns. There can be multifocal leukoencephalitis, mainly involving the deep white matter and grey-white junction. Ventriculitis and/or periventriculitis may be accompanied by vasculitis and necrosis of the ventricular wall. The large amount of virus present leads to the appearance of many intranuclear Cowdry type A inclusions. Also seen are acute hemorrhagic meningo-myelorradiculitis with necrotizing vasculitis, focal necrotizing myelitis, and leptomeningeal arterial vasculopathy with cerebral infarction. A characteristic VSV skin eruption may not be seen in cases of brain involvement. However, infections can involve skin, viscera, spinal cord, and brain. Patients may have headache, confusion, and focal weakness. The clinical course can be protracted. The syndrome of post herpetic neuralgia, which is the persistence of pain lasting for more than 4 to 6 weeks following resolution of the skin lesions of VSV, may be seen in 8 to 15% of persons with HIV infection, particularly those that are elderly.[498,854]

Patients VSV vasculitis tend to present with deep, subcortical ischemic stroke and vasculopathy affecting large and small arteries. Cerebrospinal fluid analysis shows pleocytosis and high protein with normal glucose. VZV can affect small arteries in the CNS, accounting for small subcortical strokes. Necrotizing vasculitis affecting small arteries such as vasa vasorum can be associated with VZV infection with subsequent affection of large size arteries due to ischemia and disruption of the vessel wall.[855]

**MYCOBACTERIOSIS.**-- Mycobacterial infections of the CNS in patients with AIDS are uncommon, but most of these will be caused by *Mycobacterium tuberculosis* (MTB). The diagnosis may be made by culture of cerebrospinal fluid or by acid fast staining of tissue obtained by biopsy or autopsy. Lesions seen with CNS tuberculosis include: small tuberculomas, abscesses, communicating hydrocephalus, and infarction. Most patients will have concomitant pulmonary tuberculosis. Radiographic findings include supratentorial lesions at the corticomedullary junction, meningeal enhancement, and target lesions with tuberculoma characterized by ring-enhancement around a central area of enhancement or calcification, as seen with CT or MR imaging. Tuberculous meningitis produces an exudate most prominent in basal cisterns, which obscures the basal cisterns on unenhanced CT images, while diffuse enhancement of these areas is seen with contrast-enhanced CT imaging. MR imaging is more sensitive for detection of nodular enhancement of leptomeninges. Meningeal tuberculosis can be complicated by obstructive hydrocephalus.[818,825]

Meningeal tuberculosis may manifest clinically with headache, vomiting, meningeal signs, focal deficits, vision loss, cranial nerve palsies (typically the abducens), and raised intracranial pressure. HIV-infected persons with tuberculous meningitis with higher CD4 cell counts tend to have these findings but when the CD4 lymphocyte count is low then the presentation can be subtle and atypical with malaise, weight loss, low grade fever, and gradual headache. Cerebrospinal fluid cell counts may show 10 to 500 cells/ $\mu$ L, mostly lymphocytes, low glucoses, and increased protein. When CD4 cell counts are  $<50/\mu$ L, then the CSF findings are indistinct.[849]

Tuberculomas may be associated with focal neurologic signs, headache, confusion, and seizure. The CSF findings are not striking, and an accompanying meningitis is unlikely to be present. Most lesions are  $<1$  cm in size, supratentorial in adults, and more often infratentorial in

children. MTB abscesses can present similarly to tuberculomas, but are more likely to be solitary than tuberculomas. They tend to be larger than 3 cm.[849]

Cerebral vascular involvement with MTB leads to inflammation with vasospasm, thrombosis, and infarction of internal capsule, basal ganglia, and thalamus. Tuberculous radiculomyelopathy is manifested as subacute paraparesis.[856]

MTB reaching the brain hematogenously crosses the blood–brain barrier, infects microglial cells, and leads to formation of small granulomas in the meninges and adjacent brain parenchyma that may remain dormant for months to years. Tuberculous meningitis develops when a caseating granuloma ruptures into the subarachnoid space with an intense immune response and exudate formation. Tuberculous exudates may be less pronounced in association with HIV infection with diminished numbers of lymphocytes, epithelioid macrophages, and Langhans giant cells but more numerous acid-fast bacilli. Diagnosis can be made by finding *M. tuberculosis* bacilli in the cerebrospinal fluid; detection by nucleic acid amplification is more sensitive. The lipoarabinomannan antigen-detection test in serum or cerebrospinal fluid is a rapid assay to assist in diagnosis. Treatment including rifampin is most efficacious. Patients started on antiretroviral therapy may develop an immune reconstitution inflammatory syndrome (IRIS).[849,856]

*Mycobacterium avium* complex (MAC) in the CNS is uncommon and is usually an incidental finding at autopsy in patients who had disseminated MAC. No gross pathologic findings are typically present, but histologically there can be small foci containing lymphocytes and macrophages in a predominantly perivascular location. Clinical findings may suggest a meningitis and/or encephalitis.[857]

Tuberculous brain abscess may produce intracerebral masses in patients with HIV infection. Anergy is likely to cause a false negative tuberculin skin test. However, most patients will have a prior history of extra-cerebral tuberculosis with chest radiographic abnormalities. The CD4 lymphocyte count may be above 200/ $\mu$ L. Cerebral CT imaging will usually demonstrate more than one intracranial mass lesion.[858] Tuberculous abscesses are usually multiloculated; they are indistinguishable from pyogenic abscesses.[825]

MTB of the spinal cord produces the typical granulomatous inflammation with epithelioid macrophages, Langhans giant cells, and a mixture of additional inflammatory cells including lymphocytes. The granulomas tend to be well formed and localized. In persons with HIV infection, the lymphocyte population is mainly CD8 cells, and fewer CD4 cells, reversed from non-infected persons.[859]

Pott disease, or tuberculous osteitis, may complicate tuberculosis via hematogenous dissemination or paraspinal extension in persons with AIDS. Back pain and fever are typical findings. In comparison with pyogenic abscesses, paraspinal infection with *Mycobacterium tuberculosis* is more likely to produce spinal deformity, subligamentous spread and contiguous multilevel involvement.[860]

**SYPHILIS.**-- Persons with HIV infection have an increased incidence of neurosyphilis, reflecting the common risk factor of sexual transmission for both. The disease may be accelerated when immunosuppression worsens with the appearance of clinical AIDS. The risk increases when the CD4 lymphocyte count decreases below 350/ $\mu$ L. Persons with a serologic test for syphilis (RPR) that has a titer higher than 1:128 are at increased risk, compared to persons with RPR titer no more than 1:32 at the time of diagnosis. Use of antiretroviral therapy decreases the risk. Males are at greater risk. Clinical presentations include uveitis, altered

cognition, motor weakness, headache, and gait abnormality. Cranial nerve palsies can occur, with hearing loss, Bell's palsy, or visual disturbances. However, none of these individual findings is seen in more than a third of cases. Findings on lumbar puncture with analysis of cerebrospinal fluid include increased leukocytes, usually 10 to 100 cells/ $\mu$ L, mainly lymphocytes. There can be increased protein, but usually no more than 100 mg/dL. The glucose is normal to low. A positive VDRL is present in about three fourths of cases.[849,861]

Neurosyphilis involvement is usually meningovascular and less commonly an encephalitis. Findings can include acute or chronic meningitis, cranial and peripheral neuropathies, evidence for dementia, cerebrovascular disease, and myelopathy. Radiologic imaging may reveal evidence for ischemic infarcts from vascular involvement, primarily in the regions supplied by middle cerebral artery, or in brainstem or basal ganglia. Syphilitic gummas are uncommon and may appear as isolated, peripherally located, isodense nodular on unenhanced CT that enhance intensely with enhanced CT images, while they are isointense on T1 weighted and hyperintense on T2 weighted MR images. The CSF VDRL may have a high titer. Some patients may have repeated relapses. Relapses can occur over a year following initial therapy. Symptomatic infection is more likely when the CD4 count is lower.[862,863]

**MOVEMENT DISORDERS.**-- HIV-associated illnesses can be complicated by movement disorders. Tremors may be seen with HIV associated dementia (HIVD), with drug therapies such as trimethoprim-sulfamethoxazole, and rarely with opportunistic infections. Chorea may occur with lesions involving the subthalamic region, including those caused by HIV encephalitis, HIVD, PML, and cryptococcosis. Dystonia may occur with toxoplasmosis involving the basal ganglia, or with HIVD. Myoclonus can occur with HIVD and with infections, including toxoplasmosis, spinal tuberculosis, herpes zoster radiculitis, and PML. Parkinsonism, often atypical in presentation, can occur with HIVD as well as infections such as toxoplasmosis, PML, and tuberculosis.[864]

Opsoclonus–myoclonus syndrome (OMS) has been reported with HIV infection prior to start of antiretroviral therapy. OMS is characterized by continuous multi-directional chaotic eye movements and myoclonus. Some patients also exhibit ataxia and there may be an associated encephalopathy or behavioral disturbance. The etiology is unknown, but infectious, immune, or paraneoplastic mechanisms have been suggested.[865]

A syndrome resembling amyotrophic lateral sclerosis (ALS) has been described in patients with HIV infection. These cases occur in younger patients than is typical for classical ALS, they are unusually rapidly progressive, they show evidence of inflammatory response in the CNS which is typically absent in classical ALS, and they do not progress inexorably, but show variable improvement with ART. Reports of classical ALS in patients with HIV infection are rare and probably coincidental.[866]

**STROKE.**-- Prior to widespread use of antiretroviral therapy (ART), in the absence of opportunistic infections and neoplasms characteristic for AIDS, cerebral infarction in HIV infected persons was not common. Up to 7% of AIDS patients at autopsy might show some evidence for cerebral infarction, but clinical findings to accompany these lesions were rarely evident. In the era of ART, not only are HIV-infected persons living longer, but also the number of pathologic mechanisms contributing to cerebrovascular disease has increased. A large U.S. study showed an increase of 43% in persons admitted to hospital for stroke from 1997 to 2006, and the HIV-infected persons were younger than HIV-negative persons with stroke. In

addition, HIV-infected persons were more likely to have atypical clinical findings such as acute confusion, fever, and stepwise focal neurological presentation over hours to days.[867]

Risk factors for stroke with HIV infection, not related to opportunistic infections or neoplasms, include HIV-associated vasculopathy, aneurysm formation, vasculitis, accelerated atherosclerosis, coagulopathy, and small vessel disease. Coagulopathy may include antiphospholipid syndrome. In addition, cardioembolic events can occur in association with HIV-related cardiac disease such as cardiomyopathy.[867]

HIV-associated vasculopathy can be defined as an abnormality of intracranial or extracranial cerebral blood vessels that results directly or indirectly from HIV infection, excluding lesions related to opportunistic infections or neoplasms. The pathologic changes accompanying this vasculopathy can include ischemic lesions, while vascular changes can consist of hyaline thickening of small vessels, perivascular space dilation, rarefaction, and pigment deposition, with vessel wall mineralization and perivascular inflammatory cell infiltrates. Intravascular thrombi are rarely observed. Similar features have been observed in the arterial vasculopathy accompanying HIV infection in children.[867,868]

Proposed mechanisms for HIV-associated vasculopathy include direct HIV infection of endothelium, immune deposition, and cytokines released from activated mononuclear cells that can activate endothelium or cause direct cell damage. Atherosclerosis in larger cerebral arteries may be accelerated by metabolic complications of ART with dyslipidemia and insulin resistance with hyperglycemia. ART may lead to direct toxicity to endothelium.[867]

In a study of HIV-infected persons with stroke, 20% were due to HIV vasculopathy, while an infectious etiology was present in 28%, coagulopathy 19%, embolism from cardiac lesions 14%, and multiple etiologies in 11%. HIV vasculopathy may affect carotid arteries or medium-sized intracranial arteries, with pathologic features including multiple fusiform aneurysm formation, dilation, stenosis, and variable lumen diameter.[869]

**MISCELLANEOUS FINDINGS.--** Purulent leptomeningitis, bacterial cerebritis, and abscesses are often present in AIDS brains, particularly in persons with a history of injection drug use. Bacterial infection is typically secondary to septicemia because of infection elsewhere, usually a pneumonia. Organisms such as *Staphylococcus aureus*, *Streptococcus pneumoniae*, *Pseudomonas aeruginosa*, and *Haemophilus influenzae* should be considered in such a setting.[537,538] In a patient with gastrointestinal disease, *Listeria monocytogenes* should also be included as a possible pathogen.[538,541] A vasculitis with surrounding hemorrhage, or a septic infarct, are common microscopic findings.

In a small number of AIDS cases, there is extensive subarachnoid, intraventricular, or intracerebral hemorrhage without a demonstrable opportunistic infection or evidence of trauma. The cause may be a vasculitis from systemic bacterial infection, with the presence of neutrophilic infiltrates in and around small cerebral vessels. Central nervous system hemorrhages may be due to direct endothelial damage resulting from HIV infection.

An acute necrotizing meningoencephalitis may be produced by *Trypanosoma cruzi* infection, and is distinguished from *T gondii* infection by the presence of amastigote-filled macrophages in the former.[560] Bacillary angiomatosis, caused by *Bartonella henselae*, can produce encephalitis, myelitis, cerebral arteritis, and retinitis.[870] Cerebral microsporidiosis can occur with dissemination from the gastrointestinal tract, with appearance of multiple small ring-enhancing lesions by magnetic resonance imaging, and appearance of the spores in cerebrospinal fluid.[525]

Systemic fungal infections may involve the CNS. AIDS patients with disseminated blastomycosis have CNS involvement in a fourth to three-fourths of cases. Dissemination is more likely with lower CD4 counts. The mortality rate is high.[579] *Coccidioides immitis* infection is most likely to produce meningitis with clinical presentation of headache. Radiographic imaging may show basilar meningitis and hydrocephalus requiring ventriculoperitoneal shunting. Fluconazole therapy yields a good prognosis in most cases.[871]

Though *Penicillium marneffei* is best known for skin infection, it can affect the CNS. Half of persons with CNS involvement may not have the characteristic umbilicated skin lesions. There is acute onset of altered mental status with confusion, agitation, or decreased consciousness along with fever and nonspecific constitutional symptoms. Meningeal signs are usually absent. Lumbar puncture with CSF examination shows mild pleocytosis, with normal to mildly elevated protein levels and normal to mildly low glucose levels. Organisms are unlikely to be identified microscopically, and CSF culture for *P. marneffei* is required for identification. The course is typically rapid, with high mortality.[872]

Cysticercosis has been reported in HIV infected patients. Neurocysticercosis is the most frequent helminthic infection of the central nervous system and is caused by *Taenia solium* larvae. Giant cysts and racemose forms of neurocysticercosis seem to be much more frequent in HIV-infected patients and may be secondary to an uncontrolled parasitic growth because of an impaired cell-mediated immune response. Multiple masses are usually present.[873,874]

An infectious agent first called *Mycoplasma incognitus*, a strain of *Mycoplasma fermentans*, has been identified in brain tissue of some AIDS patients with acute or subacute encephalitis by use of immunohistochemical staining when no other opportunistic agent was found. Inflammation and necrosis may or may not be present with *M. fermentans*. This agent has also been found in reticuloendothelial tissues and kidney.[570,875]

In the era of antiretroviral therapy (ART) with increasing long-term survival of persons infected with HIV, an increase in beta amyloid deposition has been observed in the brains of patients dying with AIDS. Distribution of increased beta-amyloid is seen primarily in the frontal cortex, but also in hippocampus and basal ganglia regions. The beta-amyloid appears within neuronal soma and axonal processes in most cases, and within vascular walls in a few cases. Possible causes for this finding may include local intracerebral inflammatory responses to HIV may with increased amyloid precursor protein (APP) production and susceptibility to amyloid deposition, or ART therapy mediated by inhibition of insulin degradation enzyme.[876] In addition, HIV Tat protein inhibits the major A $\beta$ -degrading enzyme neprilysin, and the  $\beta$  chemokine, CCL2/MCP-1, associated with HIV migration to the brain, also causes an increase in A $\beta$ .[877]

## PERIPHERAL NERVE AND MUSCLE PATHOLOGY IN AIDS

PERIPHERAL NERVE.-- Many HIV-infected persons develop peripheral neuropathies that can be detected through careful history and neurologic examination. The etiology is more than just muscle wasting from debilitation, for there may be clinical signs and symptoms of pain, paresthesias, electromyographic abnormalities, elevated creatine kinase, and muscle group atrophy. About half of HIV-infected persons with a CD4 lymphocyte count  $<300/\mu\text{L}$  may be affected by peripheral nerve disease, a third symptomatic and a fifth asymptomatic. The most disabling symptom, seen in a third of patients, is neuropathic pain.[878,879] Criteria have been established for the clinical diagnosis of HIV-1-associated peripheral nervous system disorders. This classification requires laboratory evidence for HIV-1 infection for diagnosis.[880]

### I. HIV-1-associated acute inflammatory demyelinating polyradiculopathy (HIV-1-associated Guillain-Barré syndrome)

PROBABLE (must have):

1. Guillain-Barré syndrome by previously published criteria, except:  
CSF mononuclear leukocyte count can be as high as 50 cells per  $\text{mm}^3$

POSSIBLE (must have):

1. Other potential etiology present (must have *each* of the following):
  - a. As above (see *Probable*) #1.
  - b. Other potential etiology is present and the cause of (see *Probable*) #1 is uncertain.
2. Incomplete clinical evaluation (must have *each* of the following):
  - a. As above (see *Probable*) #1.
  - b. Etiology cannot be determined (appropriate laboratory investigations not performed).

### II. HIV-1-associated predominantly sensory polyneuropathy

PROBABLE (must have *each* of the following):

1. Distal limb sensory symptoms (feet > hands) of a peripheral nerve nature (e.g., numbness, burning, or pain).
2. Neurologic examination confirming a distal, relatively symmetric polyneuropathy in which sensory abnormalities predominate.

3. Electrodiagnostic studies indicative of a polyneuropathy with features of both axonal loss and demyelination.
4. Normal CSF cell count and only minimal, if any, elevation of protein, with negative VDRL.
5. No other etiology (including toxic exposure to dideoxyinosine). Nerve biopsy may be indicated to rule out certain etiologies such as amyloid, but is not a requirement.

*POSSIBLE* (must have *each* of the following):

1. Other potential etiology present (must have *each* of the following):
  - a. As above (see *Probable*) #1, #2, and #3.
  - b. Other potential etiology is present and the cause is uncertain.
2. Incomplete clinical evaluation (must have *each* of the following):
  - a. As above (see *Probable*) #1 and #2.
  - b. Etiology cannot be determined (appropriate laboratory investigations not performed).

### III. HIV-1-associated myopathy

*PROBABLE* (must have *each* of the following):

1. Symptoms of proximal lower and/or upper extremity weakness, documented by physical examination.
2. No other etiology (including toxic exposure to zidovudine). Electromyography (EMG) and muscle biopsy may be necessary to rule out certain other etiologies.

*POSSIBLE* (must have *each* of the following):

1. Other potential etiology present (must have *each* of the following):
  - a. As above (see *Probable*) #1.
  - b. Other potential etiology is present and the cause is uncertain.
2. Incomplete clinical evaluation (must have *each* of the following):
  - a. As above (see *Probable*) #1.
  - b. Etiology cannot be determined (appropriate laboratory investigations not performed).

Biopsy of peripheral nerve (typically sural nerve) is rarely performed and rarely reveals an opportunistic infection as a cause for neuropathy, but there may be lymphocytic infiltrates and demyelination in peripheral nerve indicative of acute or chronic inflammatory demyelinating neuropathy. An immunologic mechanism is suggested by improvement of patients with inflammatory neuropathies undergoing plasmapheresis, corticosteroid, or intravenous immunoglobulin therapy. There are several types of neuropathy seen with HIV infection. Either autoimmunity, cytomegalovirus, direct HIV infection, or toxicities from drug therapy may be an etiology for peripheral neuropathies.[881]

The most common HIV-associated neuropathy, which tends to occur with advanced HIV infection with CD4 counts  $<200/\mu\text{L}$  and high viral loads, is distal sensory polyneuropathy (DSP). It is likely a consequence of abnormal immune activation, not viral infection of nerves. DSP clinically is manifested mainly by sensory symptoms in stocking pattern of the feet and legs that can include spontaneous or evoked pain, but there can be loss of vibration and temperature sense. Though proprioception remains intact, the pain may be so severe that the patient cannot walk. The soles of the feet may be painful on palpation. Ankle reflexes may be reduced or absent. Though there may be accompanying muscle weakness, patients are usually not disabled by this weakness. Examination of cerebrospinal fluid may show a slightly elevated protein. The course of DSP is subacute to chronic. DSP typically manifests late in the course of AIDS, though it may occur earlier. DSP is predominantly an axonal neuropathy by electrophysiologic findings, but it may be difficult to distinguish from a toxic neuropathy from antiretroviral therapy, and many patients will have elements of both. The characteristic pathologic feature of DSP is axonal degeneration of long axons in distal regions, with a “dying back” pattern of degeneration. The density of both small and large myelinated fibers is reduced, but the density of unmyelinated fibers is reduced even more. DSP may exhibit variable lymphocytic infiltration of the perineurium, but perivascular inflammation is uncommon. Dorsal root ganglia have no blood-nerve barrier, and so can be injured by cytokines released from mononuclear cell infiltrates, leading to presence of degenerating neurons. Comorbidities that may exacerbate polyneuropathy include alcohol abuse, injection drug use, malnutrition, cobalamin (B12) deficiency, nephropathy, diabetes mellitus, and hypothyroidism.[879,882]

The second most common cause for polyneuropathy in HIV infection is treatment-related, or antiretroviral toxic neuropathy (ATN). Antiretroviral drugs in the category of nucleoside analogue reverse transcriptase inhibitors (NRTIs) including ddC (most common), ddI, and d4T, can be complicated by neuropathy and/or myopathy. The NRTIs contain azido groups that compete with natural thymidine triphosphate as substrates of mitochondrial DNA polymerase and terminate mtDNA synthesis. Zalcitabine (no longer used), didanosine, and lamivudine may cause neuropathy; stavudine may cause either neuropathy or myopathy with lactic acidosis; zidovudine may cause myopathy. The NRTI induced neuropathy may present with numbness, tingling, and pain. The appearance is that of a painful sensory polyneuropathy. It can be similar to neuropathies seen in relation to HIV infection, but may be distinguished by a temporal relationship to drug therapy. ATN usually occurs within 1 year of treatment and most often within the first 3 months. ATN appears to be dose-related, so lowering the dose or interrupting therapy may help to resolve the neuropathy. NRTI-specific peripheral neuropathy may be reversible when the drug is stopped. Pathologic findings include axonal degeneration most prominently in unmyelinated fibers along with abnormal mitochondria in axons and adjacent Schwann cells.[878,879,883] Patients receiving protease inhibitor therapy may develop



an HIV-associated sensory neuropathy-SN, which may potentiate neuronal damage in HIV-infected dorsal root ganglia, and this may occur from loss of macrophage-derived trophic factors.[291]

A less common polyneuropathy with HIV infection is inflammatory demyelinating polyneuropathy (polyradiculopathy) that may occur in association with moderately advanced HIV infection with CD4 counts between 200 and 500/ $\mu$ L. There are two forms: chronic inflammatory demyelinating polyneuropathy (CIDP) and acute inflammatory demyelinating polyneuropathy (AIDP). Both forms typically appear early in the course of HIV, with acute retroviral syndrome soon after infection, and long before the onset of AIDS. They are much less common than DSP. Both CIDP and AIDP manifest with motor and sensory symptoms. AIDP is associated with ascending weakness, back pain, distal paresthesias, and areflexia over a week to a month. CIDP is characterized by progressive predominantly proximal weakness and distal sensory abnormalities and areflexia developing over 2 months or more. Examination of the cerebrospinal fluid may reveal an elevated protein and a lymphocytic pleocytosis. Electrophysiologic studies may show slow conduction, delayed latencies, and conduction blocks. The initial pathologic finding with CIDP is lymphocytic and macrophage infiltration with demyelination. More advanced findings include remyelination, onion bulbs, minimal lymphocytic infiltration, and a reduced density of both myelinated and unmyelinated fibers. The pathologic findings with AIDP are more heterogeneous, resembling the findings of Guillain-Barré syndrome, with two forms. The more common form manifests with demyelination with macrophage and CD4 cell infiltration. The less common axonal form of AIDP shows minimal inflammation, no demyelination, and mostly changes of Wallerian degeneration.[878,879,881]

Mononeuritis multiplex (MM) may also be seen with either early or advanced HIV infection as a manifestation of a vasculitic neuropathy. When MM occurs early during the course of HIV infection, it is often the result of a self-limited immune-mediated neuropathy or vasculitis. Late in the course of HIV infection, it is often associated with cytomegalovirus infection. There may be cranial nerve involvement. The usual clinical presentation is sensory involvement, with numbness and tingling in distribution of one peripheral nerve trunk. Sequential sensory and motor involvement of other noncontiguous nerves may evolve over days and weeks. The initial multifocal and random neurologic features may progress to symmetrical neuropathy. Biopsy of MM shows epineurial and endoneurial necrotizing vasculitis. This vasculitis may be similar to the cryoglobulinemic vasculitis seen with hepatitis B and C infections.[878,881]

Progressive radiculopathy appears to be related to cytomegalovirus infection, typically late in the course of AIDS when CD4 counts are below 50/ $\mu$ L. Cytomegalovirus polyradiculopathy typically manifests as a cauda equina syndrome developing over a few days or weeks. There is mainly a motor deficit in an asymmetric distribution. A common initial finding is low back pain with radiation to one leg. This may be followed by urinary incontinence, saddle anesthesia, and progressive leg weakness. If the CMV infection is not treated, polyradiculopathy then advances to flaccid paraplegia with bowel and bladder incontinence, with death in a few weeks. Electrophysiologic studies show evidence of axonal loss in lumbosacral roots with later denervation potentials in leg muscles. Examination of the cerebrospinal fluid shows a low glucose, elevated protein, and a polymorphonuclear pleocytosis with 200 cells/ $\mu$ L. CMV can be demonstrated by culture or PCR analysis. Pathologic findings include marked inflammation with infiltrates of both neutrophils and mononuclear cells and necrosis of the dorsal and ventral nerve roots with cytomegalic inclusions detectable in endothelial cells and

nerve parenchyma. In severe cases, vascular congestion, edema, and parenchymal necrosis may be present.[878,881]

A condition known as diffuse infiltrative lymphocytosis syndrome (DILS) that may mimic lymphoma can rarely involve peripheral nerve. There is an acute or subacute painful sensorimotor axonal polyneuropathy. In this condition, there is a pronounced angiocentric infiltration of peripheral nerve with CD8 lymphocytes and a vascular mural necrosis. It is associated with massive HIV proviral load within nerve, as evidenced by increased HIV p24 expression in macrophages infiltrating nerve.[622,878,879]

Autonomic neuropathies may appear late in the course of HIV infection, with or without evidence of peripheral neuropathy, in up to 12% of patients. Parasympathetic failure may present clinically as resting tachycardia, palpitation, and genitourinary dysfunction. Sympathetic dysfunction may be manifested by orthostatic hypotension and syncope, anhidrosis, and gastrointestinal disturbances. Ganglia may show neuronal degeneration with perivascular mononuclear cell infiltration. Comorbidities may include anemia and volume depletion, heart failure, and adrenal failure.[878,879]

In early HIV infection, neuropathies may occur transiently. Cranial and peripheral neuropathies, most often facial nerve palsy, may accompany primary HIV infection. Findings resembling Guillain-Barré syndrome may occur. A mononeuropathy resembling Bell's palsy has been observed.[878]

**SKELETAL MUSCLE.**— HIV-associated myopathy can occur at any stage of HIV infection, with no correlation to CD4 lymphocyte count or viral load, and has clinical and histopathologic features similar to those of polymyositis (PM). Affected persons have proximal, diffuse, and often symmetric muscle weakness that develops subacutely, over weeks to months, without cutaneous rash or involvement of the extraocular, eyelid (blepharoptosis), and facial muscles. Myalgias seem more frequent than in classic PM patients. EMG typically reveals abnormal spontaneous activity with positive sharp waves, fibrillations, and low-amplitude and short-duration polyphasic motor unit action potentials, but patients may also have a normal EMG. Serum creatine kinase (CK) levels are usually increased, often as high as 2500 IU/L, but may not correlate with disease severity. Muscle biopsy shows the characteristic triad of scattered necrotic and basophilic fibers, multiple foci of mononuclear inflammatory cells within fascicles, and focal invasion of non-necrotic muscle fibers by CD8 lymphocytes.[879,884,885]

The immunohistochemical staining to establish the diagnosis of PM includes: (1) endomysial infiltrates of activated CD8+ T cells; (2) ubiquitous sarcolemmal expression of MHC class I antigens by muscle fibers; and (3) focal invasion of non-necrotic fibers expressing MHC-I by CD8+ T cells, a condition termed MHC-I/CD8 complex. An autoimmune etiology has been postulated, and is substantiated by the benefit afforded by corticosteroid therapy, non-steroidal anti-inflammatory agents, plasma exchange, or intravenous immunoglobulin therapy.[879,884]

Dermatomyositis in association with HIV infection is rare. Reported cases have elevated creatine kinase and skin rash. A characteristic finding is the presence of Gottron's papules. These multiple hyperkeratotic, erythematous, flat papules with central atrophy on the dorsum of the metacarpophalangeal and interphalangeal joints. Microscopic examination of these lesions shows acanthosis, hyperkeratosis with focal vacuolar alteration of the basal-cell layer, and perivascular inflammatory infiltrates.[886]

Another form of HIV-associated myopathy is known as human immunodeficiency virus associated adult onset nemaline myopathy (HAONM). On muscle biopsy the skeletal muscle

fibers in HAONM show marked intra sarcoplasmic changes, including the presence of small vacuoles and granular degeneration, along with prominent, randomly distributed atrophic type 1 fibers with numerous intracytoplasmic rod bodies in the centers of the fibers, corresponding to the nemaline rods seen with electron microscopy. Necrotic fibers and inflammatory infiltrates are usually not found. Some patients may have a monoclonal gammopathy in association with this nemaline myopathy.[884]

Myopathy can be associated with nucleoside reverse transcriptase inhibitor (NRTI) therapy, including zidovudine (AZT) and stavudine therapy. The appearance of this myopathy is related to a longer course of therapy (months). It is estimated to occur in 0.4% of persons receiving AZT. Patients present with insidious pelvic and shoulder girdle muscular weakness with myalgia. Serum creatine kinase is increased 2 to 6 times normal. Cessation of the drug leads to reversal and recovery in weeks to months, with earlier recovery when weakness is less severe, but recovery may be delayed weeks to months.[879,883] The toxic effect appears to be directed at mitochondria, resulting in the hematoxylin-eosin-stained appearance of "ragged red" fibers.[281] Two-thirds of AIDS cases at autopsy reveal histologic abnormalities including disuse atrophy, denervation atrophy, and inflammatory myopathy, though opportunistic infections are rarely found.[887]

Sporadic inclusion body myositis, which is the most common inflammatory myopathy in persons over the age of 50, has been reported in association with HIV infection. There is initial proximal muscular weakness progressing to distal weakness and dysphagia. The persistent HIV infection may provide super antigenic stimulation that results in an endomysial inflammatory response. HIV-1 has been detected within endomysial macrophages, but not the muscle fibers, indicating that retroviruses do not directly infect muscle but trigger an immune response. Muscle biopsy shows primary endomysial inflammation, red-rimmed vacuoles, amyloid deposits, eosinophilic inclusions, and small round fibers in groups. Muscle fibers express MHC class-1 antigens and are invaded primarily by CD8+ T-lymphocytes.[879,888]

Diffuse infiltrative lymphocytosis syndrome (DILS), a rare condition in HIV-infected patients, is characterized by persistent CD8 hyperlymphocytosis and multivisceral CD8 T-cell infiltration that results from a strong host response to HIV infection. DILS usually presents as painless parotid enlargement, but extraglandular complications of DILS include facial palsy, peripheral neuropathy, polymyositis, lymphocytic interstitial pneumonitis, renal tubular acidosis, lymphocytic hepatitis, and lymphoma. In DILS, muscle lymphocytic infiltration is usually found in the setting of peripheral neuropathy and/or inflammatory myopathy. Diagnostic criteria with HIV infection include circulating CD8 hyperlymphocytosis at  $>1000/\text{mm}^3$  and histological confirmation of CD8 T-cell infiltration in three different organs or tissues.[884] DILS appears to be antigen-driven, and antiretroviral therapy is effective in treating it.[623]

Pyomyositis is a disease that is endemic to tropical regions, but can occasionally be seen in conjunction with immunocompromised states, including HIV infection, in temperate climates. Pyomyositis is a bacterial infection of skeletal muscle and is clinically marked by gradually developing fever along with localized muscle pain, swelling, and tenderness. The lower extremity is four times more likely than the upper extremity to be involved. Areas most often affected include thigh, thigh with the calf, buttock, upper extremity, and iliopsoas. A history of trauma may have preceded development of pyomyositis. CT imaging shows muscle swelling and well-delineated areas of fluid attenuation with rim enhancement with contrast. T1-weighted MR imaging shows higher signal intensity in involved muscles, with a rim of increased intensity at the border of the involved region. On T2-weighted images, this rim is of low intensity with

gadolinium enhancement, whereas the affected muscle displays heterogeneous increased intensity. Foci of homogeneous intensity usually correspond to fluid collections. Thickening of fascial planes and reticulation of subcutaneous fat with overlying thickened skin may also be seen. Leukocytosis may or may not be present. The serum creatine kinase may not be elevated. Blood cultures may be positive in a sixth of cases. *Staphylococcus aureus* is the most common organism cultured, followed by streptococci. Pathologically, there is extensive necrosis of muscle with neutrophilic exudates. Pyomyositis is treated with antibiotics if diagnosed early, but surgical incision and drainage in conjunction with antibiotic therapy are required for more advanced cases.[889,890]

Acute rhabdomyolysis is uncommon but may occur at any stage of HIV infection, manifesting as rhabdomyolysis in primary HIV infection, recurrent rhabdomyolysis, and isolated rhabdomyolysis. Rhabdomyolysis at the end stage of AIDS may or may not be associated with opportunistic infections of muscle. Antiretroviral drugs causing rhabdomyolysis in HIV patients include didanosine, lamuvidine, raltegravir, tenofovir, and etravirine. The protease inhibitors (PIs) ritonavir and delaviridine inhibit the cytochrome P450 3A4 isozyme (CYP3A4) hepatic enzyme, and concurrent use of PIs and simvastatin or lovastatin that rely on CYP3A4 for metabolism can increase statin levels and increase the potential for rhabdomyolysis. The antibiotic combination trimethoprim-sulfamethoxazole has also been implicated in rhabdomyolysis.[879,884]

Other skeletal muscle findings include atrophy with HIV wasting syndrome, marked by reduction in lean body mass, while body fat stores are maintained. Muscle biopsy may show diffuse atrophy, or type II atrophy, mild neurogenic atrophy, or thick-filament loss, without conspicuous inflammation, as in other cachectic myopathies of other causes. Inflammatory changes are not common. Possible causes of HIV-wasting syndrome include increased release of the proinflammatory cytokines interleukin (IL)-1 and tumor necrosis factor (TNF)-alpha from HIV-infected monocytes/macrophages. Additionally, the ubiquitin-ATP-dependent proteolytic system is activated in muscle from cachectic AIDS patients, possibly in response to changes in circulating cytokines. There is also increased expression of the negative regulator of skeletal muscle growth myostatin.[884]

Myasthenia gravis (MG) is an uncommon complication in HIV-infected patients, most often occurring in early stages of disease, and can be the presenting manifestation. It tends to be a transient phenomenon that diminishes with increasing immunosuppression. MG is assessed by the edrophonium test and electromyography. HIV-associated MG is not always accompanied by the presence antibodies to acetylcholine receptors, but muscle specific kinase antibodies may be present.[879,884]

## OPHTHALMIC PATHOLOGY IN AIDS

Ocular disease associated with HIV infection is common and reduces quality of life, but is typically not life-threatening. Clinical diagnosis for ocular diseases in patients with AIDS is most often made by funduscopy exam. Findings may include a noninfectious microangiopathy, consisting of cotton-wool spots with or without retinal hemorrhages. This retinopathy occurs in two thirds of AIDS cases but can also appear less frequently with HIV infection. The HIV envelope glycoprotein may induce an inflammatory state in retinal pigment epithelial cells, impairing its integrity and contributing to retinopathy.[891,892]

Opportunistic ocular infections are frequent with cytomegalovirus (CMV) and infrequent with *Toxoplasma gondii*, *Pneumocystis jiroveci* (*carinii*), herpesviruses, *Cryptococcus*, *Candida*, *Histoplasma*, and atypical mycobacteria. Kaposi sarcoma and malignant lymphomas may infrequently involve conjunctiva, eyelid, or orbital tissue. Neuro-ophthalmic lesions (cranial nerve palsies, optic neuropathy, papilledema) appear in less than 10% of AIDS cases but frequently accompany cryptococcal meningitis.[893]

A study comparing ocular disease in HIV-infected persons in two cohorts, from 1995-2003 and 2004-2010, both including patients receiving antiretroviral therapy. The findings included a decrease in infectious diseases from 55% of patients in the early period to 38% in the late period, primarily a result of a decrease in cases of cytomegalovirus retinitis. However, noninfectious diseases increased from 46% of patients in the early group to 62% in the later group. Also, severe visual impairment was more likely to occur in the later group.[894]

Cytomegalovirus is the most common clinical and autopsy ocular finding in patients with AIDS. CMV may lead to visual loss via multiple pathways. The most common is retinitis, which occurs in two thirds of CMV infections. Additional CMV associated ocular lesions include cataracts, retinal detachment, macular edema, and epiretinal membrane. CMV infection is most likely to occur when the CD4 count is below 100/ $\mu$ L, so patients receiving antiretroviral therapy are less likely to develop complications. Patients with CMV retinitis typically present with progressive painless loss of vision that begins in one eye, but involvement may extend to both eyes if not treated. Other findings noted by patients include floaters, photopsias, visual field loss, and blurred vision.[448,891,895]

For presumptive clinical definition of AIDS, diagnosis of CMV retinitis is defined as:[421]

A characteristic appearance on serial ophthalmoscopic examinations (e.g., discrete patches of retinal whitening with distinct borders, spreading in a centrifugal manner along the paths of blood vessels, progressing over several months, and frequently associated with retinal vasculitis, hemorrhage, and necrosis).

On funduscopy examination, CMV retinitis appears as a full thickness retinal infection that originates peripherally as perivascular, opaque white, granular areas of retinal necrosis with associated hemorrhages. It advances centrifugally along retinal vessels, and the advancing edge has a granular appearance due to engorgement of retinal cells with virions. If it is not treated, CMV retinitis progresses at a median rate of 24  $\mu$ m per day and produces full thickness retinal necrosis that may result in rhegmatogenous retinal detachment (RD) within 3 to 6 months of diagnosis.[892,895]

Therapies may include ganciclovir, valganciclovir, and foscarnet. Cidofovir has a narrow therapeutic-toxic window and complications of uveitis and decreased intraocular pressure (hypotony), so is not often used. Relapse of CMV following treatment can occur. Drug resistance is uncommon. Resolution of active CMV retinitis may leave retinal scarring and atrophy with retinal pigment epithelial mottling. Loss of vision may result from retinal destruction, optic nerve involvement, and retinal detachment. Along with antiretroviral therapy, the ganciclovir implant and use of valganciclovir have led to better control of CMV retinitis and lower rates of retinitis progression, retinal detachment, and visual loss. However, even among patients with immune recovery, the incidence of retinal detachment in at least one eye is over 100-fold greater than that in the general population [892,895]

However, patients receiving antiretroviral therapy resulting in a rise in CD4 lymphocyte counts may experience spontaneous healing of CMV retinitis lesions, even in the absence of anti-cytomegalovirus therapy. Such patients may also have atypical features of ocular CMV infection, including moderate to severe anterior chamber or vitreous inflammation.[891] The immune reconstitution inflammatory syndrome (IRIS) that accompanies successful antiretroviral therapy occurs in about 3% of patients as a result of partial reconstitution of the immune system sufficient to allow an inflammatory reaction to develop against a previously subclinical CMV infection. Clinical features include decreased visual acuity and floaters. Polymorphisms in the IL-10R1 gene are associated with risk for development of CMV retinitis. An amino acid substitution rs2229114 in the IL-10R1 gene appears protective against CMV retinitis.[310,895]

Cytomegalovirus can be confirmed at autopsy by finding characteristic inclusion bodies in the choroid. About half of CMV retinitis cases have an acute inflammatory reaction. Treatment and/or long survival may lead to extensive degeneration with loss of cells of the retina. About 20% of AIDS patients with CMV retinitis may eventually develop retinal detachment. Persons receiving antiretroviral therapy are less likely to develop retinal detachment.[892,895]

Clinically, CMV retinitis can produce loss of vision and on occasion severe discomfort, but symptomatology is lessened by antiviral therapy with ganciclovir or foscarnet. Cidofovir therapy can also be used and has the advantage of longer dosing intervals. The newest agents include formiverson and valganciclovir.[895] Initial response rates are high but recurrence of CMV retinitis can occur, so the goal of therapy is to delay progression of disease.[448] Ganciclovir implants have been employed for ongoing therapy, and pathologic findings associated with this therapy include fibrous ingrowth from the implant site into the vitreous, vitreous hemorrhage, and foreign body giant cell reactions to suture material, but these are benign occurrences because of limited extension.[896] When funduscopy examination reveals evidence for CMV and therapy is instituted, there is a decreased likelihood that the patient will have nonocular organ involvement by CMV.[892]

The second most common cause for retinitis in AIDS is infection with the Varicella-zoster virus (VZV), seen in 1 to 4% of HIV-infected persons, typically when there is involvement of the ophthalmic division of the trigeminal nerve. VSV can produce several patterns of ocular involvement. Acute retinal necrosis produces sharply demarcated inflammation of the anterior uveal tract and peripheral circular necrosis with centripetal progression toward the posterior pole associated with vitreitis, occlusive periarteritis, and confluent full thickness retinal necrosis. This process leads to decreased visual acuity, ocular pain, neuritis, arteritis, phlebitis, scotomata, and narrowing of the visual field. There can be eventual blindness from optic atrophy. Progressive outer retinal necrosis, or rapidly progressive

herpetic retinal necrosis, occurs most often with advanced AIDS and is often bilateral with involvement of deeper retinal layers, macular involvement, retinal detachment, and outer retinal opacification. This condition can be treated with ganciclovir and foscarnet.[498,895]

The eye is the most common extracerebral site for toxoplasmosis. The typical clinical manifestations of ocular toxoplasmosis include impaired visual acuity with blurred vision and visual field defects, photophobia, and redness. Chorioretinitis may be seen on fundoscopic examination.[516] The lesions are often multifocal and bilateral. There can be moderate to severe anterior chamber and vitreous inflammation and pigmented chorioretinal scars, but hemorrhages are not common.[891]

Herpetic retinitis may produce loss of visual acuity and blindness, similar to CMV, but morbidity and mortality may be higher. Herpetic retinitis appears in two forms. Acute retinal necrosis presents as a peripheral retinitis, spreads rapidly in a centrifugal fashion, and can occur at any CD4 count and in patients without immune compromise. Progressive outer retinal necrosis often presents with posterior pole involvement, spreads even more rapidly, occurs largely among patients with CD4 cells  $<50$  cells/ $\mu$ L, and has a worse prognosis.[897]

A retinal microvasculopathy may be observed in over half of AIDS cases. It is non-infectious, but the cause is unknown. Findings include cotton wool spots, intraretinal hemorrhages, and retinal microaneurysms. This condition is more likely to occur when the CD4 count drops below 100/ $\mu$ L. This condition is usually asymptomatic and transient.[891]

Acute anterior uveitis has been reported as a reversible complication in patients receiving the drug rifabutin used to treat *Mycobacterium avium*-complex (MAC) infections. Persons who weigh more than 65 kg are at greater risk. Use of a lower dosage may help avoid this complication.[898]

Conjunctival microvascular changes may be observed in up to 75% of HIV-infected persons. Such lesions, best observed by slit-lamp examination, are typically asymptomatic and include segmental vascular dilation and narrowing, microaneurysm formation, comma-shaped vascular fragments, and sludging of the blood column. Coexistent retinal microvascular changes are often present with CD4 lymphocyte counts below 100/ $\mu$ L.[891]

Keratitis, though rare, can lead to loss of vision. The most common causes are varicella-zoster virus and herpes simplex virus. Ocular complications with VZV in HIV infected persons may include reduced corneal sensation, corneal epithelial lesions, and uveitis in half or more cases, as well as elevated intraocular pressure and extra-ocular muscle palsy. Zoster keratitis and uveitis may progress to more severe disseminated disease, peripheral ulcerative keratitis, and acute retinal necrosis. The severe complication of chronic infectious pseudodendritic keratitis is usually found just with AIDS.[891,899]

Ocular syphilis is found in less than 1% of persons with HIV infection and it tends to have more aggressive, severe, and relapsing manifestations than in immunocompetent persons. Findings include granulomatous or nongranulomatous anterior uveitis, panuveitis, necrotizing retinitis, optic neuritis, papillitis, chorioretinitis, vitreitis, retinal detachment, branch retinal vein occlusion, interstitial keratitis, and scleritis. Blindness may occur.[891]

Ocular tuberculosis may occur in up to 2% of patients with HIV infection. Presenting findings can include choroidal granulomas, subretinal abscess, panophthalmitis, and conjunctival involvement. Patients all have pulmonary tuberculosis. Ocular involvement can occur over a wide range of CD4 lymphocyte counts, but generally below 300/ $\mu$ L, and the extent of disease does not correlate with level of immunosuppression or adequacy of antitubercular therapy.[900]

Ocular lymphoma may occur as an extension of CNS disease or choroidal involvement

from systemic disease. Most cases are of the large B cell non-Hodgkin lymphoma variety. Funduscopic findings include confluent yellow-white retinochoroidal infiltrates, perivascular sheathing, and retinal necrosis may occur with vitreitis and floaters.[895]

Additional infectious lesions of the orbit around the eye may be seen. HIV-infected patients with infections at this site are likely to have a very low CD4 lymphocyte count. Reported bacterial agents include *Staphylococcus aureus*, *Pseudomonas aeruginosa*, and *Propionibacterium acnes* producing orbital cellulitis or panophthalmitis. Fungal agents include *Rhizopus* and *Aspergillus* that can spread intracranially. Orbital involvement with *Pneumocystis jiroveci* (*carinii*), *Microsporidium* species, and *Toxoplasma gondii* have also been reported.[891,901]

Malignancies involving the eye can include squamous cell carcinoma (SCC) of the conjunctiva. Characteristics of conjunctival SCC can include corneal overriding, fast growth rate with size larger than 1 cm, changes in conjunctival color, and nasal-sided locations. Lesions may show regression with antiretroviral therapy.[891]



## LYMPH NODE PATHOLOGY IN AIDS

Lymphadenopathy is frequent in persons with HIV infection, occurring either as one of the earliest manifestations of infection or as a finding at any time throughout the clinical course of progression through AIDS.[54,207,902] At least one fourth of persons with AIDS have lymphadenopathy on physical examination at some time during their course. A wide variety of opportunistic infectious agents and neoplasms involve the lymph nodes of AIDS patients, though the most frequent are *Mycobacterium avium* complex (MAC), *M tuberculosis*, *C neoformans*, Kaposi sarcoma, and malignant lymphomas (Table 5). Lymphadenopathy with characteristic histologic features, however, can be seen in the absence of opportunistic infections and is known as HIV-related lymphadenopathy.

Sections of lymph node should be viewed under polarized light to determine if birefringent crystalline material is present, indicative of injection drug use. Mediastinal or periportal lymph nodes are best for this purpose.

**HIV-RELATED LYMPHADENOPATHY.**-- The histologic manifestations of HIV-related lymphadenopathy can be grouped into four major patterns: florid follicular hyperplasia, mixed follicular hyperplasia and follicular involution, follicular involution, and follicular depletion. In general, these patterns follow in the above sequence and parallel the decline in CD4 lymphocytes. With the exception of the follicular hyperplasia pattern with follicular fragmentation that is seen most frequently in inguinal and axillary lymph nodes, these patterns appear in lymph nodes throughout the body, regardless of the presence or absence of gross lymph node enlargement, and indicate that a single node biopsy will yield valid findings.[902]

The florid follicular hyperplasia pattern demonstrates reactive follicular centers that vary widely in size and shape. The follicles may represent more than two thirds of the cross-sectional area of the lymph node and the follicular centers may occupy three fourths of the cross-sectional area. Surrounding mantle zones are attenuated to absent. Follicular dendritic cell meshworks are disrupted. Within the follicles are tingible-body macrophages, mitoses, and large lymphocytes, plasma cells, and scattered small lymphocytes singly or in clusters. Small foci of follicular hemorrhage may also be seen.[902] With electron microscopic examination, HIV can be observed budding from both lymphocytes and follicular dendritic cells in greatest numbers in germinal centers of follicles.[85] CD8 lymphocytes can be found in germinal centers at all stages of HIV infection.[89]

The mixed follicular hyperplasia with follicular involution pattern shows follicles that encompass less than two thirds of the cross-sectional area of the lymph node. The interfollicular areas are larger than those of florid follicular hyperplasia and contain large numbers of plasma cells, perisinus cells, sinus histiocytes, and immunoblasts. The network of dendritic cells is disrupted. Foci of hemorrhage appear in germinal centers, with necrosis and follicular infiltration by small lymphocytes as the process progresses. Mantle zones are reduced or absent. Less than half of follicles show involution. Warthin-Finkeldey type giant cells, or polykaryocytes that represent syncytia of HIV-infected lymphocytes, can be demonstrated in slightly less than half of lymph nodes with this pattern, or about twice as often as in nodes with the other patterns.[902]

The follicular involution pattern shows more pronounced overall hypocellularity than the preceding patterns. Follicular centers are still present but are somewhat smaller than with follicular hyperplasia patterns, lack tingible-body macrophages, lack mantle zones, and are often hyalinized (scarred). Hyalinized blood vessels penetrate the involuted follicles. Arborizing post-capillary venules with high endothelia are prominent. Both CD4 and CD8 lymphocytes are reduced.[902]

The follicular depletion pattern has absent follicles. The lymph node cortex is narrow or undefined and the medullary cords and sinuses occupy most of the cross-sectional area. There can be subcapsular and sinusoidal fibrosis. CD4 cells are absent, as are dendritic cells, and just a few CD8 cells are present. Small blood vessels appear prominent due to decreased overall cellularity, and scattered histiocytes appear in sinuses. Immunoblasts and/or plasma cells may be seen throughout the node. The depletion pattern is the most commonly recognized pattern with AIDS at autopsy.[902]

Prior to the onset of clinical AIDS (in the stage of HIV infection previously known as persistent generalized lymphadenopathy (PGL), as well as some cases of AIDS-related complex) the lymph nodes throughout the body are large but usually do not exceed 3 cm in size and they may vary in size over time. This is a form of reactive hyperplasia, with lymphoid proliferation and prominent germinal centers, driven by HIV harboring dendritic cells. PGL often resolves spontaneously.[46]

Most HIV-infected patients prior to onset of AIDS have follicular hyperplasia, with or without follicular fragmentation, while almost 90% of AIDS patients have follicular atrophy or depletion patterns. Though the lymph nodes in patients with AIDS can be small, they are routinely enlarged from 1 to 2 cm. During the hyperplastic phase, germinal centers contain predominantly CD19+ B-lymphocytes, which may account for hypergammaglobulinemia. However, CD4 lymphocytes continue to decrease as a patient moves from follicular hyperplasia to depletion.[902]

Antiretroviral therapy (ART) can suppress viral replication and lead to partial reconstitution of the immune system. In the lymph nodes the population of follicular dendritic cells can be restored, and a follicular pattern may be partially restored. However, CD4 lymphocyte counts may not significantly increase. Abnormalities in lymphoid architecture persist with ART. In one study, 89% of lymphoid tissues showed abnormal T lymphocyte populations, 43% showed absence of follicles, 43% showed hyperplasia, and 14% showed regression.[902,903]

**EXTRANODAL LYMPHOID TISSUES.--** Findings similar to those seen in lymph nodes may occur in lymphoid tissues elsewhere in the body in patients with HIV infection. Enlargement of nasopharyngeal and palatine tonsils may be associated with airway obstruction, pharyngitis, and a visible mass lesion. Histologic changes are similar to HIV-related lymphadenopathy, and the appearance of multinucleated giant cells is quite suggestive of HIV infection.[904]

**PEDIATRIC FINDINGS.--** Lymph node histopathologic changes with HIV infection in children may differ from those in adults. Findings reported at autopsy, mostly in association with deaths from AIDS, have included marked lymphocyte depletion, more selective follicular or paracortical atrophy, hemophagocytosis, hyperplasia, and lymphadenitis. About half of cases with lymphadenitis are due to an identifiable opportunistic infectious agent.[905]

**MYCOBACTERIOSIS.**-- Massive lymphadenopathy may indicate infection by *Mycobacterium avium* complex (MAC). Mesenteric and retroperitoneal lymphadenopathy due to MAC can demonstrate homogenous soft tissue attenuation by computed tomographic scan.[447] If the involvement is extensive, a grossly lemon-yellow cut surface of lymph node, similar in color to microbiologic culture plates, may be observed. Microscopically, MAC in lymph node may be associated with sheets of foamy macrophages (so-called pseudo-Gaucher cells), necrotizing granulomas, or non-necrotizing granulomas. In addition, a rare pseudotumor pattern has a proliferation of fibroblast-like spindle cells in a storiform pattern, without vascular slits but with abundant acid-fast bacilli, that is termed mycobacterial spindle cell pseudotumor. The foamy macrophages can occur as single cells, small clusters, or large sheets with hematoxylin-eosin staining and appear pale blue to striated. Wright-Giemsa stains can give these macrophages the appearance of a Gaucher-like cell. Acid-fast stains best reveal the presence of mycobacteria in the macrophages. These macrophages are CD68 and S100 positive by immunohistochemistry.[457]

*Mycobacterium tuberculosis* (MTB) is being seen with increasing frequency as a complication of HIV infection. By computed tomographic (CT) scan, mesenteric lymphadenopathy with low attenuation suggestive of necrosis, and occasional soft tissue attenuation, can be due to MTB. Tuberculous peritonitis on CT scan reveals high-attenuation ascites along with peritoneal and omental nodules.[447] The sites for involvement with tuberculous lymphadenitis include cervical lymph nodes in virtually all cases, followed by axillary involvement in 82%, ilioinguinal in 54%, and epitrochlear in 36%. The nodal size ranges from 1 to 3 cm, and involvement is usually symmetrical. The presentation overlaps with HIV lymphadenopathy.[906]

Histologically, with MTB infection there is usually a recognizable localized granulomatous reaction, including caseous necrosis. Langhans giant cells, lymphocytes, epithelioid macrophages, and fibrosis are present in variable numbers. Acid-fast tissue stain reveals rod-shaped acid-fast microorganisms similar to that described in non-HIV-infected patients. The organisms in the lesions are never as numerous with *M tuberculosis* as with MAC.

**FUNGAL INFECTIONS.**-- Lymph node involvement with the dimorphic fungi *C neoformans*, *H capsulatum*, and *C immitis* is frequent because these infections are often disseminated. The lymph nodes may be moderately enlarged and pale or mottled. Visible granulomas are infrequent. Cryptococci appear as clusters of oval, narrow-based budding organisms. The capsule is often missing so that the organism appears small enough to be confused with *Candida* or *H capsulatum*.[490] Epithelioid granulomas are usually absent with dimorphic fungi and any inflammatory reaction being sparse, giving a low power microscopic pattern of a clear or pale zone within the node.

Fungal organisms can be best demonstrated with a methenamine silver stain. Capsular forms of *C neoformans* appear prominent with PAS or mucin stains. Abundant clusters of small intracellular organisms are characteristic of histoplasmosis. These 2 to 4 micron organisms are usually found within macrophages. Toxoplasmosis or leishmaniasis may superficially resemble histoplasmosis. Methenamine silver stains the cell wall of *H capsulatum*, while the more delicate staining of PAS may reveal the nucleus. The microscopic appearance of large spherules with endospores indicates *C immitis*.

Lymphadenopathy with *Candida* organisms is rare but can occur in cases with widespread dissemination. Budding cells may be difficult to identify on hematoxylin-eosin staining, particularly when accompanied by necrosis. Tissue sections may show pale areas of staining in the subcapsular sinuses or sinusoids. An inflammatory reaction is usually sparse. When pseudohyphae are not prominent, these budding yeasts can be confused with *C. neoformans* and *H. capsulatum*. PAS or methenamine silver stains aid in differentiation. Definitive distinction may require microbiologic culture.

**CYTOMEGALOVIRUS.**-- Cytomegalovirus is identified very infrequently in lymph nodes, usually as part of a very widely disseminated infection. When CMV is present, it is most often seen within endothelial cells or histiocytic clusters in subcapsular sinuses, and inclusion bodies are not numerous. Pronounced inflammation, hemorrhage, or necrosis accompanying CMV in lymph nodes is very uncommon.[448]

**OTHER INFECTIONS.**-- Bacillary angiomatosis, which is caused by *Bartonella henselae* (formerly *Rochalimaea henselae*), may produce lymphadenopathy. Microscopic examination may show a pattern of coalescent nodules, which reveal a pseudoneoplastic proliferation of blood vessels with plump endothelial cells that have clear cytoplasm. The organisms can be best demonstrated by Warthin-Starry staining.[546]

Syphilitic lymphadenitis may occur in conjunction with HIV infection. The histologic appearance includes capsular fibrosis with fragmentation, follicular and interfollicular hyperplasia, vascular proliferation, plasma cell and plasmacytoid lymphocytic infiltration, and perivascular plasma cell cuffing in all or nearly all cases. Obliterative endarteritis is an infrequent finding, and spirochetes are demonstrated in a minority of cases. The microscopic findings are similar to cases in non-HIV-infected persons.[907]

**KAPOSI SARCOMA.**-- Lymphadenopathy may occasionally occur due to Kaposi sarcoma (KS), though often there will be no grossly identifiable features. By computed tomographic scan, lymph nodes enlarged by KS may show high attenuation secondary to the increased vascularity of this neoplasm.[447] Microscopically, KS may present as a subtle capsular infiltration of lymph node that frequently accompanies a pattern of follicular hyperplasia or lymphocyte depletion. Such histologic features may be difficult to distinguish from an inflamed "cellular" capsule due to other causes. Features that are helpful in identification of KS may include: presence of a definable mass lesion displacing normal nodal architecture, thickening of the capsule with infiltration of underlying subcapsular sinuses, presence of numerous plump spindle cells of uniform size bridging lymphatics and vascular spaces, appearance of a concomitant plasmacellular response, and positive immunohistochemical staining for endothelium-associated CD34 antigen or factor VIII-related antigen within the spindle to ovoid cells.

**MALIGNANT LYMPHOMAS.**-- Involvement of lymph nodes by non-Hodgkin lymphoma in the setting of HIV infection is less frequent than for either central nervous system or gastrointestinal tract. Lymph nodes may be secondarily involved with widespread systemic disease, with recurrence, or with progression of disease. AIDS-related non-Hodgkin lymphomas are of B-cell origin and fall into two broad categories: (1) intermediate grade, classified as small noncleaved-cell (SNCLL) lymphomas (Burkitt or Burkitt-like lymphomas) in working

formulation classification (Burkitt lymphoma with or without plasmablastic differentiation in Kiel classification), or (2) high grade diffuse large cell (DLCL) lymphomas, either large cell immunoblastic lymphomas in working formulation classification (immunoblastic with or without plasmacytic differentiation in Kiel classification) or large noncleaved-cell lymphomas in working formulation classification (centroblastic diffuse in Kiel classification).[601]

Gross pathologic findings include one or more enlarged lymph nodes that are firm and tan-white. Necrosis may be prominent with immunoblastic sarcoma. Sometimes only focal lymphoma may be seen in lymph nodes. Occasionally, Kaposi sarcoma and/or opportunistic infections, particularly *Mycobacterium avium*-complex (*M avium-intracellulare*), may occur simultaneously with malignant lymphoma in the same lymph node. Demonstration of monoclonality by immunohistochemical methods may aid recognition of lymphoma.[601]

Other lymphoid malignancies can occur in patients with AIDS, but are not part of the definitional criteria for AIDS. They are seen with much less frequency. Hodgkin lymphoma (HL) is more frequent in the general population than high-grade non-Hodgkin lymphomas in the age range (third to fifth decades) of higher prevalence of AIDS. However, HL is seen less frequently than high-grade lymphomas in patients with AIDS. HL that occurs in patients with AIDS more often demonstrates a high stage (III or IV), a propensity for extranodal involvement, an increased frequency of depleted and sarcomatoid morphologic features, and more often a mixed cellularity histologic type with fibrohistiocytoid stromal cells. The immunophenotype of HL in HIV infection is similar to that in persons without HIV infection.[608,610] Small cell lymphomas of follicular type appear in AIDS similar to those seen in individuals without HIV infection.

**MULTICENTRIC CASTLEMAN DISEASE (MCD).**-- MCD is a lymphoproliferative disorder associated with inflammatory symptoms such as fever and interleukin 6 (IL-6) dysregulation. The incidence increases with age. MCD is characterized by lymphadenopathy and microscopic findings of angiofollicular hyperplasia and plasma cell infiltration. The appearance of MCD in persons infected with HIV is associated with the human herpesvirus 8 (HHV-8) that is also associated with lesions of Kaposi sarcoma (KS). Patients with MCD may subsequently develop other HHV8-associated lesions including non-Hodgkin lymphoma and primary effusion lymphoma. Most patients will have a polyclonal gammopathy. The prognosis is poor, with median survival of 48 months from the time of diagnosis and a 15-fold increased risk for development of non-Hodgkin lymphoma.[902,908] With CT imaging, there is hepatosplenomegaly mediastinal or peripheral lymphadenopathy, and pulmonary bronchovascular nodularity.[909]

Of the two main pathologic types of MCD, hyaline-vascular and plasma cell variants, the latter is more frequently seen in association with HIV infection. The hyaline vascular type of MCD shows small hyalinized germinal centers surrounded by concentric layers of small lymphocytes, interfollicular vascular hyperplasia, hyalinized vessels, and stromal cell proliferations. The plasma cell type of MCD has hyperplastic, poorly defined lymphoid follicles with large, active germinal centers surrounded by a narrow mantle of small lymphocytes. The interfollicular areas are expanded by sheets of plasma cells, but may contain hyalinized vessels. There are increased numbers of medium-sized to large plasmablasts, resembling immunoblasts, that contain a moderate amount of amphophilic cytoplasm and a large vesicular nucleus with 1–2 prominent nucleoli. Plasmablasts can comprise up to 50% of the follicular mantle zone in some follicles, may colonize germinal centers, and may coalesce into microlymphomas.[910]

## SPLEEN IN AIDS

Splenomegaly is a common clinical finding in patients with AIDS, and it is present at autopsy in about one third of AIDS cases. Opportunistic infections or neoplasms are more likely to be present when the splenic weight is greater than 400 g. Weights of up to 1 kg can occur.[911] The most frequent splenic findings at autopsy are *M avium* complex (MAC), *M tuberculosis* (MTB), cryptococcosis, cytomegalovirus, Kaposi sarcoma, and malignant lymphomas (Table 5).

Gross pathologic lesions consist of a prominent follicular pattern in about half of AIDS cases and a miliary granulomatous pattern in about 10%.[911] Sepsis may lead to a soft, almost liquid splenic parenchyma. Splenic infarcts may occur with embolization from non-bacterial thrombotic endocarditis or infectious endocarditis involving mitral or aortic valves.

**OPPORTUNISTIC INFECTIONS.**-- Either MAC or MTB can be associated with the appearance of granulomas. *Mycobacterium avium* complex is more likely to produce a myriad of small 0.1 to 0.5 cm soft tan miliary granulomas, while MTB often presents with fewer scattered and variably sized granulomas that are tan to white and firm. Microscopically, MAC granulomas are predominantly composed of macrophages filled with numerous mycobacteria. *Mycobacterium tuberculosis* produces a more typical histopathologic appearance with necrosis, epithelioid cells, lymphocytes, occasional Langhans' giant cells, and scattered mycobacteria.

Cytomegalovirus and *Candida* are infrequent and difficult to diagnose in spleen. They may be found within small foci of inflammation or necrosis that are not grossly evident and seen microscopically only with careful searching at high magnification, aided by methenamine silver or PAS stains.

The dimorphic fungi *C neoformans*, *H capsulatum*, and *C immitis* may also produce visible granulomas but they are never as numerous as the granulomas seen in mycobacterial infections. The fungal organisms are usually distributed throughout the red pulp and are often accompanied by proliferations of macrophages. Diagnosis is facilitated by use of methenamine silver or PAS stains.

Disseminated *P jiroveci* infection may involve the spleen. By computed tomographic scan, multiple nonenhancing, low-density masses with necrosis, hemorrhage, or peripheral calcification may be seen. Grossly, these are large, soft, friable, tan nodules, which can have focal hemorrhage. The same foamy pink exudate seen in pulmonary alveoli is seen microscopically, but Gomori methenamine silver staining will demonstrate the cysts, though immunoperoxidase staining with monoclonal antibody to *P jiroveci* can be helpful when cysts are not readily identified.[447]

**NEOPLASMS.**-- AIDS-associated neoplasms involve the spleen less frequently than lymph nodes. Kaposi sarcoma can be difficult to diagnose in the spleen because both grossly and microscopically, KS can resemble splenic red pulp, and a mass lesion may not be apparent. Spindle cells with atypia in a definable nodule or subcapsular infiltrate help to distinguish KS. Malignant lymphomas occur in the spleen only one fifth of the time when they are present and appear either as nodular masses in regions of white pulp or as infiltrates in red or white pulp. The monomorphous nature of lymphomatous infiltrates with large cells is a helpful feature. Immunohistochemical staining may be necessary to confirm the diagnosis.

**IDIOPATHIC THROMBOCYTOPENIC PURPURA.--** There is an increased incidence of idiopathic thrombocytopenic purpura (ITP) in patients with HIV infection. The appearance of ITP may precede development of clinical AIDS. Deposition of circulating immune complexes and complement on platelets and/or circulating anti-platelet antibody are thought to be mechanisms for HIV-associated ITP. In cases of refractory ITP, splenectomy has shown to be of benefit but with initially higher relapse rates than in persons without HIV infection.[912]

**HISTOLOGIC PATTERNS.--** A variety of histopathologic patterns of red and white pulp may appear in AIDS. There may be severe lymphocyte depletion with minimal or absent white pulp, while in other cases macrophages in small groups or clusters (granulomas) may predominate. In both of these patterns, opportunistic infections or neoplasms are more likely to be present. However, when plasma cells and immunoblasts are prominent in red and/or white pulp, infections are not common. Overall, about 40% of AIDS cases have some opportunistic infection or neoplasm involving the spleen.[911]

In a majority of persons with AIDS, splenic hemosiderin deposition in red pulp is quite prominent. Iron stains will aid in visualizing these deposits. Examination of sections by polarized light may reveal crystalline birefringent material associated with injection drug use. Sometimes large foamy macrophages or multinucleated cells are found without identifiable infectious agents.

**PEDIATRIC FINDINGS.--** At autopsy, young children and infants with HIV infection, most of who died from AIDS, may show a variety of histologic changes in the spleen. These can include marked lymphocyte depletion of white pulp and hemophagocytosis. In addition, about half of cases may demonstrate so-called “kaposiform” lesions composed of foci with spindle cells admixed with plasma cells, capillaries and hemosiderin-laden macrophages. Such foci bear a resemblance to Kaposi sarcoma with marked inflammation.[905] Splenic smooth muscle tumors, including leiomyomas and leiomyosarcomas, can appear in association with childhood AIDS and in association with Epstein-Barr virus infection.[630]

## BONE MARROW AND PERIPHERAL BLOOD IN AIDS

**PERIPHERAL BLOOD.**-- Cytopenias are commonly seen in association with HIV infection. Anemia, thrombocytopenia, neutropenia, lymphocytopenia, monocytopenia, or combinations of any or all of these can occur in over 90% of patients with AIDS. The microenvironment of the marrow may also be altered by HIV infection of stromal cells including fibroblasts, endothelial cells, reticular cells, macrophages, osteoclasts, and adipocytes, resulting in dysregulation of hematopoietic cell growth with reduced hematopoiesis.[913]

Anemia is present in over half of patients early in the course of AIDS and in nearly all AIDS patients late in the course. The anemia is often normochromic and normocytic, typical of anemia of chronic disease, and iron stores are increased by measurement of serum ferritin. Though CD34+ stem cells poorly express CD4 receptors and, hence, they are relatively resistant to HIV infection, mononuclear cells are infected and produce cytokines such as TGF- $\beta$ , TNF- $\alpha$ , and IL-1 that suppress hematopoiesis. Cytopenias can be potentiated by drug therapy including zidovudine (ZDV), ganciclovir, amphotericin B, or trimethoprim-sulfamethoxazole and may require dose reduction or cessation of therapy. A positive direct antiglobulin test may be present in a third of HIV-infected persons and is associated with anemia, particularly with more advanced HIV infection, but marked hemolysis anemia is uncommon.[914,915]

Chronic B19 parvovirus infection may produce red cell aplasia or chronic anemia in up to 25% of HIV-infected persons, though it may not be severe in others. Diagnosis of parvovirus infection can be made serologically. In bone marrow biopsies, there may be overall hypercellularity and the presence of giant multinucleated erythroblasts and giant pronormoblasts with finely granulated cytoplasm and glassy, variably eosinophilic, intranuclear inclusions with a clear central halo (so-called lantern cells). Giant early erythroid cells are seen on Wright-Giemsa stain. Pronormoblasts show prominent intranuclear viral inclusions, which are eosinophilic and compress the chromatin against the nuclear membrane. Severe anemia from parvovirus B19 infection is treatable with intravenous immunoglobulin therapy. [916]

An iron deficiency type of anemia may prompt testing for occult blood in stool, the presence of which may suggest Kaposi sarcoma or malignant lymphoma as a likely cause. Cytomegalovirus and fungal lesions produce gastrointestinal bleeding less often. Macrocytic anemias in AIDS are usually the result of chronic liver disease associated with chronic alcoholism or hepatitis, particularly when injection drug use is a risk factor, but they may also result occasionally from use of drugs that act as folate antagonists (trimethoprim-sulfamethoxazole).

Thrombocytopenia was seen in up to 23% of HIV-infected persons prior to widespread use of antiretroviral drugs, but the prevalence decreases with antiretroviral therapy. However, thrombocytopenia increases with decreasing CD4 lymphocyte counts. The reduction in platelets is rarely severe enough to cause spontaneous hemorrhage. It may be primarily as a result of HIV effects upon the marrow or secondary to peripheral consumption (splenomegaly, immune complexes, drug effects). Though marrow hematopoietic stem cells express receptor CD4 and coreceptors CXCR4 or CCR5, they do not appear to become productively infected with HIV. Hence, thrombocytopenia with HIV infection is likely due to secondary, peripheral causes.[917]

Thrombocytopenia may appear in some HIV-infected persons prior to development of clinical AIDS. In some cases, the presentation is indistinguishable from classic idiopathic



thrombocytopenic purpura (ITP) with increased megakaryocytes in the bone marrow along with peripheral platelet destruction. Unlike classic ITP, however, men are more often affected, and the antibodies are primarily directed against platelet glycoprotein IIIa (GPIIIa). There are also increased numbers of CD5+ B lymphocytes producing IgM rheumatoid factor and anti-GPIIIa.[225,913] Drugs induced myelosuppression with thrombocytopenia most often occurs with antiretroviral drugs zidovudine and stavudine, but can complicate antibiotics including acyclovir, amphotericin B, and trimethoprim-sulfamethoxazole. A myelophthitic process with suppression of hematopoiesis can accompany widespread infections such as fungal and mycobacterial diseases, as well as malignancies including lymphomas.[917]

Thrombotic microangiopathies (TMA), including hemolytic-uremic syndrome (HUS) and thrombotic thrombocytopenic purpura (TTP), have been reported in persons with HIV infection. The incidence appears to have decreased in the era of antiretroviral therapy. Thrombotic microangiopathy is more likely to occur in persons who have lower CD4 lymphocyte counts and who have other AIDS-related illnesses. At least four of the five classic findings (thrombocytopenia, microangiopathic hemolytic anemia, neurologic changes, renal manifestations, and fever) are present in most cases. Neurologic problems, including seizures, and hemorrhagic complications are likely to be seen. The blood lactate dehydrogenase (LDH) is elevated, as is serum creatinine. Proteinuria is common. A Shiga-like toxin producing *Escherichia coli* may be found. Therapy with plasmapheresis is less likely to be successful with TTP in HIV infection than with sporadic cases in non-HIV-infected persons.[918]

The pathologic findings in acute TMA lesions include occlusive thrombi in glomeruli and small arteries and arterioles, detachment of glomerular endothelium from the basement membrane, mesangiolysis, and widening of the glomerular subendothelial space widening. In chronic TMA there is reduplication of glomerular capillary basement membranes from new basement membrane synthesis and/or “splitting” of capillary walls. There can be segmental sclerosis, tubular atrophy, and interstitial fibrosis. Arterioles and arteries may show onionskin intimal reduplication. Microvascular thrombi can be highlighted with trichrome stain. In severe vascular lesions cortical necrosis may occur.[918]

Etiologies for TMA in HIV infection appear heterogeneous, with some cases having markedly reduced levels of ADAMTS13, with or without detectable inhibitor, while normal levels were present in others. Direct viral or cytokine-mediated endothelial cell injury may play a role in the pathogenesis of HIV-related TMA.[919]

Lymphopenia is present in about a third of AIDS cases due to the decrease in T4 lymphocytes. Neutropenia can be common in patients with AIDS and is a risk factor for both bacterial and fungal infections. The most common cause for neutropenia is drug therapy, and the drugs most often implicated are the antiretroviral agent zidovudine, the antibiotic combination of trimethoprim-sulfamethoxazole, and the antiviral agent ganciclovir. Additional causes may include chemotherapy for AIDS-related neoplasia and non-Hodgkin lymphomas. Neutrophilia may indicate bacterial sepsis. Bone marrow failure leading to death in patients with AIDS is very uncommon.[536,913,914,920]

Neutropenia that accompanies HIV infection can increase the risk for infection or worsen the course of infection. Neutropenia can result from involvement of bone marrow by opportunistic infections, from pharmacologic therapies such as trimethoprim-sulfamethoxazole, and from direct effects of HIV through accelerated apoptosis. Both chemotaxis and phagocytic functions of neutrophils also appear to be impaired. The use of granulocyte colony stimulating factor (G-CSF) may aid in increasing neutrophil counts and preventing bacterial infections.[921]

Thromboembolic disease and deep venous thrombosis more frequent with AIDS, particularly in persons 21 to 50 years of age. Predisposing factors include opportunistic infections such as cytomegalovirus and AIDS-associated neoplasms. Antiretroviral therapy, particularly regimens including protease inhibitors such as indinavir, may increase the risk for pulmonary venous thromboembolism. A hypercoagulable state may be associated with HIV infection, including acquired protein C and protein S deficiencies, heparin cofactor II deficiency, and antithrombin deficiency. Endothelial cell dysfunction and platelet aggregation with elevated levels of Von Willebrand Factor and P-selectin can be found in HIV infection. Autoimmune phenomena such as antiphospholipid syndrome may be implicated. The risk is increased for persons taking megestrol acetate. Thrombosis is more likely to occur with clinical AIDS when the CD4 count is less than 200/ $\mu$ L.[922,923]

**BONE MARROW.**-- A bone marrow biopsy in an HIV-infected patient is most useful when there is a history of persistent fever along with cytopenia, and no localizing signs are present. Marrow biopsy can be useful in the workup of lymphoma. Morphologic examination should be combined with microbiologic culture for suspected pathogens.[924] Mycobacterial infections (both MAC and MTB) are the most frequently identified opportunistic infections of bone marrow with AIDS, followed by *C neoformans*. However, the less frequently seen dimorphic fungi *H capsulatum* and *C immitis*, commonly involve bone marrow in cases in which they are present. Other opportunistic agents are quite rare at this site (Table 5). Culture of bone marrow can be useful for diagnosis of both mycobacterial and fungal infections.[456]

It is uncommon for grossly visible lesions to appear in bone marrow with any opportunistic infections or neoplasms. Severe pancytopenia may be accompanied by a generalized pale appearance.

Microscopically, a variety of non-specific morphologic abnormalities can occur within the marrow in HIV infection. There may be overall hypercellularity early in the course of AIDS, or with systemic infections, and this is seen in about half to three fourths of cases. This is most often due to hyperplasia of granulocytic or megakaryocytic cell lines. Debilitation leads to increasing hypocellularity and serous atrophy of fat later in the course of AIDS. Additional non-specific microscopic findings may include immature or dysplastic myeloid precursors (dysmyelopoietic), lymphoid aggregates, atypical megakaryocytes, a fine reticulin fibrosis, mild vascular proliferation, histiocytosis with or without non-specific granuloma formation, and increased hemosiderin deposition.[925,926]

A consistent finding is increased plasma cell cuffing of blood vessels, which may be accompanied by polyclonal hypergammaglobulinemia in over 80% of patients. The presence of giant pronormoblasts with inclusion-like nucleoli suggests parvovirus infection. Megaloblastic features often accompany zidovudine therapy or therapy with folate antagonists. HIV can also be demonstrated in a variety of marrow cells by *in situ* hybridization.[913,916]

Granulomas are infrequently present in bone marrow and may contain fungi, acid-fast organisms, occasional parasites, or polarizable talc crystals from injection drug use. These granulomas are typically not well formed. Localized ill-defined granulomas consisting of collections of macrophages were more frequent than were granulomas containing organisms. Of the dimorphic fungi, *C neoformans* is seen most frequently. *H capsulatum*, next in frequency may produce loose lymphohistiocytic aggregates. Of the mycobacteria, *Mycobacterium avium* complex (MAC) is seen more frequently than *M tuberculosis*. [925] The most sensitive method for detection of MAC remains blood culture. Culture of bone marrow aspirates will be positive

in about half of cases of disseminated MAC. Acid fast staining of marrow biopsies is positive in about a third of cases, but is the most rapid method of detection.[927]

A hemophagocytic syndrome has been described in association with HIV infection. A malignancy is the underlying etiology in over half of cases, and an opportunistic infection in over 40% of cases. Fever, splenomegaly, hepatomegaly, lymphadenopathy, peripheral blood cytopenias, hypertriglyceridemia, hypofibrinogenemia, and hyperferritinemia are common findings. Diagnosis is made on bone marrow biopsy.[928]

Toxoplasmosis involving marrow may be subtle. Features can include interstitial edema, focal necrosis, and only a few scattered macrophages or clusters of macrophages. The tachyzoites and pseudocysts are found in or around areas of necrosis. Organisms may be found not only in macrophages but also in granulocytes and megakaryocytes.[929]

Parvovirus B19 infection may not always be detected by finding the presence of intranuclear pink inclusions within erythropoietic precursors. By the *in situ* hybridization technique, parvovirus may be detected in less than 10% of marrows in patients with AIDS. Infection is typically detectable late in the course of AIDS. Few infected patients have severe anemia.[916]

*Penicillium marneffei* infection may involve bone marrow. One study from Southeast Asia, where this infection is endemic, showed marrow involvement in 10% of patients with *P marneffei*. On bone marrow smears with Wright-Giemsa stain, the 1-2 um organisms with 1-2 um darkly staining nuclei were seen to be engulfed by phagocytes. Chromatin density was low to medium; cytoplasm was light blue and non-uniformly stained.[930]

NEOPLASMS INVOLVING BONE MARROW.-- Non-Hodgkin lymphomas (NHLs) may be found in the bone marrow in about one fourth of cases in which they are diagnosed at autopsy. Bone marrow biopsy is of value in staging of these lymphomas.[924] The small noncleaved Burkitt or Burkitt-like lymphomas are more likely to involve marrow than those of a diffuse large cell variety. Low-grade lymphomas are seen far less frequently and are not part of definitional criteria for AIDS. Non-Hodgkin lymphomas that involve some other site in persons with AIDS are seen in the marrow in 25% of cases. Patients with bone marrow involvement with NHL are more likely to have meningeal involvement. Patients with marrow involvement are more likely to have high lactate dehydrogenase levels, fever, night sweats, and/or weight loss, and such patients tend to have shorter survival. Survival is decreased with >50% marrow involvement.[931]

Many AIDS cases occur in patients in the same peak age group range in which myelogenous leukemias and Hodgkin lymphoma may be seen, but these entities not diagnostic for AIDS. Low-grade lymphomas must be distinguished from the benign reactive lymphoid aggregates found in about one third of HIV-infected patients. Such benign aggregates are usually not in a peritrabecular location, however. A plasmacytosis may be present in AIDS patients or in HIV-infected patients prior to development of clinical AIDS, but the proliferation is polyclonal, as demonstrated by immunohistochemical staining with antibody to lambda and kappa immunoglobulin light chains. Hodgkin lymphoma associated with HIV infection has a propensity for bone marrow involvement.[601]

Kaposi sarcoma is very rarely seen in bone marrow, and when it does occur in marrow, is widely disseminated.[932]

Multicentric Castleman disease (MCD) involving bone marrow is characterized by the appearance of small lymphoid follicles with depleted germinal centers and a surrounding mantle

zone containing plasmablasts containing human herpesvirus-8 (HHV-8) by immunohistochemistry. Surrounding sinusoids contain increased plasma cells. Patients often have pancytopenia.[933]

## THYMUS IN AIDS

The thymus may play a role in evolution of immunologic consequences of HIV infection. Though the thymic production of naïve CD4 and CD8 lymphocytes decreases with age, functional thymic tissue is still present in adults. Thymopoiesis is ongoing in adults. The thymus is the source of effector memory T cells that migrate to sites of inflammation as well as central memory T cells that find a home in lymphoid tissues and have the capability to differentiate into effector cells upon specific antigen stimulation.[934]

In HIV infection the depletion of CD4 effector memory cells requires continued replacement. HIV infection compromises thymopoiesis for replacement by destroying developing CD4 thymocytes, by affecting thymic stromal cells to inhibit maturation, and by impairing CD34 stem cell function in marrow to reduce the inflow of stem cells for thymopoiesis. Thus, compared with age-comparable persons, HIV-infected persons have reduced thymocyte maturation and reduced CD4 cell diversity.[934]

Antiretroviral therapy has been shown to partially restore thymocyte populations and diversity. This contributes to the immune reconstitution observed among persons receiving antiretroviral therapy. The size of the thymus is larger in persons receiving such therapy, and larger thymic size correlates with higher CD4 lymphocyte counts. Despite antiretroviral therapy, there is persistence in dysregulation of regulatory T cells (Tregs) that lead to tolerance and suppress immune responses. Tregs persist at higher levels following HIV infection. Thus, recovery of immune function following antiretroviral therapy may depend upon thymic activity with production of new CD4 cells.[934]

The CD4 lymphocytes in the thymus are preferentially targeted by CXCR4-tropic strains of HIV. At least initially, HIV-1-induced immune activation leads to a higher rate of differentiation of naïve lymphocytes into the effector/memory pool. An increase in thymic activity seems to be part of the process that maintains peripheral CD4 cells during the latent, asymptomatic phase of HIV infection.[935]

The thymus is not a significant site of pathologic lesions in adult AIDS patients. Thymic tissue in adults is not grossly prominent or microscopically cellular under normal circumstances, and is no different in patients with AIDS. Opportunistic infections are rare. Even malignant lymphomas, typically widespread in AIDS, do not involve the thymus.[936]

In adults infected with HIV-1, a B-lymphocytic follicular hyperplasia can be identified in thymic lymphoid tissue. The germinal centers are infiltrated by plasma cells. This hyperplasia is similar to that found in lymph nodes in the same HIV-infected person. Small numbers of lymphocytes can be shown to contain HIV-1 RNA, consistent with the role of the lymphoid tissue as a reservoir for HIV during the latent stage of infection.[937]

In pediatric AIDS, specific thymic pathology has been observed to consist of precocious involution, involution mimicking thymic dysplasia of congenital immune deficiency and/or thymitis. HIV may produce the lesions by injury to thymic epithelial cells. Severe, early thymic injury may be irreversible and further diminish cell-mediated immunity in infected children.[938]

Findings in the thymus at autopsy in pediatric patients with HIV infection, most of whom died from AIDS, may include severe lymphoid depletion with atrophy, microcystic transformation of Hassall's corpuscles, calcification of Hassall's corpuscles, plasma cell infiltrates, and Warthin-Finkeldey type giant cells.

Some pediatric patients may develop multilocular thymic cysts. These lesions are typically discovered incidentally by a routine chest radiograph that demonstrate an anterior mediastinal mass with cystic or soft tissue attenuation on CT imaging and high signal intensity with T2 weighted MR imaging. Septations with multiloculation are present. The children have no symptoms related to these masses. By computed tomographic scan, the mass can appear multicystic. Histologic findings include distortion of thymic architecture with focal cystic changes, follicular hyperplasia, diffuse plasmacytosis, and the presence of multinucleated giant cells. The irregular cystic spaces are lined by a keratin positive flattened epithelium. They can resemble lymphoepithelial cysts of the parotid gland. No malignant changes occur. The presence of Epstein-Barr virus can be demonstrated in lymphoid tissue in some cases. In over half of cases, the mass decreases in size or resolves completely over time.[939,940]

## ENDOCRINE ORGAN PATHOLOGY IN AIDS

Most opportunistic infections and neoplasms affecting the endocrine system in patients with AIDS occur when those diseases are widely disseminated. The most common endocrine organ affected is the adrenal gland (Table 5). A variety of endocrine disorders can be identified in patients with HIV infection and AIDS.[841,941,942]

**ADRENAL.**—Clinically apparent adrenal failure may require destruction of more than 80% of the parenchyma from pathologic processes seen with AIDS. However, frank adrenal insufficiency is uncommon, and serum cortisol is usually not markedly reduced during the course of HIV infection. Overt adrenal failure occurs in about 5% of AIDS cases, typically at a late stage of disease. Anti-adrenal antibodies may be found in 45% of HIV-infected persons, most likely from polyclonal B-lymphocyte activation, but generally cause no major adrenal problems. Most HIV-infected persons have normal to elevated basal cortisol levels, probably from the stress of the complications of this illness, but reduced cortisol levels may also occur. HIV infection of macrophages can increase IL-1 and TNF secretion, and both these cytokines can stimulate the adrenal. HIV infection of the brain can involve the median eminence, where IL-1 production may stimulate corticotrophin releasing hormone leading to increased ACTH release from the pituitary. The gp120 glycoprotein of HIV can increase hypothalamic production of corticotrophin releasing hormone.[942,943]

Maximum cortisol levels and the rise of serum cortisol appear to be diminished with HIV infection. Reduction in peak cortisol levels may affect 30% of AIDS patients. Evidence of some degree of adrenal failure with decreased cortisol and electrolyte alterations, such as hyponatremia, occurs in a majority of patients dying with AIDS. Hyporeninemic hypoaldosteronism of unknown cause has occasionally been observed to account for persistent hyperkalemia in AIDS.[841,941]

Drug-induced abnormalities can occur. The antifungal agent ketoconazole can be responsible for a reversible decrease in cortisol and aldosterone production, but it is rarely the cause for adrenal insufficiency. Rifampin therapy in patients with *Mycobacterium tuberculosis* infection has rarely been reported to cause adrenal crisis.[941,943]

Grossly, lesions of the adrenal are difficult to detect. Marked adrenal enlargement from any opportunistic infection is not common. Malignant lymphomas can on occasion cause unilateral or bilateral enlargement with white-tan to red variegated masses or infiltrates. Kaposi sarcoma may infiltrate the periadrenal fat or the substance of the gland in a linear dark-red to purple pattern. Cytomegalovirus may produce a multifocal reddish mottling within the yellow cortex. Adrenal glands may become enlarged because of stress in AIDS, though the total weight of both glands rarely exceeds 20 g.

Cytomegalovirus is the most common endocrine manifestation of AIDS at autopsy, occurring about three fourths of the time when CMV infection is present at autopsy. Identification of CMV within the adrenal glands may help to establish the diagnosis of AIDS, since adrenal may sometimes be the only tissue involved with this opportunistic agent. Cytomegalovirus may affect either the medulla or the cortex, or both. The medulla is more likely to be involved initially, with the cortex involved in a longer course or with more extensive infection. Hyponatremia with hypoglycemia may suggest adrenal insufficiency from involvement by cytomegalovirus.[450]

Microscopic changes found with CMV infection of adrenals vary from virtually no tissue reaction, through isolated clusters of small lymphocytes or focal hemorrhages, to extensive necrosis with polymorphonuclear infiltrates, to extensive fibrosis of cortex or medulla. These lesions may be accompanied by central venous thrombosis. The most common manifestation of CMV infection is clusters of small lymphocytes. These lymphocytes do not form reactive follicles. Small hemorrhages may also be present along with isolated small areas of necrosis. Whenever any of these changes are present, a careful search for CMV should be made. The greater the degree of necrosis, inflammation, or fibrosis, the more likely electrolyte or hormonal abnormalities will become apparent clinically.[450,943]

The CMV inclusions in adrenal are similar to those elsewhere, with large violaceous, dark red, or mauve intranuclear inclusion bodies surrounded by a clear halo beneath the thin nuclear membrane. An extensive amount of basophilic finely reticulated cytoplasm (basophilic inclusions) may draw attention to the CMV cell at low or medium power magnification. Cells with characteristic basophilic stippling are rare. The inclusions are larger than the nucleoli of medullary ganglion cells.

Adrenal involvement with other opportunistic infections and neoplasms usually occurs with widespread dissemination and is only diagnosed at autopsy. Malignant lymphomas are seen at autopsy in adrenal in one third of cases, followed by *Cryptococcus neoformans* infection in one fourth, and *Mycobacterium tuberculosis* in one fifth. *Mycobacterium avium*-complex, usually more common than *M tuberculosis* in high-income countries, is seen less frequently in adrenal (Table 5). In many cases the adrenal is only involved through superficial capsular infiltration from periadrenal deposits of these agents or tumors. Thus, adrenal enlargement with these diseases is uncommon.[943]

Despite the presence of adrenal CMV in over a third of all AIDS patients at autopsy, despite involvement of the adrenal with mycobacterial or fungal infections that microscopically are associated with necrosis and inflammation, and despite frequent clinical evidence for adrenal dysfunction, adrenal failure leading to demise is rare. Adrenal insufficiency accounts for less than 2% of all deaths in AIDS.[450]

**THYROID AND PARATHYROID.**—A clinical appearance similar to "sick euthyroid" state in debilitated and/or hospitalized AIDS patients is common. This condition is characterized by decreased triiodothyronine levels secondary to diminished peripheral conversion of thyroxine. Patients with advancing HIV infection are noted to have elevated concentrations of thyroid binding globulin and a progressive decline in reverse triiodothyronine concentration. Hypocalcemia has been observed as a complication of pentamidine isethionate therapy. Therapy with foscarnet may also reduce serum calcium.[941,942]

Patients receiving antiretroviral therapy may have subclinical hypothyroidism with laboratory findings of increased TSH and low thyroxine. The serum total thyroxine (T4) and triiodothyronine (T3) concentrations may be increased because of an increase in thyroxine-binding globulin, the cause of which is unknown. Late in the course of AIDS, the T4 and T3 may fall slightly. Conversely, some patients on antiretroviral therapy with immune restoration may have laboratory evidence of Graves disease.[942,944]

Thyroid and parathyroid glands are rarely the site of involvement for any opportunistic infections or neoplasms diagnostic for AIDS (Table 5). Occasional CMV inclusions may be found at these sites when there is widely disseminated CMV. The same is true for *Pneumocystis jiroveci* (*carinii*) and pathogenic fungi. However, significant organ enlargement, atrophy, or



failure does not usually ensue, probably because of the focal nature of involvement and because widespread involvement of a more critical organ--such as lung or brain--causes demise of the patient first.[941]

The whole blood calcium tends to be lower in patients with HIV infection, and both basal and maximal secretion of parathyroid hormone is reduced in patients with AIDS.[945] Hypocalcemia can occur with use of drugs including pentamidine, foscarnet, and ketoconazole. Hypercalcemia may be related to underlying malignancies, granulomatous disease with dysregulated extrarenal calcitriol production, opportunistic infection with CMV or *Pneumocystis*, and concomitant HTLV-1 infection.[941]

**PITUITARY.**-- The pituitary gland is affected only infrequently by opportunistic infections, usually CMV. Lymphomas and Kaposi sarcoma are not seen involving the pituitary with HIV infection. Microscopic microadenomas or areas of basophilic hyperplasia within adenohypophysis are seen in up to 10% of AIDS cases at autopsy, though their significance is not known.[946] Pituitary lesions in AIDS are generally focal and typically not large enough to decrease pituitary function.

Clinically, hyponatremia is often seen in hospitalized patients with AIDS. In some cases this results from volume depletion, but in others it is caused by a syndrome of inappropriate antidiuretic hormone (SIADH) secretion. In most cases, SIADH can be attributed to opportunistic infections involving lung and brain. The drug vidarabine used to treat patients with disseminated varicella zoster virus infections may also cause SIADH.[941]

Growth failure and failure to thrive may occur in HIV-infected children. Levels of insulin-like growth factor 1 (IGF1) and IGF binding protein 3 (IGFBP3) are decreased. Growth hormone (GH) deficiency inhibits thymic development. Adults with HIV wasting syndrome there is GH resistance with an increased level of GH, similar to patients with malnutrition. Adult patients with lipodystrophy had decreased GH along with increased somatostatin, decreased ghrelin, and increased free fatty acids.[942]

**PANCREATIC ISLET CELLS.**-- Persons on antiretroviral therapy can develop hyperinsulinemia, particularly in the context of lipodystrophy. Non-glucose secretagogues that drive insulin dysregulation include triglycerides, as well as apoptosis of adipose tissue. Insulin resistance occurs, both peripherally as well as at the beta cell level.[947]

## HEPATOBIILIARY SYSTEM PATHOLOGY IN AIDS

The liver is frequently involved by a variety of diseases in patients with AIDS. At autopsy, the liver is involved by opportunistic infections and neoplasms in about one third of AIDS cases but liver failure is an uncommon cause of death, occurring in less than 1% of AIDS cases. There may be a history of chronic liver disease from viral hepatitis, particularly in persons with a history of injection drug use. Chronic alcoholism may occur more often in persons with a history of injection drug use. If chronic liver disease is present, it is probably part of a process that preceded HIV infection, but the clinical course may be more aggressive than in the non-HIV-infected patient.[948,949,950,951]

HIV-1 has also been identified within Kupffer cells, hepatocytes, hepatic stellate cells, and sinusoidal endothelial cells in liver, but infection of these cells does not represent a major reservoir for HIV. HIV can induce hepatocyte apoptosis via gp120 signaling through CXCR4 in the absence of infection. Hepatocyte apoptosis can trigger pro-fibrotic activity of hepatic stellate cells activity.[950]

Moderately elevated aminotransferase levels are found in one half to three fourths of adults with AIDS, but such elevations do not necessarily correlate with significant pathologic findings, or they may be due to alcoholic liver disease or hepatitis. Both opportunistic infections and the pharmacotherapy for such infections may lead to transaminasemia. Alkaline phosphatase can be increased in half of AIDS cases, and the most common cause is hepatic granulomata. Jaundice is not common, appearing in the course of AIDS in about 10% of patients. Abnormal liver function tests are unusual in pediatric AIDS. Lactate dehydrogenase is often elevated, but this can occur with just about any opportunistic infection or neoplasm. Liver biopsy may yield diagnostic information, particularly when there is fever of unknown origin or the alkaline phosphatase is greatly increased, but the liver is only rarely the sole site of a significant opportunistic infection or neoplasm. Other tissue sites may be sampled prior to liver.[948,950,951]

In pediatric cases, granulomas are less frequent but giant cells more numerous, and lymphoplasmacytic infiltrates can be present in association with lymphocytic interstitial pneumonitis of lung. Focal fatty change is often present, sometimes with hepatocyte necrosis. Other frequent findings include portal chronic inflammation, portal fibrosis. Chronic active hepatitis is not seen. *M avium*-complex may produce a pseudosarcomatous reaction.[948,952]

**HEPATITIS B.**-- In Western Europe and the U.S., hepatitis B virus (HBV) infection has been found in 6 to 14% of the overall population, including 4 to 6% of heterosexuals, 9 to 17% of men who have sex with men, and 7 to 10% of injection drug users. [953] The prevalence was 19% in a South African cohort.[951] Vertical transmission is a function of the incidence of congenital HIV infection. Worldwide, about 90% of HIV-infected persons have evidence for past HBV infection, and 10% have evidence for chronic HBV infection. Persons who are coinfectd with HBV and HIV are less likely to clear the hepatitis virus than immunocompetent persons, leading to higher rates of chronic HBV infection, higher HBV DNA levels, and accelerated fibrosis progression to end-stage liver disease.[954]

Serum aminotransferase levels may be lower in patients with HIV and HBV coinfection. Progression to AIDS results in a decreased hepatitis B surface antibody titer and a greater likelihood of reactivation of latent infection or reinfection with another viral subtype. Evidence

for superinfection with delta agent (hepatitis D virus, or HDV) occurs in 25% of HIV-infected persons with HBV, and liver injury is worsened, with greater viral replication of both HBV and HDV. Persons with HIV infection should be vaccinated against HBV, but they also respond poorly to hepatitis B immunizations, and more poorly with lower CD4 cells counts, with lower antibody titers, and frequently lose this antibody protection.[948,955]

Treatment of HBV with HIV is considered when hepatitis B e antigen (HBeAg) is present, HBV–DNA is >20,000 IU/ml (>2000 if HBeAg negative). Since therapy is suppressive and not curative, treatment may continue indefinitely. Treatment is most likely to be successful when the serum HBV–DNA level is low, HBeAg is positive, and serum ALT is elevated. Drugs employed include interferon-alpha, lamivudine, adefovir, entecavir, telbivudine, emtricitabine, and tenofovir. Use of the antiretroviral agent tenofovir has been shown to be particularly effective in suppressing HBV replication in persons with HIV, with improvement indicated by tests of hepatic function. Such therapy has the potential to slow or reverse chronic liver disease in these patients. Resistance to nucleoside analogues may develop, and is inversely proportional to the degree of initial HBV suppression.[956]

**HEPATITIS C.**-- In Western Europe and the U.S., hepatitis C virus (HCV) infection has been found in 25-30% of HIV-positive persons overall, and by risk factor 72-95% of those who are injection drug users, 1-12% of men having sex with men, and 9-27% of heterosexuals.[953] In a South African cohort, 3% were infected with HCV.[951] Vertical transmission is a function of the incidence of congenital HIV infection. Recently infected persons tend to be asymptomatic, and disease progression occurs over years. Persons with HCV co-infected with HIV are less likely to clear HCV, and 80% go on to chronic disease. HIV co-infection is associated with increased HCV RNA levels, increased hepatic inflammation and fibrosis, and more rapid progression to cirrhosis and end-stage liver disease. The decreased number of CD4 lymphocytes, and a relative increase in CD8 cells, promotes fibrogenesis through activation of hepatic stellate cells. In addition, there is a greater prevalence of diabetes mellitus in these persons.[948,951,954,955]

Liver biopsy is required to determine the extent of liver disease. Transaminase levels may be in the normal range even when fibrosis is present. Genomic testing for detection of single nucleotide polymorphisms predicting virologic response is useful. Response rates to ribavirin therapy are lower than in immunocompetent persons. Treatment with pegylated interferon plus ribavirin results in a treatment response from 29% to 62% and a sustained HCV clearance of 17 to 53% in HIV–HCV co-infected patients.[954,956]

As survival increases with antiretroviral therapy for HIV, increasing numbers of cases of hepatocellular carcinoma occur in patients who have viral hepatitis, mainly hepatitis C. The course is more aggressive, with shorter survival, than in persons not infected with HIV.[957]

**HEPATITIS, NON B or C.**-- There is no significant effect of HIV infection upon the clinical course of hepatitis A virus (HAV) infection. However, the duration of hepatitis A viremia may be prolonged in persons infected with HIV, with a higher viral load of HAV. [958]

Hepatitis G virus (GBV-C) is not associated with a known disease. However, coinfection with GBV-C has been shown to be associated with reduced mortality in persons with HIV. The rate of HIV replication in vitro in peripheral blood mononuclear cells has been shown to be inhibited by GBV-C. Approximately 40% of HIV infected persons can have coinfection with GBV-C.[237]

**MYCOBACTERIA.**-- *Mycobacterium avium* complex (MAC) is the most frequent opportunistic infection involving the liver in high-income countries, found in slightly less than half of AIDS cases in which MAC is diagnosed. In low-income countries, *Mycobacterium tuberculosis* is the most common cause for hepatic granulomatous inflammation. Associated clinical findings include fever and weight loss. Transaminases may be two to three times normal. *Mycobacterium avium* complex infection results in moderate to marked hepatomegaly but rarely produces grossly visible lesions. Tiny echogenic foci may appear on ultrasonography of the liver, though occasional larger lesions may be hypoechoic by ultrasound or show low attenuation by computed tomography.[447]

The microscopic pattern of hepatic MAC involvement consists of small clusters of striated blue macrophages with hematoxylin-eosin staining (and numerous acid-fast bacilli) scattered throughout the parenchyma in a portal to midzonal distribution. Adjacent liver parenchyma appears normal. Obstruction does not occur. *Mycobacterium tuberculosis* may be seen in liver with dissemination and produces small tan to white granulomas that are unlikely to result in hepatomegaly. The microscopic appearance of these granulomas includes typical features of necrosis, epithelioid cells, lymphocytes, occasional Langhans giant cells, and scattered acid-fast bacilli. Tuberculosis immune reconstitution syndrome can exacerbate hepatic involvement.[950,949,959]

**FUNGAL INFECTIONS.**-- The fungi *C neoformans*, *H capsulatum*, and *C immitis* involve the liver frequently in disseminated infections, may be associated with mild abnormalities of liver function tests, but usually do not produce symptomatology from liver disease. Hepatosplenomegaly is common. These organisms do not often produce grossly conspicuous granulomas--discrete granulomas are present in less than 20% of involved livers with histoplasmosis. Cryptococcosis is the most frequently identified fungus in liver, seen in about one third of AIDS cases with *C neoformans* at autopsy (Table 5). These dimorphic fungi are most likely to have an infiltrative pattern of involvement with small numbers of organisms in portal areas. *H capsulatum* can be seen in clusters within macrophages. Accompanying inflammatory infiltrates and necrosis are usually not prominent; portal lymphohistiocytic infiltrates are the most common histologic finding.[717,949]

**CYTOMEGALOVIRUS.**-- Cytomegalovirus (CMV) can involve the liver in AIDS, usually in association with disseminated infections, and patients are rarely symptomatic just from hepatobiliary involvement. Alkaline phosphatase can be mildly elevated. A true CMV hepatitis is rare. Rarely, a granuloma or mass lesion can be produced. The characteristic inclusion bodies can appear in any cell in the liver, but they can be difficult to find.[949]

**TOXOPLASMOSIS.**-- *T gondii* are infrequently found and rarely produce a widespread infection in liver. The only evidence of their presence may be a rare cytomegalic cell or *T gondii* cyst found only after very careful searching at high power. A small focal collection of inflammatory cells may accompany them. In rare cases, hepatitis with extensive necrosis may occur.

**AMEBIASIS.**-- In parts of the world with endemic *Entamoeba histolytica* infections, there may be complications of amebiasis in patients with HIV infection. In one Taiwanese

study, half of cases of amebic liver abscess occurred in persons infected with HIV. In over half of these patients, the CD4 count was above 200/ $\mu$ L.[960]

**KAPOSI SARCOMA.**-- AIDS patients with KS have liver involvement only one fifth of the time (Table 5). The alkaline phosphatase is often elevated in these cases, because the Kaposi sarcoma is often distributed around large portal vein branches at the hilum, along the biliary tracts, near the capsule, or even in the gallbladder. Sometimes the deposits of KS resemble small hepatic hemangiomas that are usually solitary and occur in about 2% of all persons. Microscopically, KS may have dilated vascular spaces similar to hemangioma, but hemangiomas will not have atypical spindle cells. In rare cases the KS infiltration is extensive enough to produce biliary tract obstruction or liver failure. Liver biopsy may miss the predominantly central and focal lesions of KS.

**MALIGNANT LYMPHOMAS.**-- Non-Hodgkin lymphoma (NHL) may appear in liver in association with widespread dissemination and only rarely as a primary tumor. Persistent fever, tender hepatomegaly, mildly abnormal liver function tests and an elevated lactate dehydrogenase are typical clinical findings. By either ultrasound (US) or computed tomography (CT), NHL may produce solitary or, more often, variably-sized multiple lesions. A mass that is hypoechoic compared to surrounding hepatic parenchyma is a typical finding on US, while by CT there can be various patterns of enhancement after intravenous contrast material administration, including enhancement, a thin enhancing rim, or diffuse enhancement.[447] Lymphomatous infiltrates most often appear in portal zones, but if extensive can be found throughout the hepatic lobules. Large tumor masses are not common and may be identified by radiographic imaging procedures to direct biopsy for diagnosis. Lymphoma can be distinguished from nonspecific lymphocytic portal infiltrates by the larger monomorphous population of cells in the former, aided by immunohistochemical staining.[961]

**DRUG-INDUCED HEPATOTOXICITY.**-- It is not surprising that hepatotoxicity can appear in the course of AIDS because patients are treated with a variety of pharmacologic agents, and polypharmacy can contribute to liver injury. Histopathologic patterns of injury include nonspecific hepatitis, cholestasis, mixed hepatitis/cholestasis, submassive necrosis, and vanishing bile duct syndrome / ductopenia.[951]

The patterns of hepatotoxicity may include hypersensitivity, idiosyncratic reaction, mitochondrial injury, immune reconstitution inflammatory syndrome (IRIS), and steatosis. These findings overlap those of chronic viral hepatitis. Nucleoside and nonnucleoside reverse transcriptase inhibitors as well as protease inhibitors can have hepatotoxicity with elevations in liver enzymes. These findings usually appear within 2 to 3 months of starting antiretroviral therapy. Nevirapine and efavirenz are most often implicated, with nonspecific hepatitis in the former and submassive necrosis in the latter. In most cases liver enzyme elevations are low and the patients remain asymptomatic. Discontinuing the drug usually leads to complete resolution. Higher elevations may occur with concurrent hepatitis B or C infection.[282,951]

A hypersensitivity reaction is seen most often with the NRTI abacavir, with the NNRTIs nevirapine and efavirenz, and with the PI amprenavir. The hepatitis with nevirapine ranges from moderate to severe and require switching to another drug. There is typically an onset of fever, rash, and eosinophilia within a week of starting therapy.[282]

Mitochondrial toxicity leads to impairment of fatty acid oxidation and microvesicular steatosis, and lactic acidosis in more severe cases most often associated with use of didanosine or stavudine. There is mitochondrial hyperplasia with microscopic pleomorphism of the mitochondria.[282]

Hyperbilirubinemia is most likely to complicate therapy with protease inhibitors, particularly indinavir (25% of treated patients) and atazanavir. These agents may affect conjugation by the microsomal enzyme uridine diphosphate glucuronyltransferase, similar to Gilbert syndrome. The bilirubin elevation is mild (cosmetically unpleasing) and ranges from 2.5 to 5 mg/dL.[282]

The use of riboflavin may help to ameliorate lactic acidosis. Immune reconstitution with liver injury is most likely to occur when HBV or HCV infection is present. Drug-induced hepatotoxicity is more likely to occur when there is underlying hepatic fibrosis.[954,962]

Half of patients receiving prophylaxis for *Pneumocystis jiroveci* (*carinii*) with either trimethoprim-sulfamethoxazole (TMP-SMX) or pentamidine have elevations in transaminases or alkaline phosphatase that are two or more times normal, but severe hepatotoxicity is uncommon. Sulfa drugs can also cause a granulomatous hepatitis. Both ketoconazole and fluconazole used to treat fungal infections can be associated with transaminase elevations in 10 to 20% of cases. Agents used to treat *Mycobacterium tuberculosis*, such as isoniazid and rifampin, can produce enough abnormalities in liver function tests to alter the therapeutic regimen in 5% of cases. The antiretroviral agent didanosine (ddI) is associated with transaminase elevations in one third of treated patients.[949] Patients receiving cotrimoxazole are at increased risk for liver injury.[951]

The protease inhibitors, and ritonavir in particular may be associated with elevation in transaminases, while saquinavir and indinavir more often are causes for hyperbilirubinemia. The risk for hepatotoxicity occurs five times more often for ritonavir than for other protease inhibitors. The overall rate of hepatotoxicity with antiretroviral therapy is about 10%. The risk for hepatotoxicity appears to be increased in persons with hepatitis B or C infection, but 88% of persons with viral hepatitis B or C do not develop hepatotoxicity.[282,286]

**HEPATIC STEATOSIS.**-- A common clinical and pathologic finding in liver with AIDS is hepatomegaly, seen in about two thirds of cases. Steatosis (fatty metamorphosis) is a common histopathologic finding, seen in about one third of AIDS patients on biopsy or at autopsy, but it is often of a mild to moderate degree and periportal in distribution, and may result from chronic alcoholism. However, steatosis can occur with HIV infection in the absence of risk factors such as viral hepatitis, alcohol abuse, or diabetes mellitus. A suggestive laboratory marker is an elevated serum gamma-glutamyl transferase.[963] In a cohort of patients receiving a variety of medications, including antiretroviral therapy, steatosis was present in 72%.[951] Non-alcoholic fatty liver (NAFL) is increasingly common because of etiologies including diabetes mellitus, hepatitis B or C infection, and HIV associated lipodystrophy, or antiretroviral therapy with nucleoside analogues.[964] NAFL may progress to non-alcoholic steatosis (NASH) and to cirrhosis. Risk factors include male sex, elevated serum alanine aminotransferase, and increased waist circumference. Continued hepatic mitochondrial injury plays a role in this progression, particularly with use of nucleoside reverse transcriptase inhibitors. Progression to nonalcoholic steatohepatitis (NASH) and to cirrhosis occurs in a minority of cases.[964,965,966]

**MISCELLANEOUS FINDINGS.**-- Cross-sectional fibroscan studies in HIV-infected patient populations have reported unexpectedly high rates of advance fibrosis in HIV-infected

persons can have hepatic fibrosis by cross-sectional fibroscan studies, even in the absence of viral hepatitis or alcohol abuse. Contributing factors may include direct cellular effects of HIV, hepatotoxicity of ART, and metabolic abnormalities such as dyslipidemia.[967]

Liver biopsy in adult AIDS patients will often show granulomas, and most of these are due to mycobacterial infection (Table 5). In some reported series, up to one-third of cases had granulomas. Persons with a history of injection drug use are often likely to have a concomitant history of chronic alcoholism, with findings ranging from steatosis to portal fibrosis to micronodular cirrhosis, and polarizable talc crystals may be found in portal regions. Hepatomegaly may also result from acute or chronic passive congestion with cardiac failure, usually late in the course of AIDS. Hemosiderin deposition, particularly in Kupffer cells, is common in AIDS, though usually not as extensive as in spleen. It is potentiated by chronic disease and transfusion therapy and can be quite marked.[948,949]

Idiopathic noncirrhotic portal hypertension is a cryptogenic disease associated with HIV infection that may be related to antiretroviral therapy, direct effects of HIV, gut microbe translocation, and thrombophilia. Nodular regenerative hyperplasia may be present. Abnormal liver function tests may include decreased serum albumin and increased gamma-glutamyltranspeptidase. Complications may include ascites, portal thrombosis, and variceal bleeding.[968]

Some cases of noncirrhotic portal hypertension are the result of obliterative portal venopathy in which hepatic synthetic function is preserved, but complications of portal hypertension still occur. It has been diagnosed more frequently in developing nations. Possible etiologies include infection, autoimmune reaction, and drugs. Some cases may be related to antiretroviral therapy with didanosine. By ultrasound the porto-splenic axis is dilated but patent. Microscopic features include hepatic lymphocytic infiltrates around portal tracts. With progression there is phlebosclerosis with intimal fibrosis and elastosis with subendothelial thickening that obliterates lumina of medium to large portal venous branches. The portal veins may resemble adjacent hepatic arterial branches. Paraportal shunts and portal biliopathy may also develop.[969]

Peliosis hepatis, the presence of multiple small blood-filled lakes in hepatic parenchyma without surrounding epithelium or endothelium, has been rarely reported in AIDS. It must be distinguished from Kaposi sarcoma, which has atypical spindle cells, whereas peliosis does not. Bacillary angiomatosis with small bacilli of the species *Bartonella henselae* identified singly or in clusters by Warthin-Starry staining or by immunocytochemical methods can be identified within peliotic spaces. Clinical findings include fever, lymphadenopathy, cutaneous or subcutaneous vascular lesions, osteolytic lesions, and abdominal symptoms. The CD4 count is typically  $<200/\mu\text{L}$ . The hepatic alkaline phosphatase is increased. Hepatic *Bartonella* infection may also manifest with multiple granulomas, often in the form of stellate abscesses surrounded by three distinct zones: an inner layer of palisading macrophages, an intermediate rim of lymphocytes, and an outer layer of fibrosis. This disease may respond to erythromycin therapy.[547,546,970,971]

Veno-occlusive disease (VOD) has been reported in patients with AIDS, particularly in persons with a risk factor for HIV infection of injection drug use. Pathologic findings of VOD are central vein obliteration and sclerosis, sinusoidal congestion and fibrosis, and perivenular hepatocellular degeneration and necrosis. The occurrence of VOD with AIDS may be related to the effects of multiple drugs.[972]

**BILIARY TRACT.**-- The biliary tract and gallbladder with AIDS may occasionally be involved by a variety of lesions including acalculous cholecystitis, sclerosing cholangitis, and papillary stenosis. Collectively, these lesions are known as AIDS cholangiopathy, and most patients who exhibit these findings have a CD4 count  $<200/\mu\text{L}$ . This condition is infrequently encountered when patients have access to antiretroviral therapy. Clinical manifestations include right upper quadrant pain, epigastric pain, fever, diarrhea, hepatomegaly, and weight loss. The serum alkaline phosphatase is markedly elevated, while liver enzymes AST and ALT are only mildly to moderately elevated, and serum total bilirubin only mildly elevated.[973]

Acalculous cholecystitis is accompanied by marked dilation and edema with thickening of the gallbladder wall, bile duct dilation, intrahepatic duct dilation, and cholestasis seen on ultrasonography. Ultrasonography can identify nearly all cases of AIDS cholangiopathy and select cases for endoscopic retrograde pancreatography (ERCP) where cytologic samples can be collected. Magnetic resonance cholangiopancreatography (MRCP) can be employed to detect cases with high sensitivity and specificity. Findings may include a dilated common bile duct and narrowing in the distal duct consistent with papillitis or papillary stenosis. Intrahepatic ductal strictures are sometimes seen. Edema, necrosis, and ulceration can be seen pathologically. Endoscopic sphincterotomy provides relief of abdominal pain and resolution of obstruction. Cholangiography may regress with antiretroviral therapy.[948,949,973,974,975]

Infectious agents including *Cryptosporidium*, *Enterocytozoon bieneusi*, *Septata intestinalis*, *Mycobacterium avium* complex, *Cyclospora*, and cytomegalovirus have been identified in patients with AIDS cholangiopathy or cholecystitis. About one fourth of AIDS patients undergoing cholecystectomy have gallstones. Nodules of Kaposi sarcoma may occur, usually with widespread disease, at the liver hilum and lead to biliary tract obstruction, as can enlarged lymph nodes from MAC infection.[976]

AIDS cholangiopathy may manifest as a secondary sclerosing cholangitis that is suggested by the appearance of epigastric pain, fever, diarrhea, and increased alkaline phosphatase. The bilirubin is usually not elevated. Diagnosis can be made by endoscopic retrograde pancreatography (ERCP), which may demonstrate stricturing, dilation, and beading of the biliary tract. Ultrasonography is often abnormal. At the time of ERCP, abnormalities of the pancreatic duct may also be apparent in half of cases. Sphincterotomy of the papilla of Vater may provide symptomatic relief. Liver biopsy can also be helpful for diagnosis. This disease appears to have no influence upon the prognosis with AIDS.[949,977]



## CARDIOVASCULAR PATHOLOGY IN AIDS

The heart is not a frequent site for opportunistic infectious or neoplastic processes in patients with AIDS (Table 5). Most AIDS patients are in the third to fifth decades of life, at an age when cardiovascular complications from atherosclerosis are not as frequent as in older patients. Atherosclerotic cardiovascular disease leading to ischemia and infarction can and does occur in some AIDS patients, particularly as the numbers of HIV-infected persons begin to include older persons and those surviving longer on antiretroviral therapy (ART). However, the chronic debilitated state with cachexia brought on by AIDS may also lead to regression of atherosclerotic lesions. Clinical cardiac findings may be present in a fourth to three-fourths of adult AIDS patients and may be accompanied by findings that include chest pain, tachycardia, electrocardiographic changes including various arrhythmias, effusions, and congestive heart failure. There may be mild cardiomegaly on chest roentgenogram and minimal electrocardiographic findings.[978,979]

Pericardial effusions may be seen in about 40% of persons with HIV infection. In most of these cases, the effusion is small and clinically insignificant. A specific etiology for the effusion, which can include a variety of infectious agents, is found in about a fourth of cases. Persons with AIDS who have a pericardial effusion, regardless of size, tend to have lower CD4 counts and decreased survival, compared to those without effusions. Though pericardial effusions are seen in the late stages of AIDS, they are rarely the cause of death. The findings of an elevated jugular venous pulse and pulsus paradoxus with "low pressure tamponade" may be masked by dehydration. Regardless of the etiology, a large pericardial effusion in AIDS carries a high mortality, and treatment with a pericardial window is unlikely to prolong survival significantly.[978]

Cardiac tamponade is usually marked by dyspnea, fever, cough, and chest pain. Cardiac arrest may be an initial manifestation. Most cases have serosanguineous fluid. The most common etiology is mycobacterial infection, followed by neoplasms (non-Hodgkin lymphoma or Kaposi sarcoma) and bacterial infection. Most patients die from cardiac tamponade.[980]

Cardiac manifestations in pediatric AIDS are similar to those in adults. Children with HIV also are more likely to demonstrate premature atherosclerosis. Dyslipidemia is prevalent among children with HIV, both with and without ART. Nearly a third of children receiving ART may develop lipodystrophy. Prior to widespread ART, up to 25% of HIV-infected children had cardiovascular symptoms, including decreased left ventricular (LV) function and LV hypertrophy. In the ART era, HIV-infected children had a higher incidence of diastolic dysfunction and significantly increased left ventricular mass index compared to controls.[981]

**ATHEROSCLEROSIS.**-- Coronary artery disease may be seen in a specific setting in AIDS. HIV-infected persons have an increased risk for coronary artery disease, compared to the general population. Rates of risk factors such as smoking, dyslipidemia, hypertension, insulin resistance or diabetes mellitus are high in persons with HIV infection. HIV infection may lead to immune activation and low-grade chronic inflammation that promotes atherosclerosis. Risk factors are highly inter-related.[982]

The pattern of pathologic lesions, location of lesions, and plaque composition is similar to atherosclerosis in HIV-negative patients.[983] Persons with HIV infection on antiretroviral therapy (ART) are at increased risk because the syndrome of HIV lipodystrophy and because of

endothelial dysfunction from viremia, which promote atherogenesis.[984] In this syndrome, there is moderate hypercholesterolemia and marked hypertriglyceridemia along with insulin resistance and glucose intolerance typical for diabetes mellitus. These are findings characteristic of metabolic syndrome. Metabolic syndrome is defined by the presence of 3 or more of the following: a waist circumference >102 cm for men and >88 cm for women; a fasting triglyceride >150 mg/dL; an HDL cholesterol of <40 mg/dL in men or <50 mg/dL in women; a blood pressure >130/85 mm Hg; a fasting glucose >110 mg/dL. Lipid-lowering strategies with use of pharmacologic therapies such as fibric acid derivatives, along with insulin agonists including metformin and thiazolidinediones, can be employed.[985]

HIV infection is associated with a high degree of inflammation within arterial walls, with predilection to early increased cardiovascular disease. A marker of monocyte and macrophage activation called sCD163 is associated with this inflammatory signal. There is correlation between sCD163 and the extent of arterial inflammation. Monocyte and macrophage activation plays a role in the early expression of subclinical atherosclerosis in patients with HIV. CD163 is expressed specifically on the surface of monocytes and macrophages and has a known role as a scavenger receptor. In patients chronically infected with HIV, sCD163 is independently associated with increased noncalcified plaque among young, asymptomatic men.[986]

Atherosclerotic vascular disease, beginning with endothelial dysfunction similar to that seen with type 2 diabetes mellitus, has been reported with use of ART with protease inhibitors, and this may occur without metabolic markers.[987]. Additional mechanisms for protease inhibitor associated atherosclerosis include proteasome inhibition, increased CD36 expression in macrophages, inhibition of lipoprotein lipase-mediated lipolysis, decreased adiponectin levels, and dysregulation of the NF- $\kappa$ B pathway.[988] In addition, HIV has been shown to directly infect arterial smooth muscle cells, leading to proliferation, and this may promote atherosclerotic plaque formation.[989] There are increased levels of circulating adhesion molecules such as ICAM-1 and VCAM-1. Endothelial dysfunction as measured by brachial artery flow mediated vasodilation (FMD) is abnormal in HIV infected persons.[995]

One measure of risk for atheromatous disease is carotid intima media thickness. HIV-infected persons on ART may develop lipodystrophy, a risk for atherogenesis. The fat mass ratio (FMR) is increased in lipodystrophy. Persons with an increased FMR are more likely to have increased carotid intima media thickness.[990]

Smoking as an additional risk factor for atherosclerotic heart disease is seen in these patients.[991] Peripheral vascular disease may be more prevalent in persons with HIV infection, occurring 20 years earlier than in the general population. Age, diabetes, smoking, and low CD4 counts appear to be independent predictors in persons with HIV infection.[992] Peripheral vascular atherosclerosis, however, may not be associated with lipodystrophy.[993]

Acute myocardial infarction can occur, and persons with HIV infection have such an event at a younger age than the general population. However, the absolute risk for developing coronary events remains low compared with that of a HIV-negative matched population, with relative risk of 1.16 per year. Management of antiretroviral related metabolic disorders has gradually improved over time. There is a 6-fold increase in prevalence for peripheral vascular disease with HIV infection, compared to adults seronegative for HIV.[994]

**AIDS CARDIOMYOPATHY.**-- A congestive (dilated) cardiomyopathy in both adult and pediatric AIDS patients has been identified in 10 to 30% of cases. Most of these cases are idiopathic, for no specific opportunistic infection or neoplasm can be identified. Patients with

symptomatic heart failure from dilated cardiomyopathy typically present late in the course of AIDS, have low CD4 counts, have myocarditis, and have a persistent elevation of anti-heart antibodies. At autopsy, there is four-chamber dilation with a flabby, pale appearing myocardium. Echocardiographic findings include four chamber enlargement, diffuse left ventricular hypokinesis, and decreased fractional shortening. It is possible that cardiomyopathy and myocarditis are immunologic phenomenon resulting from HIV-containing lymphocytes in cardiac muscle.[978] Cytokine elaboration by inflammatory cells may contribute as well, since increased levels of both tumor necrosis factor-alpha and inducible nitric oxide synthase have been found in patients with HIV-associated cardiomyopathy. The incidence of HIV-related cardiomyopathy has decreased significantly since the advent of ART.[995]

Cardiac myocytes have also been shown to be a direct target for HIV infection, which may result in cardiomyopathy. A proposed autoimmune mechanism for myocardial damage is based upon the observation that autoantibodies to myosin and cell B receptor can be detected in HIV-infected patients with cardiomyopathy. This may occur when HIV alters myocardial cell surface proteins to elicit an immune reaction. A possible mechanism for an autoimmune contribution to myocardial damage is hypergammaglobulinemia with immune complex formation.[978]

**MALIGNANT LYMPHOMA.**-- A high grade non-Hodgkin lymphoma is one of the most common AIDS diagnostic disease seen in heart, occurring in about one sixth of AIDS cases when lymphoma is diagnosed at autopsy (Table 5). The serum creatine kinase is unlikely to be elevated. Grossly, lymphomas may produce a patchy pattern of infiltration with white streaks or distinct nodules. Despite the often widespread infiltration by malignant lymphoma, cardiac enlargement and failure are uncommon. Microscopically, the lymphomatous infiltrates extend in and around myocardial fibers, onto the endocardium, and over the epicardium. There is little myocardial fiber necrosis or inflammation resulting from such infiltration. These lymphomas can be classified either high grade (diffuse large cell) or intermediate grade (small noncleaved cell) types.[996]

**KAPOSI SARCOMA.**-- Kaposi sarcoma (KS), despite its vascular nature, is not often seen in the heart (Table 5). Cardiac involvement by KS is often limited to small subepicardial deposits in adipose tissue, which usually do not produce clinically apparent problems. Microscopically, the appearance is no different from elsewhere, with atypical spindle cells around vascular slits accompanied by red blood cell extravasation. When KS does involve the heart, there is usually widespread visceral organ involvement, and pulmonary involvement will probably be of greater significance.[996]

**INFECTIONS.**-- Elevation of creatine kinase (CK) may commonly occur with myocardial toxoplasmosis. *Toxoplasma gondii* can produce a gross pattern of patchy irregular white infiltrates in myocardium similar to non-Hodgkin lymphoma. Microscopically, the myocardium shows scattered mixed inflammatory cell infiltrates with polymorphonuclear leukocytes, macrophages, and lymphocytes. True *T gondii* cysts or pseudocysts containing bradyzoites are often hard to find, even if inflammation is extensive. Immunohistochemical staining may reveal free tachyzoites, otherwise difficult to distinguish, within the areas of inflammation. *T gondii* myocarditis can produce focal myocardial fiber necrosis. Heart failure

can ensue. There may be regional differences in the incidence of *T gondii* myocarditis, perhaps because the natural reservoir of organisms persists more easily in humid environments.[514]

Other opportunistic infections of heart are infrequent. They are often incidental findings at autopsy, and cardiac involvement is probably the result of widespread dissemination, as exemplified by *Candida* and by the dimorphic fungi *Cryptococcus neoformans*, *Coccidioides immitis*, and *Histoplasma capsulatum*. Patients living in endemic areas for *Trypanosoma cruzi* may rarely develop a pronounced myocarditis.[561] Cardiac opportunistic infectious lesions in pediatric AIDS cases are not frequent.[981]

**MYOCARDITIS.**—A non-specific myocarditis composed mainly of mononuclear cells appears much more commonly than infectious organisms in the heart of AIDS patients microscopically. There is typically four-chamber dilation. There are mononuclear cells distributed diffusely as single cells or in small clusters. Very minimal myocardial fiber ischemia or necrosis usually accompanies the myocarditis. A myocarditis may be found in 17% of AIDS cases at autopsy in association with cocaine use, and 10% without cocaine, and it usually occurs in the absence of diagnosable opportunistic infections. Many AIDS patients with a history of clinical cardiac abnormalities have myocarditis at autopsy. HIV itself may cause T lymphocyte activation with cytokine release that potentiates myocardial damage. Histologically, mononuclear cells may also be seen as a mild epicarditis, which may account for some pericardial effusions. Findings more often seen with cocaine use, but also with HIV, include coronary artery infiltrates, left ventricular hypertrophy, and thickened myocardial vessels.[978,997]

**DRUG TOXICITY.**-- A number of pharmacologic agents may induce significant cardiac arrhythmias. These include amphotericin B, pentamidine, and interferon alfa. Bradycardia is seen in children treated with amphotericin B. Doxorubicin can produce cardiomyopathy. Interferon alfa administered as part of prolonged antiretroviral therapy may also lead to a dilated cardiomyopathy, as well as ischemia, and congestive heart failure. Zidovudine can produce mitochondrial changes in striated muscle. Cocaine use in patients with a history of drug abuse may lead to myocarditis, contraction band necrosis, and cardiomyopathy.[978]

The antiretroviral drug abacavir is associated with an increased risk for cardiovascular disease and heart failure. Recent tenofovir use is associated with heart failure.[998]

**ENDOCARDITIS.**-- Debilitation of patients with AIDS, particularly in the terminal course, may predispose to the formation of non-bacterial thrombotic endocarditis (marantic endocarditis). This is the most common form of endocarditis with AIDS and may be seen in about 5% of persons dying with AIDS at autopsy, most of them older than age 50. Such marantic valvular vegetations can occur on any valve and are probably agonal, although occasional infarcts in spleen, kidney, or cerebrum may result from pre mortem embolization.[978]

Persons with HIV infection whose risk is injection drug use (IDU) have an increased risk for infective endocarditis compared to HIV seronegative IDUs. Over 90% of cases of infective endocarditis with HIV infection occur in IDUs. *Staphylococcus aureus* is the most common pathogen, followed by *Streptococcus*, viridans group. Other agents may include *Salmonella* species, *Aspergillus*, and *Pseudallescheria boydii*. The tricuspid valve is the most commonly affected valve, in over half of cases, but left sided valvular disease occurs in 45% of cases, and

multiple valves are involved in 18%. Pulmonic valve infection is rare. The mortality rate is higher with multiple valve involvement and with lower CD4 counts. Most patients have a coexisting pneumonia or meningitis.[978,999]

**VASCULITIS.**-- Vasculitis associated with HIV infection may result the effects of HIV proliferation and inflammatory response, or from opportunistic infections. About 1% or less of persons infected with HIV may develop vasculitis. The most common pattern of vasculitis resembles polyarteritis nodosa, (PAN) and involves medium to small vessels. It differs from classic PAN because of absence of waxing and waning course, absence of association with hepatitis B viral infection, and lack of multisystem organ involvement. The most common areas of involvement are skin, peripheral nerve, and muscle, followed by central nervous system, lungs, gastrointestinal tract, and kidneys. Hypersensitivity vasculitis involves medium to small sized vessels, most often in the skin and accompanied by palpable purpura. It may also result from infections with CMV, Epstein-Barr virus, or hepatitis B virus.[1000,1001]

Additional vasculitic patterns reported include cryoglobulinemic vasculitis, granulomatosis with polyangiitis, Kawasaki-like syndrome, giant cell arteritis, primary angiitis of the central nervous system, and erythema elevatum diutinum. Primary angiitis is a rare condition characterized by a granulomatous inflammatory infiltrate, often with multinucleated giant cells most often affecting small arteries and veins of the leptomeninges; it is associated with a high mortality rate. Non-necrotizing vasculitis may affect a third of HIV-infected individuals, and can be manifested as retinal microangiopathic syndrome with the presence of multiple cotton wool. Plasma endothelin-1, a potent vasoconstrictor, can be elevated.[1000,1001]

A vasculopathy involving large arteries including the aorta and its branches has also been described in young adults with AIDS. The features of this vasculopathy overlap with Takayasu's disease. With large artery vasculopathy there is a propensity for the appearance of single or multiple aneurysms. The appearance of these lesions appears due to leukocytoclastic vasculitis of vasa vasorum or small adventitial arteries. Medial fibrosis and vascular occlusion can occur. There can be angiogenesis with proliferation of slit-like channels in the adventitia. There does not seem to be an association of this vasculopathy with either atherosclerosis or with opportunistic infections.[1002]

**MISCELLANEOUS FINDINGS.**-- The complication of tuberculous pericarditis is increasing in regions where *Mycobacterium tuberculosis* infection is endemic. In HIV-infected persons, an asymptomatic presentation of pericarditis, with presence of disease elsewhere, is more common than in non-infected persons. Symptomatic presentation relates to pericardial fluid collection and also to constriction of cardiac movement. Effusions tend to be larger in HIV-infected persons. Constrictive pericarditis may ensue in over half of cases despite antitubercular therapy.[1003] Hemorrhagic pericarditis is uncommon and development of constrictive pericarditis unlikely.[978]

Rheumatic inflammatory changes, ranging from rare scattered Anitschkow myocytes to well-formed Aschoff nodules similar to those seen in rheumatic heart disease, are rarely reported to occur in AIDS. However, chronic rheumatic sequelae of fibrosis or valvular disease have not been seen in AIDS.[1004]

## GENITOURINARY PATHOLOGY IN AIDS

The genitourinary system is occasionally affected by infectious agents seen in AIDS (Table 5). When either malignant lymphoma, cryptococcosis, or *Mycobacterium tuberculosis* is present with AIDS at autopsy, the kidney is involved about one fourth of the time. Despite the fact that HIV infection is most frequently spread by sexual means, lesions of the male and female genital tract with HIV infection are not frequent, and no specific direct effect of HIV has been documented at these sites. Clinical life-threatening urologic problems are rare in AIDS, but patients can have urinary tract and prostatic infections more frequently than in immunocompetent persons.[1005]

Urinalysis may reveal proteinuria and microalbuminuria associated with HIV infection. Approximately a third of HIV-infected persons may have either finding. Risks include African-American race, higher HIV-1 RNA level, and lower CD4 lymphocyte count. Microalbuminuria is associated with development of insulin resistance and increased risk for cardiovascular and renal diseases.[1006]

Hematuria is not common from opportunistic infections or neoplasms because such lesions are neither numerous nor extensive in the genitourinary tract (Table 5). Cytomegalovirus inclusions are not commonly observed in urine specimens. Decreased renal function may be associated with nephritis from drug therapies (amphotericin B, pentamidine, sulfamethoxazole). Acute renal failure with tubular necrosis may occur in the terminal course with AIDS.

Serum electrolyte abnormalities are relatively common with AIDS. Hypokalemia can be seen with chronic diarrhea and vomiting, while hyperkalemia is associated with metabolic acidosis and impaired renal function. Hyponatremia, which is present in up to a third of hospitalized patients with HIV-infection, can occur with diarrhea and with volume depletion, as well as with a syndrome of inappropriate antidiuretic hormone secretion (SIADH) from respiratory or CNS infections. Hyponatremia is a poor prognostic sign.[1007]

A number of pharmacologic agents used to treat opportunistic infections seen in AIDS can lead to renal failure as evidenced clinically by elevated blood urea nitrogen (BUN) and creatinine measurements. The drugs foscarnet, didanosine, and pentamidine have been implicated in cases of hypocalcemia, while foscarnet may also predispose to hypercalcemia. Hyperuricemia can occur with didanosine therapy.[286,1008]

Acute tubular necrosis (ATN) can occur from a variety of causes. Nephrotoxic ATN has been reported with several pharmacologic agents for opportunistic infections, including amphotericin B, pentamidine, and foscarnet. The antiretroviral agents adefovir, tenofovir, cidofovir and ritonavir can also produce ATN.[279,1007]

Protease inhibitors have been implicated in production of crystal-induced acute renal failure and nephrolithiasis. Indinavir has been associated with nephrolithiasis in 5 to 25% of patients. Crystallization occurs from inadequate hydration of patients taking this medication. Other drugs with this side effect include sulfadiazine, acyclovir, and foscarnet. This effect can be potentiated with lysis syndrome and high uric acid levels in patients treated for malignant lymphomas. Urinary tract calculi can occur with sulfadiazine and indinavir therapy.[1007,1009]

Urinary tract infection (UTI) with HIV infection is most likely to occur when the CD4 count drops below 500/ $\mu$ L. The most common bacterial pathogens include *Escherichia coli*, *Enterobacter*, *Pseudomonas aeruginosa*, *Proteus* spp, *Klebsiella*, *Acinetobacter*, *Staphylococcus aureus*, group D *Streptococcus*, and *Serratia*. UTI with *Salmonella* organisms is of particular

concern and must be treated with life-long prophylaxis to prevent fatal recurrence. A negative urine bacterial culture should prompt search for fungal agents such as *Candida*, viral agents such as cytomegalovirus, or mycobacteria. Lower UTI may ascend to cause pyelonephritis, and gram negative bacteria are the most likely agents. Opportunistic agents leading to pyelonephritis with HIV infection can include *Candida*, *Mycobacteria*, *Histoplasma*, and *Pneumocystis*. Mycobacterial infections typically start in the kidney from hematogenous spread, then descend the urinary tract.[1005,1009]

Acute renal failure from prerenal causes can occur from volume depletion with fluid loss from vomiting or diarrhea. Sepsis can lead to volume depletion with similar outcome. Renal diseases leading to serious morbidity and mortality with AIDS can be seen in both early and late stages. Both acute renal failure as well as end stage renal disease can occur. Though not common, end stage renal disease may result from varied etiologies, including HIV nephropathy.[1008]

Additional pathologic findings in HIV-infected persons include arterionephrosclerosis, glomerulonephritis (most often with a membranoproliferative pattern), pyelonephritis, interstitial nephritis, diabetic nephropathy, fungal infection, and amyloidosis. The variety of lesions increases with prolonged survival and increasing prevalence of diabetes mellitus and hypertension.[1010]

**HIV ASSOCIATED NEPHROPATHY (HIVAN).**-- Persons with HIVAN present with nephrotic-range proteinuria and renal dysfunction. Up to 10% of HIV-infected persons, mainly of African ancestry, prior to the use of combined antiretroviral therapy (ART). Though HIVAN could appear even in the early stage of HIV infection, it was most likely diagnosed with AIDS, was associated with a collapsing glomerulopathy, and progressed to end-stage renal disease (ESRD). Since the advent of ART, the prevalence of HIVAN has diminished, along with fewer cases progressing to ESRD, because most cases are now of the non-collapsing type.[1011]

There is direct infection of renal glomerular and tubular epithelial cells by HIV, independent of CD4 receptors. This direct pathway may involve direct transfer of virus from infected lymphocytes via cell surface contact and subsequent uptake into epithelial cell endosomes. HIV genes *vpr* and *nef* can elaborate proteins that dysregulate intracellular signaling within glomerular epithelial cells, including podocytes, as well as tubular epithelial cells. This leads to increased expression of proinflammatory cytokines controlled by nuclear factor kappa B.[1012]

The renal infection by HIV can contribute to development of HIVAN. In the majority of cases the affected person is Black, though a few are Hispanic, and the disease is rare in Caucasians. The genetic susceptibility risk factor appears to be a polymorphism in the *apolipoprotein LI (APOLI)* gene, and persons carrying two copies of either the G1 or G2 alleles, or a copy of both alleles, have a 50% chance of developing HIVAN in the absence of antiretroviral therapy. The G1 and G2 alleles are more frequent in African populations.[1011,1012]

HIVAN is characterized by marked proteinuria and a rapid progression to renal failure and end stage renal disease (ERSD). Patients are typically normotensive. Rising serum urea nitrogen and creatinine levels in a non-terminal patient may suggest nephropathy. For diagnosis of HIVAN, total protein excretion should exceed 100 mg/m<sup>2</sup> in a child or 200-500 mg in an adult. The proteinuria can reach the nephrotic range. Albuminuria and lipiduria are typically absent with HIVAN.[1013,1014]

Adults with HIVAN not on ART tend to progress rapidly to ESRD and survival is only a matter of months, with those persons having just HIV infection living longer than those with clinical AIDS. In children, HIVAN has a less fulminant course. The use of ART slows the progression to renal failure.[1015]

The kidneys with HIVAN can be grossly enlarged from 10 to 25%, appearing echogenic by ultrasound. However, they are not atrophic, even in the later stages. The most common renal biopsy finding, seen in over 80% of cases, is focal segmental glomerulosclerosis (FSGS). Diffuse mesangial hypercellularity is the most common pattern seen in children. A variety of other features occur including collapse of glomerular capillaries, visceral glomerular epitheliosis, proliferation of renal tubular and visceral epithelial cells (podocytes), tubular microcystic formation, edema, interstitial fibrosis, and infiltration of the interstitium with leukocytes. Over half of renal biopsies in HIVAN will demonstrate collapsed glomeruli, and this finding, as well as findings of increased podocyte swelling, intracytoplasmic protein resorption droplets, endothelial tubuloreticular inclusions, and diminished hyalinosis serve to distinguish HIVAN from idiopathic FSGS and from heroin nephropathy.[1011,1013,1014]

Tubulointerstitial changes are prominent and may be more severe than glomerular disease in HIVAN. The most prominent feature is microcystic tubulointerstitial disease, which accounts for the renal enlargement. Other changes may include tubular epithelial cell simplification, loss or attenuation of the brush border, enlarge hyperchromatic nuclei with nucleoli, numerous proximal tubular intracytoplasmic protein droplets, and lipid resorption droplets. The amount of interstitial, microcystic change, atrophy, edema, fibrosis, and inflammation is variable. The presence of tubular degenerative changes and tubular microcyst formation is more likely in HIVAN than heroin nephropathy. The tubuloreticular inclusions seen with HIVAN by electron microscopy are similar to the “myxovirus-like” particles of lupus nephritis. Microcystic dilation in the setting of proteinuria suggest a poor outcome.[1011,1013,1014]

A subset of HIVAN cases have the predominant feature of collapsing glomerulopathy (CG) which is characterized by focal, segmental, or global glomerular capillary collapse with wrinkling of the basement membranes, obliteration of capillary lumens, disappearance of endothelial and mesangial cells, and hypertrophy and hyperplasia of adjacent visceral epithelial cells. Cases of CG are seen independent of HIV infection. CG appears to be more aggressive than the FSGS pattern seen with HIVAN.[1016]

Screening for HIVAN can include annual checks of blood pressure, serum creatinine, and glomerular filtration rate, as well as measurement of the urine protein:creatinine ratio and urine albumin:creatinine ratio. A urine albumin (in mg/dL) to creatinine (in g/dL) more than 30mg/g is a marker of chronic kidney disease. Therapies include control of blood pressure with angiotensin converting enzyme (ACE) inhibitors or angiotensin receptor blockers (ARBs). If transplantation is performed, HIVAN tends not to recur in the allograft.[1011]

**HIV-ASSOCIATED IMMUNE COMPLEX KIDNEY DISEASE (HIVICK).--** A number of immune complex related conditions may affect HIV-infected persons. Among these are conditions resembling IgA nephropathy, post-infectious glomerulonephritis, membranous glomerulopathy, and membranoproliferative glomerulonephritis. The latter two may be associated with hepatitis B and/or hepatitis C viral co-infection with HIV. The p24 antigen contributes to immune complex formation. A proliferative glomerulonephritis ensues and patients can present with proteinuria and renal failure. In general, renal diseases other than HIVAN in HIV infected persons progress more slowly to renal failure.[1011.1012.1015,1017]



**ACUTE INTERSTITIAL NEPHRITIS (AIN).**-- In one study of renal biopsies in HIV-infected persons, AIN was found in 11%. Only a fourth of cases had a classic presentation triad of fever, rash, and pyuria. Only a fourth had significant proteinuria. Over half of the patients were men, were of Black race, had concomitant hepatitis C infection, and were on antiretroviral therapy. A causative drug was identified in three fourths of cases, most often a nonsteroidal anti-inflammatory drug or sulfamethoxazole/trimethoprim. An antiretroviral drug was the cause in only three cases.[1018]

**TENOFOVIR TOXICITY.**-- The antiretroviral drug tenofovir is associated with Fanconi syndrome and declining renal function in a small number of patients. Renal tubular impairments characteristic for Fanconi syndrome include glycosuria, aminoaciduria, hyperphosphaturia, and hypophosphatemia. Osteomalacia may occur from impairment of renal production of vitamin D3 (calcitriol). If tenofovir is discontinued, the Fanconi syndrome will typically abate. However, some patients may continue to have decreased creatinine clearance. Pathologic findings can include tubular degenerative changes, including luminal ectasia, simplification and dropout of tubular epithelial cells, loss of brush borders, and thickening of tubular basement membranes. There can be interstitial fibrosis.[279] Toxicity may result in microscopic proximal tubular eosinophilic inclusions that represent giant mitochondria that by electron microscopy show dysmorphic changes. The tubular damage may be reversible if the drug is stopped.[1019]

**OPPORTUNISTIC INFECTIONS.**-- These infections most commonly involve the renal interstitium in either cortex or medulla. Small inflammatory infiltrates composed of lymphocytes or macrophages usually accompany infection with *C neoformans*, *H capsulatum*, *T gondii*, or cytomegalovirus. *M tuberculosis* and *C immitis* may produce granulomas. *Mycobacterium avium*-complex produces small clusters of pale striated blue macrophages with hematoxylin-eosin staining. *Candida* produces small microabscesses, but renal abscesses may be present in up to 5% of AIDS patients with bacterial sepsis. Sometimes, small numbers of budding cells of fungal organisms can be seen within glomeruli, often without marked inflammatory reaction. Cytomegalovirus involves renal tubular epithelium in about half of cases with renal involvement by CMV. In remaining cases, the CMV cells may be found in the interstitium or, less commonly, the glomerulus. Cytomegalovirus in kidney may be accompanied by focal chronic inflammatory cell infiltrates.

BK virus, a member of the human polyoma virus group, may be reactivated with immunosuppression. It can produce a tubulointerstitial nephritis. Renal biopsy may show intranuclear inclusions within renal tubular cells. BK viral DNA may be detected with in situ hybridization.[1020] BK viremia is not common with HIV infection, but BK viruria occurs in about half of infected patients, more often when the CD4 count is above 500 and HIV viremia is low, and there is no correlation with renal or neurologic disease.[1021]

**URINARY TRACT NEOPLASMS.**-- AIDS-associated neoplasms in the kidney occur when there is widespread involvement of multiple organs. Kaposi sarcoma produces a few widely scattered small red to red-purple nodules anywhere from the perirenal fat to the renal capsule to the collecting system. One peculiar pattern of renal involvement seen in about half of cases with high grade lymphomas in AIDS is the appearance of one or several prominent mass lesions from 1 to 5 cm in size. These masses are firm, discrete, and have a white to minimally

variegated red-white, lobulated cut surface. In remaining cases, the lymphomatous infiltrates are faintly visible to inconspicuous grossly.

Bladder carcinoma may occur in association with HIV infection, typically urothelial carcinoma. These carcinomas in HIV-infected persons tend to occur at a younger age and with only mild immunosuppression. Hematuria is the usual presenting sign.[1022]

**MALE GENITAL TRACT.**-- About half of male AIDS patients have clinical evidence of gonadal dysfunction with decreased libido and impotence that may be explained by decreased testosterone levels. The exact mechanism is not entirely clear. Both ganciclovir used to treat cytomegaloviral infections and ketoconazole used to treat fungal infections may decrease testosterone synthesis.[941] There are no specific pathologic changes in the male genital tract resulting from HIV infection despite the fact that seminal fluid is a common vehicle for transmission of HIV. By in situ hybridization, HIV-1 proviral DNA can be identified within the germ cells at all stages of differentiation but without morphologic changes.[1023] Immunohistochemical staining with anti-HIV monoclonal antibody has demonstrated the presence of HIV in both testis and prostate.[1024]

Hypogonadism late in the course of AIDS leads to loss of libido and impotence. Half of male AIDS patients have biochemical evidence for hypogonadism, but only 20% on antiretroviral therapy. Gonadal dysfunction can be due to nutritional problems, infection, drugs, and hyperprolactinemia. HIV infection reduces dopaminergic tone, leading to increased prolactin. TNF release can inhibit steroidogenesis; IL-1 prevents LH binding to Leydig cells and prevents steroid production.[942]

The testis in AIDS shows an atrophy somewhat like that of chronic alcoholism--there is decreased or absent spermatogenesis, peritubular fibrosis and loss of germ cells--but opportunistic infections and neoplasms are rare. In severely debilitated patients, there may be marked tubular atrophy. Diffuse interstitial mononuclear cell infiltrates can occur but do not necessarily accompany opportunistic infections, which produce more focal inflammation.[1025]

Over the course of HIV infection, histologic findings in the testicular tubules can include features of decreased spermatogenesis, spermatogenic arrest, and marked atrophy with only Sertoli cells. The use of antiretroviral therapy with prolongation of survival leads to greater numbers of infected males with tubular atrophy. However, even late in the course of HIV there can still be germ cells present, and the numbers of germ cells does not correlate with the CD4 count. Thus, the potential for spread of HIV infection through the sexual route from presence of infected testicular germ cells is variable but often present.[1026]

Testicular neoplasms have peak incidence in young males and may be diagnosed in patients with AIDS, and germ cell testicular tumors are estimated to be 50 times more common in HIV-positive men, with two new cases per 1000 HIV-infected persons, compared with 3.5 per 100 000 of the male population. These tumors tend to be more aggressive with a greater incidence of bilateral presentation. HIV-positive patients treated for testicular cancers have a comparable morbidity and response to that for non-immunosuppressed patients.[1005]

Orchitis and epididymitis are more common with HIV infection than the general male population, and they can become chronic and recurrent. These infections may co-exist with bladder infection and may be suspected when the UTI fails to clear with antibiotic therapy. Opportunistic pathogens may include CMV, *Mycobacterium avium*-complex, *Candida*, *Toxoplasma*, and *Histoplasma*. Gonococcal infections may occur, particularly in young men.

Infections with *Salmonella* may be difficult to treat, and life-long prophylaxis is needed to prevent overwhelming sepsis.[1005]

Inflammatory pseudotumor has been reported in the testis of a patient infected with HIV and treated with antiretroviral therapy (ART) mimicking testicular cancer. The nodular lesions on microscopic examination show a mixed chronic inflammatory infiltrate in a background of spindle cells. The inflammatory infiltrate have a mixture of plasma cells, B lymphocytes and T lymphocytes and the background spindle cells expressed CD68 and smooth muscle actin, consistent with a histiocytic and fibroblastic origin. Immune reconstitution following ART may play a role in the appearance of this lesion.[1027]

The antibacterial protection of zinc, spermine and spermidine produced in the prostate fails as HIV infection progresses, increasing the risk for prostatitis. In the general population, the incidence of bacterial prostatitis is 1–2%, rising to 3% in asymptomatic HIV-positive patients, and to 14% in patients with AIDS. Prostatitis may be caused by an ascending urethral infection, by direct invasion of rectal bacteria, or by hematogenous spread to the prostate. The clinical presentation is usually acute with severe irritative urinary symptoms, fever, and generalized malaise. On digital rectal examination, the prostate is swollen and exquisitely tender. Prostatic abscesses may be caused by the usual bacterial pathogens or by opportunistic fungal and mycobacterial infections, with symptoms similar to acute prostatitis, and a fluctuant mass may be palpated. The risk for prostate abscess and urosepsis is increased with HIV infection. Urine cultures often show sterile pyuria, although blood cultures may be positive.[1005]

Prostatitis may be found in 3% of men with HIV, and 14% of men with AIDS, compared with rates of 1% to 2% in the general population. The complication of prostatic abscess is more common as well. Despite antibiotic therapy, relapse is common. Prostate and seminal vesicle are occasionally the site for KS and CMV when these processes are widely disseminated. One important finding in prostate is cryptococcal prostatitis, typically seen with disseminated cryptococcosis. Prostatic involvement may result in clinical difficulties in treatment because of the inability of antifungal agents to reach the prostatic glands in high concentration, so that the prostate remains a reservoir for reinfection. Obstructive uropathy does not occur from these lesions.[1005]

In a study of HIV-infected men receiving antiretroviral therapy, the clinical presentation, age at diagnosis, and prostate specific antigen (PSA) levels did not appear to be altered by their HIV status. Their disease management and outcome was similar to HIV negative men.[1028]

Seminal vesicles can harbor macrophages infected with HIV that contribute to the infectivity of seminal fluid. Thus, the seminal vesicles can serve as a reservoir for HIV.[148]

Penile intraepithelial neoplasia and carcinoma occur with increased frequency in HIV positive men having sex with men. Human papillomavirus (HPV) infection involving penile shaft, and scrotum range is often present. There may be concomitant anal squamous intraepithelial lesions.[770]

**FEMALE GENITAL TRACT.**-- Opportunistic infections with AIDS are uncommon in the female genital tract. Vulvovaginal candidiasis occurs with higher incidence and greater persistence, but not greater severity, among HIV-infected women.[1029] Additional sexually transmitted diseases, including gonorrhea, syphilis, and *Chlamydia* are also more frequently seen in HIV-infected persons and require appropriate diagnostic procedures and treatment. Kaposi sarcoma and lymphoma are rare at these sites with AIDS.

Women with HIV infection are more likely to have concomitant human papillomavirus (HPV) infection, infection with multiple HPV subtypes (including the high-risk HPV16 and 18 subtypes), and have a subsequent higher risk for cervical intraepithelial neoplasia (CIN), particularly high grade CIN, and invasive cervical squamous cell carcinomas. The immunosuppression induced by HIV leads to inadequate clearance with persistence of HPV infections.[1030] HIV-infected women have more vulvar, vaginal, and perianal intraepithelial lesions than HIV-uninfected women.[1031]

The risk for developing cervical squamous intraepithelial lesions (SILs) in HIV-infected women is 17% after 1 year and 48% after 5 years, and the risk increases for younger women and those with higher initial viral load; the prevalence of SIL is related to reduced CD4 lymphocyte count. The morphologic appearances of such lesions include atypical glandular cells of uncertain significance (AGUS), atypical squamous cells of uncertain significance (ASCUS), low-grade SIL (LSIL), and high-grade SIL (HSIL).[1032] Such patients are more likely to have symptomatic human papillomavirus (HPV) infections when the CD4 lymphocyte count is  $<200/\mu\text{L}$ , particularly with the viral types HPV-16 and HPV-18 that are more often associated with dysplasias and malignancies of squamous epithelium. Thus, these high grade squamous epithelial lesions occur both as a consequence of sexually transmitted HPV infection and through promotion by concomitant immunosuppression with HIV infection.[1033] The 1993 CDC surveillance case definition for AIDS now includes HIV-infected women who have invasive cervical carcinoma.[421]

Vaginal intraepithelial neoplasia (VAIN) can be screened by Pap smear testing. VAIN is more likely to occur in HIV seropositive women, and they are less likely to clear HPV than seronegative women. Though higher grade VAIN or carcinoma is more likely to occur in HIV-infected women, it is still uncommon.[1034]

Vulvar condyloma acuminatum is more common in women with HIV infection, but can regress, particularly when the CD4 lymphocyte count is higher. Vulvar intraepithelial neoplasia (VIN), regardless of grade, occurs more frequently among HIV-seropositive than HIV-seronegative women. Vulvar carcinoma in HIV seropositive women is uncommon.[1035]

Pap smears should be obtained on women infected with HIV on a yearly basis, or at more frequent intervals if an abnormal Pap smear is obtained.[223] Cervical carcinomas in HIV-infected women are more likely to be invasive and have a worse prognosis than in uninfected women.[1036] Marked debilitation with advancing HIV illness may lead to absence of normal menstrual cycles, a non-secretory endometrium, and ovarian atrophy with loss of follicles.

**BREAST.**—The breast can be involved with both benign and malignant diseases in persons with HIV infection. Benign conditions may include gynecomastia in males and increased adipose tissue deposition as part of the lipodystrophy seen in both men and women on antiretroviral therapy (ART). Gynecomastia is most likely to occur in men receiving ART and is strongly associated with efavirenz therapy.[1037,1038] ART may be associated with just an increase in fat, or lipomastia.[1039]

In women the breast may be involved by tuberculous mastitis. There is an increased risk for mastitis, and infections with *Pseudomonas aeruginosa* can be particularly severe. HIV infection is a contra-indication to breast implantation because of the risk for infection. Pseudoangiomatous stromal hyperplasia (PASH), a keloid-like stromal hyperplasia with myofibroblast and vascular proliferation, has been reported in association with HIV infection,

and PASH can present as a rapidly enlarging mass lesion. Although there is no link between breast cancer and HIV infection, women with HIV who develop breast cancer do so at an earlier age, have a greater likelihood of bilateral breast involvement, and have an increased rate of metastatic disease. In addition to breast cancer, Kaposi sarcoma and non-Hodgkin lymphoma have also been reported in women with HIV infection.[1040] Intramammary lymph nodes involved with lymphadenopathy of HIV infection may mimic breast masses.[1041]

**FERTILITY AND REPRODUCTION.**—HIV-infected persons of reproductive age retain fertility for childbearing. HIV-1 is intermittently present in the genital tract at variable concentrations in both men and women. Semen analysis in asymptomatic HIV-1-infected men without antiretroviral therapy shows findings consistent with fertility. Spontaneous pregnancy rates, however, appear reduced in HIV-1-infected women when compared with HIV-1-negative women. A higher prevalence of sexually transmitted diseases in HIV-infected women may increase the risk for tubal infertility. Though seroconcordant couples could practice self-insemination, HIV-1 superinfection of the woman could occur and could enhance disease progression. HIV-1-infected patients have various assisted reproduction techniques (ART) available. ART with semen processing has been an effective means of generating pregnancies and has been performed in HIV-1-infected couples since the early 1990s without any reported seroconversion.[1042]

In an HIV-infected man, the goal of semen processing is to separate the spermatozoa from all other semen components to obtain an HIV-1-free spermatozoal fraction that contains sufficient morphologically normal and motile spermatozoa. The spermatozoal fraction can be tested for the presence of HIV-1 by PCR-based methods. In one study, HIV-1 could not be detected by PCR in the spermatozoal fraction in 98% of samples of men using ART and in 82% of men without antiretroviral therapy after semen processing. Though semen processing appears more effective in men using ART, even in men with full suppression of HIV-1 RNA in blood, HIV-1 RNA can rarely be found in the spermatozoal fraction after semen processing. In an HIV-infected woman, there is a theoretical risk that an assisted reproductive procedure itself could cause vertical transmission. Although receptors for HIV-1 have not been demonstrated on the surface of the oocyte itself, HIV-1 has been detected in ovarian follicles. Theoretically, a viral particle could be introduced into a human oocyte during intracytoplasmic sperm injection.[1042]

## DERMATOPATHOLOGY IN AIDS

Over 90% of persons infected with HIV will develop at least one type of dermatologic disorder during the course of their HIV infection. These include both common and uncommon infections, neoplasms, and reactions to drugs given for treatment of HIV and its complications, and dermatoses. Historically, Kaposi sarcoma has been the most characteristic skin disease associated with HIV infection. Antiretroviral therapy (ART) may increase of certain dermatologic diseases, mostly within the first 3 months after initiation, because of immune restoration that may exacerbate previously dormant conditions such as herpes zoster and mycobacterial infections. Adverse cutaneous drug reactions secondary to ART may also occur as does photosensitivity with ART use.[1043]

**KAPOSI SARCOMA.**-- Dermatopathology in AIDS primarily centers around diagnosis or exclusion of KS. Except for lesions caused by herpesviruses, lesions other than KS are quite uncommon (Table 5). Kaposi sarcoma, also called "multiple idiopathic hemorrhagic sarcoma," was once a rare entity. Kaposi sarcoma occurs in the following clinical patterns: classic (sporadic), endemic African (benign nodular, aggressive, florid, and lymphadenopathic), iatrogenic (seen in immunocompromised patients such as recipients of organ transplants, those patients on immunosuppressive drug therapy, or patients with connective tissue diseases), and epidemic (AIDS-associated). All forms of KS have a male predominance, but this is even more pronounced with AIDS. Though less common in other clinical forms, KS often has visceral involvement in AIDS. The appearance of all forms of KS is associated with infection by human herpesvirus 8 (HHV-8), also known as KS-associated herpesvirus (KSHV). [586]

A presumptive clinical diagnosis of KS indicative of AIDS can be made by CDC definitional criteria as follows:[130]

A characteristic gross appearance of an erythematous or violaceous plaque-like lesion on skin or mucous membrane. (Note: Presumptive diagnosis of Kaposi sarcoma should not be made by clinicians who have seen few cases of it.)

**STAGING OF KAPOSI SARCOMA.**-- A simple staging system for KS, which is useful when comparing and classifying the type of KS, is as follows: Stage I: locally indolent cutaneous KS; Stage II: locally aggressive cutaneous KS with or without regional lymph nodes; Stage III: generalized mucocutaneous and/or lymph node involvement; Stage IV: visceral KS. These stages are further subtype by absence (A) or presence (B) of weight loss, persistent fevers, or night sweats.[586]

Additional criteria for staging of KS have been developed to determine prognosis and treatment based upon a three tiered (Tn In Sn) system as follows: T being the extent of tumor, I being the immune system status assessed by CD4 lymphocyte count, with "n" as 0 for CD4 lymphocyte count of 150/ $\mu$ L or less and 1 for higher counts, and S being the severity of systemic illness, with "n" as 0 - "good risk" or 1 - "poor risk". Good risk factors include all of the following: tumor confined to skin and/or lymph nodes and/or minimal oral disease (defined as non-nodular KS confined to the palate; lack of systemic illness defined as no history of opportunistic infection or thrush, no "B" symptoms, or performance status of at least 70

(Karnofsky). Poor risk factors include any of the following: tumor-associated edema or ulceration, extensive oral KS, non-nodal visceral KS; immune system status of CD4 cell count less than  $150/\mu\text{L}$ ; presence of systemic illness defined as a history of opportunistic infection or oral thrush, presence of "B" symptoms, performance status less than 70, or other HIV-related illness (e.g., neurologic disease, lymphoma). The "B" symptoms include: unexplained fever, night sweats, >10% involuntary weight loss, or diarrhea persisting for more than two weeks.[586,1044] In the era of antiretroviral therapy, the CD4 count provides little prognostic information, so that a designation of T1S1 indicates poor risk.[1045]

**HISTOPATHOLOGY OF KAPOSI SARCOMA.**-- The histogenesis of Kaposi sarcoma (KS) is unclear, but the spindle cells are of mesenchymal origin, with features of both endothelium and smooth muscle. Though KS tends to be multifocal, whether involving the skin or visceral organs, it is monoclonal in origin, similar to a true neoplasm.[596] An HIV gene product may be instrumental for inducing neoplasia, with cellular proliferation mediated by cytokines produced by the KS cells. Kaposi sarcoma in AIDS has three gross pathologic patterns of skin involvement: patch, plaque, and tumor.[1046]

The early lesions of patch stage KS are clinically as well as microscopically quite inconspicuous. These flat or macular bluish to reddish-purple lesions often resemble bruises. Cutaneous lesions may occur anywhere on the trunk and extremities but there is a propensity for facial involvement. Lesions on the neck, upper trunk and arms may follow the skin cleavage lines in a dermatomal distribution pattern similar to the lesions of pityriasis rosea.[1046]

The patch stage microscopically shows a superficial and perivascular proliferation of spindle cells. The spindle cells are arranged in parallel arrays around the vessels or beneath the epidermis. The involved vessels often appear straighter than usual and seem to cut through the dermis. They tend to be more conspicuous in the immediate vicinity of native dermal vessels and cutaneous appendages. Protrusion of the normal vascular structures into the lumens of more ectatic neoplastic vascular spaces produces a promontory sign. The dermal collagen may be invaded by slit-like vascular spaces lined by a monolayer bland, flattened endothelial cells, often containing erythrocytes and with a variable degree of erythrocyte extravasation outside the vascular spaces. Most often the neoplastic cells of KS are spindle-shaped, but they may also have a fusiform to epithelioid appearance. They have an eosinophilic cytoplasm and may have prominent round, oval, or fusiform nuclei. Atypical features of nuclear pleomorphism and hyperchromatism may not be pronounced. In the earliest lesions red blood cells may not be seen. There can be an inflammatory cell infiltrate of lymphocytes and plasma cells, as well as hemosiderin-laden macrophages, most prominent around native vessels and skin adnexal structures.[1047]

Helpful findings in very early KS lesions include individually necrotic cells, a mononuclear cell infiltrate, presence of epithelioid cells, dilated irregular vascular spaces, and perivascular distribution. This is followed by a marked increase in spindle cells along slightly widened spaces between the collagen bundles. With passage of time the perivascular spindle cell proliferation becomes more prominent, and spindle cell proliferation can be observed around the skin appendages. Red blood cells are present in the slit-like spaces in association with occasional deposits of golden-brown hemosiderin granules either free or within macrophages.[1048]

The plaque stage is intermediate between the patch stage and the nodular or tumor stage, and it has some features of both. In its early phase, the plaques show more diffuse dermal

vascular infiltration along with greater cellularity and occasional extension into the underlying subcutaneous adipose tissue. A promontory sign may be seen, as in the patch stage. There are few mitotic figures and no significant nuclear or cytological pleomorphism. The initial confluence of the spindle cell proliferation within the more superficial dermis progresses to involve the deep dermis and/or subcutis. So-called autolumination may be seen in which an erythrocyte is contained within a clear perinuclear vacuole in the cytoplasm of a spindled endothelial cell. There can be extracellular hyaline globules. There is a chronic inflammatory cell infiltrate with numerous plasma cells admixed with hemosiderin laden macrophages and free hemosiderin granules. The lesions may show small clusters of capillary proliferations with rather plump endothelial cells. In these cases, differential diagnosis from chronic vascular stasis changes (stasis dermatitis) of the lower legs may be difficult. In stasis dermatitis, newly formed capillaries are located close to the epidermis, are surrounded by an edematous to fibrotic dermis, and are often accompanied by hemosiderin granules.[1047]

The patch and the plaque stages of KS both show chronic inflammatory infiltrates which may be perivascular and/or diffuse and of varying severity. These infiltrates consist of lymphoid cells, plasma cells, and some macrophages. As a result of these infiltrates, early lesions of KS may resemble granulation tissue. However, the presence of atypical spindle cells, large protruding endothelial cells, extravasated erythrocytes, hyaline globules, and hemosiderin pigment should suggest a diagnosis of KS.[1047]

The nodular, or tumor, stage of KS is characterized by the appearance of grossly visible red-purple nodules of varying sizes, usually 0.2 to 2 cm, on the skin. A solitary nodule may be present, but more likely there are multiple nodules that in severe cases may become confluent over a wide area. Microscopically, nodules are relatively circumscribed with a variable cellular proliferation of neoplastic spindled cells arranged in fascicles. Spindle cells are numerous and tend to be more monomorphic. Erythrocyte extravasation is pronounced, and hemosiderin pigment is abundant. Autolumination is present. Neoplastic cell phagocytosis of red blood cells leads to intracytoplasmic slits and formation of erythrophagosomes that form the hyaline globules seen by hematoxylin-eosin staining. The entire nodular lesion appears as a mass, though it rarely has discrete borders, and infiltration around adjacent adnexal structures or into underlying adipose tissue is common. The overlying epidermis is usually intact, but an ulcerated nodular lesion may be mistaken for a pyogenic granuloma. The periphery of some nodular lesions may show more dilated vascular spaces resembling a cavernous hemangioma.[1047,1049]

Advanced Kaposi sarcoma can be associated with chronic lymphedema. The clinical stage of KS may be difficult to assess when lymphedema is present. Grossly, the appearance may resemble a fibroma-like nodule. Microscopically, this variant of KS is characterized by epidermal hyperplasia, hyperkeratosis and fibrotic protuberances with a verrucous pattern of the skin surface. A transdermal increase in blood vessels, thick-walled lymphatic vessels, and fibroblasts may also be seen. This KS-associated lymphedema may be the result of lymphatic obstruction, venous obstruction, protein-rich interstitial fluid, tissue hemosiderin, and/or subcutaneous infection.[1050]

Immunohistochemical staining for endothelium-associated CD34 or CD31 antigens may provide a useful marker for identification of both vascular and spindle cell components of KS and help to confirm a diagnosis in some cases. The lymphatic endothelium does not contain CD34, but does mark with D2-40. The endothelial nuclei are positive for HHV-8 latent nuclear antigen 1 (LNA-1).



Factor VIII-related antigen will be found in the vascular portions of KS, but rarely in the spindle cell components. All KS cells will demonstrate positivity with immunohistochemical staining for vimentin. However, the tumor cells of KS do not always show positive staining for factor VIII-related antigen. Radiation or chemotherapeutic effect on KS may produce involutional changes including loss of atypical spindle cells, absence of vascular spaces, fibrosis, and extensive hemosiderin deposition. Flow cytometry of KS indicates that most are diploid, but a few demonstrate DNA aneuploidy. Mitotic counts are higher in more advanced stages of disease.[1051] Using the polymerase chain reaction to detect human herpesvirus-8 (HHV-8) will help in distinguishing the lesions of KS from other neoplastic spindle cell proliferations in cytologic samples.[1052]

The histologic appearances of KS can be helpful in assessment of prognosis in patients with AIDS. The appearance of an initial lesion on the lower extremities, presence of spindle-cell nodules, nodular form, absence of hemosiderin, and absence of irregular vascular spaces are all associated with increased survival. Nodular KS is associated with a 30-month survival, while patients with patch or plaque lesions survive for half this time or less. These findings are similar to survival curves with classic and endemic KS.[1053]

A diagnosis of KS in fine needle aspiration (FNA) cytology specimens can be challenging. Cytologic features of KS seen in FNA specimens may include tissue fragments of overlapping spindle cells, loosely cohesive clusters of spindle cells, individual cells, bare oval nuclei with fine chromatin, prominent nucleoli, elongated cytoplasm with vacuoles, and metachromatic background stroma on May-Grünwald-Giemsa (MGG) stain. Nodular spindle cell vascular transformation as well as mycobacterial spindle cell pseudotumor seen in lymph node can have similar features on FNA. Demonstrating the presence of HHV-8 may help to distinguish KS from other spindle cell proliferations.[664]

Histologic variations of KS have been described. Lesions of KS may contain acid-fast bacilli in patients infected with *Mycobacterium avium*-complex (MAC). These proliferations must be distinguished from the uncommon “mycobacterial pseudotumor” that contains MAC-infected macrophages forming a spindle cell proliferation. A fascicular arrangement of spindle cells with slit-like spaces, lack of granular eosinophilic cytoplasm, and presence of mitoses are features more consistent with KS. Additional KS patterns may include glomeruloid, telangiectatic, ecchymotic, lymphangioma-like, verrucous, keloidal, micronodular, bullous, myoid nodular, and pigmented. An anaplastic variant of KS is associated with a highly aggressive course poorly responsive to therapy. The presence of CD31 and CD34 and the absence of staining for CD68 and S100 by immunohistochemistry favors KS.[457,1047,1054,1055]

Differentiation between granulation tissue and KS may be a diagnostic problem, although the cells of the latter should show atypism. Non-neoplastic lesions that may partially mimic KS include: bacillary (epithelioid) angiomatosis, capillary hemangioma, sclerosing hemangioma, resolving dermal fasciitis, pyogenic granuloma, and papular angioplasia. Other vascular tumors resembling KS include spindle cell hemangioma and Kaposiform hemangioendothelioma. Other spindle cell neoplasms resembling KS include fibrohistiocytic tumors (cellular, angiomatoid and atypical variants of fibrous histiocytoma) dermatofibrosarcoma protuberans, spindle cell melanoma, cutaneous leiomyosarcoma, amelanotic melanoma, and spindle cell squamous cell carcinoma.[1047]

Antiretroviral therapy can be accompanied by regression of KS lesions. Features of regression of lesions include flattening, reduction in size, and change from a purple-red

appearance to an orange-brown macule. Microscopic features include greater circumscription of nodular lesions that are less cellular and are enveloped by a densely sclerotic stroma. KS lesions that have undergone complete regression show an absence of spindled cells, a modest increase in microvessels, hemosiderin-laden dermal macrophages, and a conspicuous superficial perivascular lymphocytic infiltrate. Partial or complete regression may also occur with chemotherapy.[1047]

An important point to remember is that in the absence of distinct features of KS, a conservative approach is recommended. Rather than mistakenly labeling a patient as having AIDS, it may be wise to obtain additional clinical information regarding HIV and immune status or defer a diagnosis of KS to a later date and repeat biopsy. A true lesion of KS will progress--with few exceptions--to a more diagnostic stage.

**OTHER SKIN NEOPLASMS.**— Since the advent of antiretroviral therapy (ART), non-AIDS defining cutaneous malignancies have become more frequent than Kaposi sarcoma among HIV-infected persons. These include basal cell carcinoma, malignant melanoma, and squamous cell carcinoma. Their appearance does not relate to CD4+ lymphocyte count or to use of ART. Risk factors are similar to those persons not infected with HIV: increasing age and white race.[1056]

Squamous epithelial dysplasias and malignancies are most frequent in the perianal region, though squamous cell carcinomas may appear elsewhere. The appearance of such lesions may be associated with concomitant human papillomavirus (HPV) infection, usually not high-risk subtypes, which is frequent in HIV-infected persons, particularly when there is a risk factor of anal intercourse with other males. The presence of the precursor lesion to anal SCC, the squamous intraepithelial lesion (SIL), has a prevalence of 36% in HIV-positive males who have sex with males, and 14% in women who are partners of these men. Persons with AIDS have a 3- to 5-fold increased risk of developing a nonmelanoma skin cancer. Squamous cell carcinoma (SCC) and basal cell carcinoma (BCC) in patients with HIV infection are similar to those seen in immunocompetent patients. The ratio of SCC to BCC in HIV-infected patients is approximately 1:7. Cutaneous SCC may be more aggressive with concomitant HIV infection, but BCC is not. Most BCCs are the superficial type presenting on the trunk as multiple lesions.[1057]

Melanocytic lesions have been reported in HIV-infected persons at a median age lower than the general population. Both dysplastic nevi and melanoma may occur in HIV-infected patients with no prior family history. There is a greater tendency for melanomas to have a greater depth and to metastasize sooner, compared to non-HIV-infected persons. The degree of immunosuppression, indicated by lower CD4 counts, appears to contribute to findings.[632,633]

Cutaneous T-cell lymphoma (CTCL) has been described in patients infected with HIV, but this entity is best termed atypical or pseudo-CTCL. Pseudo-CTCL is a lymphoproliferative disorder that appears identical to mycosis fungoides (MF), with erythematous patches, plaques, and tumors, or as a Sézary syndrome-like picture with erythroderma and circulating convoluted lymphocytes. Both Sézary and pseudo-Sézary syndromes have been described in HIV patients. Pseudo-CTCL may mimic other skin diseases, including persistent generalized eruption of erythematous papules, drug eruption, photodistributed eruption, or deep nodules and ulcers in the skin.<sup>56</sup> In most cases of MF or Sézary syndrome, the neoplastic cells are clonal, but in most pseudolymphomas, the proliferation is polyclonal. The typical microscopic finding is that of a psoriasiform, lichenoid pattern with limited infiltration of the epidermis by small lymphocytes

marking for CD4 or CD8. Since pseudo-CTCL is not a true lymphoma, chemotherapy is not recommended and therapy may consist of topical corticosteroids or psoralen ultraviolet A therapy.[1057]

**HERPESVIRUSES.**—Genital and anorectal herpes simplex virus (HSV) produces localized vesicles and ulcers that are chronic but cyclical in appearance and severity. They often respond to acyclovir therapy and may disappear following treatment. Grossly, most lesions appear as vesicles that contain fluid, but may rupture to produce shallow ulcerations.

A less common appearance, though one more likely to occur in immunocompromised persons, is hypertrophic herpes simplex genitalis (HHSg) and most often described in association with HIV-1 infection. The lesions appear as painful ulcerated nodular lesions of the vulva and perianal area that can measure up to several centimeters in diameter. Macroscopically, the lesions may appear as high-grade vulvar intraepithelial neoplasia Grade 3 (VIN 3) and invasive squamous cell carcinoma. The nodularity is produced by massive inflammatory infiltrates containing numerous plasma cells that extend into the subcutis. Multinucleated herpes simplex virus 1 and herpes simplex virus 2-positive epithelial cells with glassy intranuclear inclusions can be identified. The lesions can be resected can recur.[1058]

Varicella zoster virus (VZV) infections in association with HIV infection may resemble those typical of other immunocompromised patients. Children infected with HIV may have a severe primary VZV infection that can be fatal from internal organ involvement including pneumonitis, pancreatitis, and encephalitis. Adults with HIV infection have more extracutaneous organ involvement and risk for death from primary VZV infection. Development of dermatomal zoster is frequent in children with HIV and usually occurs in a few years. Dermatomal zoster is marked by painful vesicular eruptions, most commonly from the thoracic or cervical dorsal root ganglia or from the ophthalmic branch of the trigeminal ganglion. Less common presentations include follicular zoster and ecthymatous, crusted, or punched-out ulcerations. Chronic verrucous or ecthymatous VZV, resembling a wart caused by papillomavirus, may persist for weeks to months [503,1059,1060]

**MOLLUSCUM CONTAGIOSUM.**-- This double-stranded DNA virus of the poxvirus family may produce a self-limited cutaneous infection. It can appear in a widely disseminated form over the skin surfaces in persons with HIV infection. There can be cases with dozens of 0.2 to 0.6 cm firm tan to pink dome-shaped nodules or papules, or cases with fewer nodules but a wider size range up to 1 cm, or cases in which giant nodules >1 cm are found. The more florid verrucous form or cases of "giant" molluscum contagiosum with very large nodules can occur at a late stage of AIDS when the CD4 lymphocyte count is <50/ $\mu$ L and the plasma HIV-1 RNA level is >100,000 copies/mL.[1061,1062]

The nodules or papules may have central umbilication and can appear widely scattered or in clusters. HIV-infected patients with molluscum contagiosum are more likely to have head and neck involvement, typically the face, unlike immunocompetent patients in which lesions are most common on lower abdomen, genitalia, and thighs. Lesions may also appear less frequently on the trunk and extremities. Almost all cases occur in males.

The diagnosis can be confirmed by biopsy. The lesions of this poxvirus have the typical microscopic appearance with hematoxylin-eosin staining, with large prominent pink intracytoplasmic inclusions forming in lower epidermis and extending into a central cavity. Molluscum contagiosum infections associated with HIV-infection do not typically resolve

spontaneously and tend to have a chronic relapsing course. The lesions tend to be more extensive when the degree of immunosuppression is greater, as indicated by a lower CD4 count or increased HIV-1 RNA level.[1059]

**CRUSTED (NORWEGIAN) SCABIES.**-- Crusted (Norwegian) scabies, a highly contagious infestation of the mite *Sarcoptes scabiei*, can appear in patients with AIDS. Unlike skin involvement with acute eruption seen with ordinary scabies in immunocompetent persons, with crusted scabies the onset is insidious and the pattern of distribution of lesions involves scalp, face, back, and nails. In its classic form, there are severe extensive hyperkeratotic nonpruritic lesions that appear as horny plaques from 3 to 15 mm in size. Lesions may also appear as a papular, pruritic dermatitis. They can also be erythematous or psoriasiform. Microscopically, the hyperkeratotic, parakeratotic, and acanthotic lesions contain numerous mites in subcorneal burrows. The lesions can become secondarily infected, often with *Staphylococcus aureus*, with further complication of septicemia. Diagnosis is made by skin scraping, particularly with sampling under fingernails, and if negative, with biopsy of a non-excoriated region. Laboratory studies may reveal peripheral eosinophilia and elevated IgE levels in over half of patients. Treatment with scabicides is effective, but must be continued for a longer time frame than for ordinary cases of scabies. The lesions of crusted scabies are quite contagious and health care workers can become infected, so strict isolation and containment practices are needed.[1063,1064]

**BACILLARY ANGIOMATOSIS.** -- Bacillary angiomatosis, or epithelioid angiomatosis, is caused by fastidious gram-negative bacilli of the species *Bartonella henselae* (formerly *Rochalimaea henselae*). Clinically, this lesion may appear as multiple violaceous subcutaneous nodules or angiomatous papules. Histologically it is characterized by a pseudoneoplastic proliferation of dilated vascular channels in a circumscribed pattern resembling a pyogenic granuloma, but is distinguished by the presence of large plump, protuberant, occasionally atypical endothelial cells. These endothelial cells have an “epithelioid-like” appearance and often project into vessel lumens to give a tombstone-like appearance. The lesion differs from Kaposi sarcoma by the presence of neutrophils with leukocytoclasia, by the absence of spindle cells or hyaline globules, and by resolution with antibiotic therapy (erythromycin).[530,546,1065]

**ACUTE HIV INFECTION.** -- More than half of persons have symptoms associated with initial HIV infection, known as acute retroviral syndrome, though these manifestations are non-specific and resemble a flu-like illness or infectious mononucleosis-like illness.[207] About 75% of persons with acute retroviral syndrome will develop cutaneous manifestations, typically an exanthem characterized by erythematous papules and macules on trunk and extremities, and sometimes the palms and soles. This rash lasts for about 4 to 5 days and then resolves completely. Seroconversion occurs later.[1059]

**BACTERIAL INFECTIONS.**-- *Staphylococcus aureus* is the most common cutaneous bacterial pathogen in HIV-infected patients, because of significant rates of nasal carriage of *S. aureus*. Staphylococcal infection may produce furuncles, carbuncles, or abscesses characterized by erythematous, tender, and indurated lesions. Impetigo may exhibit honey-colored crusts or bullous lesions. The term botryomycosis describes a chronic, granulomatous, suppurative *S.*

*aureus* infection that usually occurs following skin trauma and causes subcutaneous nodules to plaques with ulcers, purulent secretions, fistulae, and “sulfur like” grains in secretions. Lesions of botryomycosis may be found in the scalp, axilla, and groin and may involve underlying muscles, tendons, and bones by direct extension.[1060]

*Staphylococcus* may be a superimposed infection of prior eczema, scabies, herpetic ulcer, Kaposi sarcoma, or catheter. HIV-infected patients are susceptible to staphylococcal cellulitis. Local staphylococcal infection may be complicated by bacteremia or sepsis. Diagnosis is aided by gram stain of pus. The culture of a biopsy specimen in cellulitis is positive in only one quarter of patients. Risk factors include indwelling catheters, injection drug use, malnutrition, encephalopathy, diminished antibody response, diminished B-cell mitogenic response, immunoglobulin G subclass deficiencies, and neutrophil and macrophage abnormalities.[1060,1066]

**PROTOTHECOSIS.**-- Cutaneous protothecosis is caused by an achlorophyllic algae of the species *Prototheca*, considered mutants of the green alga genus *Chlorella*. Infections occur mainly in immunocompromised individuals, including HIV infection, and are most often caused by *Prototheca wickerhamii*. The incubation period may be weeks to months. At least one-half of infectious cases are cutaneous, but deep soft tissues can be involved, leading to a chronic, indolent infections. Cutaneous protothecosis shares similar clinical and pathologic findings with deep tissue fungal mycoses. The typical presentation occurs most commonly on the face and extremities as erythematous plaques, nodules, or superficial ulcers. Treatment may require a combination of surgical excision and antifungal agents.[1067]

The organisms are spherical, unicellular, nonbudding organisms from 3 to 30  $\mu\text{m}$  in size. They appear as sporangia with thick, double-layer walls filled with multiple endospores. They reproduce asexually through internal septation and release the endospores when the parent cell ruptures. They may be seen on biopsy and are best visualized with periodic acid–Schiff and Gomori methenamine-silver stains. Microbiologic culture is needed for definitive diagnosis. Biopsies may show a pandermal granulomatous inflammatory infiltrate containing lymphocytes, neutrophils, and eosinophils. Necrosis may be observed within the granulomas; multinucleated giant cells and plasma cells are usually present. A minimal inflammatory response may be seen in some cases. Additional findings include hyperkeratosis and parakeratosis, pseudoepitheliomatous epidermal hyperplasia, and lymphoid hyperplasia.

**DRUG REACTIONS.**-- Drug hypersensitivity eruptions or reactions commonly occur during treatment regimens for HIV infection and related conditions. Over three-fourths of patients with HIV infection have at least one dermatologic diagnosis made while receiving health care, and the frequency of such diagnoses increases as HIV infection progresses. About 8% of all dermatologic conditions seen in patients with HIV infection are drug reactions. The drugs with the highest rate of reactions seen are trimethoprim-sulfamethoxazole (over half of patients receiving this drug), sulfadiazine, trimethoprim-dapsone, aminopenicillins, and antituberculous medications.[1059,1068]

The grossly visible lesions of drug reactions are most commonly morbilliform eruptions of erythematous papules and macules on the trunk and extremities. Less frequently, erythema multiforme with reddish papules and target-like lesions may occur on palms and soles. Other infrequent patterns of involvement include Stevens-Johnson syndrome and toxic epidermal necrolysis.[278,283,1059,1068]

Immune reconstitution inflammatory syndrome (IRIS) following institution of antiretroviral therapy may lead to granuloma formation in association with either infectious or non-infectious conditions. Non-caseating cutaneous granulomas similar to sarcoidosis may occur. Non-infectious conditions associated with foreign body granulomatous reactions with IRIS may include traumatic injuries, tattoos, injection drug use sites, autoimmune diseases, and vasculitis. Infectious agents produce granulomatous inflammation, and they must be diagnosed by histologic stains or by culture methods. Antiretroviral therapy with on-nucleoside reverse transcriptase inhibitor agents and/or protease inhibitors may induce a cutaneous rash about 10% of the time, ranging from morbilliform exanthems to toxic epidermal necrolysis (TEN) and Stevens-Johnson syndrome (STS).[1069]

**PAPULOSQUAMOUS DERMATOSES.--** A variety of papulosquamous dermatoses may occur in persons with HIV infection, particularly with CD4 lymphocyte counts less than  $150/\mu\text{L}$ . The most common condition seen in HIV-infected persons is seborrheic dermatitis, which can occur at some point in up to 80 to 85% of this population, but only 4% of the general population. The lesions appear as yellow to white scaly, greasy scales on erythematous patches or plaques on scalp, eyebrows, nasolabial folds, and posterior auricular regions where sebaceous gland activity can be increased. Microscopically, atypical features not seen in seborrheic dermatitis of immunocompetent persons include pronounced hyperkeratosis with parakeratosis, follicular plugging, acanthosis, spongiosis, lymphocyte and neutrophil exocytosis along with dyskeratosis and keratinocyte necrosis. In patients with HIV infection, seborrheic dermatitis tends to have a more rapid onset and be more extensive and severe than in immunocompromised patients. Though it can occur at any stage of HIV infection, it is more likely to appear with declining CD4 cell counts. Previously limited lesions may acutely become more severe and extensive. Topical corticosteroid therapy can be effective therapy.[1059,1070]

Pruritus alone is a frequent accompaniment of advancing HIV infection, particularly when CD4 counts drop below  $50/\mu\text{L}$ . This can be idiopathic, or part of a condition with more specific findings.[1070] An intensely pruritic papular eruption has been observed in HIV infected persons, termed pruritic papular eruption (PPE). It is characterized by symmetrically distributed papules with pruritus in the skin. This eruption consists of 2 to 8 mm erythematous papules that become excoriated, leading to larger papules and nodules up to 1 cm, with marked lichenification and hyperpigmentation. PPE-HIV occurs mainly in persons with HIV who have mean CD4 lymphocyte counts of less than  $200/\mu\text{L}$ . Eosinophil counts are significantly increased and plasma IgE levels are elevated. The density of CD8+ lymphocytes is increased while the density of CD4+ cells is decreased in dermal infiltrates. Interleukin 5 is the predominant cytokine identified in the lesions. The CD8 lymphocytes and Langerhans cells appear to play a role in the pathogenesis of PPE-HIV. The increased frequency of IL5 associated with abundant eosinophils in the lesions suggests a Th2 immune response in this form of dermatitis.[1071] PPE skin lesions microscopically resemble an insect bite, with superficial and deep perivascular interstitial lymphohistiocytic and eosinophilic inflammatory infiltrates, with Langerhans cells normally distributed in the epidermis and seen among the cellular components of dermal infiltrates.[1069,1072]

Eosinophilic folliculitis seen in patients with HIV infection typically occurs in the advanced stage or with immune restoration. It may be part of the same spectrum of disease as pruritic papular eruption. It presents as a chronic eruption of 2 to 3 millimeter intensely pruritic follicular papules in the head, neck, trunk, and upper arm regions. On biopsy, there is a

folliculocentric predominance of eosinophils and lymphocytes, with frequently associated lysis of the sebaceous gland. Secondary changes include excoriation, prurigo nodularis, and lichen simplex chronicus. Histologically, this eruption is distinguished from suppurative folliculitis caused by bacteria such as *Staphylococcus aureus* by the lack of neutrophilic infiltrates and the predominance of lymphocytes and/or eosinophils at the follicular isthmus and sebaceous gland duct. Though infectious organisms may be identified in conjunction with eosinophilic folliculitis, they are considered non-pathogenic. However, treatment that give more than transient relief, such as corticosteroids, have included permethrin and itraconazole.[1070,1072]

Psoriasis affects 2% to 5% of patients with HIV infection but only 1% of the general population. Up to 10% of affected HIV infected persons may also develop arthritis. It can be more severe, particularly with decreasing CD4 counts. A sudden onset, or an acute exacerbation of stable disease, is more likely in the setting of HIV infection. There may be more than one clinical pattern simultaneously, or the course may be complicated by exfoliative erythroderma. Microscopic findings are similar to psoriasis in immunocompetent persons, but atypical features with HIV can include fewer Munro microabscesses, irregular acanthosis, and less pronounced thinning of the suprabasal plate. Therapies are similar to non-HIV-infected cases and include phototherapy, emollients, and retinoids. Methotrexate therapy may exacerbate immune dysregulation.[1059,1070] HIV-infected persons may be refractory to traditional therapies for psoriasis, and they may have significant psoriatic arthritis.[1073]

Reactive arthritis is increased in frequency and severity in association with HIV infection; it has been reported in 4 to 10% of HIV infected persons. Persons with HLA-B27 are more likely to develop this disease. It includes the findings of arthritis, uveitis, and conjunctivitis, though only two of the three may be present in HIV-infected persons. The most characteristic appearance is a palmoplantar pustular dermatosis that may be associated with nail dystrophy, periungual erythema, and hyperkeratosis. The lesions initially present as erythematous macules, and over the course of several days, these become hyperkeratotic, waxy papules associated with an erythematous halo. Multiple papules coalesce and eventually form thickened horny plaques. The distribution of these hyperkeratotic lesions is on the palms and soles and less commonly involving the trunk and proximal extremities. Microscopically, lesions resembling those of pustular psoriasis may be present, and treatment modalities are similar to psoriasis. A relapsing course is common.[1074,1070]

Xerosis generalisata, or dry skin syndrome, may be present in up to 30% of HIV infected patients and is characterized by fine diffuse hyperpigmented scaling and crusting with severe pruritus unresponsive to antihistaminic therapy. Histologically xerosis resembles irritant contact dermatitis. Other findings have included palmoplantar keratoderma, ichthyosis, and eczematous dermatitis. Emollients have been employed as therapy.[1068,1070]

Atopic dermatitis manifests as erythematous scaling plaques with associated papules or vesicles. Affected persons may also have asthma, allergic rhinitis, and allergic conjunctivitis. The intense pruritus can lead to secondary changes from excoriation of infection, as well as lichenification with lichen simplex chronicus. On biopsy, there is a superficial perivascular infiltrate of lymphocytes and eosinophils together with epidermal hyperplasia and foci of spongiosis. Laboratory findings often include an elevated IgE and peripheral eosinophilia. Emollients, topical corticosteroids, oral antihistamines, and phototherapy have been used to treat atopic dermatitis.[1070]

ONYCHOMYCOSIS.-- The superficial mycoses are common, and the term

onychomycosis refers to infection of nails. Risk factors include male sex, active sports participation, commercial swimming pools, occlusive footwear, trauma, smoking, and psoriasis. Toenails are more frequently affected than fingernails because they grow three times slower. The five major clinical presentations of onychomycosis include:[1075]

- Distal and lateral subungual onychomycosis
- Proximal subungual onychomycosis
- Superficial white onychomycosis
- Endonyx
- Total dystrophic onychomycosis

Dermatophytes cause 90% toenail and 50% of fingernail infections, and the most common species is *Trichophyton rubrum*, followed by *T. mentagrophytes*. Dermatophyte invasion of the nail plate is termed tinea unguium. Nondermatophyte molds (NDM) cause 1.5 to 6% of all onychomycosis in two categories: (1) isolated from nails as organisms including *Scytalidium dimidiatum* and *Scytalidium hyalinum*; (2) opportunistic fungi that may also be isolated as contaminants, such as *Scopulariopsis brevicaulis*, *Aspergillus sydowii*, and *Onychocola canadensis*. Yeasts may cause fingernail infections. More than 70% are due to *Candida albicans*. Other species include *C. parapsilosis*, *C. tropicalis*, and *C. krusei*. [1075]

NDM such as *Acremonium* species can invade the nail surface, while others such as *Scytalidium* species are more often associated with distal and lateral subungual onychomycosis. Molds are considered pathogens when the following criteria are fulfilled:[1075]

- Nail abnormalities consistent with the diagnosis.
- Positive direct microscopy visualizing hyphae in the nail keratin.
- Failure to isolate a dermatophyte in the culture
- Growth of >5 colonies of the same mold in at least two consecutive nail samplings.

Rapid diagnosis is made by nail scraping and direct microscopy of a KOH preparation. Additional histologic stains include PAS and GMS. Definitive diagnosis is made with culture.[1075]

**ADDITIONAL FUNGAL INFECTIONS.--** Up to 20% of HIV-infected persons may develop an infection with one of the dermatophytes, typically at later stages of HIV infection. These infections, also known as ringworm or tinea, are caused by superficial fungal species in the genera *Trichophyton*, *Microsporum*, and *Epidermophyton*. Lesions are most commonly located on hands, feet, and groin region. *Trichophyton rubrum* is the most commonly identified dermatophyte. Tinea pedis, the most common form of dermatophytosis, is usually of the moccasin type, though the interdigital form is common, and the vesicular form infrequent.[1066,1076]

Tinea cruris or pedis may spread to produce tinea corporis, typically with truncal involvement. Even the penis and scrotum may be affected. The gross appearance is that of well-defined erythematous, scaly patches that are sometimes hyperkeratotic. In severely immunocompromised patients, lesions may have little inflammation and lack the elevated border and central clearing typical of tinea; instead, they are seen as sharply margined areas of hyperkeratosis resembling dry skin. Diagnosis can be made by examination of skin scrapings on



a glass slide KOH mount. Treatment with topical antifungal creams may be helpful in treating tinea, as can oral griseofulvin or oral imidazoles.[1059,1076]

Tinea unguium involves both toenails and fingernails to produce onychomycosis. Though proximal white subungual onychomycosis is rare in immune competent persons, it is a marker for HIV infection. In this form, fungal elements spread under the proximal nail fold to establish an infection of the nail bed that spreads distally. This produces a white hue under the proximal nail plate in the region of the lunula. Long-term treatment with fluconazole and itraconazole can be effective treatment.[1076]

Non-dermatophyte infections with *Malassezia furfur* may be associated with some cases of seborrheic dermatitis, with pityriasis versicolor, and with *Malassezia* folliculitis. Antifungal therapy with ketoconazole may be effective therapy.[1076]

Superficial *Candida* infections can occur in HIV-infected persons, though oral candidiasis is far more frequent. The most common form of involvement of the skin is in intertriginous areas of groin or axilla. The hallmark of *Candida* intertrigo is the presence of satellite pustules. Pruritus ani can result from mixed infections with both bacterial and fungal organisms. Topical antifungal creams can help treat these superficial infections.[1076]

The appearance of lesions of the skin may correlate with the level of immunosuppression. Seborrheic dermatitis and onychomycosis tend to occur in the early stages of HIV infection when the CD4 lymphocyte count is above 400/ $\mu$ L. Candidiasis and pruritus ani are more likely to appear when HIV infection has become symptomatic and the CD4 count is between 200 and 400/ $\mu$ L. Eosinophilic folliculitis typically occurs in association with clinical AIDS and CD4 counts below 200/ $\mu$ L.[1076]

Cryptococcal skin involvement may present in as many as 10 to 20% of patients with disseminated disease. The lesions are most often seen on the face, neck and scalp as erythematous papules, though pustules and umbilicated papules resembling molluscum contagiosum can be seen. Additional presentations include cellulitis, erythematous papules, nodules, pustules, and ulcers. Similar findings may be seen with disseminated coccidioidomycosis, where cutaneous morbilliform eruptions, papules, pustules, violaceous or ulcerating plaques, and nodules have been described.[1060] The presence of capsule deficient forms of *C neoformans* makes recognition difficult. Partially treated *C neoformans* may give rise to an inflammatory pseudotumor that mimics that of myofibroblastic tumor and infection with *Mycobacterium avium*-complex, but few organisms are typically present.[1069]

Histoplasmosis that involves skin and mucous membranes typically occurs in the advanced stage of AIDS when the CD4 lymphocyte count is below 150/ $\mu$ L. The morphologic appearances of mucocutaneous lesions can include nodules, plaques, vesicles, hemorrhagic macules, papules, and pustules, with or without ulceration. Erythematous scaly plaques, pyoderma gangrenosum-like lesions, erythroderma, cellulitis, petechiae, purpura, ecchymoses, and necrotizing vasculitis also have been described. Additional clinical findings include weight loss, fever, chills, lymphadenopathy, hepatosplenomegaly, and anemia. Pathologic findings with skin biopsy may include: (1) necrotizing and non-necrotizing granulomatous inflammation with a paucity of intra histiocytic microorganisms, (2) diffuse dermal and intravascular accumulation of macrophages densely parasitized by *H capsulatum*, and (3) diffuse dermal karyorrhexis, collagen necrosis and interstitial, extracellular *H capsulatum*. The skin lesions may respond dramatically to treatment with antifungal therapy.[1060,1077]

**CUTANEOUS LEISHMANIASIS.**-- Leishmaniasis involving the skin may occur as localized cutaneous leishmaniasis (LCL), diffuse cutaneous leishmaniasis (DCL), disseminated leishmaniasis, leishmaniasis recidiva cutis (LR), and mucosal leishmaniasis. In patients with HIV infection, a wide morphologic appearance of lesions can occur, including papules, nodules, plaques, and ulcerations. Leishmaniasis with newly disseminated lesions appearing or worsening may be a manifestation of an immune reconstitution inflammatory syndrome.[555]

LCL is the most form and may be caused by all of the dermatropic *Leishmania* species such as *L major* and *L tropica*. Clinically, 1 to 10 painless, pink, and round ulcerated lesions appear on an exposed area of the body. The ulcer is usually well delimited and has raised edges, an indurated base, and a clean base with overlying central crust that may bleed. Lesions may spontaneously resolve to leave a hypopigmented, smooth, thin scar. Lesions may also evolve to other forms of the disease. DCL is a rare condition evolving from LCL that occurs with anergy, so that reduced immune response results in lesions that are full of organisms. There is diffuse cutaneous infiltration but no ulceration. The most likely species to cause DCL are species involved *L mexicana* and *L amazonensis* in the New World and *L aethiopica* in the Old World.[555]

The LR form is most often found in the Old World and associated with *L tropica* infection, but cases in the New World are likely caused by *L braziliensis* and *L amazonensis* in Brazil and *L panamensis* in Ecuador. Hematogenous or lymphatic spread can lead to disseminated leishmaniasis (DL) with 1 to 300 pleomorphic acneiform, ulcerated, and papular lesions in 2 or more noncontiguous areas of the body. The mucosa is affected in 29% of cases.[555]

Mucosal leishmaniasis (ML) along with a cutaneous manifestation is called mucocutaneous leishmaniasis. ML usually occurs months or years after cutaneous leishmaniasis and primarily affects the nasal mucosa. Clinical features include nasal pruritus that progresses to crust formation and bleeding. Features include nasal inflammation and congestion of the nostrils with pruritus that can slowly progress to ulceration and perforation of the nasal septum. The oral mucosa can also be affected as well as face, soft palate, pharynx, and larynx. The causative species include *L braziliensis* in the New World as well as *L panamensis*, *L guyanensis*, and *L amazonensis*. In the Old World, ML can be caused by *L major* and viscerotropic *L infantum*.[555]

**MISCELLANEOUS FINDINGS.**-- Infectious and inflammatory dermatologic diseases are more likely to require medical attention and hospitalization in patients with AIDS than in patients without AIDS. Opportunistic infectious agents in AIDS with widespread dissemination, including fungal infections and *Pneumocystis*, may involve the skin and may produce appearances that can sometimes mimic KS or herpetic ulcers.[1066]

Acanthamebiasis, though rare, is most likely to involve the skin in patients with AIDS and can lead to the appearance of pustules, indurated papules or plaques, ulcers, and cellulitis.[581]

Hansen disease (leprosy) does not appear to occur more frequently in persons infected with HIV, even in areas where Hansen disease is endemic, nor is there an increased HIV prevalence among leprosy cases. There does not appear to be an alteration in clinical spectrum of leprosy among coinfecting patients. HIV does not appear to accelerate existing *Mycobacterium leprae* infections. Borderline tuberculoid leprosy is the most common clinical form. However, some patients may have less common chronic, hyperkeratotic, eczematous lesions. Interestingly, persons with a low CD4 lymphocyte count appear able to maintain a granulomatous response to

*M leprae*. Use of antiretroviral therapy appears to reduce numbers of *M leprae* organisms. However, some patients have a worsened course from immune reconstitution inflammatory syndrome (IRIS).[1078,1079]

Syphilis from infection with *Treponema pallidum* may present as a primary form with chancre and as a secondary form with maculopapular rash. Persons with HIV infection are more likely to exhibit lues maligna with secondary syphilis. Lues maligna (ulceronodular syphilis) exhibits a papulopustular skin lesion with well-demarcated borders, sometimes covered with a lamellar crust.[1080]

Skin lesions are characteristic findings of *Mycobacterium haemophilum* infection. These lesions tend to cluster on extremities and over joints where cooler ambient temperatures favor growth of these organisms. Septicemia is common, and the hematogenous dissemination allows *M haemophilum* to be cultured from a variety of body fluids and tissue sites. Joint involvement may produce arthralgia.[483] *Mycobacterium fortuitum* infection may present as subcutaneous nodules with necrosis in persons whose risk factor for HIV infection is injection drug use. Other mycobacterioses seen with AIDS such as *M avium* complex and *M tuberculosis* are unlikely to have cutaneous involvement.[1059]

Skin testing that relies upon delayed-type hypersensitivity reactions can still be performed in HIV-infected persons. For children, the skin test reactions are qualitatively very similar to those seen in age-matched control subjects, though anergy with loss of responsiveness suggests a progression to AIDS. In adults with AIDS, the interpretation of tuberculin skin testing may need to be modified due to partial loss of cell-mediated immunity. About 10% of persons with a CD4 lymphocyte count  $>500/\mu\text{L}$  are likely to exhibit anergy, though a positive test in HIV-infected persons should be defined as any area of induration  $>0.5$  cm (or  $>0.2$  cm for injection drug users).[223,254]

Cutaneous lymphomas can be seen with AIDS, typically at a later stage of disease. They are either CD30+ T-cell lymphomas or diffuse large B-cell lymphoma. Mycosis fungoides is rare in persons with AIDS. Cutaneous lymphomas in AIDS are typically localized nodules.[617] Late in the course of AIDS, cutaneous eruptions termed pseudolymphomas that histologically consist of a dense infiltrate of lymphocytes resembling cutaneous T-cell lymphoma may occur. Grossly they may mimic mycosis fungoides with erythroderma, disseminated papules, pustules, plaques, or nodules. However, the CD8 lymphocytes that comprise these infiltrates are polyclonal and accompanied by eosinophils, plasma cells and rare neutrophils. The pseudolymphoma may have a psoriasiform lichenoid pattern with limited epidermal infiltration by small lymphocytes, a superficial and deep perivascular and perifollicular pattern or an interface pattern with normal epidermal thickness.[1069]

Multiple eruptive dermatofibromas (MEDF) can rarely be seen in patients with HIV infection, as well as with other autoimmune diseases and in persons receiving immunosuppressive therapy. These lesions most often appear on the extremities and the trunk. Most have been reported in males. Histologically, they are similar to dermatofibromas seen in patients without HIV infection.[1081]

## PANCREAS IN AIDS

The pancreas in persons with AIDS may show opportunistic infections or neoplasms, evidence of recent or remote pancreatitis with hyperamylasemia, and acinar dilation. Opportunistic infections include mycobacteriosis, toxoplasmosis, cytomegalovirus (CMV), cryptococcosis, and pneumocystosis. Malignant lymphoma involves the pancreas in AIDS about twice as often as Kaposi sarcoma (Table 5). In general, life-threatening pancreatic lesions are uncommon in AIDS and most opportunistic infections and neoplasms occur in pancreas in the setting of widespread dissemination. Non-specific pathologic changes may be seen in the pancreas in up to 90% of persons with AIDS. These changes may include acinar atrophy, decreased acinar cell zymogen granules, acinar nuclear abnormalities, steatosis with increased lipid droplets in acinar cytoplasm, and focal necrosis. The acinar atrophy and steatosis suggest a nutritional problem. [1082,1083]

Pancreatitis in patients with AIDS may be accompanied by hyperamylasemia and hyperuricemia that represents the effect of renal insufficiency or macroamylasemia associated with polyclonal gammopathy from B-lymphocyte activation. Serum amylase and lipase can be performed along with radiologic imaging procedures to demonstrate an enlarged pancreas and heterogenous peripancreatic tissue. Pancreatitis can occur in association with opportunistic infections involving the pancreas, particularly cytomegalovirus.[1082]

Despite the prevalence of tuberculosis worldwide, pancreatic tuberculosis with HIV infection is rare. The most common presentation of fever and abdominal pain is non-specific. Pancreatic tuberculosis tends to masquerade as a pancreatic malignancy, cystic tumor, or pseudocyst. Microscopically, granuloma formation is poor, but acid-fast organisms are numerous.[1084]

Risk factors for pancreatitis include antiretroviral therapy involving any of the following: didanosine, stavudine, lamivudine, and protease inhibitors. Additional drugs implicated include pentamidine, cotrimoxazole, antimycobacterials, and chemotherapy agents. Additional risk factors typical of pancreatitis regardless of HIV status include alcohol abuse, biliary tract disease, and hypertriglyceridemia. Most AIDS patients with acute pancreatitis do not have a severe course, and the prevalence of severe disease is similar to that of the general population, even though the etiologies may be different.[282,1085]

Pancreatic ductal changes may be observed in half of AIDS patients undergoing endoscopic retrograde pancreatography (ERCP). These changes, which resemble those of pancreatitis, are often seen in association with AIDS-related sclerosing cholangitis. The observed abnormalities may include dilations, short stenoses of the main pancreatic duct, and irregularities in side branches, all features that are suggestive of chronic pancreatitis. The serum amylase may be increased in these cases. Infection of the pancreatic or hepatobiliary ducts by CMV, cryptosporidiosis, microsporidiosis, or mycobacteria may produce irregular ductular narrowing and dilation, which may resemble sclerosing cholangitis.[1086]

Pediatric patients may have nonspecific pancreatic changes including edema, inflammation, fibrosis, ductular and acinar inspissated secretions, and macronesia. Though acute pancreatitis is reported in 17% of pediatric patients with AIDS, histologic changes of acute and chronic pancreatitis are typically mild at autopsy. Involvement by opportunistic infections is focal and rare.[1087]

Antiretroviral therapy may account for some cases of pancreatitis. The use of nucleoside reverse transcriptase inhibitors, including lamuvidine, didanosine, and stavudine have been reported to produce pancreatitis, particularly when used along with pentamidine, cotrimoxazole, antitubercular therapy, and cytotoxic chemotherapy. The risk for pancreatitis increases following 6 months of drug therapy. The use of didanosine may produce the most severe pancreatitis.[282,1085]

Pentamidine administered either intravenously or by aerosol for treatment of *P jiroveci* (*carinii*), can sometimes produce acute necrotizing pancreatitis, even after months of aerosolized pentamidine therapy, and can be potentiated by further intravenous pentamidine therapy with higher systemic drug levels. Abdominal pain, along with increased serum amylase, suggests pancreatitis, which can recur when pentamidine is given again. In some cases, the onset may be rapid and the course short, ending in death. A grossly black to reddish-black pancreas with extensive necrosis but without extensive edema, fat necrosis, or hemorrhage is typical, and microscopic neutrophilic infiltrates may be minimal.[1088]

Pentamidine may also cause either hypo- or hyperglycemia. Hypoglycemia results from malfunctioning beta cells in the islets of Langerhans and may be seen in up to one third of treated patients from one to several weeks after initiating therapy. Abnormalities in regulation of glucose are more frequently observed when there is also pentamidine-induced nephrotoxicity.[941,1082]

Trimethoprim-sulfamethoxazole may produce pancreatitis. The antiretroviral drugs didanosine, zalcitabine, and stavudine can also cause acute pancreatitis, as evidenced by increased serum amylase and abdominal pain, and the risk increases with cumulative dose.[283] Patients at risk for drug-induced pancreatitis include those with previous pancreatitis, prolonged or high-dose therapy, additional pancreaticotoxic medications, and advanced stage of HIV.[278,1082]

## PREGNANCY AND THE PLACENTA IN AIDS

HIV infected women should be monitored with viral loads every month until the virus is undetectable and then every 2–3 months, along with CD4 counts each trimester. Resistance testing can be done if they have recently seroconverted or if they have failed therapy. HIV infected women in labor can be treated with either: 1) zidovudine in labor and 6 weeks to the neonate, 2) nevirapine, a single dose to the mother in labor and a single dose to the neonate, 3) zidovudine–lamivudine in labor and to the neonate for 1 week, or 4) both nevirapine as above and the zidovudine regimen as above. Cesarean delivery should be recommended to all women with an HIV-1 viral load greater than 1000 copies/mL. Discontinuation of antiretroviral therapy in the postpartum period is appropriate in those circumstances in which it would not have been used in the first instance if the woman had not been pregnant.[317] The use of nevirapine during labor to prevent perinatal HIV transmission has been shown to increase the rate of virologic resistance, but only when antiretroviral regimens including nevirapine were instituted within 6 months following delivery.[1089]

There is no solid evidence to suggest that pregnancy accelerates the progression of HIV infection to AIDS in women, though pregnancy increases the infectivity of women to sexual partners.[234,1090] Pregnancies in HIV-infected women are more likely to result in prematurity, intrauterine growth retardation, spontaneous abortion, and perinatal death. The 50% rate of HIV infection in stillbirths from HIV-infected mothers is much greater than that for liveborns, suggesting that fetal HIV infection increases fetal demise.[1091]

The placenta in mothers with HIV infection has been shown by immunocytochemistry and *in situ* hybridization to contain HIV-1 antigen by 8 weeks gestational age. Placental tissue also contains cells with CD4 receptors, and HIV infection can occur with transplacental spread of HIV to the fetus. Vertical transmission may occur through either endothelial tissues or Hofbauer cells that have CD4 receptors. Trophoblasts also have CD4 receptors, and placental cytokines and chemokines influence HIV replication within trophoblasts. The CCR5 strain of HIV-1 appears to be preferentially transmitted through the placenta.[1092]

The histology of the placenta does not appear to be altered by HIV infection. The most common inflammatory lesion is chorioamnionitis, observed in a third of cases. The most common non-inflammatory lesion is cytotrophoblastic hyperplasia, observed in about three-fourths of cases. Antiretroviral therapy does not appear to diminish the incidence of these lesions.[1093]

The risk for perinatal HIV infection is increased when chorioamnionitis, plasmacellular deciduitis, and decidual cell necrosis is present.[194,1094] When placental infection with malarial parasites is present, then the risk of mother-to-child transmission of HIV increases.[1095] An immune restoration syndrome in pregnant women starting antiretroviral therapy may lead to placental villitis and fetal loss.[1096]

Very rarely, opportunistic infections have occurred in placenta of mothers with AIDS. Placental cryptococcosis may be manifested grossly as multiple white nodules and microscopically by numerous encapsulated budding yeasts in the intervillous spaces and chorionic villi.[1097]

## HEAD AND NECK PATHOLOGY IN AIDS

Though HIV can be found in both tears and saliva, the lacrimal glands and the salivary glands do not show specific pathologic lesions in persons with HIV infection. The most common clinical findings suggestive of salivary gland abnormalities include gland enlargement and xerostomia. These findings are similar to those seen with Sjögren syndrome. Patients with these lesions may not have reached the stage of clinical AIDS. Xerostomia has been reported in 2 to 10% of HIV-infected persons.[753]

Enlargement of major salivary glands is seen in 3 to 6% of HIV-infected adult patients but up to 10% of HIV-infected children. Persistent generalized lymphadenopathy (PGL) that affects lymphoid tissue in HIV infection can also affect intraparotid lymphoid tissue and lead to parotid enlargement. There is a spectrum of cystic lymphoid hyperplasia, and lymph nodes, salivary gland, or both may be involved. The slow enlargement of the parotid gland may also be termed benign lymphoepithelial lesion (BLEL). Such lesions may be bilateral, multiple, variably sized, and may be accompanied by cervical lymphadenopathy. These lesions are thought to arise from hyperplasia of intraparotid lymphoid tissue that traps small intraparotid ducts, causing obstruction and dilation with cystic change and enlargement that can reach 5 cm in diameter. These cystic lesions are termed benign lymphoepithelial cysts (BLEC). The cyst epithelium can show squamous metaplasia. The gland can show lymphoid follicular hyperplasia, glandular atrophy, and myoepithelial islands.[902,1098,1099]

Fine needle aspiration (FNA) cytology of a lymphoepithelial cyst yields usually yields yellow fluid, but sometimes bloody or turbid fluid. Microscopic findings can mimic Sjögren syndrome and include anucleate squames, lymphoid follicle center cells, and macrophages. The surrounding salivary gland tissue typically demonstrates lymphoid infiltrates with cystic dilation of gland ducts lined by pseudostratified squamous epithelium. The lymphoid hyperplasia may appear atypical; germinal centers may appear serpentine, and there can be follicular lysis. Adjacent salivary gland tissue may have duct ectasia and glandular atrophy. The histologic features are similar to those lesions seen in non-HIV-infected persons.[664,1098,1100] Chronic, non-specific sialadenitis occurs in a fourth of patients. The most common opportunistic infections diagnosed in salivary glands include mycobacteria, cytomegalovirus, and cryptococci.[1101]

Other lymphoid lesions may occur. The entity known as diffuse infiltrative lymphocytosis syndrome (DILS) typically involves the parotid glands bilaterally, leading to facial swelling and sicca symptoms. The submandibular glands are involved in half of cases, while the lacrimal glands are involved in a third of cases. This condition results from an extensive parotid infiltration by CD8 lymphocytes, which can mimic Sjögren syndrome, or even lymphoma. Other visceral organs may also be involved. In addition, lymphocytic interstitial pneumonitis (LIP) is present in a third of cases, while myopathy may be seen in a fourth of patients with DILS. This condition can present before the onset of clinical AIDS in HIV-infected persons.[621]

Kaposi sarcoma (KS) can rarely involve submandibular and parotid salivary glands and produce gland enlargement. The histologic appearance is similar to KS seen elsewhere, with atypical spindle cells lining slit-like vascular channels, extravasated red blood cells, and hyaline globules. The lesions are invasive.[1102]

Airway obstruction, pharyngitis, and fever because of enlargement of adenoids and tonsils. This is due to florid lymphoid hyperplasia. Histologic findings include florid follicular hyperplasia, follicular lysis, an attenuation of the mantle zone, and presence of multinucleated giant cells.[904]

Sinusitis may result from parasitic infections, including those caused by *Microsporidium*, *Cryptosporidium*, and *Acanthamoeba*. Patients with these infections typically are late in the course of AIDS with a CD4 count less than 20/ $\mu$ L and the presence of other opportunistic infections. Use of nasal drugs is not a precipitating factor. Clinical symptoms can include fever, headache, nasal obstruction and/or rhinorrhea, otorrhea, local pain, and swelling. The infections can cause a mass, perforation, and invasion of surrounding tissues. The symptoms are often present for a long time. Biopsy is usually needed for a specific diagnosis. Treatment outcomes are often poor, but the patients usually die from other causes.[1103]

Examination of the ear in AIDS reveals that mild, or low grade, to severe otitis media can be present in about half of patients. When low grade, the degree of inflammation is not great, and serous to serosanguineous effusions can be seen. Purulent exudates with marked acute and chronic inflammation can be seen with severe otitis. Causative organisms are the same as those in the general population: *Streptococcus pneumoniae*, *Haemophilus influenza*, and *Moraxella catarrhalis*. *Pneumocystis carinii* may rarely present as otitis media and mastoiditis. Cholesteatoma may complicate these findings. Viral infections found in the middle ear include cytomegalovirus, adenovirus, and herpes simplex virus. Other lesions reported to involve middle and inner ear include cryptococcosis, cytomegalovirus, and Kaposi sarcoma. However, in adults these ear infections appear to be asymptomatic and not associated with deafness.[1104,1105,1106]

Otitis externa may be caused by *Pseudomonas aeruginosa* and by *Aspergillus*. [747] Otic pneumocystosis is rarely reported, with granulation tissue forming a mass in the external auditory canal. Microscopically, the amount of foamy exudate containing recognizable organisms is variable.[1107]

Otologic findings in adults with HIV infection may include tinnitus, vertigo, and hearing loss involving about a fourth of patients attending a tertiary care referral clinic in one study. Over a third had ear canal pruritus. A fifth of these patients reported otalgia. Sensorineural hearing loss increased with progression of HIV infection.[1108]

Sensorineural hearing loss in HIV-positive persons may result from infections, central nervous system lesions or ototoxicity from antiretroviral medications. The prevalence of HIV-related sensorineural hearing loss has been estimated to be between 21% and 49%. Infectious agents implicated in sensorineural hearing loss include *Pneumocystis carinii*, *Candida albicans*, *Staphylococcus aureus*, *Mycobacterium tuberculosis*, *Toxoplasma gondii*, *Cryptococcus neoformans*, *Treponema pallidum*, herpes viruses, and HIV directly.[1106]

Vestibular dysfunction with vertigo, dizziness, or balance problems may result from either otologic or central neurologic disorders. There is a greater likelihood of vestibular dysfunction in HIV-infected than in non-infected persons. Over a third of HIV-infected persons may have either peripheral or central vestibular dysfunction or both. Involvement may be early in the course of HIV infection as well as over time. Antiretroviral therapy does not appear to reduce the likelihood for vestibular dysfunction. Progression to AIDS may be accompanied by central nervous system complications that also affect vestibular function.[1109,1110]



## BONE, JOINT, AND SOFT TISSUE PATHOLOGY IN AIDS

The skeletal system and supporting structures including bone, cartilage, tendons, and ligaments do not have specific lesions related to HIV infection and its sequelae. A painful articular syndrome with HIV infection is characterized by severe articular pain from a few hours to 24 hours and associated with significant disability, resulting in many of the patients presenting to an emergency room or being hospitalized. However, there are no signs of inflammation on physical examination. The joints most frequently involved with painful articular syndrome are the knees, shoulders and elbows.[1111]

Rheumatologic abnormalities may accompany HIV infection. HIV and its proteins, particularly viral envelope proteins, may have some homology with HLA antigens, Fas protein, and immunoglobulins. Thus, there may be autoantibodies and autoimmune responses. Several nonspecific rheumatologic manifestations have been noted with HIV infection, particularly prior to use of high active antiretroviral therapy (ART). One such manifestation is arthralgia alone, oligoarticular in 54.3% of cases, monoarticular in 11.4% and polyarticular in 34.3%, and the joints most frequently involved are the knees (51%), followed by the shoulders (29%) and elbows (26%). Additional manifestations may include reactive arthritis, Reiter syndrome, psoriatic arthritis, polymyositis, and classic polyarteritis nodosa.[1112]

The rheumatologic clinical presentations in some AIDS patients may resemble systemic lupus erythematosus (SLE). These findings can include arthralgias, myalgias, and autoimmune phenomena including a low titer positive antinuclear antibody, coagulopathy with lupus anticoagulant, hemolytic anemia, and thrombocytopenic purpura. Hypergammaglobulinemia from polyclonal B-cell activation may be present, but often diminishes in the late stages of AIDS. Specific autoantibodies to double-stranded DNA, Sm antigen, RNP antigen, SSA, SSB and other histones may be found in a majority of HIV-infected persons, but their significance is unclear. Other rheumatologic manifestations include vasculitis, fibromyalgia, and spondyloarthropathy.[1113] Similar autoantibodies have also been reported in children with HIV infection.[1114] Mixed cryoglobulinemia may be detected in persons with HIV infection, and the HIV-1 viral load tends to be higher in such persons, which may lead to antigenic stimulation that drives polyclonal B lymphocyte activation.[1115]

An HIV-associated arthritis has been described that is a predominately lower extremity-occurring oligoarthritis that can occur anytime in the course of HIV. The pattern of joint involvement can vary, with some patients presenting in a rheumatoid-arthritis-like distribution. This condition tends to be self-limited, but can cause significant joint destruction. Laboratory analysis of synovial fluid shows a low cell count, while serum HLA-B27, antinuclear antibody, and rheumatoid factor are usually negative.[1111]

Septic arthritis is most likely to occur in HIV-infected patients whose risk factor is injection drug use. *Staphylococcus aureus* and streptococci are the most commonly cultured organisms. There is no correlation with CD4 lymphocyte counts.[1111,1112]

Kaposi sarcoma (KS) rarely involves bone in patients with AIDS, and the axial (vertebrae, ribs, sternum, and pelvis) and/or maxillofacial bones are most likely to be involved. These patients typically have KS elsewhere. Joint and muscle involvement by KS are rare. The lesions tend to be small, without pathologic fractures, and radiographs have poor sensitivity for detection, while CT and MR imaging are better at detecting the osteolytic lesions.[1116]

Seronegative spondyloarthropathy has been described in association with HIV infection. It appears to be more severe and more resistant to therapy than spondyloarthropathies in persons without HIV infection. This spondyloarthropathy is oligoarticular, mainly involves the lower extremities, and can be accompanied by enthesitis (at tendinous insertions on bones), skin rashes, and mucus membrane involvement. It may become quiescent with antiretroviral therapy. In Caucasians with HIV infection, HLA-B27 is found in 80 to 90% of patients with this form of reactive arthritis, but Africans are likely to be HLA-B27 negative.[1111,1117]

Osteomyelitis most often affects younger persons with AIDS with low CD4 counts. The mortality rate is high.[1124] The most common organism cultured is *Staphylococcus aureus*; other bacterial organisms cultured may include streptococci and *Enterobacter*. [1118] Some cases may be due to atypical mycobacteria, particularly with low CD4 counts. Skeletal lesions from infection with atypical mycobacteria are often multiple, and concomitant skin lesions are frequent.[1119]

Osteolytic bone lesions may appear with bacillary angiomatosis, caused by the Rickettsia-like organism *Bartonella henselae*. Such lesions can appear in the distal extremities and cause local pain. Radiographically, these lesions appear as circumscribed lytic areas that may cause cortical destruction with a periosteitis or may permeate the marrow cavity.[546]

Osteonecrosis has been observed more frequently since the 1990's with HIV infection, and is 100-fold more likely to occur in HIV-infected persons than the general population. The hip is most commonly affected area and often bilaterally.[1120] Risk factors include corticosteroid therapy, hyperlipidemia, alcoholism, hypercoagulability, and megestrol acetate use. Plain film radiographs and magnetic resonance imaging are used for diagnosis.[1121] Osteonecrosis appears to be more prevalent in HIV-positive patients undergoing primary total hip arthroplasty than in HIV-negative control patients. Compared to HIV-negative patients, osteonecrosis in HIV-infected persons develops at an earlier age, and is accompanied by a lower prevalence of osteoarthritis in HIV-positive patients. The duration of HIV infection is significantly shorter in patients with osteonecrosis.[1122]

Bone demineralization with osteopenia and osteoporosis is observed more frequently in HIV infected persons with long survival. Risk factors for the development of osteopenia include antiretroviral therapy (ART), older age, longer duration of HIV infection, high viral load, lipoatrophy, poor nutrition, and lower body weight. A decrease in bone mineral density of 2 to 6% per year in the first two years following initiation of ART is similar to that of the first two years following menopause, particular when tenofovir is part of the regimen.[332].

Multiple mechanisms contribute to HIV-associated osteopenia. The gp120 component of HIV can interact with the cell membrane of osteoblasts and induce apoptosis. Also, gp120 can upregulate RANKL promoting osteoclast activity. Both tumor necrosis factor (TNF- $\alpha$ ) and interleukin-6 are cytokines produced in increased amounts in persons infected with HIV, and these cytokines may affect osteoclast activation and resorption of bone. Up to 90 % of HIV-infected patients may have sub-optimal 25(OH)D levels.[1123]

Soft tissue and osteoarticular infections with HIV infection are not common overall. Findings may include septic arthritis, soft tissue abscesses, osteomyelitis, pyomyositis, and cellulitis. The most common pathogen is *Staphylococcus aureus*. Risk factors include a low CD4 count, presence of intravascular indwelling catheters, extra-articular infection and trauma, and history of injection drug use. The course and treatment of these conditions is similar to that of non-HIV infected persons.[1124]

Soft tissue infections with methicillin-resistant *Staphylococcus aureus* (MRSA) are

becoming increasingly common in HIV-infected persons. In one study of men having sex with men, the MRSA carriage rate was 8.2%, over half of colonized persons subsequently developed infection, and the incidence of community-associated MRSA soft-tissue infections was over 6-fold higher in the HIV-infected persons than among the non-HIV-infected persons. Soft-tissue MRSA infections presented most commonly as a furuncle or carbuncle followed by cellulitis and folliculitis located on the lower extremities, buttocks and scrotum more often than the upper extremities and face. Risk factors included perianal MRSA colonization, anal intercourse, prior MRSA infection, and illicit drug use.[782]

An inflammatory pseudotumor (IPT) is a clinical mass composed of a histologic proliferation of spindle cells in a background of inflammatory cells and collagen fibers. Cryptococcal IPTs have been reported in conjunction with HIV infection. The lesions show a storiform arrangement of plump spindle cells, in addition to spindle and polygonal cells arranged in a haphazard manner. Background lymphocytes, plasma cells, and fibrosis are present along with scattered giant cells and focal necrosis. *Cryptococcus neoformans* yeasts can be identified within and between vacuolated spindle and polygonal cells of the lesions on routine and special stains. Although a variety of microorganisms have been linked to IPTs, mycobacterial IPTs are reported most commonly.[1125]

Since the advent of ART, rheumatologic complications of HIV infection have included an immune reconstitution inflammatory syndrome. Manifestations may resemble sarcoidosis, systemic lupus erythematosus, autoimmune thyroiditis, and reactive arthritis. Such complications may arise de novo or represent exacerbation of prior disease. Autoimmune disease resembling systemic lupus erythematosus or rheumatoid arthritis may also appear with ART.[1112,1126]

## CYTOPATHOLOGY IN AIDS

Diagnostic procedures yielding primarily cytopathologic specimens, rather than tissue biopsies, in the respiratory tract include bronchial brushings, bronchoalveolar lavage, and sputum collection. Collection of these specimens is mainly for diagnosis of *P. jiroveci* (*carinii*). Without special stains, the appearance of small eosinophilic foamy bodies is quite suggestive of *Pneumocystis*. [442] The diagnostic sensitivity in specimens obtained from bronchial washing or induced sputum may be aided by use of an indirect fluorescent antibody test for *P. jiroveci* (*carinii*). [1127]

Bronchoalveolar lavage (BAL) remains overall the most useful procedure for obtaining diagnostic material from lung in immunocompromised patients, with a diagnostic yield of over 50%. [705] BAL is the method of choice for diagnosis of *Pneumocystis jiroveci* (*carinii*) pneumonia, with a yield greater than 90%. [647,706] In BAL fluids, diagnosis of cytomegalovirus (CMV) is aided by immunohistochemical staining and/or in situ hybridization techniques, which are more sensitive than CMV detection by morphology alone. [1128]

Budding yeasts of *Candida* are often seen in sputum specimens, in specimens obtained at bronchoscopy, or in esophageal brushings. Yeast organisms in such specimens may represent oral contamination rather than a pathologic process. Cytomegalovirus and *Aspergillus* likewise uncommonly represent pathogens in BAL specimens. Other infectious agents are seen much less frequently. Diagnosis of malignant lymphomas or KS from pulmonary cytologic material is extremely difficult.

Stereotaxic brain biopsy is most often undertaken to diagnose mass lesions that represent possible *T. gondii* infection or malignant lymphoma. [801] Diagnosis of other neurologic conditions in AIDS is hampered by poor yield from sampling error resulting from the focal nature of most processes in brain. However, cytology of tissues obtained from the brain by stereotactic biopsy for intraoperative diagnosis may be more sensitive for diagnosis than frozen sections, though the presence of necrosis and gliosis can make diagnosis difficult. [802]

Fine needle aspiration (FNA) cytology may be performed to diagnose mass lesions found on roentgenography. The most frequently sampled sites include lymph nodes, salivary gland, liver, paraspinal area, extremity, and chest wall. A specific diagnosis can be made in half of cases. Enlarged lymph nodes are prime targets for such procedures. Progressive generalized lymphadenopathy is a common diagnosis rendered by FNA of lymph node. Diagnosis of neoplasms such as KS and non-Hodgkin lymphoma are challenging by FNA, but can be aided by immunohistochemical staining. Malignant lymphomas can sometimes be diagnosed by the appearance of a monomorphous population of large atypical lymphoid cells. Aspirates with inflammatory cells, particularly macrophages, should be screened with special stains to detect fungal or mycobacterial organisms. The yield for diagnosis of M tuberculosis with FNA is 47%. [1129]

Imprints or smears of tissue specimens removed at surgery may aid in diagnosis of mycobacterial infections by providing more detail than paraffin sections. [483]

## PEDIATRIC AIDS

Pediatric HIV infection is primarily acquired perinatally. Infection can occur in utero prior to birth, intrapartum during delivery, or via breast milk following delivery.[196] Pediatric HIV infections acquired through transfusion of blood or blood products are rare in places where adequate testing programs for these products are in place. Sexual abuse of children may also be identified as a risk factor in some cases. In adolescents aged 13 to 19, the manner of presentation and the nature and appearance of opportunistic infections and neoplasms seen with AIDS is similar to adults.[1130]

**DIAGNOSIS.**-- The diagnosis of HIV infection in children <18 months of age is complicated because passively acquired maternal HIV antibody may be present, so tests for HIV antibody alone are not sufficient, and additional criteria are necessary.[419,420] About half of HIV-infected infants do not have detectable HIV by laboratory methods within the first month of life, but in virtually all cases HIV infection can be established at 1 to 2 months of age. The most sensitive method for HIV detection is HIV viral culture, but this is not practical. HIV RNA assay in either peripheral blood mononuclear cells or in plasma is most useful. HIV infection is presumptively excluded with 2 negative virological tests, with one at 2 or more weeks of age and the second at 1 or more months of age. HIV infection can be definitively excluded with 2 negative virological tests, with one at 1 or more months of age and the second at 4 or more months of age. Testing of cord blood should be avoided because of potential maternal contamination.[378,383,384]

Presence or absence of detectable HIV soon after birth may explain when transmission of HIV from mother to baby occurred. Thus, infants are defined as infected in utero if HIV can be cultured from peripheral blood or HIV can be detected in lymphocytes within 48 hours of birth. Intrapartum infection is defined in a neonate with a negative HIV culture or PCR assay for HIV proviral DNA in peripheral blood in the first week of life, but positive thereafter.[196]

**CLINICAL FEATURES.**-- On average, about 14 to 25% of children born to HIV-1 infected mothers are perinatally infected in the United States and Europe, while about 13 to 42% of children of HIV-1 infected mothers acquire HIV perinatally in developing nations.[1131] However, the rate of HIV infection in the firstborn of twins delivered vaginally (35%) is greater than the rate in second born (15%), and the 15% rate of HIV infection in the firstborn of twins delivered by cesarean section is greater than the 8% rate for the second born, suggesting that intrapartum HIV infection occurs.[1132] A greater HIV viral burden in the mother during late gestation and/or during the time of delivery, as measured by HIV-1 RNA levels, increases the risk for HIV transmission to the baby. The risk for HIV-1 transmission is increased with preterm labor and premature rupture of membranes.[194,196,198] The risk is halved with delivery by elective cesarean section.[196] For mothers with HIV-2 infection, the rate of perinatal transmission is only 1 to 2%.[201] Breast feeding by HIV-infected mothers further increases the risk for transmission of HIV to an infant.[184]

The risk for development of opportunistic infections, encephalopathy, and death in these infected children is increased in the first 18 months of life when, at the time of birth, the mother had clinical AIDS, p24 antigenemia, or a CD4 lymphocyte count of <400/ $\mu$ L. Almost half of children die by 18 months of age if mother had clinical AIDS at birth.[1133]

Zidovudine therapy in HIV-infected mothers has been shown to reduce the rate of perinatal transmission of HIV by two-thirds, with no association with birth defects. Zidovudine decreases viral load and decreases the risk for perinatal transmission in late gestation and/or at the time of delivery. Such therapy includes antenatal maternal oral administration of zidovudine starting at 14 to 34 weeks gestation and continuing throughout the pregnancy, intravenous maternal zidovudine therapy during labor and delivery, and oral administration of zidovudine to the infant within 12 hours after birth and continuing for 6 weeks following delivery.[195,199] However, even an abbreviated regimen of zidovudine is efficacious in reducing the risk for perinatal transmission of HIV.[319] Anemia and neutropenia occur in HIV-uninfected infants during the first 3 months of life following maternal prophylaxis to prevent transmission of HIV, and this anemia is greater in ART-exposed infants.[1134]

There appear to be two patterns of progression to AIDS with perinatal HIV infection. In about 10 to 25% of infections the infants and children manifest severe immunodeficiency with failure to thrive and encephalopathy in the first two years of life, with mortality of nearly 100% from AIDS by 4 years of age.[1135] Rapid progression of perinatally acquired HIV-1 may be predicted by a number of factors. These include positive HIV-1 culture or polymerase chain reaction (PCR) assay during the first week of life, <30% CD4+T-lymphocytes at birth, and any or all of the following noted at birth: hepatomegaly, splenomegaly, lymphadenopathy.[1136] Specific infectious diseases, severe bacterial infections, progressive neurologic disease, anemia, fever, cardiomyopathy, growth failure, hepatitis, and persistent oral candidiasis are all findings that correlate with shortened survival.[250]

In the remaining 75 to 90% of cases, children with HIV infection have a much slower progression to AIDS over 10 years or more, often remaining asymptomatic through adolescence, and their morbidity and mortality more closely resembles adult AIDS.[1135] From a pediatric standpoint, long-term nonprogressors or slow progressors may be defined as children reaching the age of 10 years without ART therapy (single or dual nucleosides only), without AIDS defining illness and with CD4 counts above 25%. In one study of such children, half showed deterioration in CD4 counts beginning at puberty while half remained stable. Thymic output did not predict this difference in course.[1137]

HIV-infected children, however, with hepatomegaly, splenomegaly, lymphadenopathy, parotitis, skin diseases, and recurrent respiratory infections tend to have longer survival. Children with lymphoid interstitial pneumonitis tend to have a survival intermediate between the above two groups. About half of children with perinatally acquired HIV infection are alive at age 9.[79] In any case, increased HIV viral replication is noted in the first 3 to 16 weeks of life, similar to acute HIV infection in adults. A higher viral load at this time suggests a more rapid pattern of progression.[1135]

In developed nations, most of the mothers of infants with HIV infection have acquired HIV infection as injection drug users or as sexual partners of drug users, but increasing numbers of mothers have acquired HIV heterosexually. In addition, some sexually abused children have contracted AIDS, with symptoms often not appearing until adolescence. Transfusion-associated AIDS in the early 1980's accounted for about 10% of pediatric cases and transfusion of blood products for hemophilia about 5%. In places where screening of blood products for HIV has been employed, these percentages have decreased substantially. Death has occurred in over 75% of reported pediatric AIDS cases, usually with opportunistic infections similar to adult AIDS patients, but with a clinical course, on overall average, shorter than that of adult patients.[250]

**FAILURE TO THRIVE.**-- Poor growth may be seen in up to half of children infected with HIV. The decrease in growth continues over time, and appears to involve lean body mass. This effect may be present from birth, since it is noted that infants born to HIV-infected mothers (even those who do not acquire HIV) have a significantly lower mean birth weight and length. Micronutrient deficiencies, and vitamin A deficiency, may play a role, but dietary supplementation does not correct deficits in lean body mass or height. The levels of HIV-1 RNA are higher in children with poor growth.[1138]

**PULMONARY FINDINGS.**-- Pulmonary problems include *Pneumocystis jiroveci* pneumonia (PJP), which occurs in more than half of pediatric patients with AIDS and has a high mortality rate in infants less than 2 months of age. Approximately 12% of infants with perinatally acquired HIV infection develop PJP in the first year of life. More than a third of pediatric AIDS patients die from PJP. Recurrent bacterial infections are common and account for about 20% of deaths from AIDS in children.[1139] The histopathology is similar to that seen in adults. Prophylaxis is recommended for all infants with perinatal HIV exposure, beginning at 4 to 6 weeks of life, and continuing throughout the first year of life if HIV infection is confirmed. Despite prophylaxis, PJP may still occur.[333] The risk for PJP is increased when the CD4 count is declining or when maternal CD4 counts are lower, but does not appear to be related to HIV-1 RNA levels.[1140]

Cytomegalovirus pneumonia can complicate HIV infection in infants being ventilated for suspected *Pneumocystis* pneumonia. High dose corticosteroids for treatment of *Pneumocystis* pneumonia may further immunocompromise these infants contributing to the development of CMV pneumonia. Ganciclovir may be used empirically until CMV disease is excluded.[1141]

Lymphoid interstitial pneumonitis (LIP) is not characteristic of adult AIDS but is seen at some point in about 20 to 30% of all children with AIDS. LIP rarely causes death and affected children may have a better prognosis than that of HIV-infected children with AIDS-defining opportunistic infections and neoplasms. It usually develops when passively acquired maternal antibody begins to disappear. Corticosteroid therapy may be useful in treatment of LIP.[1142] Bacterial pneumonias can be seen in the late stage of pediatric AIDS. Cytomegalovirus infection of the lungs is also common and may be associated with pulmonary failure and death. Mycobacterial and fungal infections are uncommon.[450,687]

A polyclonal B-cell lymphoproliferative disorder (PBLD) can affect the lungs in children with HIV infection, as well as other organ sites including liver, spleen, lymph nodes, and kidneys. Thus, hepatosplenomegaly and lymphadenopathy may be present. The lungs can demonstrate nodular infiltrates. PBLD is a more florid example of pulmonary lymphoid hyperplasia (PLH) characterized by lymphoid follicles with or without germinal centers surrounding bronchioles. With PBLD, there are nodular infiltrates of polyclonal B-lymphocytes and CD8+ T-lymphocytes.[691]

Chronic lung disease (CLD) can occur in children and adolescents living with HIV infection. CLD is defined as:[1143]

- Chronic cough present most days for 3 months per year in the past 2 years
- Recurrent respiratory tract infections with 2 antibiotic courses in the past year
- Moderate to severe limitation in physical activity caused by breathlessness
- Existing diagnosis and/or signs of cor pulmonale
- Hypoxia at rest, with oxygen saturation  $\leq 92\%$ , or desaturation of  $\geq 5\%$  on exercise

CLD is not a diagnosis, but a description of a clinical condition that can result from many etiologies. Underlying lung diseases that may contribute to CLD include: lymphoid interstitial pneumonitis, bronchiectasis, bronchiolitis obliterans, tuberculosis, aspiration, and interstitial lung diseases. Chronic immune alterations with ongoing HIV infection, as well as effects of antiretroviral therapy, can contribute to declining lung function. Children with HIV infection have an increased risk for development of asthma. Exposure to cigarette smoke can exacerbate pre-existing disease. Pulmonary function testing often reveals airway obstruction. Treatment is tailored to the underlying respiratory disease.[1144]

**CNS FINDINGS.**-- The most common neurologic finding in pediatric AIDS is a progressive encephalopathy, or progressive HIV-related encephalopathy (PHE), which appears to be caused by direct CNS infection by HIV. PHE may affect 30 to 60% of children with AIDS. Neurologic signs can occur before complications of immune suppression appear. In children, neurologic symptoms related to PHE include acquired microcephaly, acquired symmetric motor deficits such as paresis or pathologic reflexes, and a failure to attain age-appropriate milestones or a loss of those previously attained. With effective antiretroviral therapy PHE has become an infrequent and reversible complication of HIV infection. However, PHE may relapse if viral control is lost. Though children on antiretroviral therapy may show significant improvement, they show higher rates of residual neurologic, cognitive, and scholastic impairments compared with children who never had PHE.[1145]

There are three major patterns of encephalopathy in children, which is the counterpart of AIDS dementia complex, or human immunodeficiency virus-associated dementia (HIVD) in adults: (1) subacute progressive - patients at first develop normally but then social, language, and motor skills are lost, and microcephaly may be present; (2) plateau progressive - patients initially develop at a normal pace but then decline in their rate of developmental progress with little or no further acquisition of skills, and microcephaly may be present; (3) static encephalopathy - children are late to acquire motor and language skills, are cognitively impaired, and acquire skills slowly; radiographic scans are normal.[812]

Neuropathologic findings distinctive to pediatric HIV infection include acquired microcephaly. In such cases there is no gross or microscopic malformation, only decreased brain weight accompanied by cortical atrophy and ventriculomegaly. Gliosis is seen microscopically. Other frequent histologic findings include calcification in vascular walls of basal ganglia and deep cerebral white matter, and these changes are often progressive with age. As in adult AIDS cases, multinucleated giant cells are often present. Children with encephalopathy often have corticospinal tract degeneration from myelin loss, while the vacuolar myelopathy seen in spinal cords of adults is uncommon. An anoxic-ischemic encephalopathy with neuronal necrosis in cerebral cortex, hippocampus, and basal ganglia may be seen in association with systemic hypoxemia from cardiovascular disease. Although non-Hodgkin lymphoma can be seen in pediatric AIDS patients with focal CNS lesions, opportunistic infections such as toxoplasmosis, cryptococcosis, cytomegalovirus, and progressive multifocal leukoencephalopathy are uncommon in pediatric AIDS, as contrasted with adult AIDS cases.[1146,1147]

**ORAL LESIONS.**—Children manifest many of the same oral lesions, such as oral candidiasis, as to adults with HIV infection. The use of antiretroviral therapy has reduced the prevalence of most oral diseases in the pediatric age range. However, oral warts have increased in frequency, likely related to immune reconstitution. Salivary gland enlargement, often the first



manifestation of HIV illness, remains more common in children than adults. Xerostomia may or may not be present. Benign lymphoepithelial lesions are the most commonly diagnosed parotid condition.[1148]

**NEOPLASIA.**-- Neoplasms are seen less frequently in cases of pediatric AIDS than in adult cases. About 2.5% will develop a malignant neoplasm. The most frequent neoplasm of HIV-infected children is high-grade non-Hodgkin lymphoma (NHL). A third of NHL's in children are of the intermediate (Burkitt) type and a fourth are seen to occur in the brain.[1149] Clinical findings seen at presentation with NHL's in pediatric AIDS include fever, weight loss, jaundice, hepatosplenomegaly, abdominal distension, anemia, and neurologic abnormalities. Most patients are at stage III or IV on presentation. In children, NHL's are more likely to occur in boys who are Caucasians and who are older. Brain lymphomas tend to occur late in the course of AIDS. In addition to NHL's, mucosa-associated lymphoid tissue (MALT) lesions have been seen in association with pediatric HIV infection.[614]

Kaposi sarcoma has been reported in children with AIDS in both skin and visceral sites, but with far less frequency than in adults with HIV. The etiology of KS probably involves infection with human herpes virus 8 (HHV-8), but risk factors may be difficult to identify. The average age of onset is between 5 and 6 years.[1149]

Next in frequency are smooth muscle tumors. These are either leiomyomas or leiomyosarcomas. Leiomyosarcoma is one of the most common cancers in children with HIV infection. These smooth muscle tumors are generally central and visceral in location (central nervous system, gastrointestinal tract, respiratory tract, spleen, liver, adrenal).[1150] In lung, these lesions appear as multiple nodules; tracheobronchial involvement may lead to respiratory distress with wheezing. Gastrointestinal lesions may produce bloody diarrhea, abdominal pain, and obstruction.[629,630] Epstein-Barr virus can be demonstrated in the cells of HIV-associated smooth muscle neoplasms, and EBV stimulated clonal proliferation may contribute to their pathogenesis in both children as well as adults.[1151] Histologic findings include interlacing fascicles of spindled smooth muscle cells with elongated, blunt-ended nuclei and eosinophilic cytoplasm. Those that appear benign have a uniform cell population and little or no mitoses; malignant-appearing leiomyosarcomas are densely cellular, with pleomorphic, hyperchromatic nuclei and many mitoses. There may be collections of primitive round cells with irregular nuclear contours that, on immunohistochemistry have a smooth muscle phenotype, including positivity for smooth muscle actin and desmin. In some cases, a variable T-cell inflammatory infiltrate is present.[630]

**MISCELLANEOUS FINDINGS.**-- An arteriopathy has been described at autopsy in children dying of AIDS in which there is either cerebral vasculitis or generalized fibrocalcific change in elastic lamina or media of arteries in brain, lung, heart, thymus, kidney, spleen, heart, and lymph node. Pathologic findings in large vessels consist of vasa vasorum medial involvement with chronic inflammation. Coronary artery involvement is mainly calcific. The luminal narrowing may explain focal necrosis, atrophy, fibrosis, or gliosis.[1152,1153] In the brain, this arteriopathy is manifested as a diffuse dilation with ectasia of major arteries of the circle of Willis, with intimal fibroplasia, medial thinning, and elastic lamina destruction or reduplication. This arteriopathy can lead to hemorrhages in cerebrum, basal ganglia, and subarachnoid space. Infarctions may also occur. Though little inflammation is identified within these lesions at

autopsy, the features suggest a prior vasculitis, and there is often a history of a prior opportunistic infection, particularly varicella zoster virus (VZV).[1154,1155]

Human immunodeficiency virus-associated nephropathy (HIVAN) can occur in children., and is diagnosed with: (1) persistent proteinuria for 3 months or more, in the absence of acute infection, especially in children of African descent; (2) urine sediment with urine microcasts (shed epithelial cells).; (3) highly echogenic kidneys as detected by serial renal ultrasound performed 3 months apart; and (4) Black race with a clinical history of nephrotic-range proteinuria with or without edema or hypertension. Patients have excessive proteinuria or albuminuria. Classic features of nephrotic syndrome may be present. The use of antiretroviral therapy has greatly decreased the incidence of HIVAN.[1156]

Focal and segmental glomerulosclerosis (FSGS) may be seen along with mesangial hyperplasia, microcystic tubular lesions, or minimal change. The course in children is less fulminant than in adults, but progression to end-stage renal disease can still occur, particularly those African-American children with a genetic predisposition. Hematuria may also occur. A fatal form of hemolytic-uremic syndrome (HUS) has been described, but with more insidious onset and without the diarrhea characteristic for the classic HUS related to shiga toxin.[1157]

An HIV immune complex kidney (HIVICK) disease can also occur. HIVICK may develop from either trapping or in situ deposition of circulating immune complexes comprised of HIV core and envelope antigens coupled with a polyclonal immune response directed against these antigens. HIVICK is more likely to occur in Caucasian children, and without the genetic predisposition more characteristic of HIVAN in African-Americans.

The thymus in pediatric AIDS can undergo marked involution with irreversible injury that contributes to immunosuppression and rapid progression of disease from immune dysfunction. This occurs more often in children with HIV strains using CXCR4 as a coreceptor. Aggressive antiretroviral therapy may lead to thymic recovery in children without extensive thymic damage.[1158]

*Candida* infection of the esophagus or lung has been seen in 10% of pediatric cases. Recurrent oral thrush, a frequent finding in infants with AIDS, may give rise to invasive or systemic candidiasis. Systemic, recurrent bacterial infections are seen with frequency and may satisfy definitional criteria for diagnosis of AIDS.[420]

Diarrhea can be a serious problem in HIV-infected infants and appears more frequently, tends to be more persistent, and has an onset earlier in life than in infants who are not HIV-infected. Fever, vomiting, anorexia, and dehydration often accompany the diarrheal illness. In many cases, a pathogen cannot be found. The most common pathogens identified are cytomegalovirus (particularly involving the cecum), rotavirus and *Salmonella* species.[1159]

Metabolic complications associated with antiretroviral therapy (ART) are seen in children. The HIV-associated lipoatrophy (lipodystrophy) described in adults, with dyslipidemia, fat redistribution, and insulin resistance, also occurs in children. Up to a third of children receiving ART may be affected.[1160] In addition, there can be growth retardation and decreased bone mineral density. Mitochondrial toxicity can produce neurologic complications with hyperlactatemia.[1161]

Granulomas are seen less frequently in children and fewer organisms are present with either mycobacterial or fungal infections than in adult AIDS patients. The large macrophages containing *Mycobacterium avium*-complex (MAC) found throughout the reticuloendothelial system in some cases may mimic the cells observed with some storage diseases such as Gaucher disease and Niemann-Pick disease.[1162]

## CHAPTER 6 - SAFETY PROCEDURES WITH AIDS

### EDUCATIONAL GOALS

Human immunodeficiency virus (HIV) and other infectious agents may be encountered in the daily routine of workers employed in health care. There is concern by workers about exposure to infected persons or specimens. Questions may arise about the hazards, risks, and consequences of job-related exposure to infectious agents--and HIV in particular.

All health care providers have a basic responsibility to attend all patients, regardless of disease. Physicians in particular have a special responsibility to model professional behavior and display their willingness to provide competent, sensitive, and compassionate care to all patients. Failure to properly care for and attend HIV-infected patients violates a basic tenet of the medical profession: to place the patient's interest and welfare first.[1163]

Educational efforts provide health care workers with the means to understand the nature of AIDS and to cope with their fears and prejudices in treating HIV-infected patients. Educational goals should include: (1) dissemination of accurate information concerning the true risks involved in health care, (2) understanding the modes and risks of transmission of HIV, (3) training in the protective procedures, techniques, and equipment for infection control, (4) use of monitoring for compliance with infection control measures, and (5) understanding the procedures to be followed in the event of potential exposure.

## UNIVERSAL PRECAUTIONS

The Centers for Disease Control (CDC) recommends universal precautions for all health care workers when dealing with all patients and specimens at all times. The rationale for this is supported by a study which 24% of persons receiving care at an inner city hospital emergency department had serologic evidence for infection with at least one of three viruses: HBV (5%), HCV (18%), or HIV-1 (6%).[1164] In another study of patients seen in a large metropolitan hospital emergency room, a 7.8% rate of HIV-1 seropositivity was found, but even after initial HIV-1 testing by EIA and WB assays, 0.3% additional HIV infections were found by HIV-1 p24 antigen and HIV-1 plasma RNA testing.[397,1165] Thus, potentially contaminated specimens are received by a hospital's laboratories and, despite the very high sensitivity of current testing methods for HIV, limitations of testing methods mean that it is not possible to identify with certainty all infectious specimens.[370]

Despite increasing prevalence of HIV infection, the numbers of reported seroconversions in health care workers have not risen significantly during the AIDS pandemic. Most of the documented cases of occupational HIV transmission have occurred in nurses and laboratory technicians performing many procedures with needles or other sharps that carry a risk for accidental exposure. Percutaneous injury, usually inflicted by a hollow-bore needle, is the most common mechanism of occupational HIV transmission. In a few instances, inapparent inoculation through mucous membranes or inapparent breaks in the skin may occur. Contact with saliva, urine, and feces carries little risk. Infection with HIV or hepatitis viruses from aerosols has not been demonstrated.[1166,176]

The risk of HIV infection in hospitals, though very small, does exist, as with other infectious agents, especially with failure to follow proper procedures or with accidents. The risk for HIV seroconversion from inadvertent occupational exposures with blood borne transmission is only about 0.3%. However, the risk for transmission for hepatitis B virus (HBV) ranges from <6% to at least 30% based upon the absence or presence of hepatitis B e antigen. The risk for hepatitis C seroconversion ranges up to 7%, with an average risk of 1.8%. Risk is primarily based upon the number of virions present in blood, which is higher for hepatitis viruses than for HIV. The average volume of blood inoculated during a needlestick injury with a 22-gauge needle is approximately 1  $\mu$ L, a quantity sufficient to contain up to 100 infectious doses of hepatitis B.[175,176,1166]

The main risk for HIV infection with exposure to blood or body fluids is the number of viral particles, which is a function of the stage of infection. Recently infected persons have a high viral load, as do persons in the late stage of AIDS. Exposures such as needlesticks that introduce blood deep into tissues carry a greater risk, as do accidents in which visible blood is present. Risk is greater when the source patient died within 2 months following health care worker exposure.[1167]

Body fluids other than blood contain far fewer HIV virions. Therefore, mucosal exposures carry an estimated risk of 0.03% per exposure, or a rate of HIV infection of 1 for every 3300 mucus membrane exposures.[1167]

Every facility that handles the blood, body fluid, or tissue of AIDS patients must develop safety procedures that are routinely employed on a daily basis. In-service or continuing education programs should address the facts about AIDS and the proper approach of the laboratory in dealing with it. Every laboratory worker has an important responsibility to promote

infection control. The real safety factor depends upon the least amount of precaution that will routinely be taken, because any specimen could contain an infectious agent.

In hospital, HIV/AIDS patients should not require strict isolation when universal precautions are employed, and legal actions have been taken against hospitals that did so. Precautions used for patients with hepatitis are more than adequate. Segregation of HIV-infected persons or specimens is impractical, leading to inefficient duplication of facilities or services and undermining the philosophy and benefits of universal precautions. However, HIV-infected patients should not be placed in close proximity to immunosuppressed patients, such as those undergoing chemotherapy or those with lymphoreticular malignancies, who are at risk, not for contracting HIV, but for spread of opportunistic infections from the AIDS patient.

The most common form of parenteral exposure to infectious agents in the hospital setting is needlestick injury. It is estimated that 1 in 10 US health care workers has a needlestick exposure each year. Disposable syringes have the lowest rate of injuries and those devices that required disassembly have higher rates of injury. Needleless intravenous access can also be instituted to decrease injuries to health care workers. One third of needlestick injuries are related to recapping needles. Therefore, attention should be given to usage of needlestick prevention devices consisting of equipment with shielded or retracting needles along with ongoing training programs and implementation of procedures that help to avoid these penetrating injuries. Use of needlestick prevention devices results in a marked reduction in needlestick injuries.[176,1167]

Programs to improve adherence to universal precautions can be effective in reducing risk of exposure. The efficacy of such programs is related to: (1) comprehensive training; and (2) ongoing communication. Adherence to safe equipment practices can reduce exposures, including: (1) avoiding unnecessary needle usage; (2) use of needleless or protected needle systems; (3) use of needles that can be resheathed; (4) use of blunted tip needles; and (5) use of puncture-resistant sharps disposal containers.[1167]

The risk to surgeons from accidental exposure to HIV in the operating room is low, with a percutaneous injury rate of 1.7% per operative procedure in a hospital with a high HIV prevalence population.[1168] There is no evidence to suggest a higher rate of HIV infections for surgeons performing surgery in moderate to high AIDS incidence areas, and the risks for hepatitis B and hepatitis C are greater.[1169] The potential risk to a patient undergoing an invasive procedure by a physician infected with HIV is also extremely low, particularly with use of universal precautions. By contrast, the risk of death from homicide in the United States is 1 in 10 000 per year and from vehicular accident 1 in 7000 per year, and more health care workers have died from firearms injuries incurred at work than from AIDS.[1170]

HIV exposure risk reduction with invasive procedures such as surgery can include use of alternatives to suturing with needles, such as use of stapling devices, tape, glue, and electrocautery. When half of suture needles used are blunted the risk reduction is 87%. The operative field can be limited to a single operator. Hand to hand passage of sharps can be avoided. Thicker gloves, or increased thickness in the thumb and non-dominant hand can be employed.[1167]

## OSHA REGULATIONS

The United States Occupational Safety and Health Administration (OSHA) have adopted standards to be followed to protect workers against exposure to blood-borne pathogens,

particularly hepatitis B virus and HIV.[1171] These rules have as their basis the Centers for Disease Control (CDC) guidelines for universal precautions for blood borne pathogens. These rules require that the following standards be followed in the health care delivery setting:

1. Vaccines and post-exposure treatment be made available free of charge to all employees at risk of exposure on the average of one or more times per month.
2. Routine tasks are to be evaluated for potential exposure, without consideration of protective equipment, and personnel at risk are to be identified and documented. Standard operating procedures are recommended.
3. A written control plan be implemented, including:
  - a. exposure determination
  - b. proper and appropriate use of safety equipment, work practice and engineering controls
  - c. schedule and method of implementation for each provision
  - d. a summary of education and training procedures
  - e. review and update of infection control plan as needed to reflect any changes in policy
4. Personal protective clothing and equipment must be appropriate and fit properly and must be readily available at all times. The employer shall clean, launder, repair, or replace all such items as necessary. Disposable gloves may not be disinfected or washed for re-use but must be removed immediately upon leaving the work area and placed in an appropriate container for disposal. Masks, eye protection, or face shields must be worn whenever there are splashes, sprays, spatter, droplets, or aerosol of blood or other potentially infectious materials and the possibility of eye, nose, or mouth contamination.

Fluid resistant clothing must be worn in the event of splashing or spraying. Fluid-proof clothing, including shoe covers, must be worn if there is the potential for soaking with blood or other infectious material.

5. No work area with the potential for occupational exposure will be exempt from following universal precautions.

Used needles and other sharp objects shall not be sheared, bent, broken, recapped, or resheathed by hand. Used needles shall not be removed from disposable syringes. Mouth pipetting is prohibited.

Work areas where there is the potential for exposure to infectious material must be free of food or drink. Smoking, cosmetics or lip balm, and handling contact lenses in work areas are prohibited.

6. Signs and warning labels--including the name of the infectious agent, requirements for entering the area, and the name and telephone number of the responsible person--must be posted at entrances to work areas that contain biohazards.

Warning labels shall be placed on all storage containers, refrigerators, freezers, and disposal facilities used to store or transport potentially infectious fluids or materials.

7. All at risk employees shall participate in an annual training program that provides information regarding risks of exposure, transmission, and necessary precautions. An explanation of the employer's infection control plan, meaning of all signs and warnings, and the appropriate actions to take and person to contact in an emergency must also be provided.

A training program must be provided for employees inexperienced in the handling of human pathogens or tissue cultures. Persons without such training or experience shall be prohibited from working with HIV or HBV materials.

8. Employers shall maintain individual medical records that include vaccinations, circumstances of exposure incidents, results of medical testing and follow-up procedures, and any copies of physicians' written opinions. These records must be kept confidential except where reporting is required by law.

Training records must also be maintained that include dates of sessions, summary of contents, persons conducting the training, and attendance of all personnel.

These OSHA regulations do not require that all employees use all possible barrier precautions. Rather, the employer must make the determination as to which employees need to wear gloves, which require face protection, which need impermeable gowns, etc. This is to be done on a job-by-job or task-by-task basis. Guidelines promulgated by the CDC are similar and also discuss or reference disposal methods for contaminated waste.[175]

The key elements of a workplace plan to prevent transmission of bloodborne pathogens include:[1172]

- Exposure control plan to eliminate or minimize employee exposure to bloodborne pathogens.
- Hand hygiene (hand washing) to prevent disease transmission.
- Surface decontamination for cleaning of work areas.
- Personal protective equipment to protect employees, the environment, and patients.
- Sharps safety and safety-engineered devices to reduce penetrating injuries.
- Engineering controls to remove or eliminate hazards in the work environment.
- Training of employees in safety measures.

- Management of biohazardous waste and laundry.

Prevention of transmission of *Mycobacterium tuberculosis* (MTB) in health care settings is important, particularly in view of increasing numbers of MTB cases and also increasing incidence of multiple drug resistant MTB strains. OSHA have promulgated inspection and enforcement criteria which are based upon Centers for Disease Control (CDC) recommendations. First, the CDC supports use of administrative measures to reduce risk of exposure to persons with infectious MTB through policies that insure rapid detection, isolation, evaluation, and treatment of persons likely to have MTB. Second, the CDC recommends engineering controls in the workplace to reduce the concentration of infective droplet nuclei. This can be achieved through proper ventilation. Use of ultraviolet light can also aid in disinfection. Third, the CDC supports use of personal respiratory protective equipment by health care workers when engineering controls alone will not provide adequate protection. Such a respirator must filter particles 1 micron in size with 95% efficiency and have a face-seal leakage of no more than 10%. A NIOSH-certified respirator with a HEPA filter meets the CDC criteria.[1173]

High-risk settings for exposure to MTB may include:

1. Entering a room occupied by a known or suspected infectious tuberculosis patient;
2. Performing certain high hazard medical procedures such as aerosol administration of medication, bronchoscopy, and sputum induction; and
3. Transporting patients with tuberculosis.

Institutions utilizing respirators must implement a comprehensive respiratory protection program with written standard operating procedures, medical screening of health care workers who will use the respirators, employee training, and equipment inspection, cleaning, maintenance, and storage checks. Each institution must have a tuberculosis infection control program, assign supervisory responsibility to persons with expertise in infection control, and evaluate the risk for transmission of tuberculosis in the workplace. The risk for transmission in a work area is assessed as low, intermediate, or high based upon the number of patients with MTB admitted to the work area along with the number of health care workers who become PPD positive.[1173]

Develop and display leadership in implementing infection control practices. Review routine tasks and procedures to determine the potential risks for exposure to infectious agents. A reasonable approach should be taken, recognizing that risks cannot be completely eliminated and that unwieldy, complicated measures to prevent exposure are unlikely to add any additional measure of safety. In fact, institution of additional complex procedures or use of cumbersome equipment may increase the potential for accidents. Develop and practice the skills necessary to safely perform tasks as a routine that never varies. The true meaning of "universal precautions" is the safety afforded by the most minimal level of infection control in routine procedures.



## DISINFECTION PROCEDURES

Retroviruses, including HIV, are extremely susceptible to environmental degradation. The titer of HIV is reduced from 90 to 99% within several hours after drying, though both HIV and hepatitis B virus have been found to persist on dry environmental surfaces for at least 7 days.[1174] HIV is highly susceptible to common routine chemical disinfectants and fixatives used in medical practice. These include quaternary ammonium compounds, isopropanol (rubbing alcohol), ethanol, hydrogen peroxide, sodium hypochlorite (bleach), cytologic specimens received in 95% ethanol, tissues received in a formalin-containing fixative (such as 10% (v/v) neutral buffered formalin, Zenker's, B-5, or Bouin's fixatives), and glutaraldehyde. Heat treatment of serum specimens at 56° C for 10 minutes also inactivates HIV.[1175,1176,1177] Pasteurization of human breast milk has been demonstrated to inactivate HIV.[1178] Processing of blood-derived products with procedures such as solvent/detergent treatment, heat inactivation, and filtration are effective at removal of contaminating viruses.[1179]

Table 9 details many commonly available disinfectants and/or laboratory reagents effective against HIV. Recommended concentrations of these agents are based upon a sufficient safety margin, given additional factors of absorption, dilution, evaporation, or other loss of potency in the application of these disinfectants.[1177] One reason for the relatively poor infectivity of HIV from contact in the environment is that in blood there are only about 10<sup>7</sup>/L infective HIV virions as compared to 10<sup>16</sup>/L infective hepatitis B virions.[1176]

Highly concentrated retroviral preparations can have recoverable virus after more than 1 week in an aqueous environment at temperatures ranging from room to body temperature (23° C to 37° C). Five hours of heating to 56° C are needed to eliminate HIV in aqueous solutions. Lipid enveloped viruses such as HIV may persist for one week of drying at room temperature. Use of 0.1% NaOH, 0.1% hypochlorite, or 80% ethanol may not inactivate such dried viruses, though rehydration helps disinfection. Thus, spills of body fluids and specimen bottles or containers contaminated with patient fluid or tissue should be disinfected with 0.5% hypochlorite (bleach). Work areas can be routinely disinfected with the same solution. Equipment or surfaces sensitive to bleach can be cleaned with alternative disinfectants.[185,1175,1176,1177]

## OCCUPATIONAL AND NON-OCCUPATIONAL HIV EXPOSURES

Transmission of HIV from infected patients to health care workers by accidents involving parenteral exposure is highly unlikely--a risk of about 0.3% per exposure[176] Since this figure represents the findings of studies of exposures in high risk situations to patients with advanced AIDS with higher viral titers, the average risk in most health care delivery settings is much less. The risk for HIV seroconversion is increased with a deep injury, injury with a device visibly contaminated with patient blood, injury involving a procedure in which a needle is placed in a patient's artery or vein, and injury involving a patient progressing to death from AIDS within two months of the injury. Health care workers who seroconvert are less likely to have had postexposure zidovudine prophylaxis. These findings are consistent with the observations that the risk for HIV infection after a percutaneous exposure increases with a larger volume of blood and with a greater HIV viremia in the patient's blood.[176]

However, rare inadvertent exposures to HIV or other infectious agents may occur despite the best practices of health care workers. When such incidents occur, the situation that led to the exposure must be documented, reported as an industrial accident, and investigated to determine why it happened and how it could be prevented in the future. Persons exposed to HIV should have serologic testing carried out immediately for baseline determination of serologic status and followed by additional testing at 3 months, and 6 months after initial exposure. Persons with work-related exposure to HIV can still acquire HIV infection outside of the workplace, and persons in known risk groups with exposure to HIV may be employed in settings of occupational exposure. There is no laboratory method for making a distinction among the means for HIV exposure.

There is experimental and epidemiologic evidence that administration of antiretroviral therapy beginning soon after exposure to HIV and continuing for several weeks may prevent HIV infection from occurring. There is insufficient data in humans to fully verify this observation, and persons accidentally exposed to HIV have seroconverted despite immediate prophylaxis, but a risk reduction of 81% with post-exposure prophylaxis with zidovudine following percutaneous injuries has been reported.[1166]

The standard 4-week regimen consists of two drugs (zidovudine and lamivudine, or tenofovir and emtricitabine) started as soon as possible after HIV exposure through percutaneous or mucosal routes. The standard two-drug regimen is indicated when the source proves to be asymptomatic, with low viral load. If the source is symptomatic with high viral load, then additional drugs can be added to the basic two-drug regimen (these may include: lopinavir with ritonavir, atazanavir with ritonavir, darunavir with ritonavir). If the source person is determined to be HIV negative, treatment should be discontinued. Antiretroviral treatment is not indicated for contact between intact skin and blood or other body fluids contaminated by HIV. The degree of risk of exposure may be stratified to determine the appropriateness of using postexposure prophylaxis.[143,175]

Adverse side effects of such prophylaxis are frequent, but minor, with about three fourths of persons reporting nausea, malaise or fatigue, and headache. The serious side effect of bone marrow suppression is less frequent. Though pregnancy is not a contraindication to postexposure prophylaxis, use of efavirenz should be avoided. Nevirapine should be avoided because of potential hepatotoxicity.[143,176]

Recommended procedures following an exposure by a health care worker to blood or body fluids that contain HIV may include:[176]

1. Administer first aid as needed to the injured health care worker.
2. Decontaminate the exposure site when the safety of the health care worker permits.
3. Wash open wounds first with soap and water and then irrigate with sterile saline or a disinfectant.
4. Flush exposed mucosal surfaces extensively with water.
5. Exposed eyes should be irrigated with clean water, saline, or sterile eye irrigants.
6. Promptly report the exposure to the institutional occupational medicine department.
7. Counsel the exposed health care worker regarding the risks and benefits of antiretroviral chemoprophylaxis and then offer chemoprophylaxis.
8. If chemoprophylaxis is accepted, then the first dose should be administered as soon as possible, preferably within an hour of the time of exposure.
9. Specimens should be collected for baseline HIV testing on all persons provided with chemoprophylaxis using a blood or oral fluid rapid test if available; otherwise, conventional testing should be used. If the HIV test result is positive, chemoprophylaxis can be discontinued and the person referred to a clinician experienced with HIV care for treatment.
10. The chemoprophylactic drug regimen may be altered if the source and the drug resistance pattern is known.
11. Follow up at 6 weeks, 3 months, 6 months, and 1 year (note: HIV seroconversion will typically occur in the first 6 months if chemoprophylaxis has failed).

Though HIV testing of the person or specimen suspected of being the potential source of HIV exposure may be done, such testing will not always resolve the issue of transmission because: (1) even if the source is found to be positive for HIV, this does not prove that transmission to the exposed worker occurred; (2) the laboratory tests employed, though they are extremely good, are not 100% sensitive; and (3) persons recently infected by HIV may not be detected by routine testing for days to months.

In all health-care settings, opt-out screening for HIV (performing HIV screening after notifying the patient that the test will be performed, with assent inferred unless the patient declines or defers testing) is recommended for all patients aged 13--64 years.

Cost alone would preclude routine screening of all patients, persons, bodies, or specimens, nor would the detection of specific sources for HIV infection lessen the need for routine infection control. Remember that other important infectious diseases such as hepatitis

also exist! If testing of a specific source specimen or patient of HIV exposure is undertaken, it should be carried out in conformity with local statutes.

Hepatitis continues to be the greatest risk to workers exposed to blood or body fluids, though the incidence of infection declined markedly in the last decade of the 20<sup>th</sup> century. In 1985 there were over 300 000 cases of hepatitis B reported in the United States, with 12,000 health care workers infected, but this declined to 400 cases of hepatitis B in health care workers in 1995.[176]

Vaccination for hepatitis B virus (HBV) is recommended for workers in areas with potential exposure. This would include persons employed in health care with potential exposure to blood or blood products in the performance of routine duties. Post-exposure prophylaxis for HBV consists of testing for antibody to HBsAg in persons whose immune status is not known. Persons previously vaccinated against HBV should also be tested if their immune status has not been assessed in the preceding 2 years. If no immunity to HBV is found, then exposed workers should receive HBV vaccine as well as hepatitis B hyperimmune serum globulin (HBIG).[175,176,1166]

Laboratory testing after HIV exposure includes HIV test at the time of exposure, with follow-up testing at 6, 12, and 24 weeks. Measurement of HIV viral load is not recommended unless there is evidence for acute retroviral syndrome. Testing for hepatitis B and C can also be done at the time of exposure.[143]

Non-occupational exposures to HIV include inadvertent sexual transmissions and sexual assaults. Prophylaxis for such exposures is hard to define. Experiments in primates suggest that antiretroviral drug therapy must be instituted within 72 hours of sexual exposure, and optimally within 36 hours, and continued for at least 28 days.[143,1180] Postexposure prophylaxis is recommended, but complicated by early recognition and adherence to medications once prescribed. It is not cost effective for low risk exposure situations. Such prophylaxis is not completely protective. The antiretroviral drugs regimens have not been completely defined.[1181]

## INVASIVE AND SURGICAL PROCEDURES

A variety of diagnostic and therapeutic procedures may be performed in the management of patients with HIV infection and with AIDS. Procedures can be as routine as phlebotomy to as complex as major surgery. About 15% of HIV-infected persons will have one or more surgical procedures performed during the course of their infection and about 3 to 4% of patients with AIDS will require major surgery.[1168] In order for health care workers to avoid risk of exposure to HIV during performance of procedures, adherence to universal precautions is a must. Procedures must have written guidelines, personal protective equipment must be readily available, and personnel must be trained. Equipment as simple as latex gloves can reduce by 50% the volume of blood transmitted in a needlestick injury. Double gloves compared to single gloves reduce the risk of perforation.[1182] Solid needles used in surgery do not carry as much blood through barriers as do hollow core needles. Avoidance of injury-prone techniques, such as recapping of needles, would eliminate many injuries. Nurses and laboratory personnel, particularly phlebotomists, have the greatest number of occupational infections.[176]

Risk of infection through reduction in blood contacts in the operating room may be decreased by:

1. Use of double gloves
2. Use of cut-resistant gloves
3. Use of instruments and not fingers to hold or retract tissues
4. Not picking up dropped or broken sharps with fingers
5. Keeping needle use to a minimum
6. Keeping track of sharp instruments in use
7. Use of blunt instruments where applicable
8. Use of fluid-resistant gowns when blood splashing to the body may occur
9. Use of face protection when blood splashing to the face may occur
10. Requiring non-operating room personnel to wear gloves and gowns while in the operating room

Surgical procedures in the operating room are associated with a 1.7 to 5% risk for blood exposure for personnel in that setting. The majority of these exposures are to skin and eye, and the majority could be avoided by use of gloves, face protection, and fluid-resistant gowns. Surgeons and scrub staff have the highest risk for percutaneous exposures, about 1 incident per 100 procedures. Blood contacts are more frequent when performing emergency procedures,

when patient blood loss exceeds 0.25 L, and when personnel are in the operating room longer than 1 hour. The greatest number of needle sticks occur on the surgeon's non-dominant hand, indicating that injuries could be significantly reduced if maneuvers such as palpation of a suture needle and use of a retractor rather than fingers to hold tissues were avoided.[1168,1183,1184] There have been no documented cases of accidental transmission of HIV to a patient during surgery.[1185]

Adherence to universal precautions requires an ongoing effort on the part of all personnel. Ironically, lack of compliance is most acute in situations where risk of exposure is greatest--in emergency situations with profuse bleeding. The most common factors cited for lack of adherence in use of protective equipment include: insufficient time to put on protective equipment, interference with skillful maneuvers by protective equipment, and uncomfortable feel of protective equipment. The first excuse requires a reordering of priorities and a need to keep protective materials close at hand. The second and third excuses can be approached in training. Persons who begin their careers with proper training and routinely employ protective equipment are unlikely to encounter difficulties with use of such equipment.[1168,1186]

The major risk factor for the HIV-infected patient for operative morbidity and mortality is the extent of immunosuppression. The risk is increased when the CD4 count is below 200/ $\mu$ L and/or the HIV-1 viral load is >10,000 copies/mL. Complications from surgery in persons without this extent of immunosuppression in HIV infection are similar to the general population.[1187] HIV positive patients undergoing abdominal surgery with a lower CD4 lymphocyte count CD4 counts are more likely to require an urgent operation and experience a complication with increased mortality from the surgery.[1188]

## THE SURGICAL PATHOLOGY LABORATORY

Pathologists receive the greatest potential exposure to infectious agents in surgical pathology activities. Many specimens are received fresh from surgery without fixation. Surgical pathology activities should take place in a separate, well-lighted and ventilated room out of the main flow of traffic. The cutting bench and adjacent sink should be large enough for adequate manipulation of all submitted fresh or fixed tissues, including amputation and exenteration specimens. Provide a puncture-proof container for disposal of sharps--blades and needles. Work surfaces should be designed for easy cleanup and to withstand 0.5% sodium hypochlorite (bleach) disinfection.[1189]

Specimens sent to the laboratory for routine tissue processing should be in sealed, leak proof containers with fixative and within a second sealed, leak proof container. Requisition forms that accompany specimens should be handled in a manner that avoids contamination. If contaminated, copy the information on to a clean form. Avoid contamination of materials or equipment--reports, tapes, floppy disks, keyboards, telephones, etc.--that are used by others or are carried to non-contaminated clerical areas. Use dictation equipment that allows "hands-off" operation or that can be disinfected.

Personnel handling the surgical specimens should wear a gown, protective mask and eyewear (or face shield), and disposable gloves. Practice careful dissection technique with good equipment and do not be hurried or distracted. Clean up and decontamination can be accomplished with detergents, followed by disinfection with bleach. Determine procedures and equipment for use when accidental spills or splashes occur. The barrier provided by latex gloves is compromised by disinfectants and fixatives, so that heavy duty or utility gloves may be needed for jobs with exposure to these chemicals.

Consider the cryostat a contaminated area. Wear the same protective gear as when dissecting a fresh specimen. Remember that freezing propellants can potentially spread infectious agents outside of the cryostat. Decontaminate the cryostat at regular intervals, using recommended disinfectants that will not harm sensitive surfaces or seals.

Specimens for histopathologic examination can be routinely fixed in 10% (v/v) neutral buffered formalin, or alternatively in mercurial fixatives (such as B5 or Zenker's) or Bouin's fixative. Cytologic smears can be fixed with 95% ethanol. HIV will be rendered inactive in tissues or smears by proper fixation. Fixatives may not thoroughly penetrate large tissue specimens. If specimens arrive in the histology laboratory in containers whose outer surfaces are contaminated with blood or body fluids, the surfaces can be disinfected by application of 0.5% sodium hypochlorite.

Saved tissues not blocked and embedded can be stored in fixative before discarding either via a tissue grinder attached to a sink or via incineration. Large specimens not suitable for fixation or tissues saved fresh must be placed in containers or bags marked as hazardous infectious waste before disposal in accordance with local statutes.

## THE AIDS AUTOPSY

The CDC has recommended protective masks and eyewear (or face shields), laboratory gowns, gloves, and waterproof aprons be worn when performing or attending all autopsies.[175] All autopsy material should be considered potentially infectious for both HIV and HBV. Onlookers with an opportunity for exposure to blood or fluid splashes should be similarly protected. Routine standard infection control practices should be employed for all cases. Use a detergent to clean bloody or soiled work surfaces, followed by 0.5% sodium hypochlorite as a disinfectant in ALL areas of the autopsy department, except on sensitive equipment, where alternative disinfectants are used (Table 9).[1190]

The best defense against accidents is good technique. Though many dissection skills in autopsy are similar to surgical pathology, some are unique and require specific training, such as evisceration of abdominal and thoracic organs or brain and spinal cord removal. A protective face shield is recommended with use of an oscillating saw, as with any power tool. Also available for use are hand protectors such as steel mesh gloves or "fishing" gloves of tough fabric, which may provide additional security with evisceration of organs.

Although disposable latex or vinyl gloves are quite reliable, leakage can occur, so double gloving is recommended.[1191] If cuts or abrasions on potentially exposed skin surfaces are present, they should be taped or covered before protective gear is put on. Persons performing frozen sections on HIV contaminated tissues using a cryostat designated for this purpose must be protected similarly to when handling fresh tissue.

Fixed tissues or fluids may be disposed of in a routine fashion through a tissue grinder to sanitary sewer or through incineration. Fresh tissues, blood, and body fluids can be autoclaved or placed in fixatives prior to disposal in accordance with local statutes. Formalin is the most cost-effective and efficacious fixative. Other contaminated wastes can be collected into marked, leak proof plastic bags and incinerated. Housekeeping personnel handling this material should use protective gear. Needles should never be recapped, and all needles or other sharp objects such as scalpel blades should be discarded into specifically designated containers.

Disposable paper scrub suits and gowns are often easier to work with and more cost-effective than cloth materials. If linen or other cloth scrub suits, gowns, or aprons are used they may be collected into bags that can be directly laundered without removal of the contents (bag dissolves in water).

The experience of the past decade in public hospitals and other centers performing large numbers of AIDS autopsies has shown that AIDS is not a threat to pathologists or other laboratory workers. There is no such thing as a "high risk" autopsy because the autopsy room environment can be well controlled. It is also unlikely that requirements for unusual, extraordinary, or unwieldy procedures will add a definable margin of safety, but such procedures may lead to accidents or failure of compliance. A system of standard, routine procedures should be followed at all times.[1192]



## MORTUARY AND FORENSIC LABORATORY PROCEDURES

There is minimal risk of exposure to HIV for funeral directors and licensed embalmers with use of proper precautions. Bodies they receive should be handled in designated work areas that can be routinely disinfected. Personnel handling the bodies should wear a protective waterproof gown or apron, mask and protective eyewear (or face shield), and disposable gloves. Needles and other sharp objects require careful handling with proper disposal into puncture-proof containers. A waterproof, leak proof shroud or body bag should be used for transport of bodies.

The CDC has made the following specific recommendations for personnel working in forensic laboratories:[175]

Blood from ALL individuals should be considered potentially infective. In order to supplement other work site precautions, the following precautions are recommended for workers in forensic laboratories.

1. All specimens of blood should be put in a well-constructed, appropriately labeled container with a secure lid to prevent leaking during transport. Care should be taken when collecting each specimen to avoid contaminating the outside of the container and the laboratory form accompanying the specimen.
2. All persons processing blood specimens should wear gloves. Masks and protective eyewear or face shields should be worn if mucous-membrane contact with blood is anticipated (e.g., removing tops from vacuum tubes). Hands should be washed after completion of specimen processing.
3. For routine procedures, such as histologic and pathologic studies or microbiological culturing, a biological safety cabinet is not necessary. However, biological safety cabinets (Class I or II) should be used whenever procedures are conducted that have a high potential for generating droplets. These include activities such as blending, sonicating, and vigorous mixing.
4. Mechanical pipetting devices should be used for manipulating all liquids in the laboratory. Mouth pipetting must not be done.
5. Use of needles and syringes should be limited to situations in which there is no alternative, and the recommendations for preventing injuries with needles outlined under universal precautions should be followed.
6. Laboratory work surfaces should be cleaned of visible materials and then decontaminated with an appropriate chemical germicide after a spill of blood, semen, or blood-contaminated body fluid when work activities are completed.

7. Contaminated materials used in laboratory tests should be decontaminated before reprocessing or be placed in bags and disposed of in accordance with institutional and local regulatory policies for disposal of infective waste.
8. Scientific equipment that has been contaminated with blood should be cleaned and then decontaminated before being repaired in the laboratory or transported to the manufacturer.
9. All persons should wash their hands after completing laboratory activities and should remove protective clothing before leaving the laboratory.
10. Area posting of warning signs should be considered to remind employees of continuing hazard of infectious disease transmission in the laboratory setting.

Workers in the forensic sciences or law enforcement officers routinely collect and preserve forensic specimens including needles, knives, or other sharp objects that may be contaminated with blood from a crime victim. Such objects represent a potential hazard to persons handling this evidence. These specimens also require handling through a proper chain of custody procedure to be used as evidence in court, so there is a need to preserve blood or fluids or specimens without decomposition, precluding the use of airtight containers for some specimens. The following basic guidelines are recommended:

1. Use puncture-proof, non-airtight containers for transportation of potentially contaminated evidence with sharp or cutting edges. Clearly mark these containers, **HANDLE WITH CARE**.
2. Sharp or pointed objects such as needles that are confiscated but not needed as evidence should be properly discarded into designated puncture-proof containers that are clearly labeled for use with infectious materials.
3. Each department should adopt standard safety procedures for search and seizure or collection of evidence to include initial handling, transportation, booking in evidence, storage, display, and disposal of potentially contaminated objects.

Specimens collected and transported in sealed containers that could undergo decomposition or degradation, such as blood for toxicologic studies, should be processed without delay. Such tissues or fluids obtained at the scene should be transported to the laboratory in sealed containers such as plastic bags, tubes with tight-fitting stoppers, or jars with screw-cap lids. These containers should be placed within a second sealed, leak proof container. Once in the laboratory, the specimens should be initially handled in a specified area by persons wearing protective clothing appropriate to the amount of manipulation of the specimen.[1193]

## ATHLETICS AND HIV INFECTION

Exercise has benefits for persons with chronic illness, including HIV infection. Exercise reduces fatigue, pain perception, depression and anxiety while increasing vigor. The wasting effects of HIV/AIDS can be offset by exercise. In addition, high intensity exercise activates the immune system. HIV infection and sports participation has raised issues regarding risks for participants. Sports participation is not a risk for transmission. Recommendations for prevention of transmission of blood-borne pathogens during sports have included education of athletes about approaches to prevention of sexually transmitted diseases and the risks associated with injectable drugs. When resources permit, hepatitis B vaccination should be made available. Athletes should not be excluded from participation in sports solely because they are infected with HIV or hepatitis virus.[1194,1195,1196,1197]

Persons with early to moderately advanced HIV infection can engage in moderate sport activities without risk to themselves or other participants. With the onset of AIDS, the ability to exercise can be compromised by disease conditions, and intensive bouts of competitive exercise should be avoided.[1198]

In the United States, the National Football League has also determined that a player with HIV infection poses virtually no threat to others or himself by athletic participation. The long latent period between initial HIV infection and the development of AIDS means that athletic performance is unlikely to be affected for many years.[1199]

The International Climbing and Mountaineering Federation (UIAA) determined that risk for HIV infection is unlikely in the sporting arena. They do not require mandatory testing for HIV, hepatitis B, and hepatitis C. They advised that HIV-positive climbers should not be banned from climbing or climbing competitions. They recommend a focus on preventive activities and education.[1200]

A complete set of guidelines regarding blood borne pathogens and sporting events have been adopted by the American Medical Society for Sports Medicine (AMSSM) and the American Academy of Sports Medicine (AASM).[1194,1201] The American Academy of Pediatrics have adopted similar guidelines as follows:[1202]

- Athletes with human immunodeficiency virus, hepatitis B virus or hepatitis C virus infection should be allowed to participate in all competitive sports.
- The infection status of patients should be kept confidential. Confidentiality about an athlete's infection with a blood-borne pathogen is necessary to prevent exclusion of the athlete from sports because of inappropriate fear among others in the program.
- Athletes should not be tested for blood-borne pathogens because they are sports participants.
- Physicians should counsel athletes who are infected with human immunodeficiency virus, hepatitis B virus and hepatitis C virus that they have a very small risk of infecting other athletes. These athletes can then consider choosing a sport with a low risk of virus transmission. This will not only protect other participants from infection but also will protect the infected athletes themselves by reducing their possible exposure to blood-borne pathogens other than the one(s) with which they are infected. Wrestling and boxing, a sport

opposed by the AAP, probably have the greatest potential for contamination of injured skin by blood.

- Athletic programs should inform athletes and their families that they have a very small risk of infection, but that the infection status of other players will remain confidential.
- Physicians and athletic program staff should aggressively promote hepatitis B virus immunization of all persons who may be exposed to athletes' blood. If possible, all athletes should receive hepatitis B virus immunization; more than 95 percent of persons who receive this immunization will be protected against infection.
- Coaches and athletic trainers should receive training in first aid and emergency care, and in the prevention of transmission of pathogens in the athletic setting.
- Coaches and health care team members should teach athletes about the precautions listed above and about high-risk activities that may cause transmission of blood-borne pathogens. Sexual activity and needle sharing during the use of illicit drugs, including anabolic steroids, carry a high risk of viral transmission. Athletes should be told not to share personal items, such as razors, toothbrushes and nail clippers, that might be contaminated with blood.
- In some states, depending on state law, schools may be required to comply with the Occupational Safety and Health Administration (OSHA) regulations for the prevention of transmission of blood-borne pathogens. The rules that apply must be determined by each athletic program. Compliance with OSHA regulations is a reasonable and recommended precaution, even if it is not required by the state.
- The AAP committee also recommends that the following precautions be taken in sports with direct body contact and sports in which an athlete's blood or other bodily fluids may contaminate the skin or mucous membranes of other participants or staff members of the athletic program.
- Athletes should cover existing cuts, abrasions, wounds or other areas of broken skin with an occlusive dressing before and during participation. Caregivers must also cover their own damaged skin to prevent transmission of infection to or from an injured athlete.
- Disposable, water-impervious vinyl or latex gloves should be worn to avoid contact with blood or other bodily fluids visibly tinged with blood and any object contaminated with these fluids. Hands should be cleaned with soap and water or an alcohol-based antiseptic hand wash as soon as gloves are removed.
- Athletes with active bleeding should be removed from competition immediately and bleeding should be stopped. Wounds should be cleaned with soap and water or skin antiseptics. Wounds should be covered with an occlusive dressing that remains intact during further play before athletes return to competition.

- Athletes should be told to report injuries and wounds in a timely fashion before or during competition.
- Minor cuts or abrasions that are not bleeding do not require interruption of play but can be cleaned and covered during scheduled breaks. During breaks, if an athlete's equipment or uniform is wet with blood, the equipment should be cleaned and disinfected and the uniform should be replaced.
- Equipment and playing areas contaminated with blood should be cleaned and disinfected with an appropriate germicide. The decontaminated equipment or area should be in contact with the germicide for at least 30 seconds. The area may be wiped with a disposable cloth after the minimum contact time or be allowed to air dry.
- Emergency care should not be delayed because gloves or other protective equipment is not available. If the caregiver does not have appropriate protective equipment, a towel may be used to cover the wound until a location off the playing field is reached and gloves can be obtained.
- Breathing bags and oral airways should be available for giving resuscitation. Mouth to mouth resuscitation is recommended only if this equipment is not available.
- Equipment handlers, laundry personnel and janitorial staff should be trained in the proper procedures for handling washable or disposable materials contaminated with blood.

## CHAPTER 7 - MEDICOLEGAL ISSUES AND AIDS

### DEATH INVESTIGATION AND CERTIFICATION IN AIDS

The medical examiner-coroner may need to conduct a comprehensive investigation, including an autopsy, in some deaths of HIV-infected persons. When an established diagnosis of AIDS by definitional criteria can be documented, an autopsy with histological confirmation of diagnosis may not always be necessary.[420,421] However, in cases in which the diagnosis is in doubt or in which death occurred under suspicious circumstances, an autopsy should be performed. Investigation of deaths with HIV infection from job-related or accidental parenteral exposure to blood or blood products require an autopsy with histopathologic and/or laboratory confirmation of findings to prepare for possible litigation by surviving family who may challenge the medical examiner's determination of the cause and mode of death.

A thorough external examination of the body may reveal typical findings with AIDS such as cachexia, needle tracks of intravenous narcotism, onychomycosis of nails, or skin lesions typical of Kaposi sarcoma. However, not all skin lesions appearing to be KS on gross examination are confirmed by microscopy. Use routine CDC criteria for AIDS as a guide in death investigation to search for data to confirm or exclude AIDS.[420,421] The presence of a medical record may document specific clinical findings, laboratory testing, or tissue diagnoses. In some states, reporting of laboratory testing for HIV may be strictly regulated, limiting availability of medical data. In the absence of definitive documented findings in available records, an internal examination should still be performed when doubt exists concerning either mode or underlying cause of death.[1190]

Additional information may be obtained either from autopsy with microscopic examination and/or postmortem microbiologic cultures of tissues or fluids or from postmortem laboratory testing for HIV infection, or both. Postmortem testing for HIV infection can be done on sera from blood, vitreous humor from the eye, and bile from gallbladder. Samples are stable at room temperature for at least one month. Testing by enzyme immunoassay and Western blot (WB) for antibodies to HIV is performed similarly to screening pre mortem samples.[1203,1204]

Viral culture of blood, fluids, or tissues for HIV is definitive for diagnosis of infection, but is difficult to perform and has very limited availability. If specimens for enzyme immunoassay or other serologic testing are not obtained at the time of autopsy, then HIV detection by *in situ* hybridization, polymerase chain reaction, and immunohistochemical methods can be carried out in formalin-fixed and paraffin embedded tissues--even years later. Microbiologic culture of opportunistic infectious agents in tissues or fluids is typically available in many laboratories for all agents except *Pneumocystis jiroveci* (*carinii*), *Toxoplasma gondii*, *Isospora belli*, and *Cryptosporidium*. Most of the remaining agents require special media, complex procedures, and several weeks' time for definitive results.[408,409,382]

### DETERMINATION OF CAUSE AND MODE OF DEATH WITH HIV INFECTION

Not all deaths in which HIV is present are caused by HIV. The proportion of deaths from AIDS-related causes has decreased when antiretroviral therapy (ART) is widely available, and non-AIDS conditions may account for at least a third of deaths, and may include non-natural

causes such as drug overdose, suicide, and violence.[1205] The mode or manner in which HIV was acquired is of particular importance. Always investigate for risk factors for HIV infection along with information obtained from scene investigation and postmortem examination of tissues and fluids.[1190]

Deaths of HIV-infected persons who have not developed the clinical syndromes of HIV infection and AIDS by definitional criteria are usually due to causes other than HIV. HIV-infected persons with a CD4 lymphocyte count  $>200/\mu\text{L}$ , or those with stages A and B of HIV-infection, are generally not at increased risk for death from HIV. As a rule, HIV infection should lead to clinically apparent consequences of immune deficiency meeting diagnostic criteria for AIDS in order to cause death.[1206]

The proximate causes of death in 565 cases with AIDS in a large autopsy series of patients dying prior to widespread use of antiretroviral therapy are given in Table 10. Over half of these deaths were due to pneumonia, either from *Pneumocystis jiroveci* (*carinii*) pneumonia, cytomegalovirus pneumonia, or bacterial bronchopneumonias. *Cryptococcus neoformans*, Kaposi sarcoma, and malignant lymphomas also frequently involved the lungs.

A study of causes of death in HIV-infected persons receiving antiretroviral therapy, from 1996 to 2006, showed that half of deaths were AIDS related. Remaining causes of death included 12% for non-AIDS malignancies, 8% for non-AIDS infections, 8% for non-natural deaths, 7% for liver disease, and 7% for cardiovascular disease. Death related to AIDS were less likely to occur with increasing length of use of antiretroviral therapy. AIDS-related deaths were more likely with high viral load ( $>100,000$  copies/mL).[1207]

A study of HIV-infected persons living in Europe, Israel, and Argentina tracked deaths occurring from 2001 to 2009 and found that there was a 4-fold increase in risk for death following an AIDS-defining event, but the risk was 7-fold following a non-AIDS event such as malignancies, cardiovascular disease, and renal disease. a doubling of the CD4 count was associated with a 37% reduction in the incidence of AIDS events. For non-AIDS events, a liver-related event such as hepatitis B or C viral infection was associated with the worst prognosis, over a 22-fold increased risk of death. Development of anemia was a very strong risk factor for both AIDS and non-AIDS events.[1208]

Continuing into the 21<sup>st</sup> century, as over the past 500 years, autopsy remains a useful tool for quality assurance, identifying the true prevalence of disease, and for research. A study of HIV-infected persons at autopsy showed that the findings from autopsy altered the primary diagnosis in 70% of cases, and that 36% of opportunistic infections were not diagnosed prior to death. Both false positive as well as false negative premortem diagnoses occurred despite sophisticated diagnostic techniques. Infections most likely to be missed prior to death were cytomegalovirus and tuberculosis.[1209]

The single most important organ to examine at autopsy is lung, and the commonest mechanism of death in AIDS is respiratory failure (in two thirds of cases). Central nervous system lesions lead to death in one fifth of AIDS patients, so it is important to remove and examine the brain at autopsy. Gastrointestinal diseases lead to death in one seventh of cases. Over 90% of the immediate causes of death in AIDS can be determined from histological examination alone.[448]

The differentiation of natural versus accidental mode of death with HIV infection and AIDS is made primarily by risk factors. If HIV was a sexually transmitted disease, including perinatal deaths in which the mother acquired HIV sexually, then the mode is natural. Identification of intravenous narcotism as the source of HIV infection establishes an accidental

mode of death. If transmission occurred from administration of blood or blood products in the course of therapy for natural disease (e.g., treatment of hemophilia, hemorrhage, or bone marrow failure) then the mode is natural. If HIV was acquired from transfusion of blood or blood products in the course of treating a victim of accident, suicide, or homicide, and the victim later died from HIV infection or AIDS as a result, then the mode is not altered from accident, suicide, or homicide. Death from HIV infection or AIDS as a consequence of HIV transmission through job-related exposure is an accidental mode also qualifying for workman's compensation benefits.

Proper death certification in AIDS has been and will continue to be important for generation of appropriate vital statistics upon which understanding of the epidemiology and extent of HIV infection will depend.[1210]



## ETHICAL ISSUES ARISING FROM THE AIDS PANDEMIC

HIV will continue to spread in the population due to several factors: (1) a large reservoir of millions of HIV-infected persons may not know they are infected. (2) knowledge of infection may not modify sexual behavior or other practices such as injection drug use. (3) there is no effective vaccine or curative treatment available. (4) even with knowledge of infection, basic human rights cannot be restricted enough to curb the spread of this disease.

In spite of mandatory testing of blood and blood products, cases of accidental exposure to HIV from these sources will rarely occur. Complex testing schemes have eliminated much of the risk, but the testing systems are not perfect. Additional HIV subtypes, such as HIV-2, may become prevalent. These problems will require even more complex screening programs, particularly in blood banking, and medical liability problems with blood products will continue to exist.

The adoption of the criterion that a CD4 lymphocyte count of  $<200/\mu\text{L}$  is indicative of AIDS when HIV infection is present has significance because the low CD4 count itself implies a high probability of HIV infection. Thus, laboratories and other agencies performing CD4 lymphocyte count must be aware of the implications of the test results and provide for confidentiality of testing, as with tests for HIV, where appropriate.

Discrimination against HIV-infected persons on the job or in the community will lead to conflicts. Recent court cases in the United States have established the rights of HIV-infected persons against discrimination on the job, in housing, and at school. This protection against discrimination has even been extended to health care workers who, though not infected by HIV, provide essential services for persons who are HIV-infected. The courts have not generally condoned discriminatory practices by health care workers against patients with HIV by refusing to offer treatment or by refusal to accept occupational hazards.[1211,1212]

Access of AIDS patients to new treatments not yet approved by governmental agencies will be debated. HIV-infected persons may knowingly donate blood or commit purposeful acts in an attempt to transmit the infection to others, prompting criminal charges. Clinical diagnosis or death certification of congenital AIDS may have implications for surviving family members with regard to placement of children in foster homes and investigation of parents. Death certification in cases of suspected AIDS may have profound sociopsychological and socioeconomic implications for surviving family members (i.e., insurance claims or risks of exposure relating to HIV infection).

The CDC have adopted guidelines which indicate that there is no basis either for mandatory HIV testing of health care workers or for restricting the practice of HIV-infected health care workers who perform non-exposure prone invasive procedures using recommended technique with adherence to universal precautions. Exposure prone procedures are to be delineated by organizations and institutions, which oversee medical or dental practice, and health care workers who perform such procedures should know their HIV status. HIV-infected health care workers should not perform exposure prone invasive procedures unless they have sought counsel from an expert review panel and have informed the patient. HIV-infected health care workers should, it is recommended, be provided opportunities to continue appropriate patient-care activities through career counseling and job retraining.[1213,1214]

The risk for HIV infection from infected patients to health care workers, or from health care workers to patients, cannot be completely eliminated, but remains negligible. Screening of

health care workers for HIV is not cost-effective.[1215] The risk for transmission of HIV to a patient from an infected surgeon has been estimated to be comparable to the risk of HIV transmission after transfusion of blood screened for HIV and less than the risk from general anesthesia. To date, only two health care workers (a dentist and a surgeon) have been implicated in transmission of HIV to patients. For the future, risk reduction will be best accomplished via thorough infection control measures rather than reliance upon workplace restrictions or upon mandatory HIV testing.[176,1216,1217]

## HIV TESTING AND COUNSELING

Testing for HIV infection in patients has become an important issue for health care professionals in many disciplines and locations, not just for those in large metropolitan areas. Patients must receive adequate HIV test counseling and education. The mainstay of initial HIV testing in developed nations is the EIA test for HIV antibody, with all initial positives confirmed by a second more specific test, usually a Western blot. False positive EIA tests or indeterminate Western blot tests can occur but will constitute a smaller fraction of the total positives as the prevalence of HIV infection increases in the population tested. In addition to initial testing, the patient should be informed that additional testing may be warranted because HIV antibodies may not appear for 6 to 12 weeks (and rarely longer) after primary infection or because indeterminate results may appear. The patient should be provided with counseling and support as necessary to deal with the stress involved in testing and waiting for results.[187,270,370,401]

Persons to be tested should be identified primarily on the basis of their history of risk factors for HIV infection (Table 2). The history taking must include very frank, but non-judgmental and open-ended questions, which are asked in order to elicit specific risks related to sexual behavior and drug use. In the course of taking a history and performing a physical examination, findings that suggest the presence of sexually transmitted diseases, opportunistic infections or neoplasms characteristic of HIV infection, or physical findings of acute or advanced HIV infection should suggest the need for HIV testing. Health care professionals who display compassionate care and allow the patient to ask questions and express feelings through open communication will provide the best setting in which testing can proceed in the best interests of the patient as well as allow for educational efforts to be successful. Patient education should include information about: how HIV is spread, what can be done to decrease the risk of HIV infection, how HIV infection affects the body, what danger exists to others from an infected person, what treatments are available, and what the course of the disease is to the final outcome--death.[125,142,172,181,184,270]

Patients should be informed that some facilities may offer "anonymous" HIV testing in which no specific identifying information about them is collected. Such anonymous testing will provide the patient only with a positive or negative result outside of the context of continuing medical care, and additional care will require informing a physician about such results. Patients should be informed that "confidential" testing by most health care facilities requires specific patient consent and that positive results will be reported to public health officials as required by law. Health care professionals should obtain consent for such confidential testing according to local statutes and should be aware of the minimum age at which persons can legally give consent. Physicians should also be aware of the need to maintain confidentiality of additional test results such as total lymphocyte or CD4 lymphocyte counts, microbiologic cultures, or tissue diagnoses (e.g., Kaposi sarcoma) which have strong implications concerning possible HIV infection.[1218]

Persons who have been tested should be provided with the opportunity to obtain and freely discuss the results with the physician.[1219,1220] Even if the result is negative, such a session provides an opportunity to reinforce the educational information about HIV. A positive result should be discussed in regard to understanding what this result means about life expectancy, the need for eventual medical care and treatment, the need to inform others who have been exposed to HIV, the need to modify behaviors to reduce the risk for spread to others,

and the need for psychological and social support services.[270] A significant problem is the failure of persons tested to return for results. The use of rapid HIV testing for screening (results in less than an hour) leads to a greater number of new HIV infections detected and in fewer patients leaving before test results are obtained.[1221]

Pregnant women represent an important group for whom HIV testing can provide considerable benefit. This is because of the significant reduction in perinatal HIV transmission that can be accomplished by giving mothers-to-be antiretroviral therapy.[199]

Mandatory testing remains controversial. The stigma associated with a diagnosis of HIV infection continues to prevent infected persons from being treated similar to patients with most other illnesses. This makes HIV testing less than routine. In the U.S., mandatory testing has been applied to personnel in the armed forces, Foreign Service personnel, immigrants, and certain sex offenders. Other jurisdictions, including some of the individual states in the U.S., have mandated testing for additional populations, including prisoners and newborns. Many states provide for compulsory testing of patients to determine their HIV status when an injury to a health care worker may involve possible HIV transmission.[1211]

In the U.S., the results of HIV testing for medical purposes are generally held to be confidential. Most states have laws protecting confidentiality of HIV-related information. However, all states require reporting of all patients diagnosed with AIDS to governmental health departments, though little more than half of the states require similar reporting for HIV infection. A “duty to warn” other persons, including spouses and sex partners, regarding a patient’s HIV positivity by health care providers is specifically permitted by law in some states, though the courts have ruled that the health care provider has a duty to warn persons at risk for infection.[1211]

## BLOOD AND TISSUE BANKING AND AIDS

The AIDS pandemic has markedly modified screening procedures in blood and tissue banks. Transfusion-associated AIDS early in the epidemic accounted for some cases of AIDS, particularly in persons with hemophilia. Current and future retroviral laboratory screening tests for HIV, first initiated in 1985 in the U.S., have eliminated virtually all of the risk. In the U.S. blood products are currently screened for antibodies to HIV1/2, HTLVII/II, hepatitis B, hepatitis C (HCV) and syphilis. Testing is also performed for donor ALT (SGOT) levels, for the presence of hepatitis B surface antigen, human immunodeficiency virus (HIV) p24 antigen and, using nucleic acid amplification testing (NAT), for HIV and HCV nucleic acids. Despite excellent methodology, however, the tests employed are not perfect, and blood-containing HIV may very rarely be released for transfusion. Since patients receiving transfusions may die from their primary disease or other causes prior to onset of AIDS, then the overall risk for transmission HIV infection from transfusion is extremely small---on average only 1 case in 1 900 000 single donor units of screened blood in the U.S.[177] For the years 2006 to 2009 the incidence was estimated to be 1 in 8 000 000 donations in a Canadian study.[178] This risk remains low with repeat blood donors.[1222] Behavioral risk factor screening appears to be effective in reducing the risk for HIV infection through blood products.[1223]

In populations with a low prevalence of HIV, including most developed nations, the risk for HIV transmission by blood products is very low, while in some larger metropolitan areas or in parts of Africa or Asia, the risk is higher. In sub-Saharan Africa, the risk is 1 per 1000 units for HIV, 4 per 1000 units for HBV, and 2.5 per 1000 units for HCV.[1224] In developing nations where blood screening is not rigorous, 5 to 10% of HIV infections may be acquired through use of blood products. Despite economic hardships in many regions, the screening of blood donors for HIV is a cost-effective strategy to prevent the spread of HIV, particularly in areas where seroprevalence of HIV is >5%. Additional strategies to reduce the spread of transfusion-associated HIV infection include: elimination of paid donors, reduction in use of family members to donate blood for a patient, institution of guidelines for judicious use of transfusion therapy, and prevention of severe anemias.[179] During the first decade of the 21<sup>st</sup> century, 80.7 million blood units were collected globally in 167 countries during 2004-2005, of which 77.3 million were tested for HIV and at least 0.6 million of the remaining 3.4 million donations went untested. Of 192 United Nations member countries, 125 reported 100% compliance with HIV testing of donated blood.[1225]

Current screening tests include EIA for both HIV-1 and HIV-2 (though the prevalence of the latter outside of West Africa is very low) and HIV-1 p24 antigen.[1226] Addition of testing for HIV-1 p24 antigen, which can detect some newly HIV-infected persons in the EIA seronegative "window," is estimated to find approximately one infected blood donor per 6 million donations in the U.S.[179] As EIA screening test performance improves, the seronegative window period becomes more important. Nucleic acid amplification tests (NAT) for HIV RNA have reduced the window period more than p24 testing, reducing the risk of HIV transmission from blood products to less than 1 in 1 900 000, but show poor cost-effectiveness.[1227] The cost effectiveness of NAT-based screening is estimated to be \$4.7 to 11.8 million U.S. dollars per quality-adjusted life-year.[1228] In populations where the incidence of new HIV infections is increasing, this potential window error becomes more

important.[1229] Testing by donor centers in the U.S. since 1989 is also routinely performed for HTLV I and HTLV II.[119]

In addition, screening questions applied to potential donors are aimed at determination of possible high-risk behaviors which exclude them as donors (sex with another man even once, injection drug use, etc.) and symptoms of infection (generalized lymph node enlargement, mucocutaneous lesions, weight loss, etc.). Blood collection facilities also employ a confidential unit exclusion form which provides donors who are under duress to donate, but do not want to resist or answer truthfully for fear of being detected with HIV infection, to designate their blood as unsuitable for transfusion. Such donor self-deferral is effective in reducing the risk of HIV transmission through transfusion of blood products.[1230] Autologous donations for elective surgical procedures have been encouraged, but directed donations have been found to be no safer than the routine blood supply.[119,1231]

In addition to donor screening, blood processing technology can provide safeguards for transfusion therapy. Whole blood fractionation can include viral reduction treatments that include viral inactivation steps in which mainly enveloped viruses are killed as well as viral removal steps where mainly non-enveloped viruses are partitioned into specific fractions. As a consequence, there have been no documented transmissions since the late 1980's of HIV, hepatitis B virus, and hepatitis C virus by blood products that have been subjected to such inactivation treatments. This includes blood plasma and derivatives.[1232]

Liability problems for blood banks stem from the few blood products that have transmitted HIV to recipients. In the U.S., courts in some jurisdictions have held that as long as blood suppliers meet professional standards of practice they are immune from liability. However, in other jurisdictions, blood suppliers have been found negligent despite meeting the established standard of care for the time period in which transmission of HIV occurred, implying that by maintaining liability there should be an incentive to adopt new precautionary measures to increase the safety level of the blood supply. Blood banks have also been held accountable for maintaining confidentiality of testing donors and for maintaining records of such testing. Many jurisdictions also require mandatory reporting of HIV positive donors. Thus, potential donors should be advised of the confidentiality protections as well as the circumstances under which test results will be disclosed.[1233]

AIDS patients may require transfusion therapy for cytopenias resulting from progression of their disease and from bone marrow suppression resulting from drug therapy for infections or neoplasms associated with AIDS. Additionally, zidovudine (ZDV) chemotherapy against HIV has as a side effect significant severe cytopenias in about 12% of patients who take this drug. Blood products administered to AIDS patients have the potential for graft versus host reactions, but there have been no significant studies to suggest that this occurs frequently. There is no evidence that viral or cytokine activation occurs following blood transfusion in patients with advanced HIV infection, and leukoreduction appears to have no clinical benefit.[1234].

Transplantation of human tissues and organs also carries the potential risk for HIV transmission. Transplantation involving kidney, liver, heart, pancreas, bone, and skin have been reported to be associated with this risk. Nucleic acid amplification testing may reduce the risk to 1 in 315,000 donors but a window period prior to seroconversion remains.[1235,1236] Autologous transplants do not carry this risk, except potentially via administrative errors. In addition, HIV transmission via artificial insemination from banked sperm has occurred. Human milk also carries a potential risk.[1237,1238]

Screening of potential donors through assessment of risk factors and through testing for HIV (enzyme immunoassay with Western blot confirmation) should be performed similar to that for blood donation. In the case of cadaveric donors, a history must be obtained from available family or friends. In either case, HIV screening must be completed within 12 to 24 hours to allow for viability of the transplant tissues. Recipient testing for HIV is recommended just prior to transplantation and 3, 6, and 12 months thereafter in order to identify and offer therapies to persons who may become infected.[1237,1238]

There is no current method for inactivating HIV in whole organs. Use of gamma irradiation will not eliminate HIV from in vitro samples.[1239] Human breast milk can be pasteurized to inactivate HIV.[1178,1237,1238]

## TABLES 1 - 10

**Table 1 - Body Fluids Containing HIV**

Fluids routinely associated with transmission of HIV

- Blood and blood components
- Semen
- Vaginal fluid
- Breast milk

Fluids not associated with transmission of HIV

- Saliva
- Urine
- Tears
- Sweat
- Cerebrospinal fluid



**Table 2 - Behavioral Risks for HIV Infection**

**Sexual Intercourse:** The following are associated with greater risk for HIV infection for both men and women, if one or both partners, either male or female, are infected:

- Practices that result in lacerations, tears, or denudation of penile, vaginal, rectal, or oral epithelia
- Increasing the number of sexual partners
- Presence of genital, rectal, or oral ulcers from other sexually transmitted diseases
- Not wearing a condom
- Being under the influence of alcohol or drugs which impair judgment and decision-making
- Engaging in sexual intercourse with a person whose stage of HIV infection is primary or advanced

More specific risks for a particular style of intercourse include:

**Vaginal Intercourse:**

- Lack of circumcision in the male
- Cervical ectopy
- Oral contraceptive use
- Pregnancy
- Menstrual bleeding

**Anal Intercourse:**

- Receptive anal intercourse > insertive anal intercourse, though either style is a risk
- Use of douches or lubricants

**Oral Intercourse**

- Presence of oral mucosal lesions
- Use of cocaine (e.g., "crack pipes")

**Lesbian Intercourse**

- Inclusion of male partners in sexual activities
- Practices (e.g., mutual use of dildos) that allow exchange of blood or vaginal fluid

**Blood Exposure:** Any practice that allows for exchange of HIV-infected blood from one person to another, regardless of age, sex, race, or state of health, represents a risk for HIV exposure:

- Injection drug use with sharing of needles or other "works"
- Use of needles "cleaned" with a disinfectant other than bleach
- Tattooing with sharing of devices (e.g., needles) used
- Blood rituals (e.g., "blood brothers") with commingling of blood
- Transfusion with inadequately screened or tested blood or blood products

**Congenital Exposure:** The fetus or infant of a mother who is infected with HIV is at risk for acquiring HIV infection, but this risk is increased with:

- Maternal elevated CD8+ lymphocyte count
- Maternal decreased CD4+ lymphocyte percentage
- Maternal chorioamnionitis or funisitis
- Persistent maternal fever
- Breast feeding of the infant

**Table 3 – Pharmacologic Agents for Antiretroviral Therapy****Nucleoside Reverse Transcriptase Inhibitors (NRTI's)**

Abacavir (ABC)  
 Didanosine (ddI)  
 Lamivudine (3TC)  
 Stavudine (d4T)  
 Zidovudine (ZDV, or AZT)

**Nucleotide Reverse Transcriptase Inhibitors**

Adefovir (ADV)  
 Cidofovir (CDV)  
 Emtricitabine (FTC)  
 Tenofovir (TDF)

**Non-Nucleoside Reverse Transcriptase Inhibitors (NNRTI's)**

Delavirdine (DLV)  
 Efavirenz (EFV)  
 Nevirapine (NVP)  
 Etravirine (ETV) – diarylpyrimidine  
 Rilpivirine (RPV) – diarylpyrimidine

**Protease Inhibitors (PI)**

Atazanavir (ATV)  
 Amprenavir (APV)  
 Darunavir (DRV)  
 Fosamprenavir (FPV)  
 Indinavir (IDV)  
 Lopinavir (LPV)  
 Nelfinavir (NFV)  
 Ritonavir (RTV)  
 Saquinavir (SQV)  
 Tipranavir (TPV) – non-peptidic

**Cell Fusion Inhibitor**

Enfuvirtide

**CCR5 Inhibitors**

Maraviroc  
 Vicriviroc

**Integrase Inhibitors**

Elvitegravir (EVG)  
 Raltegravir (RAL)  
 Dolutegravir (DTG)

**Maturation Inhibitor**

Bevirimat

**Table 4 - Definitive Diagnostic Techniques for Diseases Indicative of AIDS**

Indicator Disease for AIDS	Microscopy (cytology, histology)	Microbiologic Culture	Serum Serology	Clinical Criteria
Candidiasis	H&E,PAS,GMS	-	-	Gross Appearance
Cervical cancer	H&E	-	-	-
<i>Coccidioides immitis</i>	H&E,PAS,GMS	Fungal	Antigen	-
<i>Cryptococcus neoformans</i>	H&E,PAS,GMS	Fungal	Antigen	-
Cryptosporidium	H&E,AFB	-	-	-
Cytomegalovirus	H&E,IPX	Viral	Antigen	-
Encephalopathy, HIV	-	-	-	Clinical Features
Herpes simplex virus	H&E,IPX	Viral	Antigen	-
<i>Histoplasma capsulatum</i>	H&E,PAS,GMS	Fungal	Antigen	-
HIV wasting syndrome	-	-	-	Clinical Features
Isosporiasis	H&E,AFB	-	-	-
Kaposi sarcoma	H&E	-	-	-
LIP	H&E	-	-	-
Malignant Lymphoma	H&E,IPX	-	-	-
Mycobacteria	-	Mycobacterial	-	-
PML	H&E,IPX	-	-	-
<i>Pneumocystis pneumonia</i>	GMS,Giemsa,IPX	-	-	-
Pneumonia, recurrent	-	Routine	-	Clinical Features
Salmonellosis	-	Routine	-	-
<i>Toxoplasma gondii</i>	H&E,IPX	-	-	-

Key: H&E=routine hematoxylin and eosin stain; IPX=immunohistochemical method with specific monoclonal antibody; GMS=Gomori methenamine silver stain; PAS=periodic acid-Schiff stain; AFB=Ziehl-Neelsen or Kinyoun acid fast stain; Giemsa=Giemsa stain; LIP=lymphoid interstitial pneumonitis; PML=progressive multifocal leukoencephalopathy

**Table 5 - Documented Opportunistic Infections and Neoplasms in the Clinical Course  
and at Autopsy by Organ System in 565 Patients with AIDS: 1982-1993  
AIDS Autopsy Program, LAC+USC Medical Center, Los Angeles, California**

	PJP	CMV	CAND	KS	MAI	HERP	LYM	CRYP	MTB	TOXO	HIST	COCCI
TOTAL CASES	308	286	240	138	104	92	81	78	76	51	13	10
HEART	2	5	13	6	3	-	13	13	5	5	4	3
LUNG	305	133	44	56	30	1	27	47	63	6	10	10
UPPER RESP	-	6	18	41	2	1	-	3	1	2	1	-
ORAL CAVITY	-	3	144	37	1	10	1	4	1	1	-	-
ESOPHAGUS	-	41	55	27	1	10	3	3	-	-	2	-
STOMACH	-	34	18	46	2	-	14	8	5	2	2	-
SM. INTESTINE	-	40	8	61	27	-	18	7	9	-	5	1
COLON-RECTUM	-	43	6	45	9	5	17	6	4	1	4	-
PERIANAL	-	4	3	-	1	27	-	-	-	-	-	-
FEMALE GENITAL	-	1	3	-	-	2	1	2	-	-	-	-
MALE GENITAL	1	11	4	16	2	2	6	15	3	2	3	-
LOWER URINARY	1	6	5	3	1	-	9	-	-	1	-	-
KIDNEY	3	12	19	5	8	-	19	23	15	-	3	5
LIVER & GB	3	16	4	28	44	-	27	25	19	2	8	6
PANCREAS	2	16	1	9	1	-	10	18	4	2	2	-
SPLEEN	4	16	8	15	65	-	19	31	27	-	9	6
LYMPH NODE	12	8	6	59	86	-	31	43	40	-	11	8
BONE MARROW	1	-	2	2	25	-	17	12	9	2	7	3
BRAIN	-	40	9	-	3	3	22	65	5	44	-	2
EYE	2	49	1	1	-	3	-	1	-	1	1	-
PITUITARY	2	5	-	-	-	-	4	11	1	2	-	-
THYROID 2	15	5	1	2	-	3	14	4	-	2	4	
ADRENAL	3	209	2	11	15	-	18	20	6	2	5	-
SKIN	1	6	16	110	1	65	5	6	1	-	-	1

**Table 6 - Average Number of Organs or Organ Systems Involved  
by AIDS Diagnostic Diseases**

Coccidioidomycosis	6.2
Histoplasmosis	4.4
Malignant Lymphoma	3.8
Cryptococcosis	3.7
M. tuberculosis	3.3
M. avium-complex	3.3
Kaposi sarcoma	2.8
Cytomegalovirus	1.9
Candidiasis	1.4
Herpes	1.4
Toxoplasmosis	1.4
Pneumocystis jiroveci (carinii)	1.1
Cryptosporidiosis	1.1

**Table 7 - Therapies for Diseases Indicative of AIDS**

Disease Process	Clinical Therapy
Candidiasis, oral	Clotrimazole troches, topical nystatin
Candidiasis, esophageal	Clotrimazole troches, topical nystatin, fluconazole, ketoconazole
Candidiasis, vulvovaginal	Miconazole, clotrimazole suppositories
Cervical cancer	Surgical therapy
<i>Coccidioides immitis</i>	Amphotericin B
<i>Cryptococcus neoformans</i>	Amphotericin B with or without flucytosine; or fluconazole or itraconazole
Cryptosporidium	Paromomycin
Cytomegalovirus	Ganciclovir, foscarnet
Herpes simplex or zoster	Acyclovir
<i>Histoplasma capsulatum</i>	Amphotericin B, or itraconazole, or fluconazole
Isosporiasis	Trimethoprim-sulfamethoxazole
Microsporidium	Albendazole (for <i>Septata intestinalis</i> )
<i>Giardia lamblia</i>	Metronidazole
Kaposi sarcoma	Surgical therapy, chemotherapy, radiation therapy
LIP	None effective
Malignant Lymphoma	Chemotherapy, radiation therapy, surgical therapy
<i>M tuberculosis</i>	Isoniazid, rifampin, pyrazinamide, plus ethambutol for resistance
<i>M avium</i> complex	Rifabutin, clarithromycin, ethambutol
PML	Cytosine arabinoside
<i>P jiroveci</i> ( <i>carinii</i> ) pneumonia	Trimethoprim-sulfamethoxazole, or pentamidine, trimetrexate
Pneumonia, recurrent	Antibiotic therapy appropriate to sensitivity of bacteria cultured
Salmonellosis	Amoxicillin, trimethoprim-sulfamethoxazole, ciprofloxacin
<i>Toxoplasma gondii</i>	Pyrimethamine with sulfadiazine and folinic acid

Key: LIP=lymphoid interstitial pneumonitis; PML=progressive multifocal leukoencephalopathy

**Table 8 - Patterns of Pulmonary Involvement with AIDS-diagnostic Diseases**

Alveolar	Pneumocystis jiroveci (carinii) Cytomegalovirus Candida
Interstitial	Cryptococcus neoformans Histoplasma capsulatum M. avium-complex Lymphoid interstitial pneumonitis
Bronchovascular	Kaposi sarcoma Malignant lymphoma Lymphoid interstitial pneumonitis
Tracheobronchial	Candida Kaposi sarcoma
Pleural	Kaposi sarcoma M. tuberculosis
Granulomatous	M. tuberculosis Cryptococcus neoformans Histoplasma capsulatum

**Table 9 - Laboratory Disinfectants and Fixatives Effective Against HIV**  
**(adapted from Tierno, 1986)**

	Minimum Effective Concentration		Common Concentration to Use	
Household bleach (sodium hypochlorite)	0.02	%	0.5	%
Hydrogen peroxide	0.3	%	1-3	%
Rubbing alcohol (isopropyl alcohol)	30	%	50	%
Lysol	1	%	1	%
Quaternary ammonium chloride	0.08	%	1	%
Nonidet P-40	1	%	1	%
Ethanol (ethyl alcohol)	25	%	50-95	%
Beta-proprionolactone	1:400		1:400	
Formalin	2	%	4-10	%
Glutaraldehyde	0.1	%	1-2	%



**Table 10 - Immediate Causes of Death by Disease and Organ Failure  
in 565 Patients with AIDS at Autopsy: 1982-1993  
AIDS Autopsy Program, LAC+USC Medical Center, Los Angeles, CA**

Organ System Involved	Resp	CNS	GI	Endo	Liver	Heart	GU	BM	Skin	Totals
<i>Pneumocystis jiroveci</i>	170	-	-	-	-	-	-	-	-	170
Bronchopneumonia	52	-	-	-	-	-	-	-	-	52
Cytomegalovirus	31	9	4	4	-	-	-	-	-	48
Malignant Lymphoma	11	16	10	1	3	4	1	1	1	48
<i>Cs neoformans</i>	13	22	1	-	-	-	1	-	-	37
<i>M tuberculosis</i>	14	1	-	-	1	-	1	-	-	26
Septicemia	-	-	-	-	-	-	-	-	-	32
Kaposi sarcoma	19	-	6	-	-	-	-	-	-	25
<i>T gondii</i>	1	19	-	-	-	1	-	-	-	21
Encephalopathy	-	16	-	-	-	-	-	-	-	16
<i>M avium-intracellulare</i>	4	-	5	1	-	-	-	-	-	10
<i>H capsulatum</i>	6	1	1	-	1	-	-	-	-	9
<i>Candida</i>	6	2	-	-	-	-	1	-	-	9
<i>Cs immitis</i>	5	1	-	-	-	-	-	-	-	6
Aspergillosis	6	-	-	-	-	-	-	-	-	6
<i>Cryptosporidium</i>	-	-	5	-	-	-	-	-	-	5
HIV nephropathy	-	-	-	-	-	-	2	-	-	2
Miscellaneous	12	5	9	2	4	6	1	1	3	43
Total Occurrences										565

Key: Resp=respiratory system from epiglottis to lung; GI=gastrointestinal system; Endo=endocrine system;  
LN=lymph nodes; CNS=central nervous system; GU=genitourinary system; BM=bone marrow;  
PML=progressive multifocal leukoencephalopathy; HIV=human immunodeficiency virus

Encephalopathy includes: HIV encephalopathy 8, Progressive multifocal leukoencephalopathy 7, acute hemorrhagic leukoencephalopathy 1. Septicemia includes: Bacterial organisms 25, MAC 4, Candida 3

## REFERENCES

- 1 Weiss RA. Special anniversary review: twenty-five years of human immunodeficiency virus research: successes and challenges. *Clin Exp Immunol*. 2008;152:201-210.
- 2 Mayer K, Pizer HF, Venkatesh KK. The social ecology of HIV/AIDS. *Med Clin North Am*. 2008;92:1363-7135, x.
- 3 Cohen MS, Hellmann N, Levy JA, DeCock K, Lange J. The spread, treatment, and prevention of HIV-1: evolution of a global pandemic. *J Clin Invest*. 2008;118:1244-1254.
- 4 Centers for Disease Control and Prevention. The Global HIV/AIDS pandemic, 2006. *MMWR*. 2006;55:841-844.
- 5 Fauci AS. The AIDS epidemic: considerations for the 21<sup>st</sup> century. *N Engl J Med*. 1999;341:1046-1050.
- 6 Centers for Disease Control and Prevention (CDC). HIV surveillance—United States, 1981-2008. *MMWR Morb Mortal Wkly Rep*. 2011;60(21):689-693.
- 7 De Cock KM, Jaffe HW, Curran JW. The evolving epidemiology of HIV/AIDS. *AIDS*. 2012;26:1205-1213.
- 8 Kilmarx PH. Global epidemiology of HIV. *Curr Opin HIV AIDS*. 2009;4:240-246.
- 9 Lozano R, Naghavi M, Foreman K, Lim S, Shibuya K, Aboyans V, Abraham J, et al. Global and regional mortality from 235 causes of death for 20 age groups in 1990 and 2010: a systematic analysis for the Global Burden of Disease Study 2010. *Lancet*. 2012;380:2095-2128.
- 10 Bozzette SA, Berry SH, Duan N, et al. The care of HIV-infected adults in the United States. *N Engl J Med*. 1998;339:1897-1904.
- 11 Whiteside A. Demography and economics of HIV/AIDS. *Br Med Bull*. 2001;58:73-88.
- 12 Harrison KM, Song R, Zhang X. Life expectancy after HIV diagnosis based on national HIV surveillance data from 25 states, United States. *J Acquir Immune Defic Syndr*. 2010;53:124-130.
- 13 Field MG. Global Health: HIV and AIDS in the former Soviet bloc. *N Engl J Med*. 2004;351:117-120.
- 14 Ruxrungtham K, Brown T, Phanuphak P. HIV/AIDS in Asia. *Lancet* . 2004;364:69-79.

- 
- 15 Okie S. Fighting HIV – lessons from Brazil. *N Engl J Med*. 2006;354:1977-1981.
  - 16 Centers for Disease Control and Prevention. Evolution of HIV/AIDS prevention programs--United States, 1981-2006. *MMWR*. 2006;55:597-603.
  - 17 Gottlieb MS. AIDS—past and future. *N Engl J Med*. 2001;344:1788-1791.
  - 18 Lert F. Advances in HIV treatment and prevention: should treatment optimism lead to prevention pessimism? *AIDS Care*. 2000;12:745-755.
  - 19 Blocker ME, Cohen MS. Biologic approaches to the prevention of sexual transmission of human immunodeficiency virus. *Infect Dis Clin North Am*. 2000;14:983-999.
  - 20 Centers for Disease Control. Advancing HIV Prevention: New Strategies for a Changing Epidemic --- United States, 2003. *MMWR*. 2003;52:329-332.
  - 21 Fauci AS. Multifactorial nature of human immunodeficiency virus disease: implications for therapy. *Science*. 1993;262:1011-1018.
  - 22 Sierra S, Kupfer B, Kaiser R. Basics of the virology of HIV-1 and its replication. *J Clin Virol*. 2005;34:233-244.
  - 23 Emerman M, Malim MH. HIV-1 regulatory/accessory genes: keys to unraveling viral and host cell biology. *Science*. 1998;280:1880-1884.
  - 24 Heeney JL, Dalgleish AG, Weiss RA. Origins of HIV and the evolution of resistance to AIDS. *Science*. 2006;313:462-466.
  - 25 Sharp PM, Hahn BH. Origins of HIV and the AIDS pandemic. *Cold Spring Harb Perspect Med*. 2011;1(1):a006841.
  - 26 Heneine W, Switzer WM, Sandstrom P, et al. Identification of a human population infected with simian foamy viruses. *Nat Med*. 1998;4:403-407.
  - 27 Ayoub A, Akoua-Koffi C, Calvignac-Spencer S, Esteban A, Locatelli S, Li H, Li Y, et al. Evidence for continuing cross-species transmission of SIVsmm to humans: characterization of a new HIV-2 lineage in rural Côte d'Ivoire. *AIDS*. 2013;27:2488-2491.
  - 28 Zhu T, Korber BT, Nahmias AJ, Hooper E, Sharp PM, Ho DD. An African HIV-1 sequence from 1959 and implications for the origin of the epidemic. *Nature*. 1998;391:594-597.

- 
- 29 Barré-Sinoussi F, Chermann JC, Rey F, et al. Isolation of a T-lymphotropic retrovirus from a patient at risk for acquired immunodeficiency syndrome (AIDS). *Science*. 1983;220:868-871.
- 30 Levy JA. HIV pathogenesis: 25 years of progress and persistent challenges. *AIDS*. 2009;23:147-160.
- 31 Pépin J. The origins of AIDS: from patient zero to ground zero. *J Epidemiol Community Health*. 2013;67(6):473-475.
- 32 Greene WC. AIDS and the immune system. *Sci Am*. 1993;269:98-105.
- 33 Sundquist WI, Kräusslich H-G. HIV-1 Assembly, Budding, and Maturation. *Cold Spring Harb Perspect Med*. 2012 Jul;2(7):a006924. doi: 10.1101/cshperspect.a006924.
- 34 Orenstein JM. Ultrastructure of HIV/AIDS. *Ultrastruct Pathol*. 2002;26:245-250.
- 35 Moir S, Chun TW, Fauci AS. Pathogenic mechanisms of HIV disease. *Annu Rev Pathol*. 2011;6:223-248.
- 36 Romani B, Engelbrecht S, Glashoff RH. Functions of Tat: the versatile protein of human immunodeficiency virus type 1. *J Gen Virol*. 2010;91(Pt 1):1-12.
- 37 Malim MH, Emerman M. HIV-1 accessory proteins--ensuring viral survival in a hostile environment. *Cell Host Microbe*. 2008;3:388-398.
- 38 Belyakov IM, Berzofsky JA. Immunobiology of mucosal HIV infection and the basis for development of a new generation of mucosal AIDS vaccines. *Immunity*. 2004;20:247-253.
- 39 Keele BF, Estes JD. Barriers to mucosal transmission of immunodeficiency viruses. *Blood*. 2011;118(4):839-846.
- 40 Tugizov SM, Herrera R, Velupillai P, Greenspan D, Soros V, Greene WC, Levy JA, Palefsky JM. Differential transmission of HIV traversing fetal oral/intestinal epithelia and adult oral epithelia. *J Virol*. 2012;86(5):2556-2570.
- 41 Bobardt MD; Chatterji U; Selvarajah S; Van der Schueren B; David G; Kahn B; Gallay PA. Cell-free human immunodeficiency virus type 1 transcytosis through primary genital epithelial cells. *J Virol*. 2007;81:395-405.
- 42 Kaushic C. HIV-1 infection in the female reproductive tract: role of interactions between HIV-1 and genital epithelial cells. *Am J Reprod Immunol*. 2011;65(3):253-260.

- 
- 43 Bobardt MD; Saphire AC; Hung HC; Yu X; Van der Schueren B; Zhang Z; David G; Gallay PA. Syndecan captures, protects, and transmits HIV to T lymphocytes. *Immunity*. 2003;18:27-39.
- 44 Stebbing J, Gazzard B, Douek DC. Mechanisms of disease: where does HIV live? *N Engl J Med*. 2004;350:1872-1880.
- 45 Magérus-Chatinet A, Yu H, Garcia S, Ducloux E, Terris B, Bomsel M. Galactosyl ceramide expressed on dendritic cells can mediate HIV-1 transfer from monocyte derived dendritic cells to autologous T cells. *Virology*. 2007;362:67-74.
- 46 Lucas S, Nelson AM. HIV and the spectrum of human disease. *J Pathol*. 2015;235(2):229-241.
- 47 Gomez C, Hope TJ. The ins and outs of HIV replication. *Cell Microbiol*. 2005;7:621-626.
- 48 Lusso P. HIV and the chemokine system: 10 years later. *EMBO J*. 2006;25:447-456.
- 49 Murdoch C, Finn A. Chemokine receptors and their role in inflammation and infectious diseases. *Blood*. 2000;95:3032-3043.
- 50 Lackner AA, Mohan M, Veazey RS. The gastrointestinal tract and AIDS pathogenesis. *Gastroenterology*. 2009;136:1965-1978.
- 51 O'Brien SJ, Moore JP. The effect of genetic variation in chemokines and their receptors on HIV transmission and progression to AIDS. *Immunol Rev*. 2000;177:99-111.
- 52 Rottman JB, Ganley KP, Williams K, Wu L, Mackay CR, Ringler DJ. Cellular localization of the chemokine receptor CCR5. Correlation to cellular targets of HIV-1 infection. *Am J Pathol*. 1997;151:1341-1351.
- 53 Campbell EM, Hope TJ. Live cell imaging of the HIV-1 life cycle. *Trends Microbiol*. 2008;16:580-587.
- 54 Pantaleo G, Graziosi C, Fauci AS. The immunopathogenesis of human immunodeficiency virus infection. *N Engl J Med*. 1993;328:327-335.
- 55 Vandegraaff N, Engelman A. Molecular mechanisms of HIV integration and therapeutic intervention. *Expert Rev Mol Med*. 2007;9:1-19.
- 56 Jouvenet N, Simon SM, Bieniasz PD. Visualizing HIV-1 assembly. *J Mol Biol*. 2011;410:501-511.
- 57 Briggs JA, Kräusslich HG. The molecular architecture of HIV. *J Mol Biol*. 2011;410(4):491-500.

- 
- 58 Pantaleo G, Graziosi C, Demarest JF, Butini L, Montroni M, Fox CH, Orenstein JM, et al. HIV infection is active and progressive in lymphoid tissue during the clinically latent stage of disease. *Nature*. 1993;362:355-358.
- 59 Verani A, Gras G, Pancino G. Macrophages and HIV-1: dangerous liaisons. *Mol Immunol*. 2005;42:195-212.
- 60 Ballana E, Pauls E, Senserrich J, Clotet B, Perron-Sierra F, Tucker GC, Este JA. Cell adhesion through alphaV-containing integrins is required for efficient HIV-1 infection in macrophages. *Blood*. 2009;113:1278-1286.
- 61 Said EA, Dupuy FP, Trautmann L, et al. Programmed death-1-induced interleukin-10 production by monocytes impairs CD4+ T cell activation during HIV infection. *Nat Med*. 2010;16:452-459.
- 62 Koppensteiner H, Brack-Werner R, Schindler M. Macrophages and their relevance in Human Immunodeficiency Virus Type I infection. *Retrovirology*. 2012;9:82.
- 63 Altfeld M, Fadda L, Frleta D, Bhardwaj N. DCs and NK cells: critical effectors in the immune response to HIV-1. *Nat Rev Immunol*. 2011;11:176-186.
- 64 Kottilil S, Shin K, Jackson JO, et al. Innate immune dysfunction in HIV infection: effect of HIV envelope-NK cell interactions. *J Immunol*. 2006;176:1107-1114.
- 65 Stevenson M. HIV-1 pathogenesis. *Nat Med*. 2003;9:853-860.
- 66 Fantuzzi L, Purificato C, Donato K, Belardelli F, Gessani S. Human immunodeficiency virus type 1 gp120 induces abnormal maturation and functional alterations of dendritic cells: a novel mechanism for AIDS pathogenesis. *J Virol*. 2004;78:9763-9772.
- 67 McMichael AJ, Borrow P, Tomaras GD, Goonetilleke N, Haynes BF. The immune response during acute HIV-1 infection: clues for vaccine development. *Nat Rev Immunol*. 2010;10:11-23.
- 68 Gougeon ML. Apoptosis as an HIV strategy to escape immune attack. *Nat Rev Immunol*. 2003;3:392-404.
- 69 Levine B, Sodora DL. HIV and CXCR4 in a kiss of autophagic death. *J Clin Invest*. 2006;116:2078-2080.
- 70 Doitsh G, Galloway NL, Geng X, Yang Z, Monroe KM, Zepeda O, Hunt PW, et al. Cell death by pyroptosis drives CD4 T-cell depletion in HIV-1 infection. *Nature*. 2014;505(7484):509-514.

- 
- 71 Klein SA, Dobmeyer JM, Dobmeyer TS, Pape M, Ottmann OG, Helm EB, Hoelzer D, Rossol R. Demonstration of the T<sub>H</sub>1 to T<sub>H</sub>2 cytokine shift during the course of HIV-1 infection using cytoplasmic cytokine detection on single cell level by flow cytometry. *AIDS*. 1997;11:1111-1118.
- 72 Pizzolo G, Vinante F, Morosato L, Nadali G, Chilosi M, Gandini G, Sinicco A, et al. High serum level of the soluble form of CD30 molecule in the early phase of HIV-1 infection as an independent predictor of progression to AIDS. *AIDS*. 1994;8:741-745.
- 73 Marone G, Florio G, Petraroli A, Triggiani M, dePaulis A. Role of human FcεpsilonRI+ cells in HIV-1 infection. *Immunol Rev*. 2001;179:128-138.
- 74 El Hed A, Khaitan A, Kozhaya L, Manel N, Daskalakis D, Borkowsky W, Valentine F, et al. Susceptibility of human T<sub>H</sub>17 cells to human immunodeficiency virus and their perturbation during infection. *J Infect Dis*. 2010;201:843-854.
- 75 Klatt NR, Brenchley JM. T<sub>H</sub>17 cell dynamics in HIV infection. *Curr Opin HIV AIDS*. 2010;5:135-140.
- 76 Streeck H, Nixon DF. T cell immunity in acute HIV-1 infection. *J Infect Dis*. 2010;202 Suppl 2:S302-S308.
- 77 Sundstrom JB, Ellis JE, Hair GA, Kirshenbaum AS, Metcalfe DD, Yi H, Cardona AC, et al. Human tissue mast cells are an inducible reservoir of persistent HIV infection. *Blood*. 2007;109:5293-5300.
- 78 Cribbs SK, Lennox J, Caliendo AM, Brown LA, Guidot DM. Healthy HIV-1-infected individuals on highly active antiretroviral therapy harbor HIV-1 in their alveolar macrophages. *AIDS Res Hum Retroviruses*. 2015;31:64-70.
- 79 Popov S, Chenine A-L, Gruber A, Li P-L, Ruprecht RM. Long-term productive human immunodeficiency virus infection of CD1a-sorted myeloid dendritic cells. *J Virol*. 2005;79:1602-1608.
- 80 Martin N, Sattentau Q. Cell-to-cell HIV-1 spread and its implications for immune evasion. *Curr Opin HIV AIDS*. 2009;4:143-149.
- 81 Pomerantz RJ. HIV-1 reservoirs. *Clin Lab Med*. 2002;22:651-680.
- 82 Martin JC, Bandres JC. Cells of the monocyte-macrophage lineage and pathogenesis of HIV-1 infection. *J Acquir Immune Defic Syndr*. 1999;22:413-429.

- 
- 83 Simonitsch I, Geusau A, Chott A, Jurecka W. Cutaneous dendritic cells are main targets in acute HIV-1 infection. *Mod Pathol*. 2000;13:1232-1237.
- 84 Keele BF, Tazi L, Gartner S, Liu Y, Burgon TB, Estes JD, Thacker TC, et al. Characterization of the follicular dendritic cell reservoir of human immunodeficiency virus type 1. *J Virol*. 2008;82:5548-5556.
- 85 Orenstein JM. Hyperplastic lymphoid tissue in HIV/AIDS: an electron microscopic study. *Ultrastruct Pathol*. 2008;32:161-169.
- 86 Lore K, Larsson M. The role of dendritic cells in the pathogenesis of HIV-1 infection. *APMIS*. 2003;111:776-788.
- 87 Jeeninga RE, Westerhout EM, van Gerven ML, Berkhout B. HIV-1 latency in actively dividing human T cell lines. *Retrovirology*. 2008;5:37.
- 88 Chevalier MF, Weiss L. The split personality of regulatory T cells in HIV infection. *Blood*. 2013;121:29-37.
- 89 Paiardini M, Müller-Trutwin M. HIV-associated chronic immune activation. *Immunol Rev*. 2013;254:78-101.
- 90 Haase AT. Population biology of HIV-1 infection: viral and CD4+ T cell demographics and dynamics in lymphatic tissues. *Annu Rev Immunol*. 1999;17:625-656.
- 91 Thompson KA, Cherry CL, Bell JE, McLean CA. Brain cell reservoirs of latent virus in presymptomatic HIV-infected individuals. *Am J Pathol*. 2011;179(4):1623-1629.
- 92 Ball JK, Holmes EC, Whitwell H, Desselberger U. Genomic variation of human immunodeficiency virus type 1 (HIV-1): molecular analyses of HIV-1 in sequential blood samples and various organs obtained at autopsy. *J Gen Virol*. 1994;75:67-79.
- 93 Coffin JM. HIV population dynamics in vivo: implications for genetic variation, pathogenesis, and therapy. *Science*. 1995;267:483-489.
- 94 Ho DD, Neumann AU, Perelson AS, et al. Rapid turnover of plasma virions and CD4 lymphocytes in HIV-1 infection. *Nature*. 1995;373:123-126.
- 95 Young B, Kuritzkes DR. Viral kinetics: implications for treatment. *AIDS*. 1999;13(Suppl 1):S11-S17.
- 96 Appay V, Sauce D. Immune activation and inflammation in HIV-1 infection: causes and consequences. *J Pathol*. 2008;214:231-241.



- 
- 97 Lehner T, Wang Y, Pido-Lopez J, Whittall T, Bergmeier LA, Babaahmady K. The emerging role of innate immunity in protection against HIV-1 infection. *Vaccine*. 2008;26:2997-3001.
  - 98 Perez-Caballero D, Zang T, Ebrahimi A, McNatt MW, Gregory DA, Johnson MC, Bieniasz PD. Tetherin inhibits HIV-1 release by directly tethering virions to cells. *Cell*. 2009;139:499-511.
  - 99 Furrer H, Wendland T, Minder C, et al. Association of syncytium-inducing phenotype of HIV-1 with CD4 cell count, viral load, and sociodemographic characteristics. *AIDS*. 1998;12:1341-1346.
  - 100 Plantier JC, Damond F, Lasky M, et al. V3 serotyping of HIV-1 infection: correlation with genotyping and limitations. *J Acquir Immune Defic Syndr Hum Retrovirol*. 1999;20:432-441.
  - 101 Knight SC, Patterson S. Bone marrow-derived dendritic cells, infection with human immunodeficiency virus, and immunopathology. *Annu Rev Immunol*. 1997;15:593-615.
  - 102 Hu DJ, Buvé A, Baggs J, van der Groen G, Dondero TJ. What role does HIV-1 subtype play in transmission and pathogenesis? An epidemiologic perspective. *AIDS*. 1999;13:873-881.
  - 103 Neel C, Etienne L, Li Y, Takehisa J, Rudicell RS, Bass IN, Moudindo J, et al. Molecular epidemiology of simian immunodeficiency virus infection in wild-living gorillas. *J Virol*. 2010;84:1464-1476.
  - 104 Taylor BS, Sobieszczyk ME, McCutchan FE, Hammer SM. The challenge of HIV-1 subtype diversity. *N Engl J Med*. 2008;358:1590-1602.
  - 105 Jaffe HW, Schochetman G. Group O human immunodeficiency virus-1 infections. *Infect Dis Clin North Am*. 1998;12:39-46.
  - 106 Simon F, Mauclore P, Roques P, et al. Identification of a new human immunodeficiency virus type 1 distinct from group M and group O. *Nat Med*. 1998;4:1032-1037.
  - 107 Geretti AM. HIV-1 subtypes: epidemiology and significance for HIV management. *Curr Opin Infect Dis*. 2006;19:1-7.
  - 108 Hemelaar J, Gouws E, Ghys PD, Osmanov S; WHO-UNAIDS Network for HIV Isolation and Characterisation. Global trends in molecular epidemiology of HIV-1 during 2000-2007. *AIDS*. 2011;25(5):679-689.

- 
- 109 Essex M. Human immunodeficiency viruses in the developing world. *Adv Virus Res.* 1999;53:71-88.
- 110 Nyamweya S, Hegedus A, Jaye A, Rowland-Jones S, Flanagan KL, Macallan DC. Comparing HIV-1 and HIV-2 infection: Lessons for viral immunopathogenesis. *Rev Med Virol.* 2013;23:221-240.
- 111 Menéndez-Arias L, Alvarez M. Antiretroviral therapy and drug resistance in human immunodeficiency virus type 2 infection. *Antiviral Res.* 2014;102:70-86.
- 112 Campbell-Yesufu OT, Gandhi RT. Update on human immunodeficiency virus (HIV)-2 infection. *Clin Infect Dis.* 2011;52(6):780-787.
- 113 Duvall MG, Jaye A, Dong T, et al. Maintenance of HIV-specific CD4+ T cell help distinguishes HIV-2 from HIV-1 infection. *J Immunol.* 2006;176:6973-6981.
- 114 Gao F, Yue L, Robertson DL, Hill SC, Hui H, Biggar RJ, Neequaye AE, et al. Genetic diversity of human immunodeficiency virus type 2: evidence for distinct sequence subtypes with differences in virus biology. *J Virol.* 1994;68:7433-7447.
- 115 Markovitz DM. Infection with the human immunodeficiency virus type 2. *Ann Intern Med.* 1993;118:211-218.
- 116 Gurtler LG, Zekeng L, Tsague JM, et al. HIV-1 subtype O: epidemiology, pathogenesis, diagnosis, and perspectives of the evolution of HIV. *Arch Virol Suppl.* 1996;11:195-202.
- 117 Casoli C, Pilotti E, Bertazzoni U. Molecular and cellular interactions of HIV-1/HTLV coinfection and impact on AIDS progression. *AIDS Rev.* 2007;9:140-149.
- 118 Ferreira OC Jr, Planelles V, Rosenblatt JD. Human T-cell leukemia viruses: epidemiology, biology, and pathogenesis. *Blood Rev.* 1997;11:91-104.
- 119 Andersson S, Thorstensson R, Ramirez KG, Krook A, von Sydow M, Dias F, Biberfeld G. Comparative evaluation of 14 immunoassays for detection of antibodies to the human T-lymphotropic virus types I and II using panels of sera from Sweden and West Africa. *Transfusion.* 1999;39:845-851.
- 120 Cooper SA, van der Loeff MS, Taylor GP. The neurology of HTLV-1 infection. *Pract Neurol.* 2009;9:16-26.
- 121 Vandamme AM, Bertazzoni U, Salemi M. Evolutionary strategies of human T-cell lymphotropic virus type II. *Gene.* 2000;261:171-180.
- 122 Araujo A, Hall WW. Human T-lymphotropic virus type II and neurological disease. *Ann Neurol.* 2004;56(1):10-19.

- 
- 123 Mahieux R, Gessain A. The human HTLV-3 and HTLV-4 retroviruses: new members of the HTLV family. *Pathol Biol (Paris)*. 2009;57:161-166.
- 124 Smith HM. AIDS. Lessons from history. *MD*. 1986;9:43-51.
- 125 Hariri S, McKenna MT. Epidemiology of human immunodeficiency virus in the United States. *Clin Microbiol Rev*. 2007;20:478-488.
- 126 Shepard RN, Schock J, Robertson K, et al. Quantitation of human immunodeficiency virus type 1 RNA in different biological compartments. *J Clin Microbiol*. 2000;38:1414-1418.
- 127 Yeung SC, Kazazi F, Randle CG, Howard RC, Rizvi N, Downie JC, Donovan BJ, et al. Patients infected with human immunodeficiency virus type 1 have low levels of virus in saliva even in the presence of periodontal disease. *J Infect Dis*. 1993;167:803-809.
- 128 Hanege FM, Kalcioğlu MT, Sargin F, Cetinkaya Z, Tekin M, Vahaboglu H. Does cerumen have a risk for transmission of HIV? *Eur J Clin Microbiol Infect Dis*. 2015;34:789-793.
- 129 Morison L. The global epidemiology of HIV/AIDS. *Br Med Bull*. 2001;58:7-18.
- 130 Hader SL, Smith DK, Moore JS, Holmberg SD. HIV infection in women in the United States: status at the Millennium. *JAMA*. 2001;285:1186-1192.
- 131 Rich JD, Buck A, Tuomala RE, Kazanjian PH. Transmission of human immunodeficiency virus infection presumed to have occurred via female homosexual contact. *Clin Infect Dis*. 1993;17:1003-1005.
- 132 Bevier PJ, Chiasson MA, Heffernan RT, Castro KG. Women at a sexually transmitted disease clinic who reported same-sex contact: their HIV seroprevalence and risk behaviors. *Am J Public Health*. 1995;85:1366-1371.
- 133 Valleroy LA, MacKellar DA, Karon JM, et al. HIV prevalence and associated risks in young men who have sex with men. *JAMA*. 2000;284:198-204.
- 134 Lansky A, Brooks JT, DiNenno E, Heffelfinger J, Hall HI, Mermin J. Epidemiology of HIV in the United States. *J Acquir Immune Defic Syndr*. 2010;55 Suppl 2:S64-68.

- 
- 135 Centers for Disease Control. Notice to readers: the 20<sup>th</sup> year of AIDS: a time to re-energize prevention. *MMWR*. 2001;50:444-445.
- 136 Lamptey PR. Reducing heterosexual transmission of HIV in poor countries. *BMJ*. 2002;324:207-211.
- 137 White PJ, Fox J, Weber J, Fidler S, Ward H. How Many HIV infections may be averted by targeting primary infection in men who have sex with men? Quantification of changes in transmission-risk behavior, using an individual-based model. *J Infect Dis*. 2014;210 Suppl 2:S594-599.
- 138 Coates TJ, Richter L, Caceres C. Behavioural strategies to reduce HIV transmission: how to make them work better. *Lancet*. 2008;372:669-684.
- 139 Guttmacher S, Lieberman L, Ward D, Freudenberg N, Radosh A, DesJarlais D. Condom availability in New York City public high schools: relationships to condom use and sexual behavior. *Am J Public Health*. 1997;87:1427-1433.
- 140 Okie S. Sex, drugs, prisons, and HIV. *N Engl J Med*. 2007;356:105-108.
- 141 Powers KA, Poole C, Pettifor A, Cohen CS. Rethinking the heterosexual infectivity of HIV-1: a systematic review and meta-analysis. *Lancet*. 2008;8:553-563.
- 142 Hladik F, McElrath MJ. Setting the stage: host invasion by HIV. *Nat Rev Immunol*. 2008;8:447-457.
- 143 Landovitz RJ, Currier JS. Postexposure prophylaxis for HIV infection. *N Engl J Med*. 2009;361:1768-1775.

- 
- 144 Gupta P, Mellors J, Kingsley L, et al. High viral load in semen of human immunodeficiency virus type 1-infected men at all stages of disease and its reduction by therapy with protease and nonnucleoside reverse transcriptase inhibitors. *J Virol*. 1997;71:6271-6275.
- 145 Iversen AK, Larsen AR, Jensen T, et al. Distinct determinants of human immunodeficiency virus type 1 RNA and DNA loads in vaginal and cervical secretions. *J Infect Dis*. 1998;177:1214-1220.
- 146 Vernazza PL, Eron JJ, Fiscus SA, Cohen MS. Sexual transmission of HIV: infectiousness and prevention. *AIDS*. 1999;13:155-166.
- 147 Krieger JN, Nirapathpongporn A, Chalyaporn M, et al. Vasectomy and human immunodeficiency virus type 1 in semen. *J Urol*. 1998;159:820-826.
- 148 Deleage C, Moreau M, Rioux-Leclercq N, Ruffault A, Jégou B, Dejucq-Rainsford N. Human immunodeficiency virus infects human seminal vesicles in vitro and in vivo. *Am J Pathol*. 2011;179(5):2397-2408.
- 149 Royce RA, Sena A, Cates W, Cohen MS. Sexual transmission of HIV. *N Engl J Med*. 1997;336:1072-1078.
- 150 Wawer MJ, Gray RH, Sewankambo NK, et al. Rates of HIV-1 transmission per coital act, by stage of HIV-1 infection, in Rakai, Uganda. *J Infect Dis*. 2005;191:1403-1409.
- 151 Gilliam BL, Dyer JR, Fiscus SA, et al. Effects of reverse transcriptase inhibitor therapy on the HIV-1 viral burden in semen. *J Acquir Immune Defic Syndr Hum Retrovirol*. 1997;15:54-60.
- 152 Cu-Uvin S, Callendo AM, Reinert S, et al. Effect of highly active antiretroviral therapy on cervicovaginal HIV-1 RNA. *AIDS*. 2000;14:415-421.
- 153 Dornadula G, Zhang H, VanUitert B, et al. Residual HIV-1 RNA in blood plasma of patients taking suppressive highly active antiretroviral therapy. *JAMA*. 1999;282:1627-1632.
- 154 Quinn TC, Wawer MJ, Sewankambo N, et al. Viral load and heterosexual transmission of human immunodeficiency virus type 1. *N Engl J Med*. 2000;342:921-929.
- 155 Modjarrad K, Chamot E, Vermund SH. Impact of small reductions in plasma HIV RNA levels on the risk of heterosexual transmission and disease progression. *AIDS*. 2008;22:2179-2185.

- 
- 156 Redd AD, Collinson-Streng AN, Chatziandreou N, Mullis CE, Laeyendecker O, Martens C, Ricklefs S, et al. Previously transmitted HIV-1 strains are preferentially selected during subsequent sexual transmissions. *J Infect Dis*. 2012;206:1433-1442.
- 157 Mostad SB, Overbaugh J, DeVange DM, et al. Hormonal contraception, vitamin A deficiency, and other risk factors for shedding of HIV-1 infected cells from the cervix and vagina. *Lancet*. 1997;350(9082):922-927.
- 158 McCoombe SG, Short RV. Potential HIV-1 target cells in the human penis. *AIDS*. 2006;20:1491-1495.
- 159 Doyle SM, Kahn JG, Hosang N, Carroll PR. The impact of male circumcision on HIV transmission. *J Urol*. 2010;183:21-26.
- 160 Tobian AA, Kacker S, Quinn TC. Male Circumcision: A Globally Relevant but Under-Utilized Method for the Prevention of HIV and Other Sexually Transmitted Infections. *Annu Rev Med*. 2014;65:293-306.
- 161 Cohen MS. Sexually transmitted diseases enhance HIV transmission: no longer a hypothesis. *Lancet*. 1998;351(suppl III):5-7.
- 162 Tobian AA, Quinn TC. Herpes simplex virus type 2 and syphilis infections with HIV: an evolving synergy in transmission and prevention. *Curr Opin HIV AIDS*. 2009;4:294-299.
- 163 de Jong MA, de Witte L, Taylor ME, Geijtenbeek TB. Herpes simplex virus type 2 enhances HIV-1 susceptibility by affecting Langerhans cell function. *J Immunol*. 2010;185:1633-1641.
- 164 Mohammed TT, Olumide YM. Chancroid and human immunodeficiency virus infection--a review. *Int J Dermatol*. 2008;47:1-8.
- 165 Celum C, Wald A, Lingappa JR, Magaret AS, Wang RS, Mugo N, Mujugira A, et al. Acyclovir and transmission of HIV-1 from persons infected with HIV-1 and HSV-2. *N Engl J Med*. 2010;362:427-439.
- 166 Myer L, Kuhn L, Stein ZA, Wright TC Jr, Denny L. Intravaginal practices, bacterial vaginosis, and women's susceptibility to HIV infection: epidemiological evidence and biological mechanisms. *Lancet Infect Dis*. 2005;5:786-794.
- 167 Cohen CR, Lingappa JR, Baeten JM, Ngayo MO, Spiegel CA, Hong T, Donnell D, et al. Bacterial vaginosis associated with increased risk of female-to-male HIV-1 transmission: a prospective cohort analysis among African couples. *PLoS Med*. 2012;9(6):e1001251.

- 
- 168 DeBeck K, Kerr T, Li K, Fischer B, Buxton J, Montaner J, Wood E. Smoking of crack cocaine as a risk factor for HIV infection among people who use injection drugs. *CMAJ*. 2009;181:585-589.
- 169 Liang H, Wang X, Chen H, Song L, Ye L, Wang SH, Wang YJ, Zhou L, Ho WZ. Methamphetamine enhances HIV infection of macrophages. *Am J Pathol*. 2008;172:1617-1624.
- 170 Pilcher CD, Joaki G, Hoffman IF, Martinson FE, Mapanje C, Stewart PW, Powers KA, et al. Amplified transmission of HIV-1: comparison of HIV-1 concentrations in semen and blood during acute and chronic infection. *AIDS*. 2007;21(13):1723-1730.
- 171 Finer LB, Darroch JE, Singh S. Sexual partnership patterns as a behavioral risk factor for sexually transmitted diseases. *Fam Plann Perspect*. 1999;31:228-236.
- 172 Winkelstein W Jr, Lyman DM, Padian N, et al. Sexual practices and risk of infection by the human immunodeficiency virus. *JAMA*. 1987;257:321-325.
- 173 Byers RH Jr, Morgan WM, Darrow WW, et al. Estimating AIDS infection rates in the San Francisco cohort. *AIDS*. 1988;2:207-210.
- 174 Baggaley RF, Boily MC, White RG, Alary M. Risk of HIV-1 transmission for parenteral exposure and blood transfusion: a systematic review and meta-analysis. *AIDS*. 2006;20:805-812.
- 175 Centers for Disease Control. Updated U.S. Public Health Service guidelines for the management of occupational exposures to HIV and recommendations for postexposure prophylaxis. *MMWR*. 2005;54(RR09):1-17.
- 176 Beltrami EM, Williams IT, Shapiro CN, Chamberland ME. Risk and management of blood-borne infections in health care workers. *Clin Microbiol Rev*. 2000;13:385-407.
- 177 Goodnough LT. Risks of blood transfusion. *Crit Care Med*. 2003;31(12 Suppl):S678-S686.
- 178 O'Brien SF, Yi QL, Fan W, Scalia V, Fearon MA, Allain JP. Current incidence and residual risk of HIV, HBV and HCV at Canadian Blood Services. *Vox Sang*. 2012;103:83-86.
- 179 Lackritz EM. Prevention of HIV transmission by blood transfusion in the developing world: achievements and continuing challenges. *AIDS*. 1998;12(Suppl A):S81-S86.
- 180 Centers for Disease Control. Human immunodeficiency virus transmission in household settings--United States. *MMWR*. 1994;43:347,353-356.

- 
- 181 Cowgill BO, Bogart LM, Corona R, Ryan G, Schuster MA. Fears about HIV transmission in families with an HIV-infected parent: a qualitative analysis. *Pediatrics*. 2008;122(5):e950-8.
- 182 Baron S, Poast J, Richardson CJ, Nguyen D, Cloyd M. Oral transmission of human immunodeficiency virus by infected seminal fluid and milk: a novel mechanism. *J Infect Dis*. 2000;181:498-504.
- 183 Campo J, Perea MA, del Romero J, Cano J, Hernando V, Bascones A. Oral transmission of HIV, reality or fiction? An update. *Oral Dis*. 2006;12:219-228.
- 184 Kreiss J. Breastfeeding and vertical transmission of HIV-1. *Acta Paediatr Suppl*. 1997;421:113-117.
- 185 Resnick L, Veren K, Salahuddin SZ, Tondreau S, Markham PD. Stability and inactivation of HTLV-III/LAV under clinical and laboratory environments. *JAMA*. 1986;255:1887-1891.
- 186 Friedland GH, Kahl P, Saltzman B, et al. Additional evidence for lack of transmission of HIV infection by close interpersonal (casual) contact. *AIDS*. 1990;4:639-644.
- 187 Branson BM, Handsfield HH, Lampe MA, Janssen RS, Taylor AW, Lyss SB, Clark JE; Centers for Disease Control and Prevention. Revised recommendations for HIV testing of adults, adolescents, and pregnant women in health-care settings. *MMWR Recomm Rep*. 2006;55(RR-14):1-17.
- 188 Cavarelli M, Scarlatti G. Human immunodeficiency virus type 1 mother-to-child transmission and prevention: successes and controversies. *J Intern Med*. 2011;270(6):561-579.
- 189 Richardson BA, John-Stewart GC, Hughes JP, Nduati R, Mbori-Ngacha D, Overbaugh J, Kreiss JK. Breast-milk infectivity in human immunodeficiency virus type 1-infected mothers. *J Infect Dis*. 2003;187:736-740.
- 190 John-Stewart G, Mbori-Ngacha D, Ekpini R, et al. Breast-feeding and transmission of HIV-1. *J Acquir Immune Defic Syndr*. 2004;35:196-202.
- 191 John GC, Nduati RW, Mbori-Ngacha DA, et al. Correlates of mother-to-child human immunodeficiency virus type 1 (HIV-1) transmission: association with maternal plasma HIV-1 RNA load, genital HIV-1 DNA shedding, and breast infections. *J Infect Dis*. 2001;183:206-212.



- 
- 192 Nduati R, John G, Mbori-Ngacha D, et al. Effect of breastfeeding and formula feeding on transmission of HIV-1. *JAMA*. 2000;283:1167-1174.
- 193 Toniolo A, Serra C, Conaldi PG, Basolo F, Falcone V, Dolei A. Productive HIV-1 infection of normal human mammary epithelial cells. *AIDS*. 1995;9:859-866.
- 194 Ahmad N. Molecular mechanisms of HIV-1 vertical transmission and pathogenesis in infants. *Adv Pharmacol*. 2008;56:453-508.
- 195 Fowler MG, Gable AR, Lampe MA, Etima M, Owor M. Perinatal HIV and its prevention: progress toward an HIV-free generation. *Clin Perinatol*. 2010;37:699-719.
- 196 Thorne C, Newell ML. HIV. *Semin Fetal Neonatal Med*. 2007;12:174-181.
- 197 Kuhn L, Sinkala M, Semrau K, Kankasa C, Kasonde P, Mwiya M, Hu C, et al. Elevations in mortality associated with weaning persist into the second year of life among uninfected children born to HIV-infected mothers. *Clin Infect Dis*. 2010;50:437-444.
- 198 Lehman DA, Farquhar C. Biological mechanisms of vertical human immunodeficiency virus (HIV-1) transmission. *Rev Med Virol*. 2007;17:381-403.
- 199 Mofenson LM, Lambert JS, Stiehler ER, et al. Risk factors for perinatal transmission of human immunodeficiency virus type 1 in women treated with zidovudine. *N Engl J Med*. 1999;341:385-393.
- 200 Garcia PM, Kalish LA, Pitt J, et al. Maternal levels of plasma human immunodeficiency virus type 1 RNA and the risk of perinatal transmission. *N Engl J Med*. 1999;341:394-402.
- 201 Adjorlolo-Johnson G, DeCock KM, Ekpini E, Vetter KM, Sibailly T, Brattegaard K, Yavo D, et al. Prospective comparison of mother-to-child transmission of HIV-1 and HIV-2 in Abidjan, Ivory Coast. *JAMA*. 1994;272:462-466.
- 202 Piot P, Plummer FA, Mhalu FS, Lamboray JL, Chin J, Mann JM. AIDS: An international perspective. *Science*. 1988;239:573-579.
- 203 Hall HI, Song R, Rhodes P, Prejean J, An Q, Lee LM, Karon J, et al. Estimation of HIV incidence in the United States. *JAMA*. 2008;300:520-529.
- 204 Centers for Disease Control and Prevention. Heterosexual transmission of HIV --- 29 states, 1999--2002. *MMWR*. 2004;53:125-129.
- 205 Vergis EN, Mellors JW. Natural history of HIV-1 infection. *Infect Dis Clin North Am*. 2000;14:809-825.

- 
- 206 Hogan CM, Hammer SM. Host determinants in HIV infection and disease. Part 1: cellular and humoral immune responses. *Ann Intern Med.* 2001;134(9 Pt 1):761-76.
- 207 Quinn TC. Acute primary HIV infection. *JAMA.* 1997;278:58-62.
- 208 Kahn JO, Walker BD. Acute human immunodeficiency virus type I infection. *N Engl J Med.* 1998;339:33-39.
- 209 Rouet F, Elenga N, Msellati P, Montcho C, Viho I, Sakarovitch C, Danel C, Rouzioux C, Leroy V, Dabis F. Primary HIV-1 infection in African children infected through breastfeeding. *AIDS.* 2002;16:2303-2309.
- 210 Coutlee F, Olivier C, Cassol S, et al. Absence of prolonged immunosilent infection with human immunodeficiency virus in individuals with high-risk behaviors. *Am J Med.* 1994;96:42-48.
- 211 Tyrer F, Walker AS, Gillett J, Porter K; UK Register of HIV Seroconverters. The relationship between HIV seroconversion illness, HIV test interval and time to AIDS in a seroconverter cohort. *Epidemiol Infect.* 2003;131:1117-1123.
- 212 Cohen MS, Gay CL, Busch MP, Hecht FM. The detection of acute HIV infection. *Infect Dis.* 2010;202 Suppl 2:S270-277.
- 213 Tenner-Racz K, Stellbrink HJ, vanLunzen J, et al. The unenlarged lymph nodes of HIV-1-infected, asymptomatic patients with high CD4 T cell counts are sites for virus replication and CD4 T cell proliferation. The impact of highly active antiretroviral therapy. *J Exp Med.* 1998;187:949-959.
- 214 Cornelissen M, Jurriaans S, Prins JM, Bakker M, van der Kuyl AC. Absence of seroreversion in 80 HAART-treated HIV-1 seropositive patients with at least five-years undetectable plasma HIV-1 viral load. *AIDS Res Ther.* 2006;Feb 16;3:3.
- 215 Sterling TR, Vlahov D, Astemborski J, Hoover DR, Margolick JB, Quinn TC. Initial plasma HIV-1 RNA levels and progression to AIDS in women and men. *N Engl J Med.* 2001;344:720-725.
- 216 Rosenberg ES, Billingsley JM, Caliendo AM, et al. Vigorous HIV-1-specific CD4+ T cell responses associated with control of viremia. *Science.* 1997;278:1447-1450.
- 217 Noursadeghi M, Katz DR, Miller RF. HIV-1 infection of mononuclear phagocytic cells: the case for bacterial innate immune deficiency in AIDS. *Lancet Infect Dis.* 2006;6:794-804.

- 
- 218 Lester RT, Yao XD, Ball TB, McKinnon LR, Kaul R, Wachihi C, Jaoko W, et al. Toll-like receptor expression and responsiveness are increased in viraemic HIV-1 infection. *AIDS*. 2008;22:685-694.
- 219 Ribeiro RM. Dynamics of CD4+ T cells in HIV-1 infection. *Immunol Cell Biol*. 2007;85:287-294.
- 220 Waters L, Smit E. HIV-1 superinfection. *Curr Opin Infect Dis*. 2012;25(1):42-50.
- 221 Redd AD, Quinn TC, Tobian AA. Frequency and implications of HIV superinfection. *Lancet Infect Dis*. 2013;13:622-628.
- 222 Chou R, Selph S, Dana T, Bougatsos C, Zakher B, Blazina I, Korthuis PT. Screening for HIV: systematic review to update the 2005 U.S. Preventive Services Task Force recommendation. *Ann Intern Med*. 2012;157:706-718.
- 223 Kaplan JE, Benson C, Holmes KH, Brooks JT, Pau A, Masur H; Centers for Disease Control and Prevention. Guidelines for prevention and treatment of opportunistic infections in HIV-infected adults and adolescents: recommendations from CDC, the National Institutes of Health, and the HIV Medicine Association of the Infectious Diseases Society of America. *MMWR Recomm Rep*. 2009;58(RR-4):1-207.
- 224 Chitra P, Bakthavatsalam B, Palvannan T. Beta-2 microglobulin as an immunological marker to assess the progression of human immunodeficiency virus infected patients on highly active antiretroviral therapy. *Clin Chim Acta*. 2011;412:1151-1154.
- 225 Tsoukas CM, Bernard NF. Markers predicting progression of human immunodeficiency virus-related disease. *Clin Microbiol Rev*. 1994;7:14-28.
- 226 Centers for Disease Control. Report of the NIH Panel to define principles of therapy of HIV infection and guidelines for the use of antiretroviral agents in HIV-infected adults and adolescents. *MMWR*. 1998;47(RR-5):1-83.
- 227 Roberts L, Passmore JA, Mlisana K, Williamson C, Little F, Bebell LM, Walzl G, et al. Genital tract inflammation during early HIV-1 infection predicts higher plasma viral load set point in women. *J Infect Dis*. 2012;205(2):194-203.
- 228 Chaisson RE, Gallant JE, Keruly JC, Moore RD. Impact of opportunistic disease on survival in patients with HIV infection. *AIDS*. 1998;12:29-33.
- 229 Sabin CA, Lundgren JD. The natural history of HIV infection. *Curr Opin HIV AIDS*. 2013;8:311-317.

- 
- 230 Singh KK, Spector SA. Host genetic determinants of human immunodeficiency virus infection and disease progression in children. *Pediatr Res*. 2009;65(5 Pt 2):55R-63R.
- 231 Kouri, V, Khouri R, Alemán Y, Abrahantes Y, Vercauteren J, Pineda-Peña A-C, Theys K, et al. CRF19\_cpx is an Evolutionary fit HIV-1 Variant Strongly Associated With Rapid Progression to AIDS in Cuba. *EbioMedicine*. 2015;2(3):244-254.
- 232 Chaisson RE, Keruly JC, Moore RD. Race, sex, drug use, and progression of human immunodeficiency virus disease. *N Engl J Med*. 1995;333:751-756.
- 233 Galai N, Park LP, Wesch J, Visscher B, Riddler S, Margolick JB. Effect of smoking on the clinical progression of HIV-1 infection. *J Acquir Immune Defic Syndr*. 1997;15:451-458.
- 234 Bessinger R, Clark R, Kissinger P, Rice J, Coughlin S. Pregnancy is not associated with the progression of HIV disease in women attending an HIV outpatient program. *Am J Epidemiol*. 1998;147:434-440.
- 235 Addo MM, Altfeld M. Sex-based differences in HIV type 1 pathogenesis. *J Infect Dis*. 2014;209(Suppl 3):S86-92.
- 236 Pratt G, Gascoyne K, Cunningham K, Tunbridge A. Human immunodeficiency virus (HIV) in older people. *Age Ageing*. 2010;39:289-294.
- 237 Xiang J, Wunschmann S, Diekema DJ, Klinzman D, Patrick KD, George SL, Stapleton JT. Effect of coinfection with GB virus C on survival among patients with HIV infection. *N Engl J Med*. 2001;345:707-714.
- 238 Stone CA, Kawai K, Kupka R, Fawzi WW. Role of selenium in HIV infection. *Nutr Rev*. 2010;68:671-681.
- 239 Pantaleo G, Menzo S, Vaccarezza M, Graziosi C, Cohen OJ, Demarest JF, et al. Studies in subjects with long-term nonprogressive human immunodeficiency virus infection. *N Engl J Med*. 1995;332:209-216.
- 240 O'Connell KA, Bailey JR, Blankson JN. Elucidating the elite: mechanisms of control in HIV-1 infection. *Trends Pharmacol Sci*. 2009;30:631-637.
- 241 Okulicz JF, Lambotte O. Epidemiology and clinical characteristics of elite controllers. *Curr Opin HIV AIDS*. 2011;6(3):163-8.

- 
- 242 Ioannidis JPA, Rosenberg PS, Goedert JJ, et al. Effects of CCR5-delta32, CCR2-64I, and SDF-1-3'A alleles on HIV-1 disease progression: an international meta-analysis of individual patient data. *Ann Intern Med*. 2001;135:782-795.
- 243 Reynes J, Portales P, Segondy M, et al. CD4 T cell surface CCR5 density as a host factor in HIV-1 disease progression. *AIDS*. 2001;15:1627-1634.
- 244 Faure S, Meyer L, Genin E, Pellet P, Debre P, Theodorou I, Combadiere C. Deleterious genetic influence of CX3CR1 genotypes on HIV-1 disease progression. *J Acquir Immune Defic Syndr*. 2003;32:335-337.
- 245 Balog K, Minarovits J. Nef: a pleiotropic modulator of primate lentivirus infectivity and pathogenesis. *Acta Microbiol Immunol Hung*. 2006;53:51-75.
- 246 Habeshaw JA, Wilson SE, Hounsell EF, Oxford JS. How HIV-1 lentivirus causes immune deficiency disease. *Med Hypotheses*. 1999;52:59-67.
- 247 Hendel H, Caillat-Zucman S, Lebuanec H, et al. New class I and II HLA alleles strongly associated with opposite patterns of progression to AIDS. *J Immunol*. 1999;162:6942-6946.
- 248 Horton H, Frank I, Baydo R, Jalbert E, Penn J, Wilson S, McNevin JP, et al. Preservation of T cell proliferation restricted by protective HLA alleles is critical for immune control of HIV-1 infection. *J Immunol*. 2006;177:7406-7415.
- 249 Alter G, Altfeld M. NK cells in HIV-1 infection: evidence for their role in the control of HIV-1 infection. *J Intern Med*. 2009;265:29-42.
- 250 Tovo PA, de Martino M, Gabiano C, Cappello N, D'Elia R, Loy A, Plebani A, et al. Prognostic factors and survival in children with perinatal HIV-1 infection. *Lancet*. 1992;339:1249-1253.
- 251 Dollfus C, Le Chenadec J, Faye A, Blanche S, Briand N, Rouzioux C, Warszawski J. Long-term outcomes in adolescents perinatally infected with HIV-1 and followed up since birth in the French perinatal cohort (EPF/ANRS CO10). *Clin Infect Dis*. 2010;51:214-224.
- 252 Shearer WT, Quinn TC, LaRussa P, et al. Viral load and disease progression in infants infected with human immunodeficiency virus type 1. *N Engl J Med*. 1997;336:1337-1342.
- 253 DeRossi A, Ometto L, Masiero S, Zanchetta M, Chieco-Bianchi L. Viral phenotype in mother-to-child HIV-1 transmission and disease progression of vertically acquired HIV-1 infection. *Acta Paediatr Suppl*. 1997;421:22-28.

- 
- 254 Raszka WV, Moriarty RA, Ottolini MG, et al. Delayed-type hypersensitivity skin testing in human immunodeficiency virus-infected pediatric patients. *J Pediatr*. 1996;129:245-250.
- 255 Luo L, Li T. Idiopathic CD4 lymphocytopenia and opportunistic infection--an update *FEMS Immunol Med Microbiol*. 2008;54:283-289.
- 256 Walker UA, Warnatz K. Idiopathic CD4 lymphocytopenia. *Curr Opin Rheumatol*. 2006;18:389-395.
- 257 Hua VJ, Bressler RB, Miranda CH, Huston DP. Behcet's-like syndrome associated with idiopathic CD4+ T-lymphocytopenia, opportunistic infections, and a large population of TCR alpha beta+ CD4- CD8- T cells. *Am J Med Sci*. 1997;313:236-238.
- 258 Zonios DI, Falloon J, Bennett JE, Shaw PA, Chaït D, Baseler MW, Adelsberger JW, et al. Idiopathic CD4+ lymphocytopenia: natural history and prognostic factors. *Blood*. 2008;112:287-294.
- 259 Scott-Algara D, Balabanian K, Chakrabarti LA, Mouthon L, Dromer F, Didier C, Arenzana-Seisdedos F, Lortholary O. Idiopathic CD4+ T-cell lymphocytopenia is associated with impaired membrane expression of the chemokine receptor CXCR4. *Blood*. 2009;115:3708-3717.
- 260 Berg CJ, Michelson SE, Safren SA. Behavioral aspects of HIV care: adherence, depression, substance use, and HIV-transmission behaviors. *Infect Dis Clin North Am*. 2007;21:181-200.
- 261 DiClemente RJ, Crittenden CP, Rose E, Sales JM, Wingood GM, Crosby RA, Salazar LF. Psychosocial predictors of HIV-associated sexual behaviors and the efficacy of prevention interventions in adolescents at-risk for HIV infection: what works and what doesn't work? *Psychosom Med*. 2008;70:598-605.
- 262 Johnson BT, Scott-Sheldon LA, Huedo-Medina TB, Carey MP. Interventions to reduce sexual risk for human immunodeficiency virus in adolescents: a meta-analysis of trials, 1985-2008. *Arch Pediatr Adolesc Med*. 2011;165:77-84.
- 263 Champenois K, Cousien A, Cuzin L, Le Vu S, Deuffic-Burban S, Lanoy E, Lacombe K, et al. Missed opportunities for HIV testing in newly-HIV-diagnosed patients, a cross sectional study. *BMC Infect Dis*. 2013 May 2;13:200. doi: 10.1186/1471-2334-13-200.
- 264 Klein PW, Martin IB, Quinlivan EB, Gay CL, Leone PA. Missed Opportunities for Concurrent HIV-STD Testing in an Academic Emergency Department. *Public Health Rep*. 2014;129 Suppl 1:12-20.

- 
- 265 Jukes M, Simmons S, Bundy D. Education and vulnerability: the role of schools in protecting young women and girls from HIV in southern Africa. *AIDS*. 2008;22 Suppl 4:S41-56.
- 266 Krishnan S, Dunbar MS, Minnis AM, Medlin CA, Gerdt CE, Padian NS. Poverty, gender inequities, and women's risk of human immunodeficiency virus/AIDS. *Ann N Y Acad Sci*. 2008;1136:101-110.
- 267 Kidder DP, Wolitski RJ, Pals SL, Campsmith ML. Housing status and HIV risk behaviors among homeless and housed persons with HIV. *J Acquir Immune Defic Syndr*. 2008;49:451-455.
- 268 Abdala N, Crowe M, Tolstov Y, Heimer R. Survival of human immunodeficiency virus type 1 after rinsing injection syringes with different cleaning solutions. *Subst Use Misuse*. 2004;39:581-600.
- 269 Monterroso ER, Hamburger ME, Vlahov D, et al. Prevention of HIV infection in street-recruited injection drug users: the Collaborative Injection Drug User Study (CIDUS). *J Acquir Immune Defic Syndr*. 2000;25:63-70.
- 270 Khalsa AM. Preventive counseling, screening, and therapy for the patient with newly diagnosed HIV infection. *Am Fam Physician*. 2006;73:271-280.
- 271 Holtgrave D. Evidence-based efforts to prevent HIV infection: an overview of current status and future challenges. *Clin Infect Dis*. 2007;45 Suppl 4:S293-299.
- 272 Baeten JM, Donnell D, Ndase P, Mugo NR, Campbell JD, Wangisi J, Tappero JW, et al. Antiretroviral prophylaxis for HIV prevention in heterosexual men and women. *N Engl J Med*. 2012;367:399-410.
- 273 Chang LW, Serwadda D, Quinn TC, Wawer MJ, Gray RH, Reynolds SJ. Combination implementation for HIV prevention: moving from clinical trial evidence to population-level effects. *Lancet Infect Dis*. 2013;13:65-76.
- 274 Hoffmann CJ, Gallant JE. Rationale and Evidence for Human Immunodeficiency Virus Treatment as Prevention at the Individual and Population Levels. *Infect Dis Clin North Am*. 2014;28:549-561.
- 275 Yarchoan R, Mitsuya H, Broder S. AIDS therapies. *Sci Am*. 1988;259:110-119.
- 276 Warnke D, Barreto J, Temesgen Z. Antiretroviral drugs. *J Clin Pharmacol*. 2007;47:1570-1579.
- 277 Hirsch MS, D'Aquila RT. Therapy for human immunodeficiency virus infection. *N Engl J Med*. 1993;328:1686-1695.

- 
- 278 Thompson MA, Aberg JA, Cahn P, Montaner JS, Rizzardini G, Telenti A, Gatell JM, Günthard HF, et al; International AIDS Society-USA. Antiretroviral treatment of adult HIV infection: 2010 recommendations of the International AIDS Society-USA panel. *JAMA*. 2010;304:321-333..
- 279 Jao J, Wyatt CM. Antiretroviral medications: adverse effects on the kidney. *Adv Chronic Kidney Dis*. 2010;17:72-82.
- 280 Vivet-Boudou V, Didierjean J, Isel C, Marquet R. Nucleoside and nucleotide inhibitors of HIV-1 replication. *Cell Mol Life Sci*. 2006;63:163-186.
- 281 Arenas-Pinto A, Grant AD, Edwards S, Weller IV. Lactic acidosis in HIV infected patients: a systematic review of published cases. *Sex Transm Infect*. 2003;79:340-343.
- 282 Neuman MG, Schneider M, Nanau RM, Parry C. HIV-Antiretroviral therapy induced liver, gastrointestinal, and pancreatic injury. *Int J Hepatol*. 2012;2012:760706. doi: 10.1155/2012/760706.
- 283 Hoetelmans RM. Pharmacology of antiretroviral drugs. *Antiviral Ther*. 1999;4 Suppl 3:29-41.
- 284 Rotunda A, Hirsch RJ, Scheinfeld N, Weinberg JM. Severe cutaneous reactions associated with the use of human immunodeficiency virus medications. *Acta Derm Venereol*. 2003;83:1-9.
- 285 Adams J, Patel N, Mankaryous N, Tadros M, Miller CD. Nonnucleoside reverse transcriptase inhibitor resistance and the role of the second-generation agents. *Ann Pharmacother*. 2010;44:157-165.
- 286 Wensing AM, van Maarseveen NM, Nijhuis M. Fifteen years of HIV Protease Inhibitors: raising the barrier to resistance. *Antiviral Res*. 2010;85:59-74.
- 287 Mehandru S, Markowitz M. Tipranavir: a novel non-peptidic protease inhibitor for the treatment of HIV infection. *Expert Opin Investig Drugs*. 2003;12:1821-1828.
- 288 Flexner C. HIV-protease inhibitors. *N Engl J Med*. 1998;338:1281-1292.



- 
- 289 Yanovski JA, Miller KD, Kino T, Friedman TC, Chrousos GP, Tsigos C, Falloon J. Endocrine and metabolic evaluation of human immunodeficiency virus-infected patients with evidence of protease inhibitor-associated lipodystrophy. *J Clin Endocrinol Metab.* 1999;84:1925-1931.
- 290 Noor MA, Parker RA, O'Mara E, et al. The effects of HIV protease inhibitors atazanavir and lopinavir/ritonavir on insulin sensitivity in HIV-seronegative healthy adults. *AIDS.* 2004;18:2137-244.
- 291 Pettersen JA, Jones G, Worthington C, et al. Sensory neuropathy in human immunodeficiency virus/acquired immunodeficiency syndrome patients: protease inhibitor-mediated neurotoxicity. *Ann Neurol.* 2006;59:816-824.
- 292 Piscitelli SC, Gallicano KD. Interactions among drugs for HIV and opportunistic infections. *N Engl J Med.* 2001;344:984-996.
- 293 Haqqani AA, Tilton JC. Entry inhibitors and their use in the treatment of HIV-1 infection. *Antiviral Res.* 2013;98:158-170.
- 294 Lalezari JP, Henry K, O'Hearn M, et al. Enfuvirtide, an HIV-1 fusion inhibitor, for drug-resistant HIV infection in North and South America. *N Engl J Med.* 2003;348:2175-2185.
- 295 Schafer JJ, Squires KE. Integrase inhibitors: a novel class of antiretroviral agents. *Ann Pharmacother.* 2010;44:145-156.
- 296 Shah BM, Schafer JJ, Desimone JA Jr. Dolutegravir: a new integrase strand transfer inhibitor for the treatment of HIV. *Pharmacotherapy.* 2014;34:506-520.
- 297 Martin DE, Salzwedel K, Allaway GP. Bevirimat: a novel maturation inhibitor for the treatment of HIV-1 infection. *Antivir Chem Chemother.* 2008;19:107-113.
- 298 Das K, Arnold E. HIV-1 reverse transcriptase and antiviral drug resistance. Part 1. *Curr Opin Virol.* 2013;3:111-118.
- 299 Das K, Arnold E. HIV-1 reverse transcriptase and antiviral drug resistance. Part 2. *Curr Opin Virol.* 2013;3:119-128.
- 300 Lapadula G, Izzo I, Gargiulo F, Paraninfo G, Castelnuovo F, Quiros-Roldan E, Cologni G, et al. Updated prevalence of genotypic resistance among HIV-1 positive patients naïve to antiretroviral therapy: a single center analysis. *J Med Virol.* 2008;80:747-753.
- 301 De Feo CJ, Weiss CD. Escape from human immunodeficiency virus type 1 (HIV-1) entry inhibitors. *Viruses.* 2012;4:3859-3911.

- 
- 302 Li JZ, Paredes R, Ribaudo HJ, Svarovskaia ES, Metzner KJ, Kozal MJ, Hullsiek KH, et al. Low-frequency HIV-1 drug resistance mutations and risk of NNRTI-based antiretroviral treatment failure: a systematic review and pooled analysis. *JAMA*. 2011;305:1327-1335.
- 303 Palella FJ Jr, Armon C, Buchacz K, Cole SR, Chmiel JS, Novak RM, Wood K, Moorman AC, Brooks JT. The association of HIV susceptibility testing with survival among HIV-infected patients receiving antiretroviral therapy: a cohort study. *Ann Intern Med*. 2009;151:135-136.
- 304 Perno CF, Moyle G, Tsoukas C, Ratanasuwan W, Gatell J, Schechter M. Overcoming resistance to existing therapies in HIV-infected patients: the role of new antiretroviral drugs. *J Med Virol*. 2008;80:565-576.
- 305 AIDSinfo. Guidelines for the use of antiretroviral agents in HIV-1-infected adults and adolescents. <http://aidsinfo.nih.gov/guidelines> (Accessed April 10, 2015).
- 306 World Health Organization. Antiretroviral therapy. <http://www.who.int/hiv/topics/treatment/en/> (Accessed April 10, 2015).
- 307 Josephson F, Albert J, Flamholc L, Gisslén M, Karlström O, Moberg L, Navér L, et al. Treatment of HIV infection: Swedish recommendations 2009. *Scand J Infect Dis*. 2009;41:788-807.
- 308 Bozzette SA, Joyce G, McCaffrey DF, et al. Expenditures for the care of HIV-infected patients in the era of highly active antiretroviral therapy. *N Engl J Med*. 2001;344:817-823.
- 309 Silverberg MJ, Leyden W, Horberg MA, DeLorenze GN, Klein D, Quesenberry CP. Older age and the response to and tolerability of antiretroviral therapy. *Arch Intern Med*. 2007;167:684-691.
- 310 Elston JW, Thaker H. Immune reconstitution inflammatory syndrome. *Int J STD AIDS*. 2009;20:221-224.
- 311 Tsang CS, Samaranayake LP. Immune reconstitution inflammatory syndrome after highly active antiretroviral therapy: a review. *Oral Dis*. 2010;16:248-256.
- 312 Novak RM, Richardson JT, Buchacz K, Chmiel JS, Durham MD, Palella FJ, Wendrow A, et al. Immune reconstitution inflammatory syndrome: incidence and implications for mortality. *AIDS*. 2012;26:721-730.

- 
- 313 Bell SK, Little SJ, Rosenberg ES. Clinical management of acute HIV infection: best practice remains unknown. *J Infect Dis*. 2010;202 Suppl 2:S278-288.
- 314 Tincati C, Biasin M, Bandera A, Violin M, Marchetti G, Piacentini L, Vago GL, et al. Early initiation of highly active antiretroviral therapy fails to reverse immunovirological abnormalities in gut-associated lymphoid tissue induced by acute HIV infection. *Antivir Ther*. 2009;14:321-330.
- 315 Luzuriaga K, Bryson Y, Krogstad P, et al. Combination treatment with zidovudine, didanosine, and nevirapine in infants with human immunodeficiency virus type I infection. *N Engl J Med*. 1997;336:1343-1349.
- 316 Gortmaker SL, Hughes M, Servia J, et al. Effect of combination therapy including protease inhibitors on mortality among children and adolescents infected with HIV-1. *N Engl J Med*. 2001;345:1522-1528.
- 317 McIntyre J. Strategies to prevent mother-to-child transmission of HIV. *Curr Opin Infect Dis*. 2006;19:33-38.
- 318 Panel on Treatment of HIV-Infected Pregnant Women and Prevention of Perinatal Transmission. Recommendations for Use of Antiretroviral Drugs in Pregnant HIV-1-Infected Women for Maternal Health and Interventions to Reduce Perinatal HIV Transmission in the United States. May 24, 2010; pp 1-117. Available at <http://aidsinfo.nih.gov/ContentFiles/PerinatalGL.pdf> (Accessed April 10, 2015).
- 319 Wade NA, Birkhead GS, Warren BL, et al. Abbreviated regimens of zidovudine prophylaxis and perinatal transmission of the human immunodeficiency virus. *N Engl J Med*. 1998;339:1409-1414.
- 320 Hart CE, Lennox JL, Pratt-Palmore M, et al. Correlation of human immunodeficiency virus type 1 RNA levels in blood and the femal genital tract. *J Infect Dis*. 1999;179:871-882.
- 321 Monge S, Jarrín I, Pérez-Hoyos S, et al; GEMES. Educational level and HIV disease progression before and after the introduction of HAART: a cohort study in 989 HIV seroconverters in Spain. *Sex Transm Infect*. 2011;87(7):571-576.
- 322 Descamps D, Flandre P, Calvez V, et al. Mechanisms of virologic failure in previously untreated HIV-infected patients from a trial of induction-maintenance therapy. *JAMA*. 2000;283:205-211.
- 323 SMART Study Group. CD4+ count-guided interruption of antiretroviral treatment. *N Engl J Med*. 2006;355:2283-2296.

- 
- 324 Ledergerber B, Egger M, Opravil M, et al. Clinical progression and virological failure on highly active antiretroviral therapy in HIV-1 patients: a prospective cohort study. *Lancet*. 1999;353: 863-868.
- 325 Lucas GM, Chaisson RE, Moore RD. Highly active antiretroviral therapy in a large urban clinic: risk factors for virologic failure and adverse drug reactions. *Ann Intern Med*. 1999;131:81-87.
- 326 Eron JJ, Vernazza PL, Johnston DM, et al. Resistance of HIV-1 to antiretroviral agents in blood and seminal plasma: implications for transmission. *AIDS*. 1998;12:F181-189.
- 327 Hecht FM, Grant RM, Petropoulos CJ, et al. Sexual transmission of an HIV-1 variant resistant to multiple reverse-transcriptase and protease inhibitors. *N Engl J Med*. 1998;339:307-311.
- 328 Boden D, Hurley A, Zhang L, et al. HIV-1 drug resistance in newly infected individuals. *JAMA*. 1999;282:1135-1141.
- 329 Paredes R, Clotet B. Clinical management of HIV-1 resistance. *Antiviral Res*. 2010;85:245-265.
- 330 Schragger LK, D'Souza MP. Cellular and anatomical reservoirs of HIV-1 in patients receiving potent antiretroviral combination therapy. *JAMA*. 1998;280:67-71.
- 331 Smith PD, Meng G, Salazar-Gonzalez JF, Shaw GM. Macrophage HIV-1 infection and the gastrointestinal tract reservoir. *J Leukoc Biol*. 2003;74:642-649.
- 332 McComsey GA, Tebas P, Shane E, Yin MT, Overton ET, Huang JS, Aldrovandi GM, Cardoso SW, Santana JL, Brown TT. Bone disease in HIV infection: a practical review and recommendations for HIV care providers. *Clin Infect Dis*. 2010;51(8):937-946.
- 333 Pyrgos V, Shoham S, Roilides E, Walsh TJ. Pneumocystis pneumonia in children. *Paediatr Res*. 2009;10:192-198.
- 334 DeQuiros JCLB, Miro JM, Peña JM, et al. A randomized trial of the discontinuation of primary and secondary prophylaxis against *Pneumocystis carinii* pneumonia after highly active antiretroviral therapy in patients with HIV infection. *N Engl J Med*. 2001;344:159-167.
- 335 Palella FJ Jr, Delaney KM, Moorman AC, et al. Declining morbidity and mortality among patients with advanced human immunodeficiency virus infection. *N Engl J Med*. 1998;338:853-860.

- 
- 336 Szeto GL, Brice AK, Yang HC, Barber SA, Siliciano RF, Clements JE. Minocycline attenuates HIV infection and reactivation by suppressing cellular activation in human CD4+ T cells. *J Infect Dis*. 2010;201:1132-1140.
- 337 INSIGHT-ESPRIT Study Group; SILCAAT Scientific Committee, Abrams D, Lévy Y, Losso MH, Babiker A, Collins G, Cooper DA, Darbyshire J, et al. Interleukin-2 therapy in patients with HIV infection. *N Engl J Med*. 2009;361:1548-1559.
- 338 Duggan J, Peterson WS, Schutz M, Khuder S, Charkraborty J. Use of complementary and alternative therapies in HIV-infected patients. *AIDS Patient Care STDS*. 2001;15:159-167.
- 339 Greene M, Justice AC, Lampiris HW, Valcour V. Management of human immunodeficiency virus infection in advanced age. *JAMA*. 2013;309:1397-1405.
- 340 Camacho RJ. Special aspects of the treatment of HIV-2-infected patients. *Intervirology*. 2012;55:179-183.
- 341 Borrego P, Taveira N. HIV-2 Susceptibility to Entry Inhibitors. *AIDS Rev*. 2013;15:49-61.
- 342 García-Lerma JG, Paxton L, Kilmarx PH, Heneine W. Oral pre-exposure prophylaxis for HIV prevention. *Trends Pharmacol Sci*. 2010;31:74-81.
- 343 Grant RM, Lama JR, Anderson PL, et al. Preexposure Chemoprophylaxis for HIV Prevention in Men Who Have Sex with Men. *N Engl J Med*. 2010;363:2587-2599.
- 344 McMichael AJ. HIV vaccines. *Annu Rev Immunol*. 2006;24:227-255.
- 345 D'Souza MP, Cairns JS, Plaeger SF. Current evidence and future directions for targeting HIV entry. *JAMA*. 2000;284:215-222.
- 346 Durier C, Launay O, Meiffredy V, et al. Clinical safety of HIV lipopeptides used as vaccines in healthy volunteers and HIV-infected adults. *AIDS*. 2006;20:1039-1049.
- 347 Mudd PA, Martins MA, Ericson AJ, Tully DC, Power KA, Bean AT, Piaskowski SM, et al. Vaccine-induced CD8+ T cells control AIDS virus replication. *Nature*. 2012;491:129-133.
- 348 Schiffner T, Sattentau QJ, Dorrell L. Development of prophylactic vaccines against HIV-1. *Retrovirology*. 2013 Jul 17;10:72. doi: 10.1186/1742-4690-10-72.
- 349 Walker BD, Burton DR. Toward an AIDS vaccine. *Science*. 2008;320(5877):760-764.

- 
- 350 von Laer D, Hasselmann S, Hasselmann K. Gene therapy for HIV infection: what does it need to make it work? *J Gene Med*. 2006;8:658-667.
- 351 Baden LR, Dolin R. The road to an effective HIV vaccine. *N Engl J Med*. 2012;366(14):1343-1344.
- 352 Richman DD, Margolis DM, Delaney M, Greene WC, Hazuda D, Pomerantz RJ. The challenge of finding a cure for HIV infection. *Science*. 2009;323(5919):1304-1307.
- 353 Le Douce V, Janossy A, Hallay H, Ali S, Riclet R, Rohr O, Schwartz C. Achieving a cure for HIV infection: do we have reasons to be optimistic? *J Antimicrob Chemother*. 2012;67(5):1063-1074.
- 354 Barton KM, Burch BD, Soriano-Sarabia N, Margolis DM. Prospects for treatment of latent HIV. *Clin Pharmacol Ther*. 2013;93:46-56.
- 355 McNulty A, Jennings C, Bennett D, Fitzgibbon J, Bremer JW, Ussery M, Kalish ML, Heneine W, García-Lerma JG. Evaluation of dried blood spots for human immunodeficiency virus type 1 drug resistance testing. *J Clin Microbiol*. 2007;45:517-521.
- 356 Cohen MS, Shaw GM, McMichael AJ, Haynes BF. Acute HIV-1 Infection. *N Engl J Med*. 2011;364(20):1943-1954.
- 357 Mylonakis E, Paliou M, Lally M, Flanigan TP, Rich JD. Laboratory testing for infection with the human immunodeficiency virus: established and novel approaches. *Am J Med*. 2000;109:568-576.
- 358 Schito ML, D'Souza MP, Owen SM, Busch MP. Challenges for rapid molecular HIV diagnostics. *J Infect Dis*. 2010;201 Suppl 1:S1-6.
- 359 Hutchinson AB, Branson BM, Kim A, Farnham PG. A meta-analysis of the effectiveness of alternative HIV counseling and testing methods to increase knowledge of HIV status. *AIDS*. 2006;20:1597-1604.
- 360 Branson BM. State of the art for diagnosis of HIV infection. *Clin Infect Dis*. 2007;45 (Suppl 4):S221-225.
- 361 Constantine NT, Zink H. HIV testing technologies after two decades of evolution. *Indian J Med Res*. 2005;121:519-538.
- 362 Branson BM. The future of HIV testing. *J Acquir Immune Defic Syndr*. 2010;55 Suppl 2:S102-105.

- 
- 363 Fanmi AN, Ramière C, Tardy JC, André P. Real-life evaluation of a human immunodeficiency virus screening algorithm using a single combined p24 antigen-antibody assay. *Eur J Clin Microbiol Infect Dis*. 2013;32:425-430.
- 364 Holguín A, Gutiérrez M, Portocarrero N, Rivas P, Baquero M. Performance of OraQuick Advance((R)) Rapid HIV-1/2 Antibody Test for detection of antibodies in oral fluid and serum/plasma in HIV-1+ subjects carrying different HIV-1 subtypes and recombinant variants. *J Clin Virol*. 2009;45:150-152.
- 365 Chan D, Stewart M, Smith M, Price T, Lusk J, Ooi C, Read P, Finlayson R. The rise of targeted HIV oral rapid testing in Australia. *Med J Aust*. 2015;202:251-255.
- 366 Hashida S, Hashinaka K, Ishikawa S, Ishikawa E. More reliable diagnosis of infection with human immunodeficiency virus type 1 (HIV-1) by detection of antibody IgGs to pol and gag proteins of HIV-1 and p24 antigen of HIV-1 in urine, saliva, and/or serum with highly sensitive and specific enzyme immunoassay (immune complex transfer enzyme immunoassay): a review. *J Clin Lab Anal*. 1997;11:267-286.
- 367 Vessière A, Rousset D, Kfutwah A, Leoz M, Depatureaux A, Simon F, Plantier JC. Diagnosis and monitoring of HIV-1 group O-infected patients in Cameroun. *J Acquir Immune Defic Syndr*. 2010;53:107-110.
- 368 Cárdenas AM, Baughan E, Hodinka RL. Evaluation of the Bio-Rad Multispot HIV-1/HIV-2 Rapid Test as an alternative to Western blot for confirmation of HIV infection. *J Clin Virol*. 2013;58 Suppl 1:e97-e103.
- 369 Bennett B, Neumann D, Fordan S, Villaraza R, Crowe S, Gillis L. Performance of the new HIV-1/2 Diagnostic Algorithm in Florida's public health testing population: A review of the first five months of utilization. *J Clin Virol*. 2013;58 Suppl 1:e29-33.
- 370 Sloand EM, Pitt E, Chiarello RJ, Nemo GJ. HIV testing: State of the art. *JAMA*. 1991;266:2861-2866.
- 371 Sullivan PS, Schable C, Koch W, et al. Persistently negative HIV-1 antibody enzyme immunoassay screening results for patients with HIV-1 infection and AIDS: serologic, clinical, and virologic results. *AIDS*. 1999;13:89-96.
- 372 Johannessen A, Trøseid M, Calmy A. Dried blood spots can expand access to virological monitoring of HIV treatment in resource-limited settings. *J Antimicrob Chemother*. 2009;64:1126-1129.
- 373 Spielberg F, Levine RO, Weaver M. Self-testing for HIV: a new option for HIV prevention? *Lancet Infect Dis*. 2004;4:640-646.

- 
- 374 Walensky RP, Paltiel AD. Rapid HIV testing at home: does it solve a problem or create one? *Ann Intern Med*. 2006;145:459-462.
- 375 Benjamin RJ. Nucleic acid testing: update and applications. *Semin Hematol*. 2001;38(4 Suppl 9):11-16.
- 376 Scuracchio PS, Poli MC, Lemos MM, Oliveira Filho AG, Salles NA, Chamone DA, Magri M, Cavalcante NJ, Collela R. Detection of HIV-1 infection in blood donors during the immunological window period using the nucleic acid-amplification technology. *Transfus Med*. 2007;17:200-204.
- 377 Jackson JB. Human immunodeficiency virus type 1 antigen and culture assays. *Arch Pathol Lab Med*. 1990;114:249-253.
- 378 Palumbo P. Laboratory findings in HIV infection in infancy. *Clin Perinatol*. 1994;21:109-124.
- 379 Centers for Disease Control. U.S. Public Health Service guidelines for testing and counseling blood and plasma donors for human immunodeficiency virus type 1 antigen. *MMWR*. 1996;45(RR-2):1-9.
- 380 Wessman MJ, Theilgaard Z, Katzenstein TL. Determination of HIV status of infants born to HIV-infected mothers: a review of the diagnostic methods with special focus on the applicability of p24 antigen testing in developing countries. *Scand J Infect Dis*. 2012;44:209-215.
- 381 Sherman GG, Stevens G, Stevens WS. Affordable diagnosis of human immunodeficiency virus infection in infants by p24 antigen detection. *Pediatr Infect Dis J*. 2004 Feb;23(2):173-176.
- 382 Jackson JB. Detection and quantitation of human immunodeficiency virus type 1 using molecular DNA/RNA technology. *Arch Pathol Lab Med*. 1993;117:473-477.
- 383 Nesheim S, Palumbo P, Sullivan K, Lee F, Vink P, Abrams E, Bulterys M. Quantitative RNA testing for diagnosis of HIV-infected infants. *J Acquir Immune Defic Syndr*. 2003;32:192-195.
- 384 Robinson LG, Fernandez AD. Clinical care of the exposed infants of HIV-infected mothers. *Clin Perinatol*. 2010;37:863-872.
- 385 Centers for Disease Control. Guidelines for laboratory test result reporting of human immunodeficiency virus type 1 ribonucleic acid determination. *MMWR*. 2001;50(RR20):1-12.
- 386 Relucio K, Holodniy. HIV-1 RNA and viral load. *Clin Lab Med*. 2002;22:593-610.



- 
- 387 Chew CB, Herring BL, Zheng F, Browne C, Saksena NK, Cunningham AL, Dwyer DE. Comparison of three commercial assays for the quantification of HIV-1 RNA in plasma from individuals infected with different HIV-1 subtypes. *J Clin Virol.* 1999;14:87-94.
- 388 Mellors JW, Rinaldo CR Jr, Gupta P, White R, Todd JA, Kingsley L. Prognosis in HIV infection predicted by the quantity of virus in plasma. *Science.* 1996;272:1167-1170.
- 389 Mulder J, McKinney N, Christopherson C, Sninsky J, Greenfield L, Kwok S. Rapid and simple PCR assay for quantitation of human immunodeficiency virus type 1 RNA in plasma: application to acute retroviral infection. *J Clin Microbiol.* 1994;32:292-300.
- 390 O'Brien WA, Hartigan PM, Martin D, et al. Changes in plasma HIV-1 RNA and CD4+ lymphocyte counts and the risk of progression to AIDS. *N Engl J Med.* 1996;334:426-431.
- 391 Deeks SG, Coleman RL, White R, et al. Variance of plasma human immunodeficiency virus type 1 RNA levels measured by branched DNA within and between days. *J Infect Dis.* 1997;176:514-517.
- 392 Bush CE, Donovan RM, Markowitz NP, Kvale P, Saravolatz LD. A study of HIV RNA viral load in AIDS patients with bacterial pneumonia. *J Acquir Immune Defic Syndr Hum Retrovirol.* 1996;13:23-26.
- 393 Ren A, Louie B, Rauch L, Castro L, Liska S, Klausner JD, Pandori MW. Screening and confirmation of human immunodeficiency virus type 1 infection solely by detection of RNA. *J Med Microbiol.* 2008;57:1228-1233.
- 394 O'Gorman MRG, Weber D, Landis SE, Schoenbach VJ, Mittal M, Folds JD. Interpretive criteria of the western blot assay for serodiagnosis of human immunodeficiency virus type 1 infection. *Arch Pathol Lab Med.* 1991;115:26-30.
- 395 Mahajan VS, Pace CA, Jarolim P. Interpretation of HIV serologic testing results. *Clin Chem.* 2010;56:1523-1526.
- 396 Guan M. Frequency, causes, and new challenges of indeterminate results in Western blot confirmatory testing for antibodies to human immunodeficiency virus. *Clin Vaccine Immunol.* 2007;14:649-659.
- 397 Celum CL, Coombs RW, Jones M, Murphy V, Fisher L, Grant C, Corey L, et al. Risk factors for repeatedly reactive HIV-1 EIA and indeterminate Western blots. *Arch Intern Med.* 1994;154:1129-1137.

- 
- 398 Jackson JB, Hanson MR, Johnson GM, Spahlinger TG, Polesky HF, Bowman RJ. Long-term follow-up of blood donors with indeterminate human immunodeficiency virus type 1 results on Western blot. *Transfusion*. 1995;35:98-102.
- 399 Henrard DR, Phillips J, Windsor I, Fortenberry D, Korte L, Fang C, Williams AE. Detection of human immunodeficiency virus type 1 p24 antigen and plasma RNA: relevance to indeterminate serologic tests. *Transfusion*. 1994;34:376-380.
- 400 Dodd RY, Fang CT. The Western immunoblot procedure for HIV antibodies and its interpretation. *Arch Pathol Lab Med*. 1990;114:240-245.
- 401 Kleinman S. The significance of HIV-1-indeterminate Western blot results in blood donor populations. *Arch Pathol Lab Med*. 1990;114:298-303.
- 402 Hecht FM, Wellman R, Busch MP, Pilcher CD, Norris PJ, Margolick JB, Collier AC, et al; Acute Infection Early Disease Research Program. Identifying the early post-HIV antibody seroconversion period. *J Infect Dis*. 2011;204(4):526-533.
- 403 Duong YT, Qiu M, De AK, Jackson K, Dobbs T, Kim AA, Nkengasong JN, Parekh BS. Detection of recent HIV-1 infection using a new limiting-antigen avidity assay: potential for HIV-1 incidence estimates and avidity maturation studies. *PLoS One*. 2012;7(3):e33328. doi: 10.1371/journal.pone.0033328.
- 404 Napravnik S, Cachafeiro A, Stewart P, Eron JJ Jr, Fiscus SA. HIV-1 viral load and phenotypic antiretroviral drug resistance assays based on reverse transcriptase activity in comparison to amplification based HIV-1 RNA and genotypic assays. *J Clin Virol*. 2010;47:18-22.
- 405 Quinn TC, Kline RL, Halsey N, et al. Early diagnosis of perinatal HIV infection by detection of viral-specific IgA antibodies. *JAMA*. 1991;266:3439-3442.
- 406 Ravanshad M, Sabahi F, Mahboudi F, Roostaei MH, Forooshani RS, Kazemnejad A. An Accurate Confirmation of Human Immunodeficiency Virus Type 1 (HIV-1) and 2 (HIV-2) Infections with a Dot blot assay Using Recombinant p24, gp41, gp120 and gp36 Antigens. *Int J Med Sci*. 2004;1:193-200.
- 407 Zehner R, Bratzke H, Mebs D. Evaluation of a rapid assay system, HIV 1/HIV 2 Testpack, Abbott, to detect human immunodeficiency virus antibodies in postmortem blood. *J Forensic Sci*. 1995;40:113-115.
- 408 Moonim MT, Alarcon L, Freeman J, Mahadeva U, van der Walt JD, Lucas SB. Identifying HIV infection in diagnostic histopathology tissue samples--the role of HIV-1 p24 immunohistochemistry in identifying clinically unsuspected HIV infection: a 3-year analysis. *Histopathology*. 2010;56:530-541.

- 
- 409 Shapshak P, Sun NC, Resnick L, et al. The detection of HIV by *in situ* hybridization. *Modern Pathol.* 1990;3:146-153.
- 410 Sharma UK, Song HF, Willingham FF, et al. Diagnosis of human immunodeficiency virus infection using citrated whole blood. *Clin Diagn Lab Immunol.* 1997;4:261-263.
- 411 Centers for Disease Control. 1997 Guidelines for performing CD4+ T-cell determinations in persons infected with the human immunodeficiency virus (HIV). *MMWR.* 1997;46(RR-2):1-29.
- 412 Gompels M, Dunn DT, Phillips A, Dooley D, De Burgh Thomas A, Anderson J, Post F, et al. Does discordancy between the CD4 count and CD4 percentage in HIV-positive individuals influence outcomes on highly active antiretroviral therapy? *J Infect Dis.* 2012;205:540-547.
- 413 Carmichael KF, Abayomi A. Analysis of diurnal variation of lymphocyte subsets in healthy subjects in the Caribbean, and its implication in HIV monitoring and treatment. *Afr J Med Med Sci.* 2006;35:53-57.
- 414 Raboud JM, Haley L, Montaner JS, Murphy C, Januszewska M, Schechter MT. Quantification of the variation due to laboratory and physiologic sources in CD4 lymphocyte counts of clinically stable HIV-infected individuals. *J Acquir Immune Defic Syndr Hum Retrovirol.* 1995;10 (Suppl 2):S67-S73.
- 415 Nixon DE, Landay AL. Biomarkers of immune dysfunction in HIV. *Curr Opin HIV AIDS.* 2010;5:498-503.
- 416 Leeansyah E, Malone DF, Anthony DD, Sandberg JK. Soluble biomarkers of HIV transmission, disease progression and comorbidities. *Curr Opin HIV AIDS.* 2013;8:117-124.
- 417 Owen SM, Yang C, Spira T, Ou CY, Pau CP, Parekh BS, Candal D, et al. Alternative algorithms for human immunodeficiency virus infection diagnosis using tests that are licensed in the United States. *J Clin Microbiol.* 2008;46:1588-1595.
- 418 Centers for Disease Control. Revision of the CDC surveillance case definition for acquired immunodeficiency syndrome. *MMWR.* 1987;36(Suppl):3S-15S.
- 419 Centers for Disease Control. Classification system for human immunodeficiency virus (HIV) infection in children under 13 years of age. *MMWR.* 1987;36:225-230.
- 420 Centers for Disease Control. 1994 revised classification system for human immunodeficiency virus infection in children less than 13 years of age. *MMWR.* 1994;43(RR-12)1-10.

- 
- 421 Centers for Disease Control. Revised classification system for HIV infection and expanded surveillance case definition for AIDS among adolescents and adults. *MMWR*. 1992;41(RR-17):1-19.
- 422 Centers for Disease Control. Guidelines for national human immunodeficiency virus case surveillance, including monitoring for human immunodeficiency virus infection and acquired immunodeficiency syndrome. *MMWR*. 1999;48(RR13):1-31.
- 423 Schneider E, Whitmore S, Glynn KM, Dominguez K, Mitsch A, McKenna MT; Centers for Disease Control and Prevention (CDC). Revised surveillance case definitions for HIV infection among adults, adolescents, and children aged <18 months and for HIV infection and AIDS among children aged 18 months to <13 years--United States, 2008. *MMWR Recomm Rep*. 2008;57(RR-10):1-12.
- 424 World Health Organization. Antiretroviral therapy for HIV infection in adults and adolescents. Recommendations for a public health approach: 2010 revision. [http://whqlibdoc.who.int/publications/2010/9789241599764\\_eng.pdf](http://whqlibdoc.who.int/publications/2010/9789241599764_eng.pdf) (Accessed April 10, 2015).
- 425 Read JS; Committee on Pediatric AIDS, American Academy of Pediatrics. Diagnosis of HIV-1 infection in children younger than 18 months in the United States. *Pediatrics*. 2007;120:e1547-1562.
- 426 Klepser ME, Klepser TB. Drug treatment of HIV-related opportunistic infections. *Drugs*. 1997;53:40-73.
- 427 Catherinot E, Lanternier F, Bougnoux ME, Lecuit M, Couderc LJ, Lortholary O. *Pneumocystis jirovecii* Pneumonia. *Infect Dis Clin North Am*. 2010;24:107-138.
- 428 Gilroy SA, Bennett NJ. *Pneumocystis pneumonia*. *Semin Respir Crit Care Med*. 2011;32:775-782.
- 429 Llibre JM, Revollo B, Vanegas S, Lopez-Nuñez JJ, Ornelas A, Marin JM, Santos JR, et al. *Pneumocystis jirovecii* pneumonia in HIV-1-infected patients in the late-HAART era in developed countries. *Scand J Infect Dis*. 2013 Apr 3.
- 430 Helweg-Larsen, J., C. H. Lee, S. Jin, J. Y. Hsueh, T. L. Benfield, J. Hansen, J. D. Lundgren, and B. Lundgren. 2001. Clinical correlation of variations in the internal transcribed spacer regions of rRNA genes in *Pneumocystis carinii* f. sp. hominis. *AIDS*. 2001;15:451-459.

- 
- 431 Kovacs JA, Gill VJ, Meshnick S, Masur H. New insights into transmission, diagnosis, and drug treatment of *Pneumocystis carinii* pneumonia. *JAMA*. 2001;286:2450-2460.
- 432 Wazir JF, Ansari NA. *Pneumocystis carinii* Infection: Update and Review. *Arch Pathol Lab Med*. 2004;128:1023-1027.
- 433 Thomas CF Jr, Limper AH. *Pneumocystis* pneumonia. *N Engl J Med*. 2004;350:2487-2498.
- 434 Garvey W, Fathi A, Bigelow F, Jimenez C, Carpenter B. One minute oxidation with silver impregnation for fungi and *Pneumocystis carinii*. *J Histotechnol*. 1992;15:307-310.
- 435 Churukian CJ, Schenk EA, Clark G. Dilute ammoniacal silver as a substitute for methenamine silver to demonstrate *Pneumocystis carinii* and fungi. *Lab Medicine*. 1986;17:87-90.
- 436 Orenstein M, Webber CA, Heurich AE. Cytologic diagnosis of *Pneumocystis carinii* infection by bronchoalveolar lavage in acquired immune deficiency syndrome. *Acta Cytol*. 1985;29:727-731.
- 437 Blumenfeld W, Griffiss JM. *Pneumocystis carinii* in sputum. Comparable efficacy of screening stains and determination of cyst density. *Arch Pathol Lab Med*. 1988;112:816-820.
- 438 Fraire AE, Kemp B, Greensberg SD, Kim H-S, Estrada R, McBride RA. Calcofluor white stain for the detection of *Pneumocystis carinii* in transbronchial lung biopsy specimens: a study of 68 cases. *Mod Pathol*. 1996;9:861-864.
- 439 Aslanzadeh J, Stelmach PS. Detection of *Pneumocystis carinii* with direct fluorescence antibody and calcofluor white stain. *Infection*. 1996;24:248-250.
- 440 Samuel CM, Whitelaw A, Corcoran C, Morrow B, Hsiao NY, Zampoli M, Zar HJ. Improved detection of *Pneumocystis jirovecii* in upper and lower respiratory tract specimens from children with suspected pneumocystis pneumonia using real-time PCR: a prospective study. *BMC Infect Dis*. 2011;11:329.
- 441 Harris JR, Marston BJ, Sangrue N, DuPlessis D, Park B. Cost-effectiveness analysis of diagnostic options for pneumocystis pneumonia (PCP). *PLoS One*. 2011;6(8):e23158. doi: 10.1371/journal.pone.0023158.
- 442 Strigle SM, Gal AA, Koss MN. Rapid diagnosis of *Pneumocystis carinii* infection in AIDS by cytocentrifugation and rapid hematoxylin-eosin staining. *Diagn Cytopathol*. 1990;6:164-168.

- 
- 443 Lautenschlager I, Lyytikainen O, Jokipii L, et al. Immunodetection of *Pneumocystis carinii* in bronchoalveolar lavage specimens compared with methenamine silver stain. *J Clin Microbiol.* 1996;34:728-730.
- 444 Armbruster C, Pokieser L, Hassl A. Diagnosis of *Pneumocystis carinii* pneumonia by bronchoalveolar lavage in AIDS patients. Comparison of Diff-Quik, fungifluor stain, direct immunofluorescence test and polymerase chain reaction. *Acta Cytol.* 1995;39:1089-1093.
- 445 Nakamura H, Tateyama M, Tasato D, Haranaga S, Yara S, Higa F, Ohtsuki Y, Fujita J. Clinical utility of serum beta-D-glucan and KL-6 levels in *Pneumocystis jiroveci* pneumonia. *Intern Med.* 2009;48:195-202.
- 446 Radin DR, Baker EL, Klatt EC, et al. Visceral and nodal calcification in patients with AIDS-related *Pneumocystis carinii* infection. *AJR.* 1990;154:27-31.
- 447 Pantongrag-Brown L, Nelson AM, Brown AE, Buetow PC, Buck JL. Gastrointestinal manifestations of acquired immunodeficiency syndrome: radiologic-pathologic correlation. *Radiographics.* 1995;15:1155-1178.
- 448 Klatt EC, Nichols L, Noguchi TT. Evolving trends revealed by autopsies of patients with AIDS. *Arch Pathol Lab Med.* 1994;118:884-890.
- 449 Smith MA, Brennessel DJ. Cytomegalovirus. *Infect Dis Clin North Am.* 1994;8:427-438.
- 450 Klatt EC, Shibata D. Cytomegalovirus infection in the acquired immunodeficiency syndrome: clinical and autopsy findings. *Arch Pathol Lab Med.* 1988;112:540-544.
- 451 Delvenne P, Margiotta M, Nuovo GJ. Comparison of in situ hybridization and immunohistochemistry for detection of cytomegalovirus infection in fixed tissue sections. *J Histotechnol.* 1993;16:27-31.
- 452 Ahmed A. Antiviral treatment of cytomegalovirus infection. *Infect Disord Drug Targets.* 2011;11:475-503.
- 453 Horsburgh Jr CR. The pathophysiology of disseminated *Mycobacterium avium* complex disease in AIDS. *J Infect Dis.* 1999;179(Suppl 3):S461-S465.
- 454 Klatt EC, Jensen DF, Meyer PR. Pathology of *Mycobacterium avium-intracellulare* infection in patients with AIDS. *Hum Pathol.* 1987;18:709-14.
- 455 Benson CA, Ellner JJ. *Mycobacterium avium* complex infection and AIDS: advances in theory and practice. *Clin Infect Disease.* 1993;17:7-20.

- 
- 456 Kilby JM, Marques MB, Jaye DL, Tabereaux PB, Reddy VB, Waites KB. The yield of bone marrow biopsy and culture compared with blood culture in the evaluation of HIV-infected patients for mycobacterial and fungal cultures. *Am J Med.* 1998;104:123-128.
- 457 Wannakrairot P, Leong TY, Leong AS. The morphological spectrum of lymphadenopathy in HIV infected patients. *Pathology.* 2007;39:223-227.
- 458 Shafran SD, Singer J, Zarowny DP, et al. A comparison of two regimens for the treatment of Mycobacterium avium complex bacteremia in AIDS: rifabutin, ethambutol, and clarithromycin versus rifampin, ethambutol, clofazimine, and ciprofloxacin. *N Engl J Med.* 1996;335:377-383.
- 459 Havlir DV, Barnes PF. Tuberculosis in patients with human immunodeficiency virus infection. *N Engl J Med.* 1999;340:367-373.
- 460 Waxman Getahun H, Gunneberg C, Granich R, Nunn P. HIV infection-associated tuberculosis: the epidemiology and the response. *Clin Infect Dis.* 2010;50Suppl3:S201-207.
- 461 Centers for Disease Control and Prevention. Reported HIV status of tuberculosis patients--United States, 1993-2005. *MMWR.* 2007;56:1103-1106.
- 462 Anandaiah A, Dheda K, Keane J, Koziel H, Moore DA, Patel NR. Novel developments in the epidemic of human immunodeficiency virus and tuberculosis coinfection. *Am J Respir Crit Care Med.* 2011;183(8):987-997.
- 463 Schneider E, Moore M, Castro KG. Epidemiology of tuberculosis in the United States. *Clin Chest Med.* 2005;26:183-195.
- 464 Mesfin YM, Hailemariam D, Biadgign S, Kibret KT. Association between HIV/AIDS and multi-drug resistance tuberculosis: a systematic review and meta-analysis. *PLoS One.* 2014 Jan 8;9(1):e82235. doi: 10.1371/journal.pone.0082235.
- 465 Dheda K, Warren RM, Zumla A, Grobusch MP. Extensively drug-resistant tuberculosis: epidemiology and management challenges. *Infect Dis Clin North Am.* 2010;24:705-725.
- 466 Fischl MA, Daikos GL, Uttamchandani RB, Poblete RB, Moreno JN, Reyes RR, et al. Clinical presentation and outcome of patients with HIV infection and tuberculosis caused by multiple-drug-resistant bacilli. *Ann Intern Med.* 1992;117:184-190.
- 467 Wells CD, Cegielski JP, Nelson LJ, Laserson KF, Holtz TH, Finlay A, et al. HIV infection and multidrug-resistant tuberculosis: the perfect storm. *J Infect Dis.* 2007;196(Suppl):S86-107.

- 
- 468 Van Rie A, Westreich D, Sanne I. Tuberculosis in patients receiving antiretroviral treatment: incidence, risk factors, and prevention strategies. *J Acquir Immune Defic Syndr*. 2011;56:349-355.
- 469 Aichelburg MC, Rieger A, Breitenecker F, et al. Detection and prediction of active tuberculosis disease by a whole-blood interferon-[gamma] release assay in HIV-1-infected individuals. *Clin Infect Dis*. 2009;48:954-962.
- 470 Monkongdee P, McCarthy KD, Cain KP, Tasaneeyapan T, Nguyen HD, Nguyen TN, Nguyen TB, et al. Yield of acid-fast smear and mycobacterial culture for tuberculosis diagnosis in people with human immunodeficiency virus. *Am J Respir Crit Care Med*. 2009;180(9):903-908.
- 471 Azzopardi P, Bennett CM, Graham SM, Duke T. Bacille Calmette-Guérin vaccine-related disease in HIV-infected children: a systematic review. *Int J Tuberc Lung Dis*. 2009;13:1331-1344.
- 472 Leung AN, Brauner MW, Gamsu G, et al. Pulmonary tuberculosis: comparison of CT findings in HIV-seropositive and HIV-seronegative patients. *Radiology*. 1996;198:687-691.
- 473 Hsieh S-M, Hung C-C, Chen M-Y, Hsueh P-R, Chang S-C, Luh K-T. Clinical features and outcome in disseminated mycobacterial diseases in AIDS patients in Taiwan. *AIDS*. 1998;12:1301-1307.
- 474 DiPerri G, Cazzadori A, Vento S, et al. Comparative histopathological study of pulmonary tuberculosis in human immunodeficiency virus-infected and non-infected patients. *Tuber Lung Dis*. 1996;77:244-249.
- 475 von Reyn CF, Kimambo S, Mtei L, Arbeit RD, Maro I, Bakari M, Matee M, et al. Disseminated tuberculosis in human immunodeficiency virus infection: ineffective immunity, polyclonal disease and high mortality. *Int J Tuberc Lung Dis*. 2011;15:1087-1092.
- 476 Schutz C, Meintjes G, Almajid F, Wilkinson RJ, Pozniak A. Clinical management of tuberculosis and HIV-1 co-infection. *Eur Respir J*. 2010;36:1460-1481.
- 477 Smith MB, Schnadig VJ, Boyars MC, Woods GL. Clinical and pathologic features of *Mycobacterium fortuitum* infections. *Am J Clin Pathol*. 2001;116:225-232.
- 478 Kerbiriou L, Ustianowski A, Johnson MA, Gillespie SH, Miller RF, Lipman MC. Human immunodeficiency virus type 1-related pulmonary *Mycobacterium xenopi* infection: a need to treat? *Clin Infect Dis*. 2003;37:1250-1254.



- 
- 479 El-Helou P, Rachlis A, Fong I, Walmsley S, Phillips A, Salit I, Simor AE. Mycobacterium xenopi infection in patients with human immunodeficiency virus infection. *Clin Infect Dis*. 1997;25:206-210.
- 480 Henkle E, Winthrop KL. Nontuberculous mycobacteria infections in immunosuppressed hosts. *Clin Chest Med*. 2015;36:91-99.
- 481 Meyer CG, Scarisbrick G, Niemann S, Browne EN, Chinbuah MA, Gyapong J, Osei I, et al. Pulmonary tuberculosis: virulence of Mycobacterium africanum and relevance in HIV co-infection. *Tuberculosis (Edinb)*. 2008;88:482-489.
- 482 Smith MB, Molina CP, Schnadig VJ, Boyars MC, Aronson JF. Pathologic features of Mycobacterium kansasii infection in patients with acquired immunodeficiency syndrome. *Arch Pathol Lab Med*. 2003;127:554-560.
- 483 Kelley CF, Armstrong WS, Eaton ME. Disseminated Mycobacterium haemophilum infection. *Lancet Infect Dis*. 2011;11(7):571-578.
- 484 Walsh DS, Portaels F, Meyers WM. Buruli ulcer (Mycobacterium ulcerans infection). *Trans R Soc Trop Med Hyg*. 2008;102:969-978.
- 485 Warkentin T, Crum-Cianflone NF. An update on Cryptococcus among HIV-infected patients. *Int J STD AIDS*. 2010;21(10):679-684.
- 486 Miceli MH, Díaz JA, Lee SA. Emerging opportunistic yeast infections. *Lancet Infect Dis*. 2011;11:142-151.
- 487 Rodríguez-Cerdeira C, Arenas R, Moreno-Coutiño G, Vázquez E, Fernández R, Chang P. Systemic fungal infections in patients with human immunodeficiency virus. *Actas Dermosifiliogr*. 2014;105:5-17.
- 488 Powderly WG. Cryptococcal meningitis in HIV-infected patients. *Curr Infect Dis Rep*. 2000;2:352-357.
- 489 Müller F-MC, Groll AH, Walsh TJ. Current approaches to diagnosis and treatment of fungal infections in children infected with human immunodeficiency virus. *Eur J Pediatr*. 1999;158:187-199.
- 490 Minamoto GY, Rosenberg AS. Fungal infections in patients with acquired immunodeficiency syndrome. *Med Clin North Am*. 1997;81:389-409.

- 
- 491 Shibuya K, Coulson WF, Wollman JS, et al. Histopathology of cryptococcosis and other fungal infection in patients with acquired immunodeficiency syndrome. *Int J Infect Dis.* 2001;5:78-85.
- 492 Lazcano O, Speights VO Jr, Strickler JG, Bilbao, Becker J, Diaz J. Combined histochemical stains in the differential diagnosis of *Cryptococcus neoformans*. *Mod Pathol.* 1993;6:80-84.
- 493 Quinnan GV Jr, Masur H, Rook AH, et al. Herpesvirus infections in the acquired immune deficiency syndrome. *JAMA.* 1984;252:72-77.
- 494 Walling DM, Flaitz CM, Nichols CM. Epstein-Barr virus replication in oral hairy leukoplakia: response, persistence, and resistance to treatment with valacyclovir. *J Infect Dis.* 2003;188:883-890.
- 495 Kosuge H. HHV-6, 7 and their related diseases. *J Dermatol Sci.* 2000;22:205-212.
- 496 Sheth PM, Sunderji S, Shin LY, Rebbapragada A, Huibner S, Kimani J, Macdonald KS, et al. Coinfection with herpes simplex virus type 2 is associated with reduced HIV-specific T cell responses and systemic immune activation. *J Infect Dis.* 2008;197:1394-1401.
- 497 Corey L, Spear PG. Infections with herpes simplex virus (Part I). *N Engl J Med* 1986;314:686-691(part I) and 749-757(part II).
- 498 Vafai A, Berger M. Zoster in patients infected with HIV: a review. *Am J Med Sci.* 2001;321:372-380.
- 499 Blank LJ, Polydefkis MJ, Moore RD, Gebo KA. Herpes zoster among persons living with HIV in the current antiretroviral therapy era. *J Acquir Immune Defic Syndr.* 2012;61:203-207.
- 500 Safrin S, Ashley R, Houlihan C, Cusick PS, Mills J. Clinical and serologic features of herpes simplex virus infection in patients with AIDS. *AIDS.* 1991;5:1107-1110.
- 501 Van de Perre P, Segondy M, Foulongne V, Ouedraogo A, Konate I, Huraux JM, Mayaud P, Nagot N. Herpes simplex virus and HIV-1: deciphering viral synergy. *Lancet Infect Dis.* 2008;8:490-497.
- 502 Nikkels AF, Snoeck R, Rentier B, Pierard GE. Chronic verrucous varicella zoster virus skin lesions: clinical, histological, molecular, and therapeutic aspects. *Clin Exp Dermatol.* 1999;24:346-353.
- 503 Sanguenza OP, Gordon MD, White CR Jr. Subtle clues to the diagnosis of the herpesvirus by light microscopy. Herpetic syringitis. *Am J Dermatol.* 1995;17:163-168.

- 
- 504 Gilbert C, Bestman-Smith J, Boivin G. Resistance of herpesviruses to antiviral drugs: clinical impacts and molecular mechanisms. *Drug Resist Updat*. 2002;5:88-114.
- 505 Clark DA. Human herpesvirus 6. *Rev Med Virol*. 2000;10:155-173.
- 506 Black JB, Pellett PE. Human herpesvirus 7. *Rev Med Virol*. 1999;9:245-262.
- 507 Kempf W, Muller B, Maurer R, Adams V, Campadelli Fiume G. Increased expression of human herpesvirus 7 in lymphoid organs of AIDS patients. *J Clin Virol*. 2000;16:193-201.
- 508 Laurent C, Meggetto F, Brousset P. Human herpesvirus 8 infections in patients with immunodeficiencies. *Hum Pathol*. 2008;39:983-993.
- 509 Wen KW, Damania B. Kaposi sarcoma-associated herpesvirus (KSHV): molecular biology and oncogenesis. *Cancer Lett*. 2010;289:140-150.
- 510 La Ferla L, Pinzone MR, Nunnari G, Martellotta F, Lleshi A, Tirelli U, De Paoli P, Berretta M, Cacopardo B. Kaposi's sarcoma in HIV-positive patients: the state of art in the HAART-era. *Eur Rev Med Pharmacol Sci*. 2013;17:2354-2365.
- 511 Egusa H, Soysa NS, Ellepola AN, Yatani H, Samaranayake LP. Oral candidosis in HIV-infected patients. *Curr HIV Res*. 2008;6:485-499.
- 512 Berberi A, Noujeim Z, Aoun G. Epidemiology of oropharyngeal candidiasis in human immunodeficiency virus/acquired immune deficiency syndrome patients and CD4+ counts. *J Int Oral Health*. 2015;7:20-23.
- 513 DeRepentigny L, Lewandowski D, Jolicoeur P. Immunopathogenesis of oropharyngeal candidiasis in human immunodeficiency virus infection. *Clin Microbiol Rev*. 2004;17:729-759.
- 514 Tschirhart DL and Klatt EC. Disseminated toxoplasmosis in the acquired immunodeficiency syndrome. *Arch Pathol Lab Med*. 1988;112:1237-1241.
- 515 Wong S-Y, Remington JS. Biology of *Toxoplasma gondii*. *AIDS*. 1993;7:299-316.
- 516 Rabaud C, May T, Amiel C, Katlama C, Leport C, Ambroise-Thomas P, Canton P. Extracerebral toxoplasmosis in patients infected with HIV. A French national survey. *Medicine*. 1994;73:306-314.
- 517 Loulergue P, Bastides F, Baudouin V, Chandenier J, Mariani-Kurkdjian P, Dupont B, Viard JP, et al. Literature review and case histories of *Histoplasma capsulatum* var. *duboisii* infections in HIV-infected patients. *Emerg Infect Dis*. 2007;13:1647-1652.

- 
- 518 Martin-Iguacel R, Kurtzhals J, Jouvion G, Nielsen SD, Llibre JM. Progressive disseminated histoplasmosis in the HIV population in Europe in the HAART era. Case report and literature review. *Infection*. 2014;42:611-620.
- 519 Wheat LJ. Histoplasmosis and coccidioidomycosis in individuals with AIDS. A clinical review. *Infect Dis Clin North Am*. 1994;8:467-482.
- 520 McKinsey DS, Spiegel RA, Hutwagner L, et al. Prospective study of histoplasmosis in patients infected with human immunodeficiency virus: incidence, risk factors, and pathophysiology. *Clin Infect Dis*. 1997;24:1195-1203.
- 521 Kauffman CA. Diagnosis of histoplasmosis in immunosuppressed patients. *Curr Opin Infect Dis*. 2008;21:421-425.
- 522 Singh VR, Smith DK, Lawrence J, Kelly PC, Thomas AR, Spitz B, Sarosi GA. Coccidioidomycosis in patients infected with human immunodeficiency virus: review of 91 cases at a single institution. *Clin Infect Dis*. 1996;23:563-568.
- 523 Masannat FY, Ampel NM. Coccidioidomycosis in patients with HIV-1 infection in the era of potent antiretroviral therapy. *Clin Infect Dis*. 2010;50:1-7.
- 524 Inungu JN, Morese AA, Gordon C. Risk factors, seasonality, and trends of cryptosporidiosis among patients infected with human immunodeficiency virus. *Am J Trop Med Hyg*. 2000;62:384-387.
- 525 Stark D, Barratt JLN, van Hal S, Marriott D, Harkness J, Ellis JT. Clinical significance of enteric protozoa in the immunosuppressed human population. *Clin Microbiol Rev*. 2009;22:634-650.
- 526 Agholi M, Hatam GR, Motazedian MH. HIV/AIDS-associated opportunistic protozoal diarrhea. *AIDS Res Hum Retroviruses*. 2013;29:35-41.
- 527 Ma P, Villanueva TG, Kaufman D, Gillooley JF. Respiratory cryptosporidiosis in the acquired immune deficiency syndrome: use of modified cold Kinyoun and hemacolor stains for rapid diagnoses. *JAMA*. 1984;252:1298-1301.
- 528 Loose JH, Sedergran DJ, Cooper HS. Identification of *Cryptosporidium* in paraffin-embedded tissue sections with the use of a monoclonal antibody. *Am J Clin Pathol*. 1989;91:206-209.
- 529 Chui DW, Owen RL. AIDS and the gut. *J Gastroenterol Hepatol*. 1994;9:291-303.
- 530 Field AS. Light microscopic and electron microscopic diagnosis of gastrointestinal opportunistic infections in HIV-positive patients. *Pathology*. 2002;34:21-35.

- 
- 531 Orenstein JM. Diagnostic pathology of microsporidiosis. *Ultrastruct Pathol*. 2003;27:141-149.
- 532 Contreas CN, Sowerby T, Berlin GW, et al. Fluorescence techniques for diagnosing intestinal microsporidiosis in stool, enteric fluid, and biopsy specimens from acquired immunodeficiency syndrome patients with chronic diarrhea. *Arch Pathol Lab Med*. 1996;120:847-853.
- 533 Lewthwaite P, Gill GV, Hart CA, Beeching NJ. Gastrointestinal parasites in the immunocompromised. *Curr Opin Infect Dis*. 2005;18:427-435.
- 534 Lowther SA, Dworkin MS, Hanson DL. Entamoeba histolytica/Entamoeba dispar infections in human immunodeficiency virus-infected patients in the United States. *Clin Infect Dis*. 2000;30:955-959.
- 535 Tsai JJ, Sun HY, Ke LY, Tsai KS, Chang SY, Hsieh SM, Hsiao CF, Yen JH, Hung CC, Chang SC. Higher seroprevalence of Entamoeba histolytica infection is associated with human immunodeficiency virus type 1 infection in Taiwan. *Am J Trop Med Hyg*. 2006;74:1016-1019.
- 536 Jacobson MA, Ching-chi Liu R, Davies D, Cohen PT. Human immunodeficiency virus disease-related neutropenia and the risk of hospitalization for bacterial infection. *Arch Intern Med*. 1997;157:1825-1831.
- 537 Daley CL. Bacterial pneumonia in HIV-infected patients. *Semin Respir Infect*. 1993;8:104-115.
- 538 Benito N, Moreno A, Miro JM, Torres A. Pulmonary infections in HIV-infected patients: an update in the 21st century. *Eur Respir J*. 2012;39:730-745.
- 539 Japiassú AM, Amâncio RT, Mesquita EC, Medeiros DM, Bernal HB, Nunes EP, Luz PM, Grinsztejn B, Bozza FA. Sepsis is a major determinant of outcome in critically ill HIV/AIDS patients. *Crit Care*. 2010;14:R152. Epub 2010 Aug 10.
- 540 Petrosillo N, Pagani L, Ippolito G; Gruppo HIV e Infezioni Ospedaliere. Nosocomial infections in HIV-positive patients: an overview. *Infection*. 2003;31(Suppl 2):28-34.
- 541 Ewert DP, Lieb L, Hayes PS, Reeves MW, Mascola L. Listeria monocytogenes infection and serotype distribution among HIV-infected persons in Los Angeles County, 1985-1992. *J Acquir Immune Defic Syndr Hum Retrovirol*. 1995;8:461-465.
- 542 Decker CF, Simon GL, DiGioia RA, Tuazon CU. Listeria monocytogenes infections in patients with AIDS: report of five cases and review. *Rev Infect Dis*. 1991;13:413-417.

- 
- 543 Yuoh G, Hove MGM, Wen J, Haque AK. Pulmonary malakoplakia in acquired immunodeficiency syndrome: an ultrastructural study of morphogenesis of Michaelis-Gutman bodies. *Mod Pathol*. 1996;9:476-483.
- 544 Rodriguez-Barradas MC, Goulet J, Brown S, Goetz M, Rimland D, Simberkoff MS, Crothers K, Justice AC. Impact of pneumococcal vaccination on the incidence of pneumonia by HIV infection status among patients enrolled in the Veterans Aging Cohort 5-Site Study. *Clin Infect Dis*. 2008;46:1093-1100.
- 545 Mayer HB, Wanke CA. Diagnostic strategies in HIV-infected patients with diarrhea. *AIDS*. 1994;8:1639-1648.
- 546 Mosepele M, Mazo D, Cohn J. Bartonella infection in immunocompromised hosts: immunology of vascular infection and vasoproliferation. *Clin Dev Immunol*. 2012;2012:612809. doi: 10.1155/2012/612809.
- 547 Agan BK, Dolan MJ. Laboratory diagnosis of Bartonella infections. *Clin Lab Med*. 2002;22:937-962.
- 548 Minnick MF, Battisti JM. Pestilence, persistence and pathogenicity: infection strategies of Bartonella. *Future Microbiol*. 2009;4:743-758.
- 549 White JA. Manifestations and management of lymphogranuloma venereum. *Curr Opin Infect Dis*. 2009;22:57-66.
- 550 Desjeux P, Alvar J. Leishmania/HIV co-infections: epidemiology in Europe. *Ann Trop Med Parasitol*. 2003;97 Suppl 1:3-15.
- 551 Van Griensven J, Carrillo E, López-Vélez R, Lynen L, Moreno J. Leishmaniasis in immunosuppressed individuals. *Clin Microbiol Infect*. 2014;20:286-299.
- 552 Rosenthal E, Marty P, delGiudice P, et al. HIV and Leishmania coinfection: a review of 91 cases with focus on atypical locations of Leishmania. *Clin Infect Dis*. 2000;31:1093-1095.
- 553 Daher EF, Fonseca PP, Gerhard ES, Leitão TM, Silva Júnior GB. Clinical and epidemiological features of visceral leishmaniasis and HIV co-infection in fifteen patients from Brazil. *J Parasitol*. 2009;95:652-655.
- 554 Alvar J, Aparicio P, Aseffa A, Den Boer M, Cañavate C, Dedet JP, Gradoni L, TerHorst R, López-Vélez R, Moreno J. The relationship between leishmaniasis and AIDS: the second 10 years. *Clin Microbiol Rev*. 2008;21:334-359.

- 
- 555 Goto H, Lauletta Lindoso JA. Cutaneous and mucocutaneous leishmaniasis. *Infect Dis Clin North Am.* 2012;26:293-307.
- 556 Hofman V, Marty P, Perrin C, et al. The histological spectrum of visceral leishmaniasis caused by *Leishmania infantum* MON-1 in acquired immunodeficiency syndrome. *Hum Pathol.* 2000;31:75-84.
- 557 Srividya G, Kulshrestha A, Singh R, Salotra P. Diagnosis of visceral leishmaniasis: developments over the last decade. *Parasitol Res.* 2012;110:1065-1078.
- 558 Abdollahi A, Morteza A, Khalilzadeh O, Rasoulinejad M. Brucellosis serology in HIV-infected patients. *Int J Infect Dis.* 2010;14:e904-6
- 559 Hajiabdolbaghi M, Rasoulinejad M, Abdollahi A, Paydary K, Valiollahi P, SeyedAlinaghi S, Parsa M, Jafari S. Brucella infection in HIV infected patients. *Acta Med Iran.* 2011;49(12):801-815.
- 560 Diazgranados CA, Saavedra-Trujillo CH, Mantilla M, Valderrama SL, Alquichire C, Franco-Paredes C. Chagasic encephalitis in HIV patients: common presentation of an evolving epidemiological and clinical association. *Lancet Infect Dis.* 2009;9:324-330.
- 561 Corti M. AIDS and Chagas' disease. *AIDS Patient Care STDS.* 2000;14:581-588.
- 562 Morejón KML, Machado AA, Martinez R. Paracoccidioidomycosis in patients infected with and not infected with human immunodeficiency virus: a case-control study. *Am J Trop Med Hyg.* 2009;80:359-366.
- 563 Nogueira LM, Santos M, Ferreira LC, Talhari C, Rodrigues RR, Talhari S. AIDS-associated paracoccidioidomycosis in a patient with a CD4+ T-cell count of 4 cells/mm<sup>3</sup>. *An Bras Dermatol.* 2011;86(4 Suppl 1):S129-S132.
- 564 Paniago AM, de Freitas AC, Aguiar ES, Aguiar JI, da Cunha RV, Castro AR, Wanke B. Paracoccidioidomycosis in patients with human immunodeficiency virus: review of 12 cases observed in an endemic region in Brazil. *J Infect.* 2005;51:248-52.
- 565 Sarangarajan R, Ranganathan A, Belmonte AH, Tchertkoff V. *Strongyloides stercoralis* infection in AIDS. *AIDS Patient Care STDS.* 1997;11:407-414.
- 566 Keiser PB, Nutman TB. *Strongyloides stercoralis* in the immunocompromised population. *Clin Microbiol Rev.* 2004;17:208-217.

- 
- 567 Ramdial PK, Hlatshwayo NH, Singh B. *Strongyloides stercoralis* mesenteric lymphadenopathy: clue to the etiopathogenesis of intestinal pseudo-obstruction in HIV-infected patients. *Ann Diagn Pathol*. 2006;10:209-214.
- 568 Secor WE. Interactions between schistosomiasis and infection with HIV-1. *Parasite Immunol*. 2006;28:597-603.
- 569 Secor WE, Sundstrom JB. Below the belt: new insights into potential complications of HIV-1/schistosome coinfections. *Curr Opin Infect Dis*. 2007;20:519-523.
- 570 Blanchard A, Montagnier L. AIDS-associated mycoplasmas. *Annu Rev Microbiol*. 1994;48:687-712.
- 571 Gatski M, Martin DH, Theall K, Amedee A, Clark RA, Dumestre J, Chhabra P, Schmidt N, Kissinger P. Mycoplasma genitalium infection among HIV-positive women: prevalence, risk factors and association with vaginal shedding. *Int J STD AIDS*. 2011;22:155-159.
- 572 Nichols L, Ocque RZ, Daly I. Zygomycosis Associated with HIV Infection and Liver Transplantation. *Patholog Res Int*. 2011 Jan 23;2011:545981.
- 573 Ustianowski AP, Sieu TP, Day JN. *Penicillium marneffei* infection in HIV. *Curr Opin Infect Dis*. 2008;21:31-36.
- 574 Wu TC, Chan JWM, Ng CK, Tsang DNC, Lee MP, Li PCK. Clinical presentations and outcomes of *Penicillium marneffei* infections: a series from 1994 to 2004. *Hong Kong Med J*. 2008;14:103-109.
- 575 Mootsikapun P, Srikulbutr S. Histoplasmosis and penicilliosis: comparison of clinical features, laboratory findings and outcome. *Int J Infect Dis*. 2006;10:66-71.
- 576 Wong KF. Marrow penicilliosis: a readily missed diagnosis. *Am J Clin Pathol*. 2010;134(2):214-218.
- 577 Ramos-e-Silva M, Vasconcelos C, Carneiro S, Cestari T. Sporotrichosis. *Clin Dermatol*. 2007;25:181-187.
- 578 Freitas DF, de Siqueira Hoagland B, do Valle AC, Fraga BB, de Barros MB, de Oliveira Schubach A, de Almeida-Paes R, et al. Sporotrichosis in HIV-infected patients: report of 21 cases of endemic sporotrichosis in Rio de Janeiro, Brazil. *Med Mycol*. 2012;50(2):170-178.
- 579 Ramos-e-Silva M, Lima CM, Schechtman RC, Trope BM, Carneiro S. Systemic mycoses in immunodepressed patients (AIDS). *Clin Dermatol*. 2012;30:616-627.



- 
- 580 Roman AD, Salvaña EM, Guzman-Peñamora MA, Roxas EA, Leyritana KT, Saniel MC. Invasive trichosporonosis in an AIDS patient: case report and review of the literature. *Int J STD AIDS*. 2014;25:70-75.
- 581 Murakawa GJ, McCalmont T, Altman J, et al. Disseminated acanthamebiasis in patients with AIDS. A report of five cases and a review of the literature. *Arch Dermatol*. 1995;131:1291-1296.
- 582 Skinner-Adams TS, McCarthy JS, Gardiner DL, Andrews KT. HIV and malaria co-infection: interactions and consequences of chemotherapy. *Trends Parasitol*. 2008;24:264-271.
- 583 Alemu A, Shiferaw Y, Addis Z, Mathewos B, Birhan W. Effect of malaria on HIV/AIDS transmission and progression. *Parasit Vectors*. 2013 Jan 17;6:18. doi: 10.1186/1756-3305-6-18.
- 584 Simmons R, Sharp C, McClure CP, Rohrbach J, Kovari H, Frangou E, Simmonds P, et al. Parvovirus 4 infection and clinical outcome in high-risk populations. *J Infect Dis*. 2012;205:1816-1820.
- 585 Glaser CA, Angulo FJ, Rooney JA. Animal-associated opportunistic infections among persons infected with the human immunodeficiency virus. *Clin Infect Dis*. 1994;18:14-24.
- 586 Antman K, Chang Y. Kaposi's sarcoma. *N Engl J Med*. 2000;342:1027-1038.
- 587 Mesri EA, Cesarman E, Boshoff C. Kaposi's sarcoma and its associated herpesvirus. *Nat Rev Cancer*. 2010;10:707-719.
- 588 Blackbourn DJ, Lennette E, Klencke B, et al. The restricted cellular host range of human herpesvirus 8. *AIDS*. 2000;14:1123-1133.
- 589 La Ferla L, Pinzone MR, Nunnari G, Martellotta F, Lleshi A, Tirelli U, De Paoli P, Berretta M, Cacopardo B. Kaposi's sarcoma in HIV-positive patients: the state of art in the HAART-era. *Eur Rev Med Pharmacol Sci*. 2013;17:2354-2365.
- 590 Levy J. Three new human herpesviruses (HHV6, 7, and 8). *Lancet*. 1997;349:558-563.

- 
- 591 Cathomas G, Stalder A, McGandy CE, Mihatsch MJ. Distribution of human herpesvirus 8 DNA in tumorous and nontumorous tissue of patients with acquired immunodeficiency syndrome with and without Kaposi's sarcoma. *Mod Pathol*. 1998;11:415-420.
- 592 Ensoli B, Sgadari C, Barillari G, Sirianni MC, Sturzl M, Monini P. Biology of Kaposi's sarcoma. *Eur J Cancer*. 2001;37:1251-1269.
- 593 Gnann Jr WW, Pellett PE, Jaffe HW. Human herpesvirus 8 and Kaposi's sarcoma in persons infected with human immunodeficiency virus. *Clin Infect Dis*. 2000;30(S1):S72-S76.
- 594 Kempf W, Adams V, Pfaltz M, et al. Human herpesvirus type 6 and cytomegalovirus in AIDS-associated Kaposi's sarcoma: no evidence for an etiological association. *Hum Pathol*. 1995;26:914-919.
- 595 Kedes DH, Ganem D, Ameli N, et al. The prevalence of serum antibody to human herpesvirus 8 (Kaposi sarcoma-associated herpesvirus) among HIV-seropositive and high risk HIV-seronegative women. *JAMA*. 1997;277:478-481.
- 596 Rabkin CS, Janz S, Lash A, et al. Monoclonal origin of multicentric Kaposi's sarcoma lesions. *N Engl J Med*. 1997;336:988-993.
- 597 Di Lorenzo G, Konstantinopoulos PA, Pantanowitz L, Di Trollo R, De Placido S, Dezube BJ. Management of AIDS-related Kaposi's sarcoma. *Lancet Oncol*. 2007;8:167-176.
- 598 Brodt H-R, Kamps BS, Helm EB, Schöfer H, Mitrou P. Kaposi's sarcoma in HIV infection: impact on opportunistic infections and survival. *AIDS*. 1998;12:1475-1481.
- 599 Nasti G, Martellotta F, Berretta M, et al. Impact of highly active antiretroviral therapy on the presenting features and outcome of patients with acquired immunodeficiency syndrome-related Kaposi sarcoma. *Cancer*. 2003;98:2440-2446.
- 600 Goedert JJ. The epidemiology of acquired immunodeficiency syndrome malignancies. *Semin Oncol*. 2000;27:390-401.
- 601 Gaidano G, Carbone A, Dalla-Favera R. Pathogenesis of AIDS-related lymphomas: molecular and histogenetic heterogeneity. *Am J Pathol*. 1998;152:623-630.

- 
- 602 Rabkin CS, Yang Q, Goedert JJ, Nguyen G, Mitsuya H, Sei S. Chemokine and chemokine receptor gene variants and risk of non-Hodgkin lymphoma in human immunodeficiency virus-1-infected individuals. *Blood*. 1999;93:1838-1842.
- 603 Biggar RJ, Chaturvedi AK, Goedert JJ, Engels EA; HIV/AIDS Cancer Match Study . AIDS-related cancer and severity of immunosuppression in persons with AIDS. *J. Natl. Cancer Inst*. 2007;99:962-972.
- 604 Knowles DM. Etiology and pathogenesis of AIDS-related non-Hodgkin lymphoma. *Hematol Oncol Clin North Am*. 2003;17:785-820.
- 605 Carbone A, Cesarman E, Spina M, Gloghini A, Schulz TF. HIV-associated lymphomas and gamma-herpesviruses. *Blood*. 2009;113:1213-1224.
- 606 Cesarman E. Gammaherpesviruses and lymphoproliferative disorders. *Annu Rev Pathol*. 2014;9:349-372.
- 607 Raphael, M, Gentilhomme O, Tulliez M, Byron PA, Diebold J. Histopathologic features of high-grade non-Hodgkin lymphomas in acquired immunodeficiency syndrome. *Arch Pathol Lab Med*. 1991;115:15-20.
- 608 Carbone A, Gloghini A, Serraino D, Spina M. HIV-associated Hodgkin lymphoma. *Curr Opin HIV AIDS*. 2009;4:3-10.
- 609 Michelow P, Wright C, Pantanowitz L. A review of the cytomorphology of Epstein-Barr virus-associated malignancies. *Acta Cytol*. 2012;56(1):1-14.
- 610 Thompson LDR, Fisher SI, Chu WS, Nelson A, Abbondanzo SL. HIV-associated Hodgkin lymphoma. *Am J Clin Pathol*. 2004;121:727-738.
- 611 Patel S, Xiao P. Primary effusion lymphoma. *Arch Pathol Lab Med*. 2013;137:1152-1154.
- 612 Carbone A, Gloghini A. KSHV/HHV8-associated lymphomas. *Br J Haematol*. 2008;140:13-24.
- 613 Chadburn A, Hyjek E, Mathew S, et al. KSHV-positive solid lymphomas represent an extra-cavitary variant of primary effusion lymphoma. *Am J Surg Pathol*. 2004;28:1401-1416.
- 614 Joshi VV, Gagnon GA, Chadwick EG, et al. The spectrum of mucosa-associated lymphoid tissue lesions in pediatric patients infected with HIV: a clinicopathologic study of six cases. *Am J Clin Pathol*. 1997;107:592-600.

- 
- 615 Wotherspoon AC, Diss TC, Pan L, Singh N, Whelan J, Isaacson PG. Low grade gastric B-cell lymphoma of mucosa associated lymphoid tissue in immunocompromised patients. *Histopathology*. 1996;28:129-134.
- 616 Perez K, Castillo J, Dezube BJ, Pantanowitz L. Human immunodeficiency virus-associated anaplastic large cell lymphoma. *Leuk Lymphoma*. 2010;51:430-438.
- 617 Beylot-Barry M, Vergier B, Masquelier B, et al. The spectrum of cutaneous lymphomas in HIV infection. *Am J Surg Pathol*. 1999;23:1208-1216.
- 618 Nava VE, Cohen P, Kalan M, Ozdemirli M. HIV-associated anaplastic large cell lymphoma: a report of three cases. *AIDS*. 2008;22:1892-1894.
- 619 Castillo JJ, Furman M, Beltrán BE, Bibas M, Bower M, Chen W, Díez-Martín JL, et al. Human immunodeficiency virus-associated plasmablastic lymphoma: Poor prognosis in the era of highly active antiretroviral therapy. *Cancer*. 2012;118:5270-5277.
- 620 Riedel DJ, Gonzalez-Cuyar LF, Zhao XF, Redfield RR, Gilliam BL. Plasmablastic lymphoma of the oral cavity: a rapidly progressive lymphoma associated with HIV infection. *Lancet Infect Dis*. 2008;8:261-267.
- 621 Kazi S, Cohen PR, Williams F, Schempp R, Reveille JD. The diffuse infiltrative lymphocytosis syndrome. Clinical and immunogenetic features in 35 patients. *AIDS*. 1996;10:385-391.
- 622 Gherardi RK, Chretien F, Delfau-Larue MH, et al. Neuropathy in diffuse infiltrative lymphocytosis syndrome: an HIV neuropathy, not a lymphoma. *Neurology*. 1998;50:1041-1044.
- 623 Basu D, Williams FM, Ahn CW, Reveille JD. Changing spectrum of the diffuse infiltrative lymphocytosis syndrome. *Arthritis Rheum*. 2006;55:466-472.
- 624 Fiorino AS, Atac B. Paraproteinemia, plasmacytoma, myeloma, and HIV infection. *Leukemia*. 1997;11:2150-2156.
- 625 Demopoulos BP, Vamvakas E, Ehrlich JE, Demopoulos R. Non-acquired immunodeficiency syndrome-defining malignancies in patients infected with human immunodeficiency virus. *Arch Pathol Lab Med*. 2003;127:589-592.
- 626 Bonnet F, Lewden C, May T, et al. Malignancy-related causes of death in human immunodeficiency virus-infected patients in the era of highly active antiretroviral therapy. *Cancer*. 2004;101:317-324.

- 
- 627 Patel P, Hanson DL, Sullivan PS, Novak RM, Moorman AC, Tong TC, Holmberg SD, Brooks JT; Adult and Adolescent Spectrum of Disease Project and HIV Outpatient Study Investigators. Incidence of types of cancer among HIV-infected persons compared with the general population in the United States, 1992-2003. *Ann Intern Med.* 2008;148:728-736.
- 628 Gallien S, Zuber B, Polivka M, Lagrange-Xelot M, Thiebault JB, Bertheau P, Gray F, Molina JM. Multifocal Epstein-Barr virus-associated smooth muscle tumor in adults with AIDS: case report and review of the literature. *Oncology.* 2008;74:167-176.
- 629 Ramdial PK, Sing Y, Deonarain J, Vaubell JJ, Naicker S, Sydney C, Hadley LG, et al. Extra-uterine myoid tumours in patients with acquired immunodeficiency syndrome: a clinicopathological reappraisal. *Histopathology.* 2011;59(6):1122-1134.
- 630 Purgina B, Rao UN, Miettinen M, Pantanowitz L. AIDS-related EBV-associated smooth muscle tumors: a review of 64 published cases. *Patholog Res Int.* 2011;2011:561548.
- 631 Pantanowitz L, Michelow P. Review of human immunodeficiency virus (HIV) and squamous lesions of the uterine cervix. *Diagn Cytopathol.* 2011;39:65-72.
- 632 Del Mistro A, Chieco Bianchi L. HPV-related neoplasias in HIV-infected individuals. *Eur J Cancer.* 2001;37:1227-1235.
- 633 Cutrell J, Bedimo R. Non-AIDS-defining cancers among HIV-infected patients. *Curr HIV/AIDS Rep.* 2013;10:207-216.
- 634 Pakkala S, Ramalingam SS. Lung cancer in HIV-positive patients. *J Thorac Oncol.* 2010;5:1864-1871.
- 635 Shebl FM, Engels EA, Goedert JJ, Chaturvedi AK. Pulmonary infections and risk of lung cancer among persons with AIDS. *J Acquir Immune Defic Syndr.* 2010;55(3):375-379.
- 636 Chapman C, Aboulafia DM, Dezube BJ, Pantanowitz L. Human immunodeficiency virus-associated adenocarcinoma of the colon: clinicopathologic findings and outcome. *Clin Colorectal Cancer.* 2009;8:215-219.
- 637 Persson EC, Shiels MS, Dawsey SM, Bhatia K, Anderson LA, Engels EA. Increased risk of stomach and esophageal malignancies in people with AIDS. *Gastroenterology.* 2012;14:943-950.
- 638 Hentrich MU, Brack NG, Schmid P, Schuster T, Clemm C, Hartenstein RC. Testicular germ cell tumors in patients with human immunodeficiency virus infection. *Cancer.* 1996;77:2109-2116.

- 
- 639 Kesselring A, Gras L, Smit C, van Twillert G, Verbon A, de Wolf F, Reiss P, Wit F. Immunodeficiency as a risk factor for non-AIDS-defining malignancies in HIV-1-infected patients receiving combination antiretroviral therapy. *Clin Infect Dis*. 2011;52(12):1458-1465.
- 640 Huang L, Crothers K. HIV-associated opportunistic pneumonias. *Respirology*. 2009;14:474-485..
- 641 Patel N, Talwar A, Reichert VC, Brady T, Jain M, Kaplan MH. Tobacco and HIV. *Clin Occup Environ Med*. 2006;5:193-207, xi.
- 642 Rosen MJ. Pulmonary complications of HIV infection. *Respirology*. 2008;13:181-190.
- 643 Miguez-Burbano MJ, Ashkin D, et al. Increased risk of *Pneumocystis carinii* and community-acquired pneumonia with tobacco use in HIV disease. *Int J Infect Dis*. 2005;9:208-217.
- 644 Saldana MJ, Mones JM. Pulmonary pathology in AIDS: atypical *Pneumocystis carinii* infection and lymphoid interstitial pneumonitis. *Thorax*. 1994;49(Suppl):S46-S55.
- 645 Benfield TL, Helweg-Larsen J, Bang D, Junge J, Lundgren JD. Prognostic markers of short-term mortality in AIDS-associated *Pneumocystis carinii* pneumonia. *Chest*. 2001;119:844-851.
- 646 Beck JM. Pleural disease in patients with acquired immune deficiency syndrome. *Clin Chest Med*. 1998;19:341-349.
- 647 Miller RF, Huang L, Walzer PD. *Pneumocystis* pneumonia associated with human immunodeficiency virus. *Clin Chest Med*. 2013;34:229-241.
- 648 Allen CM, Al-Jahdali HH, Irion KL, Al Ghanem S, Gouda A, Khan AN. Imaging lung manifestations of HIV/AIDS. *Ann Thorac Med*. 2010;5(4):201-216.
- 649 Kanne JP, Yandow DR, Meyer CA. *Pneumocystis jiroveci* pneumonia: high-resolution CT findings in patients with and without HIV infection. *AJR Am J Roentgenol*. 2012;198:W555-61.
- 650 Marks MJ, Haney PJ, McDermott MP, White CS, Vennos AD. Thoracic disease in children with AIDS. *Radiographics*. 1996;16:1349-1362.
- 651 Read CA, Cerrone F, Busseniers AE, Waldhorn RE, Lavelle JP, Pierce PF. Differential lobe lavage for diagnosis of acute *Pneumocystis carinii* pneumonia in patients receiving prophylactic aerosolized pentamidine therapy. *Chest*. 1993;103:1520-1523.

- 
- 652 Elvin K. Laboratory diagnosis and occurrence of *Pneumocystis carinii*. *Scand J Infect Dis Suppl.* 1994;94:1-34.
- 653 Hartel PH, Shilo K, Klassen-Fischer M, Neafie RC, Ozbudak IH, Galvin JR, Franks TJ. Granulomatous reaction to *pneumocystis jiroveci*: clinicopathologic review of 20 cases. *Am J Surg Pathol.* 2010;34:730-734.
- 654 Moran CA, Angritt P. Granulomatous *Pneumocystis carinii* in AIDS patients. *Mil Med.* 1993;158:633-635.
- 655 Travis WD, Pittaluga S, Lipschik GY, et al. Atypical pathologic manifestations of *Pneumocystis carinii* pneumonia in the acquired immunodeficiency syndrome. *Am J Surg Pathol.* 1990;14:615-625.
- 656 Franquet T, Gimenez A, Hidalgo A. Imaging of opportunistic fungal infections in immunocompromised patient. *Eur J Radiol.* 2004;51:130-138.
- 657 Ferre C, Baguena F, Podzamczar D, Sanchez C, Viladrich PF, Garau J, Gudiol F. Lung cavitation associated with *Pneumocystis carinii* infection in the acquired immunodeficiency syndrome: a report of six cases and review of the literature. *Eur Respir J.* 1994;7:134-139.
- 658 Cheng WL, Ko WC, Lee NY, Chang CM, Lee CC, Li CW. Pneumomediastinum in patients with AIDS: a case report and literature review. *Int J Infect Dis.* 2014;22:31-34.
- 659 Horowitz ML, Schiff M, Samuels J, Russo R, Schnader J. *Pneumocystis carinii* pleural effusion. Pathogenesis and pleural fluid analysis. *Am Rev Respir Dis.* 1993;148:232-234.
- 660 Gal AA, Klatt EC, Koss MK, Strigle SM, Boylen CT. The effectiveness of bronchoscopy in the diagnosis of *Pneumocystis carinii* and cytomegalovirus pulmonary infections in acquired immunodeficiency syndrome. *Arch Pathol Lab Med.* 1987;111:238-241.
- 661 Mann M, Schelhamer JH, Masur H, et al. Lack of clinical utility of bronchoalveolar lavage cultures for cytomegalovirus in HIV infection. *Am J Respir Crit Care Med.* 1997;155:1723-1728.
- 662 Salomon N, Gomez T, Perlman DC, Laya L, Eber C, Mildvan D. Clinical features and outcomes of HIV-related cytomegalovirus pneumonia. *AIDS.* 1997;11:319-324.
- 663 Lacomis JM, Costello P, Vilchez R, Kusne S. The radiology of pulmonary cryptococcosis in a tertiary medical center. *J Thorac Imaging.* 2001;16:139-148.

- 
- 664 Kocjan G, Miller R. The cytology of HIV-induced immunosuppression. Changing pattern of disease in the era of highly active antiretroviral therapy. *Cytopathology*. 2001;12:281-296.
- 665 O'Connell ML, Birkenkamp KE, Kleiner DE, Folio LR, Holland SM, Olivier KN. Lung manifestations in an autopsy-based series of pulmonary or disseminated nontuberculous mycobacterial disease. *Chest*. 2012;141:1203-1209.
- 666 Campo RE, Campo CE. *Mycobacterium kansasii* disease in patients infected with human immunodeficiency virus. *Clin Infect Dis*. 1999;24:1233-1238.
- 667 Nash G, Irvine R, Kerschmann RL, Herndier B. Pulmonary aspergillosis in acquired immunodeficiency syndrome: autopsy study of an emerging pulmonary infection. *Hum Pathol*. 1997;28:1268-1275.
- 668 Mylonakis E, Barlam TF, Flanigan T, Rich JD. Pulmonary aspergillosis and invasive disease in AIDS: review of 342 cases. *Chest*. 1998;114:251-262.
- 669 Guinea J, Jensen J, Peláez T, Gijón P, Alonso R, Rivera M, Muñoz P, Bouza E. Value of a single galactomannan determination (Platelia) for the diagnosis of invasive aspergillosis in non-hematological patients with clinical isolation of *Aspergillus* spp. *Med Mycol*. 2008;46:575-579.
- 670 Uttamchandani RB, Daikos GL, Reyes RR, Fischl MA, Dickinson GM, Yamaguchi E, Kramer MR. Nocardiosis in 30 patients with advanced human immunodeficiency virus infection: clinical features and outcome. *Clin Infect Dis*. 1994;18:348-353.
- 671 Menendez R, Cordero PJ, Santos M, Gobernado M, Marco V. Pulmonary infection with *Nocardia* species: a report of 10 cases and review. *Eur Respir J*. 1997;10:1542-1546.
- 672 Pappas PG, Pottage JC, Powderly WG, et al. Blastomycosis in patients with the acquired immunodeficiency syndrome. *Ann Intern Med*. 1992;116:847-853.
- 673 Shen YZ, Qi TK, Ma JX, Jiang XY, Wang JR, Xu QN, Huang Q, et al. Invasive fungal infections among inpatients with acquired immune deficiency syndrome at a Chinese university hospital. *Mycoses*. 2007;50:475-480.
- 674 Hirschtick RE, Glassroth J, Jordan MC, et al. Bacterial pneumonia in persons infected with the human immunodeficiency virus. *N Engl J Med*. 1995;333:845-851.
- 675 Feldman C, Anderson R. HIV-associated bacterial pneumonia. *Clin Chest Med*. 2013;34:205-216.
- 676 Miller RF, Foley NM, Kessel D, Jeffrey AA. Community acquired lobar pneumonia in patients with HIV infection and AIDS. *Thorax*. 1994;49:367-368.



- 
- 677 Verghese A, Al-Samman M, Nabhan D, Naylor AD, Rivera M. Bacterial bronchitis and bronchiectasis in human immunodeficiency virus infection. *Arch Intern Med*. 1994;154:2086-2091.
- 678 Sandkovsky U, Sandkovsky G, Suh J, Smith B, Sharp V, Polsky B. Legionella pneumonia and HIV: case reports and review of the literature. *AIDS Patient Care STDS*. 2008;22:473-481.
- 679 von Bargen K, Haas A. Molecular and infection biology of the horse pathogen *Rhodococcus equi*. *FEMS Microbiol Rev*. 2009;33:870-891.
- 680 Topino S, Galati V, Grilli E, Petrosillo N. *Rhodococcus equi* infection in HIV-infected individuals: case reports and review of the literature. *AIDS Patient Care STDS*. 2010;24:211-222.
- 681 Shankar EM, Kumarasamy N, Balakrishnan P, Saravanan S, Solomon S, Vengatesan A, Murugavel KG, Rao UA. Detection of pulmonary *Mycoplasma pneumoniae* infections in HIV-infected subjects using culture and serology. *Int J Infect Dis*. 2007;11:232-238.
- 682 Connolly MG Jr, Baughman RP, Dohn MN, Linnemann CC Jr. Recovery of viruses other than cytomegalovirus from bronchoalveolar lavage fluid. *Chest*. 1994;105:1775-1781.
- 683 Aryee AM, Solomon AW, Taylor MN, Kidd IM, Shaw PJ, Miller RF. Clinical, radiological and laboratory features of human metapneumovirus lower respiratory tract infection in HIV-positive patients: a case series. *AIDS*. 2013;27:2317-2319.
- 684 Knox KK, Carrigan DR. Disseminated active HHV-6 infections in patients with AIDS. *Lancet*. 1994;343:577-578.
- 685 Gasparetto TD, Marchiori E, Lourenço S, Zanetti G, Vianna AD, Santos AA, Nobre LF. Pulmonary involvement in Kaposi sarcoma: correlation between imaging and pathology. *Orphanet J Rare Dis*. 2009 Jul 14;4:18. doi: 10.1186/1750-1172-4-18.
- 686 Lambert AA, Merlo CA, Kirk GD. Human immunodeficiency virus-associated lung malignancies. *Clin Chest Med*. 2013;34:255-272.
- 687 Moran CA, Suster S, Pavlova Z, Mullick FG, Koss MN. The spectrum of pathological changes in the lung in children with the acquired immunodeficiency syndrome. *Hum Pathol*. 1994;25:877-882.
- 688 Pitcher RD, Beningfield SJ, Zar HJ. Chest radiographic features of lymphocytic interstitial pneumonitis in HIV-infected children. *Clin Radiol*. 2010;65:150-154.

- 
- 689 Swigris JJ, Berry GJ, Raffin TA, Kuschner WG. Lymphoid interstitial pneumonia: a narrative review. *Chest*. 2002;122:2150-2164.
- 690 Travis WD, Fox CH, Devaney KO, et al. Lymphoid pneumonitis in 50 adult patients infected with the human immunodeficiency virus: lymphocytic interstitial pneumonitis versus nonspecific interstitial pneumonitis. *Hum Pathol*. 1992;23:529-541.
- 691 Joshi VV, Kauffman S, Oleske JM, Fikrig S, Denny T, Gadol C, Lee E. Polyclonal polymorphic B-cell lymphoproliferative disorder with prominent pulmonary involvement in children with acquired immunodeficiency syndrome. *Cancer*. 1987;59:1455-1462.
- 692 Poletti V, Romagnoli M, Piciucchi S, Chilosi M. Current status of idiopathic nonspecific interstitial pneumonia. *Semin Respir Crit Care Med*. 2012;33(5):440-449.
- 693 Nan DN, Fernández-Ayala M, Iglesias L, García-Palomo D, Parra JA, Fariñas MC. Talc granulomatosis. A differential diagnosis of interstitial lung disease in HIV patients. *Chest*. 2000;118:258-260.
- 694 Zar HJ. Chronic lung disease in human immunodeficiency virus (HIV) infected children. *Pediatr Pulmonol*. 2008;43:1-10.
- 695 Degano B, Guillaume M, Savale L, Montani D, Jaïs X, Yaici A, Le Pavec J, Humbert M, Simonneau G, Sitbon O. HIV-associated pulmonary arterial hypertension: survival and prognostic factors in the modern therapeutic era. *AIDS*. 2010;24:67-75.
- 696 Araújo I, Enjuanes-Grau C, Lopez-Guarch CJ, Narankiewicz D, Ruiz-Cano MJ, Velazquez-Martin T, Delgado J, Escribano P. Pulmonary arterial hypertension related to human immunodeficiency virus infection: A case series. *World J Cardiol*. 2014;6:495-501.
- 697 Petrache I, Diab K, Knox KS, Twigg HL 3rd, Stephens RS, Flores S, Tudor RM. HIV associated pulmonary emphysema: a review of the literature and inquiry into its mechanism. *Thorax*. 2008;63:463-469.
- 698 Morris A, George MP, Crothers K, Huang L, Lucht L, Kessinger C, Kleerup EC; Lung HIV Study. HIV and chronic obstructive pulmonary disease: is it worse and why? *Proc Am Thorac Soc*. 2011;8(3):320-325.
- 699 Afessa B. Pleural effusions and pneumothoraces in AIDS. *Curr Opin Pulm Med*. 2001;7:202-209.

- 
- 700 Miller RF, Howling SJ, Reid AJ, Shaw PJ. Pleural effusions in patients with AIDS. *Sex Transm Infect.* 2000;76:122-125.
- 701 Crothers K, Butt AA, Gibert CL, Rodriguez-Barradas MC, Crystal S, Justice AC. Increased COPD among HIV-positive compared to HIV-negative veterans. *Chest.* 2006;130:1326-1333.
- 702 Schlossbauer T, Schmidt GP, Bogner JR, Sing A, Reiser MF, Becker-Gaab C. Pulmonary radiological characteristics in patients with HIV infection at the time of highly active antiretroviral therapy (HAART). *Eur J Med Res.* 2007;12:341-346.
- 703 Palestro CJ, Goldsmith SJ. The role of gallium and labeled leukocyte scintigraphy in the AIDS patient. *Q J Nucl Med.* 1995;39:221-230.
- 704 Wang Y, Doucette S, Qian Q, Kirby JE. Yield of primary and repeat induced sputum testing for *Pneumocystis jirovecii* in human immunodeficiency virus-positive and -negative patients. *Arch Pathol Lab Med.* 2007;131:1582-1584.
- 705 Narayanswami G, Salzman SH. Bronchoscopy in the human immunodeficiency virus-infected patient. *Semin Respir Infect.* 2003;18:80-86.
- 706 Djamin RS, Drent M, Schreurs AJ, Groen EA, Wagenaar SS. Diagnosis of *Pneumocystis carinii* pneumonia in HIV-positive patients. *Acta Cytol.* 1998;42:933-938.
- 707 Gracia JD, Miravittlles M, Mayordomo C, et al. Empiric treatments impair the diagnostic yield of BAL in HIV-positive patients. *Chest.* 1997;111:1180-1186.
- 708 Liu R, Huang L, Li J, Zhou X, Zhang H, Zhang T, et al. HIV Infection in gastric epithelial cells. *J Infect Dis.* 2013;208:1221-1230.
- 709 Smith PD. Infectious diarrheas in patients with AIDS. *Gastroenterol Clin NA.* 1993;22(3):535-548.
- 710 Monkemuller KE, Call SA, Lazenby AJ, Wilcox CM. Declining prevalence of opportunistic gastrointestinal disease in the era of combination antiretroviral therapy. *Am J Gastroenterol.* 2000;95:457-462.
- 711 Vyas N, Pathan N, Aziz A. Enteric pathogens in HIV-positive patients with diarrhoea and their correlation with CD4+ T-lymphocyte counts. *Trop Parasitol.* 2012;2:29-34.
- 712 Bini EJ, Weinshel EH, Gamagaris Z. Comparison of duodenal with jejunal biopsy and aspirate in chronic human immunodeficiency virus-related diarrhea. *Am J Gastroenterol.* 1998;93:1837-180.

- 
- 713 Leigh JE, Steele C, Wormley FL Jr, Luo W, Clark RA, Gallaher W, Fidel PL Jr. T<sub>H</sub>1/T<sub>H</sub>2 cytokine expression in saliva of HIV-positive and HIV-negative individuals: a pilot study in HIV-positive individuals with oropharyngeal candidiasis. *J Acquir Immune Defic Syndr Hum Retrovirol*. 1998;19:373-380.
- 714 Reichart PA, Samaranayake LP, Phillipsen HP. Pathology and clinical correlates in oral candidiasis and its variants: a review. *Oral Dis*. 2000;6:85-91.
- 715 Clayton F, Clayton CH. Gastrointestinal pathology in HIV-infected patients. *Gastroenterol Clin NA*. 1997;26:191-240.
- 716 Jacob LS, Flaitz CM, Nichols CM, Hicks MJ. Role of dentinal carious lesions in the pathogenesis of oral candidiasis in HIV infection. *J Am Dental Assoc*. 1998;129:187-194.
- 717 Lamps LW, Molina CP, West AB, Haggitt RC, Scott MA. The pathologic spectrum of gastrointestinal and hepatic histoplasmosis. *Am J Clin Pathol*. 2000;113:64-72.
- 718 Bhaijee F, Subramony C, Tang SJ, Pepper DJ. Human immunodeficiency virus-associated gastrointestinal disease: common endoscopic biopsy diagnoses. *Patholog Res Int*. 2011;2011:247923.
- 719 Carr A, Marriott D, Field A, Vasak E, Cooper DA. Treatment of HIV-1-associated microsporidiosis and cryptosporidiosis with combination antiretroviral therapy. *Lancet*. 1998;351:256-261.
- 720 Vakil NB, Schwartz SM, Buggy BP, et al. Biliary cryptosporidiosis in HIV-infected people after the waterborne outbreak of cryptosporidiosis in Milwaukee. *N Engl J Med*. 1996;334:19-23.
- 721 Clavel A, Arnal AC, Sanchez EC, et al. Respiratory cryptosporidiosis: case series and review of the literature. *Infection*. 1996;24:341-346.
- 722 Michiels JF, Hofman P, Bernard E, et al. Intestinal and extraintestinal *Isospora belli* infection in an AIDS patient. *Pathol Res Pract*. 1994;190:1089-1093.
- 723 Gassama A, Sow PS, Fall F, et al. Ordinary and opportunistic enteropathogens associated with diarrhea in Senegalese adults in relation to human immunodeficiency virus serostatus. *Int J Infect Dis*. 2001;5:192-198.
- 724 Slavik T. Human immunodeficiency virus-related gastrointestinal pathology: a southern Africa perspective with review of the literature (part 1: infections). *Arch Pathol Lab Med*. 2012;136:305-315.

- 
- 725 Velásquez JN, Di Risio C, Etchart DB, Chertcoff AV, Mendez N, Cabrera MG, Labbé JH, Carnevalle S. Systemic sarcocystis in a patient with acquired immune deficiency syndrome. *Hum Pathol*. 2008;39:1263-1267.
- 726 Angulo FJ, Swerdlow DL. Bacterial enteric infections in persons infected with human immunodeficiency virus. *Clin Infect Dis*. 1995;21(Suppl 1):S84-93.
- 727 Romanelli F, Smith KM, Murphy BS. Does HIV infection alter the incidence or pathology of *Helicobacter pylori* infection? *AIDS Patient Care STDS*. 2007;21:908-919.
- 728 Olmos M, Araya V, Pschorz E, Quesada EC, Concetti H, Perez H, Cahn P. Coinfection: *Helicobacter pylori*/human immunodeficiency virus. *Dig Dis Sci*. 2004;49:1836-1839.
- 729 Haines CF, Moore RD, Bartlett JG, Sears CL, Cosgrove SE, Carroll K, Gebo KA. *Clostridium difficile* in a HIV-infected cohort: incidence, risk factors, and clinical outcomes. *AIDS*. 2013;27:2799-2807.
- 730 Collini PJ, Bauer M, Kuijper E, Dockrell DH. *Clostridium difficile* infection in HIV-seropositive individuals and transplant recipients. *J Infect*. 2012;64:131-147.
- 731 Orenstein JM, Kotler DP. Diarrheogenic bacterial enteritis in acquired immune deficiency syndrome: a light and electron microscopy study of 52 cases. *Hum Pathol*. 1995;26:481-492.
- 732 Aragon TJ, Vugia DJ, Shallow S, Samuel MC, Reingold A, Angulo FJ, Bradford WZ. Case-control study of shigellosis in San Francisco: the role of sexual transmission and HIV infection. *Clin Infect Dis*. 2007;44:327-334.
- 733 Gray JR, Rabeneck L. Atypical mycobacterial infection of the gastrointestinal tract in AIDS patients. *Am J Gastroenterol*. 1989;84:1521-1524.
- 734 Pankhurst CL, Luo N, Kelly P, Drobniewski F, Ngwenya B, Farthing MJG. Intestinal mycobacteria in African AIDS patients. *Lancet*. 1995;345:585.
- 735 Dray X, Vahedi K, Delcey V, Lavergne-Slove A, Raskine L, Bergmann JF, Marteau P. *Mycobacterium avium* duodenal infection mimicking Whipple's disease in a patient with AIDS. *Endoscopy*. 2007;39(Suppl 1):E296-297.
- 736 Yuhan R, Orsay C, DelPino A, Pearl R, Pulvirenti J, Kay S, Abcarian H. Anorectal disease in HIV-infected patients. *Dis Colon Rectum*. 1998;41:1367-1370.

- 
- 737 Huppmann AR, Orenstein JM. Opportunistic disorders of the gastrointestinal tract in the age of highly active antiretroviral therapy. *Hum Pathol*. 2010;41:1777-1787.
- 738 Grohmann GS, Glass RI, Pereira HG, et al. Enteric viruses and diarrhea in HIV-infected patients. *N Engl J Med*. 1993;329:14-20.
- 739 Yan Z, Nguyen S, Poles M, Melamed J, Scholes JV. Adenovirus colitis in human immunodeficiency virus infection. *Am J Surg Pathol*. 1998;22:1101-1106.
- 740 Liste MB, Natera I, Suarez JA, Pujol FH, Liprandi F, Ludert JE. Enteric virus infections and diarrhea in healthy and human immunodeficiency virus-infected children. *Clin Microbiol*. 2000;38:2873-2877.
- 741 Ena J, Simón-Aylón A, Pasquau F. Intestinal spirochetosis as a cause of chronic diarrhoea in patients with HIV infection: case report and review of the literature. *Int J STD AIDS*. 2009;20:803-805.
- 742 Anthony NE, Blackwell J, Ahrens W, Lovell R, Scobey MW. Intestinal spirochetosis: an enigmatic disease. *Dig Dis Sci*. 2013;58:202-208.
- 743 Zhou Y, Shetty J, Pins MR. Small-intestine pneumocystis jiroveci pseudotumor as an acquired immunodeficiency syndrome-presenting illness: report of a case and review of the literature. *Arch Pathol Lab Med*. 2012;136:1001-1003.
- 744 Ioachim HL, Antonescu C, Giancotti F, Dorsett B, Weinstein MA. EBV-associated anorectal lymphomas in patients with acquired immunodeficiency syndrome. *Am J Surg Pathol*. 1997;21:997-1006.
- 745 Heise W. GI-lymphomas in immunosuppressed patients (organ transplantation; HIV). *Best Pract Res Clin Gastroenterol*. 2010;24:57-69.
- 746 Slavik T. Human immunodeficiency virus-related gastrointestinal pathology: a southern Africa perspective with review of the literature (part 2: neoplasms and noninfectious disorders). *Arch Pathol Lab Med*. 2012;136:316-323.
- 747 Ramirez-Amador V, Esquivel-Pedraza L, Sierra-Madero J, Anaya-Saavedra G, Gonzalez-Ramirez I, Ponce-de-Leon S. The changing clinical spectrum of human immunodeficiency virus (HIV)-related oral lesions in 1000 consecutive patients: a 12-year study in a referral center in Mexico. *Medicine*. 2003;82:39-50.
- 748 Holmstrup P, Westergaard J. Periodontal diseases in HIV-infected patients. *J Clin Periodontol*. 1994;21:270-280.

- 
- 749 Feller L, Lemmer J. Necrotizing periodontal diseases in HIV-seropositive subjects: pathogenic mechanisms. *J Int Acad Periodontol*. 2008;10:10-15.
- 750 Miziara ID, Araujo Filho BC, Weber R. AIDS and Recurrent Aphthous Stomatitis. *Rev Bras Otorrinolaringol*. 2005;71:517-520. 15.
- 751 Kerr AR, Ship JA. Management strategies for HIV-associated aphthous stomatitis. *Am J Clin Dermatol*. 2003;4:669-680.
- 752 Shetty K. Current role of thalidomide in HIV-positive patients with recurrent aphthous ulcerations. *Gen Dent*. 2007;55:537-542.
- 753 Schiodt M. Less common oral lesions associated with HIV infection: prevalence and classification. *Oral Dis*. 1997;3(Suppl 1):S208-S213.
- 754 Pantanowitz L, Khammissa RA, Lemmer J, Feller L. Oral HIV-associated Kaposi sarcoma. *J Oral Pathol Med*. 2013;42:201-207.
- 755 Fatahzadeh M, Schwartz RA. Oral Kaposi's sarcoma: a review and update. *Int J Dermatol*. 2013;52:666-672.
- 756 Butt FM, Chindia ML, Rana F. Oral squamous cell carcinoma in human immunodeficiency virus positive patients: clinicopathological audit. *J Laryngol Otol*. 2012;126:276-278.
- 757 Tirantos D, Porter SR, Scully C, Teo CG. Oral hairy leukoplakia,: clinicopathologic features, pathogenesis, diagnosis, and clinical significance. *Clin Infect Dis*. 1997;25:1392-1396.
- 758 Brehmer-Andersson E, Lucht E, Lindskog S, Ekman M, Biberfeld P. Oral hairy leukoplakia: pathogenetic aspects and significance of the lesion. *Acta Derm Venereol*. 1994;74:81-89.
- 759 Braz-Silva PH, Santos RT, Schussel JL, Gallottini M. Oral hairy leukoplakia diagnosis by Epstein-Barr virus in situ hybridization in liquid-based cytology. *Cytopathology*. 2014;25:21-26.
- 760 Thomas JA, Cotter F, Hanby AM, Long LQ, Morgan PR, Bramble B, Bailey BM. Epstein-Barr virus-related oral T-cell lymphoma associated with human immunodeficiency virus immunosuppression. *Blood*. 1993;81:3350-3356.
- 761 Dias EP, Israel MS, Silva Jr A, Maciel VA, Gagliardi JP, Oliveira RH. Prevalence of oral hairy leukoplakia in 120 pediatric patients infected with HIV-1. *Braz Oral Res*. 2006;20:103-107.

- 
- 762 Hagensee ME, Cameron JE, Leigh JE, Clark RA. Human papillomavirus infection and disease in HIV-infected individuals. *Am J Med Sci*. 2004;328:57-63.
- 763 Phelan JA. Oral manifestations of human immunodeficiency virus infection. *Med Clinics NA*. 1997;81:511-531.
- 764 Lopez deBlanc S, Sambuelli R, Femopase F, et al. Bacillary angiomatosis affecting the oral cavity. Report of two cases and review. *J Oral Pathol Med*. 2000;29:91-96.
- 765 Chidzonga MM, Mahomva L. Noma (cancrum oris) in human immunodeficiency virus infection and acquired immunodeficiency syndrome (HIV and AIDS): clinical experience in Zimbabwe. *J Oral Maxillofac Surg*. 2008;66:475-485.
- 766 Casariego Z, Pombo T, Perez H, Patterson P. [Eruptive cheilitis: a new adverse effect in reactive HIV-positive patients subjected to high activity antiretroviral therapy (HAART). Presentation of six clinical cases.] *Med Oral*. 2001;6:19-30.
- 767 De Faria PR, Vargas PA, Saldiva PHN, Böhm GM, Mauad T, de Almeida OP. Tongue disease in advanced AIDS. *Oral Diseases*. 2005;11:72-80.
- 768 Diz Dios P, Fernandez Feijoo J, Vazquez Garcia E. Tooth extraction in HIV sero-positive patients. *Int Dent J*. 1999;49:317-321.
- 769 Bower M, Martin F. Anal intraepithelial neoplasia in HIV positive people. *Sex Trasm Infect*. 2001;77:327-335.
- 770 Kreuter A, Wieland U. Human papillomavirus-associated diseases in HIV-infected men who have sex with men. *Curr Opin Infect Dis*. 2009;22:109-114.
- 771 Kreuter A, Potthoff A, Brockmeyer NH, Gambichler T, Swoboda J, Stücker M, Schmitt M, et al. Anal carcinoma in human immunodeficiency virus-positive men: results of a prospective study from Germany. *Br J Dermatol*. 2010;162:1269-1277.
- 772 Gaisa M, Sigel K, Hand J, Goldstone S. High rates of anal dysplasia in HIV-infected men who have sex with men, women, and heterosexual men. *AIDS*. 2014;28(2):215-22
- 773 Machalek DA, Poynten M, Jin F, Fairley CK, Farnsworth A, Garland SM, Hillman RJ, et al. Anal human papillomavirus infection and associated neoplastic lesions in men who have sex with men: a systematic review and meta-analysis. *Lancet Oncol*. 2012;13:487-500.
- 774 Sirera G, Videla S, Pinol M, et al. High prevalence of human papillomavirus infection in the anus, penis and mouth in HIV-positive men. *AIDS*. 2006;20:1201-1204.



- 
- 775 Salit IE, Tinmouth J, Chong S, Raboud J, Diong C, Su D, Sano M, et al. Screening for HIV-associated anal cancer: correlation of HPV genotypes, p16, and E6 transcripts with anal pathology. *Cancer Epidemiol Biomarkers Prev*. 2009;18:1986-1992.
- 776 Nathan M, Singh N, Garrett N, Hickey N, Prevost T, Sheaff M. Performance of anal cytology in a clinical setting when measured against histology and high-resolution anoscopy findings. *AIDS*. 2010;24:373-379.
- 777 Swedish KA, Lee EQ, Goldstone SE. The changing picture of high-grade anal intraepithelial neoplasia in men who have sex with men: the effects of 10 years of experience performing high-resolution anoscopy. *Dis Colon Rectum*. 2011;54:1003-1007.
- 778 Tong WW, Jin F, McHugh LC, Maher T, Sinclair B, Grulich AE, Hillman RJ, Carr A. Progression to and spontaneous regression of high-grade anal squamous intraepithelial lesions in HIV-infected and uninfected men. *AIDS*. 2013;27:2233-2243.
- 779 Abramowitz L, Benabderrahmane D, Baron G, Walker F, Yeni P, Duval X. Systematic Evaluation and Description of Anal Pathology in HIV-Infected Patients During the HAART Era. *Dis Colon Rectum*. 2009;53:1130-1136.
- 780 Holly EA, Ralston ML, Darragh TM, Greenblatt RM, Jay N, Palefsky JM. Prevalence and risk factors for anal squamous intraepithelial lesions in women. *J Natl Cancer Inst*. 2001;93:843-849.
- 781 Cranston RD, Hart SD, Gornbein JA, Hirschowitz SL, Cortina G, Moe AA. The prevalence, and predictive value, of abnormal anal cytology to diagnose anal dysplasia in a population of HIV-positive men who have sex with men. *Int J STD AIDS*. 2007;18:77-80.
- 782 Rodgers S, Leslie KS. Skin infections in HIV-infected individuals in the era of HAART. *Curr Opin Infect Dis*. 2011;24:124-129.
- 783 Kotler DP. HIV infection and the gastrointestinal tract. *AIDS*. 2005;19:107-117.
- 784 Batman PA, Kapembwa MS, Belmonte L, Tudor G, Kotler DP, Potten CS, Booth C, Cahn P, Griffin GE. HIV enteropathy: HAART reduces HIV-induced stem cell hyperproliferation and crypt hypertrophy to normal in jejunal mucosa. *J Clin Pathol*. 2014;67:14-18.

- 
- 785 Mangili A, Murman DH, Zampini AM, Wanke CA. Nutrition and HIV infection: review of weight loss and wasting in the era of highly active antiretroviral therapy from the nutrition for healthy living cohort. *Clin Infect Dis*. 2006;42:836-842.
- 786 Dworkin MS, Williamson JM; Adult/Adolescent Spectrum of HIV Disease Project. AIDS wasting syndrome: trends, influence on opportunistic infections, and survival. *J Acquir Immune Defic Syndr*. 2003;33:267-273.
- 787 Shlay JC, Bartsch G, Penq G, Wang J, Grunfeld C, Gibert CL, Visnegarwala F, et al. Long-term body composition and metabolic changes in antiretroviral naïve persons randomized to protease inhibitor-, nonnucleoside reverse transcriptase inhibitor-, or protease inhibitor plus nonnucleoside reverse transcriptase inhibitor-based strategy. *J Acquir Immune Defic Syndr*. 2007;44:506-517.
- 788 Mallewa JE, Wilkins E, Vilar J, Mallewa M, Doran D, Back D, Pirmohamed M. HIV-associated lipodystrophy: a review of underlying mechanisms and therapeutic options. *J Antimicrob Chemother*. 2008;62:648-660.
- 789 Galescu O, Bhangoo A, Ten S. Insulin resistance, lipodystrophy and cardiometabolic syndrome in HIV/AIDS. *Rev Endocr Metab Disord*. 2013;14:133-140.
- 790 Sweeney LL, Brennan AM, Mantzoros CS. The role of adipokines in relation to HIV lipodystrophy. *AIDS*. 2007;21:895-904..
- 791 Guaraldi G, Orlando G, Squillace N, Roverato A, De Fazio D, Vandelli M, Nardini G, Beghetto B, De Paola M, Esposito R, Palella F. Prevalence of and risk factors for pubic lipoma development in HIV-infected persons. *J. Acquir. Immune Defic. Syndr*. 2007;45:72-76.
- 792 Freitas P, Santos AC, Carvalho D, Pereira J, Marques R, Martinez E, Sarmiento A, Medina JL. Fat mass ratio: an objective tool to define lipodystrophy in HIV-infected patients under antiretroviral therapy. *J Clin Densitom*. 2010;13:197-203.
- 793 Echevarria KL, Hardin TC, Smith JA. Hyperlipidemia associated with protease inhibitor therapy. *Ann Pharmacother*. 1999;33:859-863.
- 794 Kingsley L, Smit E, Riddler S, et al. Prevalence of lipodystrophy and metabolic abnormalities in the Multicenter AIDS Cohort Study (MACS). Program and Abstracts of the 8<sup>th</sup> Conference on Retroviruses and Opportunistic Infections; February 4-8, 2001; Chicago, Illinois. Abstract 538.
- 795 Davison SP, Timpone J Jr, Hannan CM. Surgical algorithm for management of HIV lipodystrophy. *Plast Reconstr Surg*. 2007;120:1843-1858.

- 
- 796 Grunfeld C, Dritselis A, Kirkpatrick P. Tesamorelin. *Nat Rev Drug Discov*. 2011;10:95-96.
- 797 Wood BJ, Kuman PN, Cooper C, Silverman PM, Zeman RK. AIDS-associated intussusception in young adults. *J Clin Gastroenterol*. 1995;21:158-162.
- 798 Ramdial PK, Sing Y, Hadley GP, Chotey NA, Mahlakwane MS, Singh B. Paediatric intussusception caused by acquired immunodeficiency syndrome-associated Kaposi sarcoma. *Pediatr Surg Int*. 2010;26:783-787.
- 799 Subsai K, Kanoksri S, Siwaporn C, Helen L, Kanokporn O, Wantana P. Neurological complications in AIDS patients receiving HAART: a 2-year retrospective study. *Eur J Neurol*. 2006;13:233-239.
- 800 Thurnher MM, Donovan Post MJ. Neuroimaging in the brain in HIV-1-infected patients. *Neuroimaging Clin N Am*. 2008;18:93-117; viii.
- 801 Luzzati R, Ferrari S, Nicolato A, et al. Stereotactic brain biopsy in human immunodeficiency virus-infected patients. *Arch Intern Med*. 1996;156:565-568.
- 802 Cajulis RS, Hayden R, Frias-Hidvegi D, Brody BA, Yu GH, Levy R. Role of cytology in the intraoperative diagnosis of HIV-positive patients undergoing stereotactic brain biopsy. *Acta Cytol*. 1997;41:481-486.
- 803 Ghafouri M, Amini S, Khalili K, Sawaya BE. HIV-1 associated dementia: symptoms and causes. *Retrovirology*. 2006;3:28.
- 804 Crews L, Patrick C, Achim CL, Everall IP, Masliah E. Molecular Pathology of Neuro-AIDS (CNS-HIV). *Int J Mol Sci*. 2009;10:1045-1063.
- 805 Burdo TH, Lackner A, Williams KC. Monocyte/macrophages and their role in HIV neuropathogenesis. *Immunol Rev*. 2013;254:102-113.
- 806 Singer EJ, Faldes-Sueiras M, Commins D, Levine A. Neurologic presentations of AIDS. *Neurol Clin*. 2010;28:253-275.
- 807 Valcour V, Chalermchai T, Sailasuta N, Marovich M, Lerdlum S, Suttichom D, Suwanwela NC, et al. Central nervous system viral invasion and inflammation during acute HIV infection. *J Infect Dis*. 2012;206:275-282.
- 808 Clifford DB, Ances BM. HIV-associated neurocognitive disorder. *Lancet Infect Dis*. 2013;13:976-986.
- 809 Manji H, Jäger HR, Winston A. HIV, dementia and antiretroviral drugs: 30 years of an epidemic. *J Neurol Neurosurg Psychiatry*. 2013;84:1126-1137.

- 
- 810 Bonnet F, Amieva H, Marquant F, Bernard C, Bruyand M, Dauchy FA, Mercié P, et al; S CO3 Aquitaine Cohort. Cognitive disorders in HIV-infected patients: are they HIV-related? *AIDS*. 2013;27:391-400.
- 811 Soontornniyomkij V, Umlauf A, Chung SA, Cochran ML, Soontornniyomkij B, Gouaux B, Toperoff W, Moore DJ, Masliah E, Ellis RJ, Grant I, Achim CL. HIV protease inhibitor exposure predicts cerebral small vessel disease. *AIDS*. 2014;Mar 15. doi: 10.1097/QAD.0000000000000262.
- 812 Clifford DB. AIDS dementia. *Med Clin North Am*. 2002;86:537-550.
- 813 Ances BM, Ellis RJ. Dementia and neurocognitive disorders due to HIV-1 infection. *Semin Neurol*. 2007;27:86-92.
- 814 Kaul M. HIV-1 associated dementia: update on pathological mechanisms and therapeutic approaches. *Curr Opin Neurol*. 2009;22:315-320.
- 815 Glass JD, Fedor H, Wesselingh SL, McArthur JC. Immunocytochemical quantitation of human immunodeficiency virus in the brain: correlations with dementia. *Ann Neurol*. 1995;38:755-762.
- 816 Hori K, Burd PR, Furuke K, Kutza J, Weih KA, Clouse KA. Human immunodeficiency virus-1-infected macrophages induce inducible nitric oxide synthetase and nitric oxide (NO) production in astrocytes: astrocytic NO as a possible mediator of neural damage in acquired immunodeficiency syndrome. *Blood*. 1999;93:1843-1850.
- 817 Churchill MJ, Wesselingh SL, Cowley D, Pardo CA, McArthur JC, Brew BJ, Gorry PR. Extensive astrocyte infection is prominent in human immunodeficiency virus-associated dementia. *Ann Neurol*. 2009;66:253-258.
- 818 Smith AB, Smimiotopoulos JG, Rushing EJ. From the archives of the AFIP: central nervous system infections associated with human immunodeficiency virus infection: radiologic-pathologic correlation. *Radiographics*. 2008;28:2033-2058.
- 819 Wiley CA, Achim CL, Christopherson C, et al. HIV mediates a productive infection of the brain. *AIDS*. 1999;13:2055-2059.
- 820 Purohit V, Rapaka R, Shurtleff D. Drugs of abuse, dopamine, and HIV-associated neurocognitive disorders/HIV-associated dementia. *Mol Neurobiol*. 2011;44(1):102-110.
- 821 DeGirolami U, Smith TW, Hénin D, Hauw JJ. Neuropathology of the acquired immunodeficiency syndrome. *Arch Pathol Lab Med*. 1990;114:643-655.

- 
- 822 Gray F, Adle-Biasette H, Chretien F, Lorin de la Grandmaison G, Force G, Keohane C. Neuropathology and neurodegeneration in human immunodeficiency virus infection. Pathogenesis of HIV-induced lesions of the brain, correlations with HIV-associated disorders and modifications according to treatments. *Clin Neuropathol*. 2001;20:146-155.
- 823 Bissel SJ, Wiley CA. Human immunodeficiency virus infection of the brain: pitfalls in evaluating infected/affected cell populations. *Brain Pathol*. 2004;14:97-108.
- 824 Jellinger KA, Setinek U, Drlicek M Böhm G, Steurer A, Lintner F. Neuropathology and general autopsy findings in AIDS during the last 15 years. *Acta Neuropathol*. 2000;100:213-220.
- 825 Offiah CE, Turnbull IW. The imaging appearances of intracranial CNS infections in adult HIV and AIDS patients. *Clin Radiol*. 2006;61:393-401.
- 826 Morrison HL, Neal JW, Parkes AB, Jasani B. Immunohistochemical retrieval of the principal HIV antigens p24, gp41, and gp120 in formalin fixed tissue: an investigation using HIV infected lymphoblasts and postmortem brain tissue from AIDS cases. *Mol Pathol*. 1998;51:227-231.
- 827 Kibayashi K, Mastri AR, Hirsch CS. Neuropathology of human immunodeficiency virus infection at different disease stages. *Hum Pathol*. 1996;27:637-642.
- 828 Cinque P, Vago L, Ceresa D, et al. Cerebrospinal fluid HIV-1 RNA levels: correlation with HIV encephalitis. *AIDS*. 1998;12:389-394.
- 829 Nebuloni M, Pellegrinelli A, Ferri A, et al. Etiology of microglial nodules in brains of patients with acquired immunodeficiency syndrome. *J Neurovirol*. 2000;6:46-50.
- 830 Gray F, Lescure FX, Adle-Biasette H, Polivka M, Gallien S, Pialoux G, Moulignier A. Encephalitis with infiltration by CD8+ lymphocytes in HIV patients receiving combination antiretroviral treatment. *Brain Pathol*. 2013;23:525-533.
- 831 Cinque P, Koralnik IJ, Gerevini S, Miro JM, Price RW. Progressive multifocal leukoencephalopathy in HIV-1 infection. *Lancet Infect Dis*. 2009;9:625-636.
- 832 Tavazzi E, White MK, Khalili K. Progressive multifocal leukoencephalopathy: clinical and molecular aspects. *Rev Med Virol*. 2012;22:18-32.
- 833 Tan CS, Dezube BJ, Bhargava P, Autissier P, Wüthrich C, Miller J, Koralnik IJ. Detection of JC virus DNA and proteins in the bone marrow of HIV-positive and HIV-negative patients: implications for viral latency and neurotropic transformation. *J Infect Dis*. 2009;199:881-888.

- 
- 834 Khanna N, Elzi L, Mueller NJ, Garzoni C, Cavassini M, Fux CA, Vernazza P, Bernasconi E, Battegay M, Hirsch HH; Swiss HIV Cohort Study. Incidence and outcome of progressive multifocal leukoencephalopathy over 20 years of the Swiss HIV Cohort Study. *Clin Infect Dis*. 2009;48:1459-1466.
- 835 Johnson T, Nath A. Neurological complications of immune reconstitution in HIV-infected populations. *Ann N Y Acad Sci*. 2010;1184:106-120.
- 836 DiRocco A. Diseases of the spinal cord in human immunodeficiency virus infection. *Semin Neurol*. 1999;19:151-155.
- 837 Tan SV, Gulloff RJ, Scaravilli F. AIDS-associated vacuolar myelopathy. A morphometric study. *Brain*. 1995;119:1247-1261.
- 838 Dickson DW, Belman AL, Kim TS, Horoupian DS, Rubinstein A. Spinal cord pathology in pediatric acquired immunodeficiency syndrome. *Neurology*. 1989;39:227-235.
- 839 Shimojima Y, Yazaki M, Kaneko K, Fukushima K, Morita H, Hashimoto T, Ikeda S. Characteristic spinal MRI findings of HIV-associated myelopathy in an AIDS patient. *Intern Med*. 2005;44:763-764.
- 840 García-García C, Castillo-Álvarez F, Azcona-Gutiérrez JM, Herraiz MJ, Ibarra V, Oteo JA. Spinal cord toxoplasmosis in human immunodeficiency virus infection/acquired immunodeficiency syndrome. *Infect Dis (Lond)*. 2015;47:277-282.
- 841 Grinspoon SK, Bilezikian JP. HIV disease and the endocrine system. *N Engl J Med*. 1992;327:1360-1365.
- 842 Setinek U, Wondrusch E, Jellinger K, et al. Cytomegalovirus infection of the brain in AIDS: a clinicopathologic study. *Acta Neuropathol*. 1995;90:511-515.
- 843 Mamidi A, DeSimone JA, Pomerantz RJ. Central nervous system infections in individuals with HIV-1 infection. *J Neurovirol*. 2002;8:158-167.
- 844 Pereira-Chiocola VL, Vidal JE, Su C. Toxoplasma gondii infection and cerebral toxoplasmosis in HIV-infected patients. *Future Microbiol*. 2009;4:1363-1379.
- 845 Chang L, Cornford ME, Chiang FL, Ernst TM, Sun NC, Miller BL. Radiologic-pathologic correlation. Cerebral toxoplasmosis and lymphoma in AIDS. *AJNR Am J Neuroradiol*. 1995;16:1653-1663.
- 846 Falangola MF, Reichler BS, Petito CK. Histopathology of cerebral toxoplasmosis in human immunodeficiency virus infection. *Human Pathol*. 1994;25:1091-1097.

- 
- 847 Mitchell DH, Sorrell TC, Allworth AM, et al. Cryptococcal disease of the CNS in immunocompetent hosts: influence of cryptococcal variety on clinical manifestations and outcome. *Clin Infect Dis*. 1995;20:611-616.
- 848 Brouwer AE, Teparukkul P, Pinpraphaporn S, et al. Baseline correlation and comparative kinetics of cerebrospinal fluid colony-forming unit counts and antigen titers in cryptococcal meningitis. *J Infect Dis*. 2005;192:681-684.
- 849 Chamie G, Marquez C, Luetkemeyer A. HIV-Associated Central Nervous System Tuberculosis. *Semin Neurol*. 2014;34:103-116.
- 850 Klock C, Cerski M, Goldani LZ. Histopathological aspects of neurocryptococcosis in HIV-infected patients: autopsy report of 45 patients. *Int J Surg Pathol*. 2009;17:444-448.
- 851 Camilleri-Broet S, Davi F, Feuillard J, et al. AIDS-related primary brain lymphomas: histopathologic and immunohistochemical study of 51 cases. *Hum Pathol*. 1997;28:367-374.
- 852 Buttner A, Marquart KH, Mehraein P, Weis S. Kaposi's sarcoma in the cerebellum of a patient with AIDS. *Clin Neuropathol*. 1997;16:185-189.
- 853 Grover D, Newsholme W, Brink N, Manji H, Miller R. Herpes simplex virus infection of the central nervous system in human immunodeficiency virus-type 1-infected patients. *Int J STD AIDS*. 2004;15:797-600.
- 854 Gray F, Belec L, Lescs MC, Chretien F, Ciardi A, Hassine D, Flament-Saillour M. Varicella-zoster virus infection of the central nervous system in the acquired immune deficiency syndrome. *Brain*. 1994;117:987-999.
- 855 Gutierrez J, Ortiz G. HIV/AIDS patients with HIV vasculopathy and VZV vasculitis: a case series. *Clin Neuroradiol*. 2011;21(3):145-151.
- 856 Garg RK, Sinha MK. Tuberculous meningitis in patients infected with human immunodeficiency virus. *J Neurol*. 2011;258:3-13.
- 857 Gyure KA, Prayson RA, Estes ML, Hall GS. Symptomatic Mycobacterium avium complex infection of the central nervous system. *Arch Pathol Lab Med*. 1995;119:836-839.
- 858 Vidal JE, Penalva de Oliveira AC, Bonasser Filho F, et al. Tuberculous brain abscess in AIDS patients: report of three cases and literature review. *Int J Infect Dis*. 2005;9:201-207.
- 859 Danaviah S, Sacks JA, Kumar KP, Taylor LM, Fallows DA, Naicker T, et al. Immunohistological characterization of spinal TB granulomas from HIV-negative and -

- 
- positive patients. *Tuberculosis (Edinb)*. 2013;93:432-441.
- 860 Metta H, Corti M, Redini L, Yampolsky C, Shtirbu R. Spinal epidural abscess due to *Mycobacterium tuberculosis* in a patient with AIDS: case report and review of the literature. *Braz J Infect Dis*. 2006;10:146-148.
- 861 Ghanem KG, Moore RD, Rompalo AM, Erbeling EJ, Zenilman JM, Gebo KA. Neurosyphilis in a clinical cohort of HIV-1-infected patients. *AIDS*. 2008;22:1145-1151.
- 862 Katz DA, Berger JR. Neurosyphilis in acquired immunodeficiency syndrome. *Arch Neurol*. 1989;46:895-898.
- 863 Malone JL, Wallace MR, Hendrick BB, et al. Syphilis and neurosyphilis in a human immunodeficiency virus type-1 seropositive population: evidence for frequent serologic relapse after therapy. *Am J Med*. 1995;99:55-63.
- 864 Tse W, Cersosimo MG, Gracies J-M, Morgello S, Olanow CW, Koller W. Movement disorders and AIDS: a review. *Parkinsonism Relat Disord*. 2004;10:323-334.
- 865 Scott KM, Parker F, Heckmann JM. Opsoclonus-myoclonus syndrome and HIV-infection. *J Neurol Sci*. 2009;284:192-195.
- 866 Verma A, Berger JR. ALS syndrome in patients with HIV-1 infection. *J Neurol Sci*. 2006;240:59-64.
- 867 Benjamin LA, Bryer A, Emsley HC, Khoo S, Solomon T, Connor MD. HIV infection and stroke: current perspectives and future directions. *Lancet Neurol*. 2012;11:878-890.
- 868 Connor MD, Lammie GA, Bell JE, Warlow CP, Simmonds P, Brett RD. Cerebral infarction in adult AIDS patients: observations from the Edinburgh HIV autopsy cohort. *Stroke*. 2000;31:2117-2126.
- 869 Tipping B, deVilliers L, Wainwright N, Candy S, Bryer A. Stroke in patients with human immunodeficiency virus infection. *J Neurol Neurosurg Psychiatry*. 2007; 78:1320-1324.
- 870 Schwartzman WA, Patnaik M, Barka NE, Peter JB. Rochalimaea antibodies in HIV-associated neurologic disease. *Neurology*. 1994;44:1312-1316.
- 871 Drake KW, Adam RD. Coccidioidal meningitis and brain abscesses: analysis of 71 cases at a referral center. *Neurology*. 2009 Nov;73(21):1780-1786.
- 872 Le T, Huu Chi N, Kim Cuc NT, Manh Sieu TP, Shikuma CM, Farrar J, Day JN. AIDS-associated *Penicillium marneffei* infection of the central nervous system. *Clin Infect Dis*. 2010;51:1458-1462



- 
- 873 Delobel, P., Signate, A., El Guedj, M., Couppie, P., Gueye, M., Smadja, D. & Pradinaud, R. Unusual form of neurocysticercosis associated with HIV infection. *Eur J Neurol*. 2004;11:55-58.
- 874 Serpa JA, Moran A, Goodman JC, Giordano TP, White AC Jr. Neurocysticercosis in the HIV era: a case report and review of the literature. *Am J Trop Med Hyg*. 2007;77:113-1117.
- 875 Lo SC, Dawson MS, Wong DM, et al. Identification of *Mycoplasma incognitus* infection in patients with AIDS: an immunohistochemical, *in situ* hybridization and ultrastructural study. *Am J Trop Med Hyg*. 1989;41:601-616.
- 876 Green DA, Masliah E, Vinters HV, Beizai P, Moore DJ, Achim CL. Brain deposition of beta-amyloid is a common pathologic feature in HIV positive patients. *AIDS*. 2005;19:407-411.
- 877 Pulliam L. HIV regulation of amyloid beta production. *J Neuroimmune Pharmacol*. 2009;4:213-217.
- 878 Robinson-Papp J, Simpson DM. Neuromuscular diseases associated with HIV-1 infection. *Muscle Nerve*. 2009;40:1043-1053.
- 879 Harrison TB, Smith B. Neuromuscular manifestations of HIV/AIDS. *J Clin Neuromuscul Dis*. 2011;13(2):68-84.
- 880 Working Group of the American Academy of Neurology AIDS Task Force. Nomenclature and research case definitions for neurologic manifestations of human immunodeficiency virus-type 1 (HIV-1) infection. *Neurology*. 1991;41:778-785.
- 881 Ferrari S, Vento S, Monaco S, Cavallaro T, Cainelli F, Rizzuto N, Temesgen Z. Human immunodeficiency virus-associated peripheral neuropathies. *Mayo Clin Proc*. 2006;81:213-219.
- 882 Gonzalez-Duarte A, Robinson-Papp J, Simpson DM. Diagnosis and management of HIV-associated neuropathy. *Neurol Clin*. 2008;26:821-832.
- 883 Dalakas MC. Peripheral neuropathy and antiretroviral drugs. *J Periph Nerv Syst*. 2001;6:14-20.
- 884 Authier FJ, Chariot P, Gherardi RK. Skeletal muscle involvement in human immunodeficiency virus (HIV)-infected patients in the era of highly active antiretroviral therapy (HAART). *Muscle Nerve*. 2005;32:247-260.
- 885 Moscato EE, Bloomer MM, Garcia-Kennedy R, Seiff SR. Human immunodeficiency virus-associated blepharoptosis. *Ophthal Plast Reconstr Surg*. 2011;27:360-363.

- 
- 886 Carroll MB, Holmes R. Dermatomyositis and HIV infection: case report and review of the literature. *Rheumatol Int*. 2011;31:673-679.
- 887 Wrzolek MA, Sher JH, Kozlowski PB, Rao C. Skeletal muscle pathology in AIDS: an autopsy study. *Muscle Nerve*. 1990;13:508-515.
- 888 Cupler EJ, Leon-Monzon M, Miller J, Semino-Mora C, Anderson TL, Dalakas MC. Inclusion body myositis in HIV-1 and HTLV-1 infected patients. *Brain*. 1996;119(Pt 6):1887-1893.
- 889 Crum NF. Bacterial pyomyositis in the United States. *Am J Med*. 2004;117:420-428.
- 890 Small LN, Ross JJ. Tropical and temperate pyomyositis. *Infect Dis Clin North Am*. 2005;19981-989.
- 891 Ali R, Kim JY, Henderson BA. Anterior and adnexal manifestations of HIV/AIDS. *Int Ophthalmol Clin*. 2007;47:15-32.
- 892 Tan S, Duan H, Xun T, Ci W, Qiu J, Yu F, Zhao X, et al. HIV-1 impairs human retinal pigment epithelial barrier function: possible association with the pathogenesis of HIV-associated retinopathy. *Lab Invest*. 2014;94(7):777-787.
- 893 Morinelli EN, Dugel PU, Lee M, Klatt EC, Rao NA. Opportunistic intraocular infections in AIDS. *Tr Am Ophth Soc*. 1992;90:97-109.
- 894 Miller C, Short WR, Perez-Povis L, Lontok J, Fecarotta C, Liu M, Sendekci J, Belden K. The spectrum of eye disease in hospitalized adults living with HIV, 1995-2010. *AIDS Patient Care STDS*. 2014;28:47-55.
- 895 Jabs DA. Cytomegalovirus retinitis and the acquired immunodeficiency syndrome--bench to bedside: LXVII Edward Jackson Memorial Lecture. *Am J Ophthalmol*. 2011;151:198-216.
- 896 Srivastava SK, Martin DF, Mellow SD, Parks DJ, Dastgheib K, Chan CC. Pathological findings in eyes with the ganciclovir implant. *Ophthalmology*. 2005;112:780-786.
- 897 Gangaputra S, Drye L, Vaidya V, Thorne JE, Jabs DA, Lyon AT. Non-cytomegalovirus ocular opportunistic infections in patients with acquired immunodeficiency syndrome. *Am J Ophthalmol*. 2013;155:206-212.
- 898 Shafran SD, Singer J, Zarowny DP, et al. Determinants of rifabutin-associated uveitis in patients treated with rifabutin, clarithromycin, and ethambutol for Mycobacterium avium complex bacteremia: a multivariate analysis. Canadian HIV Trials Network Protocol 010 Study Group. *J Infect Dis*. 1998;177:252-255.

- 
- 899 Nithyanandam S, Joseph M, Stephen J. Ocular complications and loss of vision due to herpes zoster ophthalmicus in patients with HIV infection and a comparison with HIV-negative patients. *Int J STD AIDS*. 2013;24:106-109.
- 900 Babu RB, Sudharshan S, Kumarasamy N, Therese L, Biswas J. Ocular tuberculosis in acquired immunodeficiency syndrome. *Am J Ophthalmol*. 2006;142:413-418.
- 901 Kronish JW, Johnson TE, Gilberg SM, Corrent GF, McLeish WM, Scott KR. Orbital infections in patients with human immunodeficiency virus infection. *Ophthalmology*. 1996;103:1483-1492.
- 902 Chadburn A, Abdul-Nabi AM, Teruya BS, Lo AA. Lymphoid proliferations associated with human immunodeficiency virus infection. *Arch Pathol Lab Med*. 2013;137:360-370.
- 903 Schacker TW, Nguyen PL, Martinez E. Persistent abnormalities in lymphoid tissues of human immunodeficiency virus-infected patients successfully treated with highly active antiretroviral therapy. *J Infect. Dis*. 2002;186:1092-1097.
- 904 Wenig BM, Thompson LDR, Frankel SS, Burke AP, Abbondanzo SL, Sesterhann I, Heffner DK. Lymphoid changes of the nasopharyngeal and palatine tonsils that are indicative of human immunodeficiency virus infection. *Am J Surg Pathol*. 1996;20:572-587.
- 905 Quijano G, Siminovich M, Drut R. Histopathologic findings in the lymphoid and reticuloendothelial system in pediatric HIV infection: a postmortem study. *Pediatr Pathol Lab Med*. 1997;17:845-856.
- 906 Bem C. Human immunodeficiency virus-positive tuberculous lymphadenitis in Central Africa: clinical presentation of 157 cases. *Int J Tuberc Lung Dis*. 1997;1:215-219.
- 907 Farhi DC, Wells SJ, Siegel RJ. Syphilitic lymphadenopathy: histology and human immunodeficiency virus status. *Am J Clin Pathol*. 1999;112:330-334.
- 908 Collins LS, Fowler A, Tong CY, de Ruiter A. Multicentric Castleman's disease in HIV infection. *Int J STD AIDS*. 2006;17:19-24.
- 909 Hillier JC, Shaw P, Miller RF, Miller RF, et al. Imaging features of multicentric Castleman's disease in HIV infection. *Clin Radiol*. 2004;59:596-601.
- 910 Stebbing J, Pantanowitz L, Dayyani F, Sullivan RJ, Bower M, Dezube BJ. HIV-associated multicentric Castleman's disease. *Am J Hematol*. 2008;83:498-503.
- 911 Klatt EC, Meyer PR. Pathology of the spleen in acquired immunodeficiency syndrome. *Arch Pathol Lab Med*. 1987;111:1050-1053.

- 
- 912 Mikhael J, Northridge K, Lindquist K, Kessler C, Deuson R, Danese M. Short-term and long-term failure of laparoscopic splenectomy in adult immune thrombocytopenic purpura patients: a systematic review. *Am J Hematol*. 2009;84:743-748.
- 913 Moses A, Nelson J, Bagby GC Jr. The influence of human immunodeficiency virus-1 on hematopoiesis. *Blood*. 1998;91:1479-1495.
- 914 Volberding PA, Baker KR, Levine AM. Human immunodeficiency virus hematology. *Hematology (Am Soc Hematol Educ Program)*. 2003;294-313.
- 915 Lai M, Visconti E, D'Onofrio G, Tamburrini E, Cauda R, Leone G. Lower hemoglobin levels in human immunodeficiency virus-infected patients with a positive direct antiglobulin test (DAT): relationship with DAT strength and clinical stages. *Transfusion*. 2006;46:1237-1243.
- 916 Florea AV, Ionescu DN, Melhem MF. Parvovirus B19 infection in the immunocompromised host. *Arch Pathol Lab Med*. 2007;131:799-804.
- 917 Passos AM, Treitinger A, Spada C. An overview of the mechanisms of HIV-related thrombocytopenia. *Acta Haematol*. 2010;124:13-8.
- 918 Fine DM, Fogo AB, Alpers CE. Thrombotic microangiopathy and other glomerular disorders in the HIV-infected patient. *Semin Nephrol*. 2008;28:545-555.
- 919 Gunther K, Garizio D, Nesara P. ADAMTS13 activity and the presence of acquired inhibitors in human immunodeficiency virus-related thrombotic thrombocytopenic purpura. *Transfusion*. 2007;47:1710-1716.
- 920 Meynard JL, Guiguet M, Arsac S, Frottier J, Meyohas MC. Frequency and risk factors of infectious complications in neutropenic patients infected with HIV. *AIDS*. 1997;11:995-998.
- 921 Kuritzkes DR. Neutropenia, neutrophil dysfunction, and bacterial infection in patients with human immunodeficiency virus disease: the role of granulocyte colony-stimulating factor. *Clin Infect Dis*. 2000;30:256-260.
- 922 Dentali F, Nicolini E, Ageno W. Venous and arterial thrombosis associated with HIV infection. *Semin Thromb Hemost*. 2012;38(5):524-529.
- 923 Malek J, Rogers R, Kufera J, Hirshon JM. Venous thromboembolic disease in the HIV-infected patient. *Am J Emerg Med*. 2011;29:278-282.

- 
- 924 Llewelyn MJ, Noursadeghi M, Dogan A, Edwards SG, Miller RF. Diagnostic utility of bone marrow sampling in HIV-infected patients since the advent of highly active antiretroviral therapy. *Int J STD AIDS*. 2005;16:686-690.
- 925 Calore EE, Tanaka PY, Perez NM, deAlmeida LV. Bone marrow pathology in AIDS. *Pathol Res Pract*. 2004;200:591-597.
- 926 Diebold J, Tabbara W, Marche C, Audouin J, LeTourneau A. Bone marrow changes at several stages of HIV infection, studied on bone marrow biopsies in 85 patients. *Arch Anat Cytol Pathol*. 1991;39:137-146.
- 927 Hussong J, Peterson LR, Warren JR, Peterson LC. Detecting disseminated *Mycobacterium avium* complex infections in HIV-positive patients. *Am J Clin Pathol*. 1998;110:806-809.
- 928 Fardet L, Lambotte O, Meynard JL, Kamouh W, Galicier L, Marzac C, de Labarthe A, Cabane et al. Reactive haemophagocytic syndrome in 58 HIV-1-infected patients: clinical features, underlying diseases and prognosis. *AIDS*. 2010;24:1299-1306.
- 929 Brouland JP, Audouin J, Hofman P, et al. Bone marrow involvement by disseminated toxoplasmosis in acquired immunodeficiency syndrome: the value of bone marrow trephine biopsy and immunohistochemistry for the diagnosis. *Hum Pathol*. 1996;27:302-306.
- 930 Nong S, Liang J. Bone marrow *Penicillium marneffe* infection in acquired immunodeficiency syndrome patients: report of 35 cases. *Trop Biomed*. 2013;30:89-91.
- 931 Seneviratne L, Espina BM, Nathwani BN, Chan JA, Brynes RK, Levine AM. Clinical, immunologic, and pathologic correlates of bone marrow involvement in 291 patients with acquired immunodeficiency syndrome-related lymphoma. *Blood*. 2001;98:2358-2363.
- 932 The BS, Lu HH, Lynch GR, Banez E, Kroll MH. AIDS-related Kaposi's sarcoma involving bone and bone marrow. *South Med J*. 1999;92:61-64.
- 933 Bacon CM, Miller RF, Noursadeghi M, McNamara C, Du M-Q, Dogan A. Pathology of bone marrow in human herpes virus-8 (HHV-8)-associated multicentric Castleman disease. *Br J Haematol*. 2004;127:585-591.
- 934 Kolte L. Thymic function in HIV-infection. *Dan Med J*. 2013;60(4):B4622.
- 935 Ho Tsong Fang R, Colantonio AD, Uittenbogaart CH. The role of the thymus in HIV infection: a 10 year perspective. *AIDS*. 2008;22:171-184.
- 936 Schuurman HJ, Krone WJ, Broekhuizen R, et al. The thymus in acquired immunodeficiency syndrome. *Am J Pathol*. 1989;134:1329-1338.

- 
- 937 Burke AP, Anderson D, Benson W, Turnicky R, Mannan P, Liang Y-H, Smialek J, et al. Localization of human immunodeficiency virus 1 RNA in thymic tissues from asymptomatic drug addicts. *Arch Pathol Lab Med*. 1995;119:36-41.
- 938 Joshi VV, Oleske JM, Saad S, et al. Thymus biopsy in children with acquired immunodeficiency syndrome. *Arch Pathol Lab Med*. 1986;110:837-842.
- 939 Kontny HU, Sleasman JW, Kingma DW, et al. Multilocular thymic cysts in children with human immunodeficiency virus infection: clinical and pathologic aspects. *J Pediatr*. 1997;131:264-270.
- 940 Chou SH, Prabhu SJ, Crothers K, Stern EJ, Godwin JD, Pipavath SN. Thoracic diseases associated with HIV infection in the era of antiretroviral therapy: clinical and imaging findings. *Radiographics*. 2014;34:895-911.
- 941 Danoff A. Endocrinologic complications of HIV infection. *Med Clin North Am*. 1996;80:1453-1469.
- 942 Sinha U, Sengupta N, Mukhopadhyay P, Roy KS. Human immunodeficiency virus endocrinopathy. *Indian J Endocrinol Metab*. 2011;15(4):251-260.
- 943 Bons J, Moreau L, Lefebvre H. Adrenal disorders in human immunodeficiency virus (HIV) infected patients. *Ann Endocrinol (Paris)*. 2013;74(5-6):508-14.
- 944 Parsa AA, Bhangoo A. HIV and thyroid dysfunction. *Rev Endocr Metab Disord*. 2013;14:127-131.
- 945 Jaeger P, Otto S, Speck RF, Villiger L, Horber FF, Casez JP, Takkinen R. Altered parathyroid gland function in severely immunocompromised patients infected with human immunodeficiency virus. *J Clin Endocrinol Metab*. 1994;79:1701-1705.
- 946 Sano T, Kovacs K, Scheithauer BW, Rosenblum MK, Petito CK, Greco CM. Pituitary pathology in acquired immunodeficiency syndrome. *Arch Pathol Lab Med*. 1989;113:1066-1070.
- 947 Haugaard SB. Alteration in pancreatic islet function in human immunodeficiency virus. *Endocrinol Metab Clin North Am*. 2014;43:697-708.
- 948 Lefkowitz JH. The liver in AIDS. *Semin Liver Dis*. 1997;17:335-344.
- 949 Keaveny AP, Karasik MS. Hepatobiliary and pancreatic infections in AIDS: part I. *AIDS Patient Care STDS*. 1998;12:347-357.

- 
- 950 Crane M, Iser D, Lewin SR. Human immunodeficiency virus infection and the liver. *World J Hepatol*. 2012;4(3):91-98.
- 951 Sonderup MW, Wainwright H, Hall P, Hairwadzi H, Spearman CW. A clinicopathological cohort study of liver pathology in 301 patients with human immunodeficiency virus/acquired immune deficiency syndrome. *Hepatology*. 2015 Jan 16. doi: 10.1002/hep.27710.
- 952 Kahn E, Alba Greco M, Daum F, et al. Hepatic pathology in pediatric acquired immunodeficiency syndrome. *Hum Pathol*. 1991;22:1111-1119.
- 953 Blackard JT, Sherman KE. HCV/ HIV co-infection: time to re-evaluate the role of HIV in the liver? *J Viral Hepat*. 2008;15:323-330.
- 954 Joshi D, O'Grady J, Dieterich D, Gazzard B, Agarwal K. Increasing burden of liver disease in patients with HIV infection. *Lancet*. 2011;377:1198-1209.
- 955 Koziel MJ, Peters MG. Viral hepatitis in HIV infection. *N Engl J Med*. 2007;356:1445-1454.
- 956 Soriano V, Vispo E, Labarga P, Medrano J, Barreiro P. Viral hepatitis and HIV co-infection. *Antiviral Res*. 2010;85:303-315.
- 957 Puoti M, Bruno R, Soriano V, et al. Hepatocellular carcinoma in HIV-infected patients: epidemiological features, clinical presentation and outcome. *AIDS*. 2004;18:2285-2293.
- 958 Ida S, Tachikawa N, Nakajima A, et al. Influence of human immunodeficiency virus type 1 infection on acute hepatitis A virus infection. *Clin Infect Dis*. 2002;34:379-385.
- 959 Sonderup MW, Wainwright H, Hall P, Hairwadzi H, Spearman CW. A clinicopathological cohort study of liver pathology in 301 patients with human immunodeficiency virus/acquired immune deficiency syndrome. *Hepatology*. 2015;61:1721-1729.
- 960 Hsu MS, Hsieh SM, Chen MY, Hung CC, Chang SC. Association between amebic liver abscess and human immunodeficiency virus infection in Taiwanese subjects. *BMC Infect Dis*. 2008;16:8:48.
- 961 Scerpella EG, Villareal AA, Casanova PF, Moreno JN. Primary lymphoma of the liver in AIDS. Report of one new case and review of the literature. *J Clin Gastroenterol*. 1996;22:51-53.
- 962 Dalton SD, Rahimi AR. Emerging role of riboflavin in the treatment of nucleoside analogue-induced type B lactic acidosis. *AIDS Patient Care STDS*. 2001;15:611-614.

- 
- 963 Sterling RK, Smith PG, Brunt EM. Hepatic steatosis in human immunodeficiency virus: a prospective study in patients without viral hepatitis, diabetes, or alcohol abuse. *J Clin Gastroenterol*. 2013;47:182-187.
- 964 Ristig M, Drechsler H, Powderly WG. Hepatic steatosis and HIV infection. *AIDS Patient Care STDS*. 2005;19:356-365.
- 965 Guaraldi G, Squillace N, Stentarelli C, Orlando G, D'Amico R, Ligabue G, Fiocchi F, et al. Nonalcoholic fatty liver disease in HIV-infected patients referred to a metabolic clinic: prevalence, characteristics, and predictors. *Clin Infect Dis*. 2008;47:250-257.
- 966 Lemoine M, Serfaty L, Capeau J. From nonalcoholic fatty liver to nonalcoholic steatohepatitis and cirrhosis in HIV-infected patients: diagnosis and management. *Curr Opin Infect Dis*. 2012;25(1):10-16.
- 967 Rockstroh JK, Mohr R, Behrens G, Spengler U. Liver fibrosis in HIV: which role does HIV itself, long-term drug toxicities and metabolic changes play? *Curr Opin HIV AIDS*. 2014;9:365-370.
- 968 Cesari M, Schiavini M, Marchetti G, Caramma I, Ortu M, Franzetti F, Galli M, Antinori S, Milazzo L. Noncirrhotic portal hypertension in HIV-infected patients: a case control evaluation and review of the literature. *AIDS Patient Care STDS*. 2010;24:697-703.
- 969 Aggarwal S, Fiel MI, Schiano TD. Obliterative portal venopathy: a clinical and histopathological review. *Dig Dis Sci*. 2013;58:2767-2776.
- 970 Mohle-Boetani JC, Koehler JE, Berger TG, et al. Bacillary angiomatosis and bacillary peliosis in patients infected with human immunodeficiency virus: clinical characteristics in a case-control study. *Clin Infect Dis*. 1996;22:794-800.
- 971 Lamps LW, Gray GF, Scott MA. The histologic spectrum of hepatic cat scratch disease. *Am J Surg Pathol*. 1996;20:1253-1259.
- 972 Buckley JA, Hutchins GM. Association of hepatic veno-occlusive disease with the acquired immunodeficiency syndrome. *Mod Pathol*. 1995;8:398-401.
- 973 Tonolini M, Bianco R. HIV-related/AIDS cholangiopathy: pictorial review with emphasis on MRCP findings and differential diagnosis. *Clin Imaging*. 2013;37:219-226.



- 
- 974 Wilcox CM, Monkemuller KE. Hepatobiliary diseases in patients with AIDS: focus on AIDS cholangiopathy and gallbladder disease. *Dig Dis*. 1998;16:205-213.
- 975 Devarbhavi H, Sebastian T, Seetharamu SM, Karanth D. HIV/AIDS cholangiopathy: clinical spectrum, cholangiographic features and outcome in 30 patients. *J Gastroenterol Hepatol*. 2010;25:1656-6160.
- 976 French AL, Beaudet LM, Benator DA, Levy CS, Kass M, Orenstein JM. Cholecystectomy in patients with AIDS: clinicopathologic correlations in 107 cases. *Clin Infect Dis*. 1995;21:852-858.
- 977 De Angelis C, Mangone M, Bianchi M, Saracco G, Repici A, Rizzetto M, Pellicano R. An update on AIDS-related cholangiopathy. *Minerva Gastroenterol Dietol*. 2009;55:79-82.
- 978 Rerkpattanapipat P, Wongpraparut N, Jacobs LE, Kotler ME. Cardiac manifestations of acquired immunodeficiency syndrome. *Arch Intern Med*. 2000;160:602-608.
- 979 Sudano I, Spieker LE, Noll G, Corti R, Weber R, Luscher TF. Cardiovascular disease in HIV infection. *Am Heart J*. 2006;151:1147-1155.
- 980 Gowda RM, Khan IA, Mehta NJ, Gowda MR, Sacchi TJ, Vasavada BC. Cardiac tamponade in patients with human immunodeficiency virus disease. *Angiology*. 2003;54:469-474.
- 981 Sims A, Hadigan C. Cardiovascular complications in children with HIV infection. *Curr HIV/AIDS Rep*. 2011;8:209-214.
- 982 Boccara F, Lang S, Meuleman C, Ederhy S, Mary-Krause M, Costagliola D, Capeau J, Cohen A. HIV and coronary heart disease: time for a better understanding. *J Am Coll Cardiol*. 2013;61:511-523.
- 983 Micheletti RG, Fishbein GA, Fishbein MC, Singer EJ, Weiss RE, Jeffries RA, Currier JS. Coronary atherosclerotic lesions in human immunodeficiency virus-infected patients: a histopathologic study. *Cardiovasc Pathol*. 2009;18:28-36.
- 984 Aberg JA. Cardiovascular complications in HIV management: past, present, and future. *J Acquir Immune Defic Syndr*. 2009;50:54-64.
- 985 Grinspoon SK. Metabolic syndrome and cardiovascular disease in patients with human immunodeficiency virus. *Am J Med*. 2005;118(Suppl 2):23S-28S.
- 986 Subramanian S, Tawakol A, Burdo TH, Abbara S, Wei J, Vijayakumar J, Corsini E, et al. Arterial inflammation in patients with HIV. *JAMA*. 2012;308:379-386.

- 
- 987 van Wijk JP, de Koning EJ, Cabezas MC, Joven J, op't Roodt J, Rabelink TJ, Hoepelman AM. Functional and structural markers of atherosclerosis in human immunodeficiency virus-infected patients. *J Am Coll Cardiol*. 2006;47:1117-1123.
- 988 Thomas CM, Smart EJ. How HIV protease inhibitors promote atherosclerotic lesion formation. *Curr Opin Lipidol*. 2007;18:561-565.
- 989 Eugenin EA, Morgello S, Klotman ME, Mosoian A, Lento PA, Berman JW, Schechter AD. Human immunodeficiency virus (HIV) infects human arterial smooth muscle cells in vivo and in vitro: implications for the pathogenesis of HIV-mediated vascular disease. *Am J Pathol*. 2008;172:1100-1111.
- 990 Freitas P, Carvalho D, Santos AC, Madureira AJ, Martinez E, Pereira J, Sarmento A, Medina JL. Carotid intima media thickness is associated with body fat abnormalities in HIV-infected patients. *BMC Infect Dis*. 2014;Jun 23;14:348.
- 991 Duong M, Buisson M, Cotin Y, et al. Coronary heart disease associated with the use of human immunodeficiency virus (HIV)-1 protease inhibitors: report of four cases and review. *Clin Cardiol*. 2001;24:690-694.
- 992 Periard D, Cavassini M, Taffé P, Chevalley M, Senn L, Chapuis-Taillard C, deVallière S, Hayoz D, Tarr PE. High prevalence of peripheral arterial disease in HIV-infected persons. *Clin Infect Dis*. 2008;46:761-767.
- 993 Depairon M, Chessex S, Sudre P, et al. Premature atherosclerosis in HIV-infected individuals—focus on protease inhibitor therapy. *AIDS*. 2001;15:329-334.
- 994 Monsuez JJ, Charniot JC, Escaut L, Teicher E, Wyplosz B, Couzigou C, Vignat N, et al. HIV-associated vascular diseases: structural and functional changes, clinical implications. *Int J Cardiol*. 2009;133:293-306.
- 995 Ho JE, Hsue PY. Cardiovascular manifestations of HIV infection. *Heart*. 2009;95:1193-1202.
- 996 Klatt EC, Heitz DR. Cardiac metastases. *Cancer*. 1990;65:1456-1459.
- 997 Mosunjac MI, Sundstrom JB, Heninger M, Ansari AA, Mosunjac MB. Combined pathological effects of cocaine abuse and HIV infection on the cardiovascular system: an autopsy study of 187 cases from the Fulton County Medical Examiner's office. *Am J Forensic Med Pathol*. 2008;29:9-13.
- 998 Choi AI, Vittinghoff E, Deeks SG, Weekley CC, Li Y, Shlipak MG. Cardiovascular risks associated with abacavir and tenofovir exposure in HIV-infected persons. *AIDS*. 2011;25(10):1289-1298.

- 
- 999 Cicalini S, Forcina G, DeRosa FG. Infective endocarditis in patients with human immunodeficiency infection. *J Infect.* 2001;42:267-271.
- 1000 Guillevin L. Vasculitides in the context of HIV infection. *AIDS.* 2008;22(Suppl 3):S27-33.
- 1001 Patel N, Patel N, Khan T, Patel N, Espinoza LR. HIV infection and clinical spectrum of associated vasculitides. *Curr Rheumatol Rep.* 2011;13(6):506-512.
- 1002 Chetty R, Batitang S, Nair R. Large artery vasculopathy in HIV-positive patients: another vasculitic enigma. *Hum Pathol.* 2000;31:374-379.
- 1003 Ntsekhe M, Mayosi BM. Tuberculous pericarditis with and without HIV. *Heart Fail Rev.* 2013;18:367-373.
- 1004 DiCarlo FJ, Anderson DW, Virmani R, et al. Rheumatic heart disease in a patient with acquired immunodeficiency syndrome. *Hum Pathol.* 1989;20:917-920.
- 1005 Shindel AW, Akhavan A, Sharlip ID. Urologic aspects of HIV infection. *Med Clin North Am.* 2011;95:129-151.
- 1006 Szczech LA, Grunfeld C, Scherzer R, Canchola JA, van der Horst C, Sidney S, Wohl D, Shlipak MG. Microalbuminuria in HIV infection. *AIDS.* 2007;21:1003-1009.
- 1007 Perazella MA. Acute renal failure in HIV-infected patients: a brief review of common causes. *Am J Med Sci.* 2000;319:385-391.
- 1008 Rao TK. Renal complications in HIV disease. *Med Clin North Am.* 1997;80:1437-1451.
- 1009 Lebovitch S, Mydio JH. HIV-AIDS – Urologic considerations. *Urol Clin North Am.* 2008;35:59-68.
- 1010 Wyatt CM, Morgello S, Katz-Malamed R, Wei C, Klotman ME, Klotman PE, D'Agati VD. The spectrum of kidney disease in patients with AIDS in the era of antiretroviral therapy. *Kidney Int.* 2009;75:428-434.
- 1011 Rosenberg AZ, Naicker S, Winkler CA, Kopp JB. HIV-associated nephropathies: epidemiology, pathology, mechanisms and treatment. *Nat Rev Nephrol.* 2015;11:150-160.
- 1012 Ross MJ. Advances in the pathogenesis of HIV-associated kidney diseases. *Kidney Int.* 2014;86:266-274.

- 
- 1013 D'Agati V, Appel G. Renal pathology of human immunodeficiency virus infection. *Semin Nephrol.* 1998;18:406-421.
- 1014 Wyatt CM, Klotman PE. HIV-1 and HIV-associated nephropathy 25 years later. *Clin J Am Soc Nephrol.* 2007;2 Suppl 1:S20-24.
- 1015 Szczech LA, Gupta SK, Habash R, et al. The clinical epidemiology and course of the spectrum of renal diseases associated with HIV infection. *Kidney Int.* 2004;66:1145-1152.
- 1016 Laurinavicius A, Hurwitz S, Rennke HG. Collapsing glomerulopathy in HIV and non-HIV patients: a clinicopathological and follow-up study. *Kidney Int.* 1999;56:2203-2213.
- 1017 Fine DM, Perazella MA, Lucas GM, Atta MG. Kidney biopsy in HIV: beyond HIV-associated nephropathy. *Am J Kidney Dis.* 2008;51:504-514.
- 1018 Parkhie SM, Fine DM, Lucas GM, Atta MG. Characteristics of patients with HIV and biopsy-proven acute interstitial nephritis. *Clin J Am Soc Nephrol.* 2010;5:798-804.
- 1019 Herlitz LC, Mohan S, Stokes MB, Radhakrishnan J, D'Agati VD, Markowitz GS. Tenofovir nephrotoxicity: acute tubular necrosis with distinctive clinical, pathological, and mitochondrial abnormalities. *Kidney Int.* 2010;78:1171-1177.
- 1020 Sukov WR, Lewin M, Sethi S, Rakowski TA, Lager DJ. BK virus-associated nephropathy in a patient with AIDS. *Am J Kidney Dis.* 2008;51:e15-18.
- 1021 Ledesma J, Muñoz P, Garcia de Viedma D, Cabrero I, Loeches B, Montilla P, Gijon P, Rodriguez-Sanchez B, Bouza E; BKV Study Group. BK virus infection in human immunodeficiency virus-infected patients. *Eur J Clin Microbiol Infect Dis.* 2012;31:1531-1535.
- 1022 Gaughan EM, Dezube BJ, Bower M, Aboulafia DM, Bohac G, Cooley TP, Pantanowitz L. HIV-associated bladder cancer: a case series evaluating difficulties in diagnosis and management. *BMC Urol.* 2009;9:10.
- 1023 Muciaccia B, Uccini S, Filippini A, et al. Presence and cellular distribution of HIV in the testes of seropositive subjects: an evaluation by in situ PCR hybridization. *FASEB J.* 1998;12:151-163.
- 1024 DaSilva M, Shevchuk MM, Cronin WJ, et al. Detection of HIV-related protein in testes and prostates of patients with AIDS. *Am J Clin Pathol.* 1990;93:196-201.
- 1025 Klatt EC, Rogers CR. Pathology of the testis in acquired immunodeficiency syndrome. *Histopathology.* 1988;12:659-665.

- 
- 1026 Shevchuk MM, Pigato JB, Khalife G, Armenakas NA, Fracchia JA. Changing testicular histology in AIDS: its implication for sexual transmission of HIV. *Urology*. 1999;53:203-208.
- 1027 Mazhari M, Skordilis K, Pearce I. Inflammatory pseudotumour of the testis in an HIV patient. *Histopathology*. 2006;48:616-617.
- 1028 Pantanowitz L, Bohac G, Cooley TP, Aboulafia D, Dezube BJ. Human immunodeficiency virus-associated prostate cancer: clinicopathological findings and outcome in a multi-institutional study. *BJU Int*. 2008;101:1519-1523.
- 1029 Duerr A, Heilig CM, Meikle SF, Cu-Uvin S, Klein RS, Rompalo A, Sobel JD. Incident and persistent vulvovaginal candidiasis among human immunodeficiency virus-infected women: Risk factors and severity. *Obstet Gynecol*. 2003;101:548-556.
- 1030 Chirenje ZM. HIV and cancer of the cervix. *Best Pract Res Clin Obstet Gynaecol*. 2005;19:269-276.
- 1031 Jamieson DJ, Paramsothy P, Cu-Uvin S, Duerr A, HIV Epidemiology Research Study Group. Vulvar, vaginal, and perianal intraepithelial neoplasia in women with or at risk for human immunodeficiency virus. *Obstet Gynecol*. 2006;107:1023-1028.
- 1032 Lehtovirta P, Finne P, Nieminen P, Skogberg K, Savonius H, Paavonen J, Heikinheimo O. Prevalence and risk factors of squamous intraepithelial lesions of the cervix among HIV-infected women – a long-term follow-up study in a low-prevalence population. *Int J STD AIDS*. 2006;17:831-834.
- 1033 Sun X-W, Kuhn L, Ellerbrock TV, Chiasson MA, Bush TJ, Wright TC Jr. Human papillomavirus infection in women with the human immunodeficiency virus. *N Engl J Med*. 1998;337:1343-1349.
- 1034 Massad LS, Xie X, Greenblatt RM, Minkoff H, Sanchez-Keeland L, Watts DH, Wright RL, et al. Effect of human immunodeficiency virus infection on the prevalence and incidence of vaginal intraepithelial neoplasia. *Obstet Gynecol*. 2012;119(3):582-589.
- 1035 Massad LS, Xie X, Darragh T, Minkoff H, Levine AM, Watts DH, Wright RL, et al; Women's Interagency HIV Study Collaborative Study Group. Genital warts and vulvar intraepithelial neoplasia: natural history and effects of treatment and human immunodeficiency virus infection. *Obstet Gynecol*. 2011;118(4):831-839.
- 1036 Danso D, Lyons F, Bradbeer C. Cervical screening and management of cervical intraepithelial neoplasia in HIV-positive women. *Int J STD AIDS*. 2006;17:579-584.

- 
- 1037 Evans DL, Pantanowitz L, Dezube BJ, Aboulafia DM. Breast enlargement in 13 men who were seropositive for human immunodeficiency virus. *Clin Infect Dis*. 2002;35:1113-1119.
- 1038 Rahim S, Ortiz O, Maslow M, Holzman R. A case-control study of gynecomastia in HIV-1-infected patients receiving HAART. *AIDS Read*. 2004;14:23-4, 29-32, 35-40.
- 1039 Deonarain J, Ramdial PK, Singh B. Bilateral lipomastia in men: a side effect of highly active antiretroviral therapy. *Int J Surg Pathol*. 2008;16:171-175.
- 1040 Pantanowitz L, Connolly JL. Pathology of the breast associated with HIV/AIDS. *Breast J*. 2002;8:234-243.
- 1041 Konstantinopoulos PA, Dezube BJ, March D, Pantanowitz L. HIV-associated intramammary lymphadenopathy. *Breast J*. 2007;13:192-195.
- 1042 van Leeuwen E, Prins JM, Jurriaans S, Boer K, Reiss P, Repping S, van der Veen F. Reproduction and fertility in human immunodeficiency virus type-1 infection. *Hum Reprod Update*. 2007;13(2):197-206.
- 1043 Zancanaro PC, McGirt LY, Mamelak AJ, Nguyen RH, Martins CR. Cutaneous manifestations of HIV in the era of highly active antiretroviral therapy: an institutional urban clinic experience. *J Am Acad Dermatol*. 2006;54:581-588.
- 1044 Krown SE, Testa MA, Huang J. AIDS-related Kaposi's sarcoma: prospective validation of the AIDS Clinical Trials Group staging classification. *J Clin Oncol*. 1997;15:3085-3092.
- 1045 Nasti G, Talamini R, Antinori A, Martellotta F, Jacchetti G, Chiodo F, Ballardini G, et al. AIDS-related Kaposi's Sarcoma: evaluation of potential new prognostic factors and assessment of the AIDS Clinical Trial Group Staging System in the Haart Era. *J Clin Oncol*. 2003;21:2876-2882.
- 1046 Radu O, Pantanowitz L. Kaposi sarcoma. *Arch Pathol Lab Med*. 2013;137:289-294.
- 1047 Grayson W, Pantanowitz L. Histological variants of cutaneous Kaposi sarcoma. *Diagn Pathol*. 2008;3:31.
- 1048 Niedt GW, Myskowski PL, Urmacher C, Niedzwiecki D, Chapman D, Safai B. Histology of early lesions of AIDS-associated Kaposi's sarcoma. *Mod Pathol*. 1990;3:64-70.
- 1049 Kao GF, Johnson FB, Sulica VI. The nature of hyaline (eosinophilic) globules and vascular slits of Kaposi's sarcoma. *Am J Dermatopathol*. 1990;12:256-267.

- 
- 1050 Ramdial PK, Chetty R, Singh B, Singh R, Aboobaker J. Lymphedematous HIV-associated Kaposi's sarcoma. *J Cutan Pathol*. 2006;33:474-481.
- 1051 Ioachim HL, Adsay V, Giancotti FR, Dorsett B, Melamed J. Kaposi's sarcoma of internal organs. *Cancer*. 1995;75:1376-1385.
- 1052 Alkan S, Eltoum IA, Tabbara S, Day E, Karcher DS. Usefulness of molecular detection of human herpesvirus-8 in the diagnosis of Kaposi sarcoma by fine-needle aspiration. *Am J Clin Pathol*. 1999;111:91-96.
- 1053 Niedt GW, Myskowski PL, Urmacher C, Niedzwiecki D, Chapman D, Krown SE, Safai B. Histologic predictors of survival in acquired immunodeficiency syndrome-associated Kaposi's sarcoma. *Hum Pathol*. 1992;23:1419-1426.
- 1054 O'Donnell PJ, Pantanowitz L, Grayson W. Unique histologic variants of cutaneous Kaposi sarcoma. *Am J Dermatopathol*. 2010;32:244-250.
- 1055 Yu Y, Demierre MF, Mahalingam M. Anaplastic Kaposi's sarcoma: an uncommon histologic phenotype with an aggressive clinical course. *J Cutan Pathol*. 2010;37:1088-1091.
- 1056 Crum-Cianflone N, Hullsiek KH, Satter E, Marconi V, Weintrob A, Ganesan A, Barthel RV, Fraser S, Agan BK. Cutaneous malignancies among HIV-infected persons. *Arch Intern Med*. 2009;169:1130-1138.
- 1057 Wilkins K, Turner R, Dolev JC, LeBoit PE, Berger TG, Maurer TA. Cutaneous malignancy and human immunodeficiency virus disease. *J Am Acad Dermatol*. 2006 Feb;54(2):189-206.
- 1058 Strehl JD, Mehlhorn G, Koch MC, Harrer EG, Harrer T, Beckmann MW, Agaimy A. HIV-associated Hypertrophic Herpes Simplex Genitalis With Concomitant Early Invasive Squamous Cell Carcinoma Mimicking Advanced Genital Cancer: Case Report and Literature Review. *Int J Gynecol Pathol*. 2012;31:286-293.
- 1059 Myskowski PL, Ahkami R. Dermatologic complications of HIV infection. *Med Clin North Am*. 1996;80:1415-1435.
- 1060 Hogan MT. Cutaneous infections associated with HIV/AIDS. *Dermatol Clin*. 2006;24:473-495.
- 1061 Petersen CS, Gerstoft J. Molluscum contagiosum in HIV-infected patients. *Dermatology*. 1992;184:19-21.

- 
- 1062 Smith KJ, Yeager J, Skelton H. Molluscum contagiosum: its clinical, histopathologic, and immunohistochemical spectrum. *Int J Dermatol*. 1999;38:664-672.
- 1063 Orkin M. Scabies in AIDS. *Semin Dermatol*. 1993;12:9-14.
- 1064 Karthikeyan K. Crusted scabies. *Indian J Dermatol Venereol Leprol*. 2009;75:340-347.
- 1065 Maguiña C, Guerra H, Ventosilla P. Bartonellosis. *Clin Dermatol*. 2009;27(3):271-80.
- 1066 Garman ME, Tyring SK. The cutaneous manifestations of HIV infection. *Dermatol Clin*. 2002;20:193-208.
- 1067 Hillesheim PB, Bahrami S. Cutaneous protothecosis. *Arch Pathol Lab Med*. 2011;135(7):941-944.
- 1068 Coopman SA, Johnson RA, Platt R, Stern RS. Cutaneous disease and drug reactions in HIV infection. *N Engl J Med*. 1993;328:1670-1674.
- 1069 Ramdial PK. Dermatopathological challenges in the human immunodeficiency virus and acquired immunodeficiency syndrome era. *Histopathology*. 2010;56:39-56.
- 1070 Dlova N, Mosam A. Inflammatory noninfectious dermatoses of HIV. *Dermatol Clin*. 2006;24:439-448.
- 1071 Ramos H, Pagliari C, Takakura CF, Sotto MN, Duarte MI. Pruritic papular eruption associated with HIV-etio-pathogenesis evaluated by clinical, immunohistochemical, and ultrastructural analysis. *J Dermatol*. 2005;32:549-556.
- 1072 Afonso JP, Tomimori J, Michalany NS, Nonogaki S, Porro AM. Pruritic papular eruption and eosinophilic folliculitis associated with human immunodeficiency virus (HIV) infection: a histopathological and immunohistochemical comparative study. *Am Acad Dermatol*. 2012;67:269-275.
- 1073 Menon K, Van Voorhees AS, Bebo BF Jr, Gladman DD, Hsu S, Kalb RE, Lebwohl MG, Strober BE. Psoriasis in patients with HIV infection: from the medical board of the National Psoriasis Foundation. *J Am Acad Dermatol*. 2010;62:291-299.
- 1074 Wu IB, Schwartz RA. Reiter's syndrome: the classic triad and more. *J Am Acad Dermatol*. 2008;59:113-121.
- 1075 Singal A, Khanna D. Onychomycosis: Diagnosis and management. *Indian J Dermatol Venereol Leprol*. 2011;77(6):659-672.



- 
- 1076 Aly R, Berger T. Common superficial fungal infections in patients with AIDS. *Clin Infect Dis*. 1996;22(suppl2):S128-S132.
- 1077 Ramdial PK, Mosam A, Dlova NC, B Satar N, Aboobaker J, Singh SM. Disseminated cutaneous histoplasmosis in patients infected with human immunodeficiency virus. *J Cutan Pathol*. 2002;29:215-225.
- 1078 Ustianowski AP, Lawn SD, Lockwood DN. Interactions between HIV infection and leprosy: a paradox. *Lancet Infect Dis*. 2006;6:350-360.
- 1079 Talhari C, Mira MT, Massone C, Braga A, Chrusciak-Talhari A, Santos M, Orsi AT, et al. Leprosy and HIV coinfection: a clinical, pathological, immunological, and therapeutic study of a cohort from a Brazilian referral center for infectious diseases. *J Infect Dis*. 2010;202:345-354.
- 1080 Tucker JD, Shah S, Jarrell AD, Tsai KY, Zembowicz A, Kroshinsky D. Lues maligna in early HIV infection case report and review of the literature. *Sex Transm Dis*. 2009;36:512-514.
- 1081 Kanitakis J, Carbonnel E, Delmonte S, Livrozet JM, Faure M, Claudy A. Multiple eruptive dermatofibromas in a patient with HIV infection: case report and literature review. *J Cutan Pathol*. 2000;27:54-56.
- 1082 Cappell MS, Hassan T. Pancreatic disease in AIDS--a review. *J Clin Gastroenterol*. 1993;17:254-263.
- 1083 Chehter EZ, Longo MA, Laudanna AA, Duarte MI. Involvement of the pancreas in AIDS: a prospective study of 109 postmortems. *AIDS*. 2000;14:1879-1886.
- 1084 Meesiri S. Pancreatic tuberculosis with acquired immunodeficiency syndrome: a case report and systematic review. *World J Gastroenterol*. 2012;18(7):720-6.
- 1085 Manfredi R, Calza L. HIV infection and the pancreas: risk factors and potential management guidelines. *Int J STD AIDS*. 2008;19:99-105.
- 1086 Barthet M, Chauveau E, Bonnet E, Petit N, Bernard JP, Gastaut JA, Sahel J. Pancreatic ductal changes in HIV-infected patients. *Gastrointest Endosc*. 1997;45:59-63.
- 1087 Kahn E, Anderson VM, Alba Greco M, Magid M. Pancreatic disorders in pediatric acquired immune deficiency syndrome. *Hum Pathol*. 1995;26:765-770.
- 1088 Klatt EC. Pathology of pentamidine-induced pancreatitis. *Arch Pathol Lab Med*. 1992;116:162-164.

- 
- 1089 Lockman S, Shapiro RL, Smeaton LM, et al. Response to antiretroviral therapy after a single, peripartum dose of nevirapine. *N Engl J Med*. 2007;356:135-147.
- 1090 Ahdieh L. Pregnancy and infection with human immunodeficiency virus. *Clin Obstet Gynecol*. 2001;44:154-166.
- 1091 Langston C, Lewis DE, Hammill HA, et al. Excess intrauterine fetal demise associated with maternal human immunodeficiency virus infection. *J Infect Dis*. 1995;172:1451-1460.
- 1092 Al-Husaini AM. Role of placenta in the vertical transmission of human immunodeficiency virus. *J Perinatol*. 2009;29:331-336.
- 1093 D'costa GF, Khadke K, Patil YV. Pathology of placenta in HIV infection. *Indian J Pathol Microbiol*. 2007;50:515-519.
- 1094 Bhoopat L, Khunamornpong S, Sirivatanapa P, Rithaporn T, Lerdsrimongkol P, Thorner PS, Bhoopat T. Chorioamnionitis is associated with placental transmission of human immunodeficiency virus-1 subtype E in the early gestational period. *Mod Pathol*. 2005;18:1357-1364.
- 1095 Brahmabhatt H, Sullivan D, Kigozi G, Askin F, Wabwire-Mangenm F, Serwadda D, Sewankambo N, Wawer M, Gray R. Association of HIV and malaria with mother-to-child transmission, birth outcomes, and child mortality. *J Acquir Immune Defic Syndr*. 2008;47:472-476.
- 1096 Caby F, Lemercier D, Coulomb A, Grigorescu R, Paris L, Touafek F, Carcelain G, Canestri A, et al. Fetal death as a result of placental immune reconstitution inflammatory syndrome. *J Infect*. 2010;61:185-188.
- 1097 Darko AD, Dim DC, Taylor G, Watson DC, Sun CC. Placental *Cryptococcus neoformans* infection without neonatal disease: case report and review of the literature. *Pediatr Dev Pathol*. 2009;12:249-252.
- 1098 Dave SP, Pernas FG, Roy S. The benign lymphoepithelial cyst and a classification system for lymphocytic parotid gland enlargement in the pediatric HIV population. *Laryngoscope*. 2007;117:106-113.
- 1099 Meer S, Dulabh S. Cystic lymphoid hyperplasia: an orofacial lesion strongly associated with HIV and AIDS. *Histopathology*. 2013;62:1067-1074.
- 1100 Maiorano E, Favia G, Viale G. Lymphoepithelial cyts of salivary glands: an immunohistochemical study of HIV-related and HIV-unrelated lesions. *Hum Pathol*. 1998;29:260-265.

- 
- 1101 Vargas PA, Mauad T, Bohm GM, Saldiva PH, Almeida OP. Parotid gland involvement in advanced AIDS. *Oral Dis*. 2003;9:55-61.
- 1102 Castle JT, Thompson LDR. Kaposi sarcoma of major salivary gland origin: a clinicopathologic series of six cases. *Cancer*. 2000;88:15-23.
- 1103 Dunand VA, Hammer SM, Rossi R, et al. Parasitic sinusitis and otitis in patients infected with human immunodeficiency virus: report of five cases and review. *Clin Infect Dis*. 1997;25:267-272.
- 1104 Davis LE, Rarey KE, McLaren LC. Clinical viral infections and temporal bone histologic studies of patients with AIDS. *Otolaryngol Head Neck Surg*. 1995;113:695-701.
- 1105 Michaels L, Soucek S, Liang J. The ear in the acquired immunodeficiency syndrome: I. Temporal bone histopathologic study. *Am J Otol*. 1994;15:515-522.
- 1106 Gurney TA, Murr AH. Otolaryngologic manifestations of human immunodeficiency virus infection. *Otolaryngol Clin North Am*. 2003;36:607-624.
- 1107 Mahlakwane MS, Ramdial PK, Sing Y, Calonje E, Biyana S. Otic pneumocystosis in acquired immune deficiency syndrome. *Am J Surg Pathol*. 2008;32:1038-1043.
- 1108 Van der Westhuizen Y, Swanepoel de W, Heinze B, Hofmeyr LM. Auditory and otological manifestations in adults with HIV/AIDS. *Int J Audiol*. 2013;52(1):37-43.
- 1109 Heinze B, Swanepoel DW, Hofmeyr LM. Systematic review of vestibular disorders related to human immunodeficiency virus and acquired immunodeficiency syndrome. *J Laryngol Otol*. 2011;125(9):881-890.
- 1110 Heinze BM, Vinck BM, Hofmeyr LM, Swanepoel DW. Vestibular involvement in adults with HIV/AIDS. *Auris Nasus Larynx*. 2013;Oct 19. pii: S0385-8146(13)00181-8.
- 1111 Mody GM, Parke FA, Reveille JD. Articular manifestations of human immunodeficiency virus infection. *Best Pract Res Clin Rheumatol*. 2003;17:265-287.
- 1112 Patel N, Patel N, Espinoza LR. HIV infection and rheumatic diseases: the changing spectrum of clinical enigma. *Rheum Dis Clin North Am*. 2009;35:139-161.
- 1113 Louthrenoo W. Rheumatic manifestations of human immunodeficiency virus infection. *Curr Opin Rheumatol*. 2008;20:92-99.
- 1114 Rodriquez-Mahou M, Lopez-Longo J, Lapointe N, et al. Autoimmune phenomena in children with human immunodeficiency virus infection and acquired immunodeficiency syndrome. *Acta Paediatr Suppl*. 1994;400:31-34.

- 
- 1115 Dimitrakopoulos AN, Kordossis T, Hatzakis A, Moutsopoulos HM. Mixed cryoglobulinemia in HIV-1 infection: the role of HIV-1. *Ann Intern Med.* 1999;130:226-230.
- 1116 Caponetti G, Dezube BJ, Restrepo CS, Pantanowitz L. Kaposi sarcoma of the musculoskeletal system: a review of 66 patients. *Cancer.* 2007;109:1040-1052.
- 1117 McGonagle D, Reade S, Marzo-Ortega H, et al. Human immunodeficiency virus associated spondyloarthropathy: pathogenic insights based on imaging findings and response to highly active antiretroviral therapy. *Ann Rheum Dis.* 2001;60:696-698.
- 1118 Zalavras CG, Gupta N, Patzakis MJ, Holtom PD. Microbiology of osteomyelitis in patients infected with the human immunodeficiency virus. *Clin Orthop Relat Res.* 2005;439:97-100.
- 1119 Hirsch R, Miller SM, Kazi S, Cate TR, Reveille JD. Human immunodeficiency virus-associated atypical mycobacterial skeletal infections. *Semin Arthritis Rheum.* 1996;25:347-356.
- 1120 Morse CG, Mican JM, Jones EC, Joe GO, Rick ME, Formentini E, Kovacs JA. The incidence and natural history of osteonecrosis in HIV-infected adults. *Clin Infect Dis.* 2007;44:739-748.
- 1121 Allison GT, Bostrom MP, Glesby MJ. Osteonecrosis in HIV disease: epidemiology, etiologies, and clinical management. *AIDS.* 2003;17:1-9.
- 1122 Mahoney CR, Glesby MJ, DiCarlo EF, Peterson MG, Bostrom MP. Total hip arthroplasty in patients with human immunodeficiency virus infection: pathologic findings and surgical outcomes. *Acta Orthop.* 2005;76:198-203.
- 1123 Panayiotopoulos A, Bhat N, Bhangoo A. Bone and vitamin D metabolism in HIV. *Rev Endocr Metab Disord.* 2013;14:119-125.
- 1124 Casado E, Olive A, Holgado S, et al. Musculoskeletal manifestations in patients positive for human immunodeficiency virus: correlation with CD4 count. *J Rheumatol.* 2001;28:802-804.
- 1125 Sing Y, Ramdial PK. Cryptococcal inflammatory pseudotumors. *Am J Surg Pathol.* 2007;31:1521-1527.
- 1126 Calabrese LH, Kirchner E, Shrestha R. Rheumatic complications of human immunodeficiency virus infection in the era of highly active antiretroviral therapy: emergence of a new syndrome of immune reconstitution and changing patterns of disease. *Semin Arthritis Rheum.* 2005;35:166-174.

- 
- 1127 Baughman RP, Strohofer SS, Glinton BA, Nickol AD, Frame PT. The use of an indirect fluorescent antibody test for detecting *Pneumocystis carinii*. *Arch Pathol Lab Med*. 1989;113:1062-1065.
- 1128 Sheehan MM, Coker R, Coleman DV. Detection of cytomegalovirus (CMV) in HIV+ patients: comparison of cytomorphology, immunocytochemistry, and in situ hybridization. *Cytopathology*. 1998;9:29-37.
- 1129 Nayak S, Mani R, Kavatkar AN, Puranik SC, Holla VV. Fine-needle aspiration cytology in lymphadenopathy of HIV-positive patients. *Diagn Cytopathol*. 2003;29:146-148.
- 1130 D'Angelo LJ. Adolescents and HIV infection: a clinician's perspective. *Acta Paediatr Suppl*. 1994;400:88-94.
- 1131 The Working Group on Mother-to-Child Transmission of HIV. Rates of mother-to-child transmission of HIV-1 in Africa, America, and Europe: results from 13 perinatal studies. *J Acquir Immune Defic Syndr Hum Retrovirol*. 1995;8:506-510.
- 1132 Duliege AM, Amos CI, Felton S, Biggar RJ, Goedert JJ. Birth order, delivery route, and concordance in the transmission of human immunodeficiency virus type 1 from mothers to twins. *J Pediatr*. 1995;126:625-632.
- 1133 Blanche S, Mayaux MJ, Rouzioux C, Teglas JP, Firtion G, Monpoux F, et al. Relation of the course of HIV infection in children to the severity of the disease in their mothers at delivery. *N Engl J Med*. 1994;330:308-312.
- 1134 Feiterna-Sperling C, Weizsaecker K, Bühner C, Casteleyn S, Loui A, Schmitz T, Wahn V, Obladen M. Hematologic effects of maternal antiretroviral therapy and transmission prophylaxis in HIV-1-exposed uninfected newborn infants. *J Acquir Immune Defic Syndr*. 2007;45:43-51.
- 1135 Wilfert CM, Wilson C, Luzuriaga K, Epstein L. Pathogenesis of pediatric human immunodeficiency virus type 1 infection. *J Infect Dis*. 1994;170:286-292.
- 1136 Mayaux MJ, Burgard M, Teglas JP, et al. Neonatal characteristics in rapidly progressive perinatally acquired HIV-1 disease. *JAMA*. 1996;275:606-610.
- 1137 Ofori-Mante JA, Kaul A, Rigaud M, Fidelia A, Rochford G, Krasinski K, Chandwani S, Borkowsky W. Natural history of HIV infected pediatric long-term or slow progressor population after the first decade of life. *Pediatr. Infect. Dis. J*. 2007;26:217-220.

- 
- 1138 Arpadi SM. Growth failure in children with HIV infection. *J Acquir Immune Defic Syndr*. 2000;25(Suppl 1):S37-S42.
- 1139 Nicholas SW. The opportunistic and bacterial infections associated with pediatric human immunodeficiency virus disease. *Acta Paediatr Suppl*. 1994;400:46-50.
- 1140 Katan M, Platzker A, Mellins RB, et al. Respiratory diseases in the first year of life in children born to HIV-1-infected women. *Pediatr Pulmonol*. 2001;31:267-276.
- 1141 Goussard P, Kling S, Gie RP, Nel ED, Heyns L, Rossouw GJ, Janson JT. CMV pneumonia in HIV-infected ventilated infants. *Pediatr Pulmonol*. 2010;45(7):650-655.
- 1142 Graham SM, Gibb DM. HIV disease and respiratory infection in children. *Br Med Bull*. 2002;61:133-150.
- 1143 Weber HC, Gie RP, Cotton MF. The challenge of chronic lung disease in HIV-infected children and adolescents. *J Int AIDS Soc*. 2013 Jun 18;16:18633. doi: 10.7448/IAS.16.1.18633.
- 1144 Calligaro GL, Gray DM. Lung function abnormalities in HIV-infected adults and children. *Respirology*. 2015;20(1):24-32.
- 1145 Chiriboga CA, Fleishman S, Champion S, Gaye-Robinson L, Abrams EJ. Incidence and prevalence of HIV encephalopathy in children with HIV infection receiving highly active anti-retroviral therapy (HAART). *J Pediatr*. 2005;146:402-407.
- 1146 Dickson DW, Llena JF, Nelson SJ, Weidenheim KM. Central nervous system pathology in pediatric AIDS. *Ann N Y Acad Sci*. 1993;693:93-106.
- 1147 Burns DK. The neuropathology of pediatric acquired immunodeficiency syndrome. *J Child Neurol*. 1992;7:332-346.
- 1148 dos Santos Pinheiro R, França TT, Ribeiro CM, Leão JC, de Souza IP, Castro GF. Oral manifestations in human immunodeficiency virus infected children in highly active antiretroviral therapy era. *J Oral Pathol Med*. 2009;38:613-622.
- 1149 Biggar RJ, Frisch M, Goedert JJ. Risk of cancer in children with AIDS. *JAMA*. 2000;284:205-209.
- 1150 Hussein K, Rath B, Ludewig B, Kreipe H, Jonigk D. Clinico-pathological characteristics of different types of immunodeficiency-associated smooth muscle tumours. *Eur J Cancer*. 2014;50(14):2417-2424.

- 
- 1151 McClain KL, Leach CT, Jenson HB, Joshi VV, Pollock BH, Parmley RT, DiCarlo FJ, et al. Association of Epstein-Barr virus with leiomyosarcomas in young people with AIDS. *N Engl J Med*. 1995;332:12-18.
- 1152 Joshi VV, Pawel B, Conner E, et al. Arteriopathy in children with acquired immune deficiency syndrome. *Pediatr Pathol*. 1987;7:261-275.
- 1153 Perez-Atayde AR, Kearney DI, Bricker JT, et al. Cardiac, aortic, and pulmonary arteriopathy in HIV-infected children: the Prospective P2C2 HIV Multicenter Study. *Pediatr Dev Pathol*. 2004;7:61-70.
- 1154 Dubrovsky T, Curless R, Scott G, et al. Cerebral aneurysmal arteriopathy in childhood AIDS. *Neurology*. 1998;51:560-565.
- 1155 Mazzoni P, Chiriboga CA, Millar WS, Rogers A. Intracerebral aneurysms in human immunodeficiency virus infection: case report and literature review. *Pediatr Neurol*. 2000;23:252-255.
- 1156 Bhimma R, Purswani MU, Kala U. Kidney disease in children and adolescents with perinatal HIV-1 infection. *J Int AIDS Soc*. 2013 Jun 18;16:18596. doi: 10.7448/IAS.16.1.18596.
- 1157 McCulloch MI, Ray PE. Kidney disease in HIV-positive children. *Semin Nephrol*. 2008;28:585-594.
- 1158 Ye P, Kirschner DE, Kourtis AP. The thymus during HIV disease: role in pathogenesis and in immune recovery. *Curr HIV Res*. 2004;2:177-183.
- 1159 Kotloff KL, Johnson JP, Nair P, Hickman D, Lippincott P, Wilson D, Clemens JD. Diarrheal morbidity during the first 2 years of life among HIV-infected infants. *JAMA*. 1994;271:448-452.
- 1160 Krause JC, Toye MP, Stechenberg BW, Reiter EO, Allen HF. HIV--associated lipodystrophy in children. *Pediatr Endocrinol Rev*. 2005;3:45-51.
- 1161 Leonard EG, McComsey GA. Metabolic complications of antiretroviral therapy in children. *Pediatr Inf Dis J*. 2003;22:77-84.
- 1162 Haller JO, Cohen HL. Gastrointestinal manifestations of AIDS in children. *AJR Am J Roentgenol*. 1994;162:387-393.
- 1163 American College of Physicians. Human immunodeficiency virus (HIV) infection: position paper. *Ann Intern Med*. 1994;120:310-319.

- 
- 1164 Kelen GD, Green GB, Purcell RH, Chan DW, Qaish BF, Sivertson KT, Quinn TC. Hepatitis B and hepatitis C in emergency department patients. *N Engl J Med*. 1992;326:1399-1404.
- 1165 Clark SJ, Kelen GD, Henrard DR, Daar ES, Craig S, Shaw GM, Quinn TC. Unsuspected primary human immunodeficiency virus type 1 infection in seronegative emergency department patients. *J Infect Dis*. 1994;170:194-197.
- 1166 Gerberding JL. Occupational exposure to HIV in health care settings. *N Engl J Med*. 2003; 348:826-833.
- 1167 Henderson DK. Management of needlestick injuries: a house officer who has a needlestick. *JAMA*. 2012 ;307:75-84.
- 1168 Klatt EC. Surgery and human immunodeficiency virus infection: indications, pathologic findings, risks, and risk prevention. *Int Surg*. 1994;79:1-5.
- 1169 Panlilio AL, Shapiro CN, Schable CA, Mendelson MH, Montecalvo MA, Kunches LM, Perry SW 3rd, et al. Serosurvey of human immunodeficiency virus infection among hospital-based surgeons. *J Am Coll Surg*. 1995;180:16-24.
- 1170 Goodman RA, Jenkins EL, Mercy JA. Workplace-related homicide among health care workers in the United States, 1980 through 1990. *JAMA*. 1994;272:1686-1688.
- 1171 Department of Labor, Occupational Safety and Health Administration. Occupational exposure to bloodborne pathogens: final rule. *Federal Register*. December 6, 1991;64004-64182 (29 CFR § 1910.1030).
- 1172 Hart PD. Complying with the bloodborne pathogen standard: protecting health care workers and patients. *AORN J*. 2011;94:393-399.
- 1173 Centers for Disease Control. Guidelines for preventing the transmission of tuberculosis in health-care facilities, 1994. *MMWR*. 1994;43(RR-13):1-144.
- 1174 Kramer A, Schwebke I, Kampf G. How long do nosocomial pathogens persist on inanimate surfaces? *BMC Infectious Diseases*. 2006;6:130-138.
- 1175 Terpstra FG, van den Blink AE, Bos LM, Boots AG, Brinkhuis FH, Gijzen E, van Remmerden Y, et al. Resistance of surface-dried virus to common disinfection procedures. *J Hosp Infect*. 2007;66:332-338.
- 1176 Sattar SA, Springthorpe VS. Survival and disinfectant inactivation of the human immunodeficiency virus: a critical review. *Rev Infect Dis*. 1991;13:430-447.



- 
- 1177 Tierno PM Jr. Preventing acquisition of human immunodeficiency virus in the laboratory: safe handling of AIDS specimens. *Lab Medicine*. 1986;17:696-698.
- 1178 Orloff SL, Wallinford JC, McDougal JS. Inactivation of human immunodeficiency virus type 1 in human milk: effects of intrinsic factors in human milk and of pasteurization. *J Human Lactation*. 1993;9:13-17.
- 1179 Guertler L. Virus safety of human blood, plasma, and derived products. *Thromb Res*. 2002;107 Suppl 1:S39-45.
- 1180 Cohen MS, Gay C, Kashuba AD, Blower S, Paxton L. Narrative review: antiretroviral therapy to prevent the sexual transmission of HIV-1. *Ann Intern Med*. 2007;146:591-601.
- 1181 Roland ME. Postexposure prophylaxis after sexual exposure to HIV. *Curr Opin Infect Dis*. 2007;20:39-46.
- 1182 Mischke C, Verbeek JH, Saarto A, Lavoie MC, Pahwa M, Ijaz S. Gloves, extra gloves or special types of gloves for preventing percutaneous exposure injuries in healthcare personnel. *Cochrane Database Syst Rev*. 2014 Mar 7;3:CD009573.
- 1183 Panlilio AL, Foy DR, Edwards JR, Bell DM, Welch BA, Parrish CM, et al. Blood contacts during surgical procedures. *JAMA*. 1991;265:1533-1537.
- 1184 Tokars JJ, Bell DM, Culver DH, et al. Percutaneous injuries during surgical procedures. *JAMA*. 1992;267:2899-2904.
- 1185 Fry DE. Occupational risks of blood exposure in the operating room. *Am Surg*. 2007;73:637-46.
- 1186 Kelen GD, DiGiovanna TA, Celentino DD, et al. Adherence to universal (barrier) precautions during interventions on critically ill and injured emergency department patients. *J Acquir Immune Defic Syndr*. 1990;3:987-994.
- 1187 Davison SP, Reisman NR, Pellegrino ED, Larson EE, Dermody M, Hutchison PJ. Perioperative guidelines for elective surgery in the human immunodeficiency virus-positive patient. *Plast Reconstr Surg*. 2008;121:1831-1840.
- 1188 Deneve JL, Shantha JG, Page AJ, Wyrzykowski AD, Rozycki GS, Feliciano DV. CD4 count is predictive of outcome in HIV-positive patients undergoing abdominal operations. *Am J Surg*. 2010;200:694-649.
- 1189 CAP AIDS Task Force. Planning reduces transmission risk in surgical pathology. *CAP Today*. 1990;4(1):24,26.

- 
- 1190 Klatt EC, Noguchi TT. The medical examiner and AIDS: death certification, safety procedures, and future medicolegal issues. *Am J Forensic Med Pathol*. 1988;9:141-148.
- 1191 DeGroot-Kosolcharoen J, Jones JM. Permeability of latex and vinyl gloves to water and blood. *Am J Infect Control*. 1989;17:196-201.
- 1192 Burton JL. Health and safety at necropsy. *J Clin Pathol*. 2003;56:254-260.
- 1193 Klatt EC, Noguchi TT. AIDS and infection control in forensic investigation. *Am J Forensic Med Pathol*. 1990;11:44-49.
- 1194 Clem KL, Borchers JR. HIV and the athlete. *Clin Sports Med*. 2007;26:413-424.
- 1195 Pirozzolo JJ, LeMay DC. Blood-borne infections. *Clin Sports Med*. 2007;26:425-341.
- 1196 Kordi R, Wallace WA. Blood borne infections in sport: risks of transmission, methods of prevention, and recommendations for hepatitis B vaccination, *Br J Sports Med*. 2004;38:678-684
- 1197 Schöffl V, Morrison A, Küpper T. Risk of transmission of blood borne infections in climbing--consensus statement of UIAA Medcom. *Int J Sports Med*. 2011;32:170-173.
- 1198 Shephard RJ. Exercise, immune function, and HIV infection. *J Sports Med Phys Fitness*. 1998;38:101-110.
- 1199 Brown LS Jr, Phillips RY, Brown CL Jr, Knowlan D, Castle L, Moyer J. HIV/AIDS policies and sports: the National Football League. *Med Sci Sports Exerc*. 1994;26:403-407.
- 1200 Schöffl V, Morrison A, Küpper T. Risk of transmission of blood borne infections in climbing--consensus statement of UIAA Medcom. *Int J Sports Med*. 2011;32:170-173.
- 1201 American Medical Society for Sports Medicine. Joint position statement: human immunodeficiency virus and other blood-borne pathogens in sports. *Clin J Sports Med*. 1995;5:199-204.
- 1202 American Academy of Pediatrics. Human immunodeficiency virus and other blood-borne viral pathogens in the athletic setting. Committee on Sports Medicine and Fitness. *Pediatrics*. 1999;104:1400-1403.
- 1203 Klatt EC, Shibata D, Strigle SM. Postmortem enzyme immunoassay for human immunodeficiency virus antibody. *Arch Pathol Lab Med*. 1989;113:485-487.

- 
- 1204 Karhunen PJ, Brummer-Korvenkontio H, Leinikki P, Nyberg M. Stability of human immunodeficiency virus (HIV) antibodies in postmortem samples. *J Forensic Sci.* 1994;39:129-135.
- 1205 Krentz HB, Kliwer G, Gill MJ. Changing mortality rates and causes of death for HIV-infected individuals living in Southern Alberta, Canada from 1984 to 2003. *HIV Med.* 2005;6:99-106.
- 1206 Lucas S. Causes of death in the HAART era. *Curr Opin Infect Dis.* 2012;25:36-41.
- 1207 Antiretroviral Therapy Cohort Collaboration. Causes of death in HIV-1-infected patients treated with antiretroviral therapy, 1996-2006: collaborative analysis of 13 HIV cohort studies. *Clin Infect Dis.* 2010;50:1387-1396.
- 1208 Mocroft A, Reiss P, Gasiorowski J, Ledergerber B, Kowalska J, Chiesi A, Gatell J, et al; EuroSIDA Study Group. Serious fatal and nonfatal non-AIDS-defining illnesses in Europe. *J Acquir Immune Defic Syndr.* 2010;55:262-270.
- 1209 Beadsworth MB, Cohen D, Ratcliffe L, Jenkins N, Taylor W, Campbell F, Beeching NJ, Azadeh B. Autopsies in HIV: still identifying missed diagnoses. *Int J STD AIDS.* 2009;20:84-86.
- 1210 Klatt EC, Noguchi TT. Death certification: purposes, procedures, and pitfalls. *West J Med.* 1989;151:345-347.
- 1211 Gostin LO, Webber DW. HIV infection and AIDS in the public health and health care systems. *JAMA.* 1998;279:1108-1113.
- 1212 Halevy A, Brody A. Acquired immunodeficiency syndrome and the Americans with Disabilities Act: a legal duty to treat. *Am J Med.* 1994;96:282-291.
- 1213 Centers for Disease Control. Recommendations for preventing transmission of human immunodeficiency virus (HIV) and hepatitis B virus (HBV) to patients during exposure-prone invasive procedures. *MMWR.* 1991;40(RR-8):1-9.
- 1214 Deuffic-Burban S, Delarocque-Astagneau E, Abiteboul D, Bouvet E, Yazdanpanah Y. Blood-borne viruses in health care workers: prevention and management. *J Clin Virol.* 2011;52:4-10.
- 1215 Phillips KA, Lowe RA, Kahn JG, Lurie P, Avins AL, Ciccarone D. The cost-effectiveness of HIV testing of physicians and dentists in the United States. *JAMA.* 1993;271:851-858.
- 1216 Head KC, Bradley-Springer L, Sklar D. The HIV-infected health care worker: legal, ethical, and scientific perspectives. *J Emerg Med.* 1994;12:95-102.

- 
- 1217 Owens DK, Harris RA, Scott PMcJ, Nease RF Jr. Screening surgeons for HIV infection: a cost-effectiveness analysis. *Ann Intern Med.* 1995;122:641-652.
- 1218 Centers for Disease Control and Prevention. HIPAA Privacy Rule and Public Health: Guidance from CDC and the U.S. Department of Health and Human Services. *MMWR.* 2003;52(Sup1):1-24.
- 1219 Centers for Disease Control and Prevention. Revised guidelines for HIV counseling, testing, and referral. *MMWR.* 2001;50(RR-19):1-57.
- 1220 Kasten MJ. Human immunodeficiency virus: the initial physician-patient encounter. *Mayo Clin Proc.* 2002;77:957-962.
- 1221 Kendrick SR, Kroc KA, Withum D, Rydman RJ, Branson BM, Weinstein RA. Outcomes of offering rapid point-of-care HIV testing in a sexually transmitted disease clinic. *J Acquir Immune Defic Syndr.* 2005;38:142-146.
- 1222 Whyte GS, Savoia HF. The risk of transmitting HCV, HBV, or HIV by blood transfusion in Victoria. *Med J Aust.* 1997;166:584-586.
- 1223 Glynn SA, Kleinman SH, Schreiber GB, et al. Trends in incidence and prevalence of major transfusion-transmissible viral infections in US blood donors, 1991 to 1996. *JAMA.* 2000;284:229-235.
- 1224 Jayaraman S, Chalabi Z, Perel P, Guerriero C, Roberts I. The risk of transfusion-transmitted infections in sub-Saharan Africa. *Transfusion.* 2010;50:433-442.
- 1225 Takei T, Amin NA, Schmid G, Dhingra-Kumar N, Rugg D. Progress in global blood safety for HIV. *J Acquir Immune Defic Syndr.* 2009;52(Suppl 2):S127-131.
- 1226 Centers for Disease Control. Testing for antibodies to HIV type 2 in the United States. *MMWR.* 1992;41[RR-12]:1-9.
- 1227 Stramer SL, Glynn SA, Kleinman SH, et al. Detection of HIV-1 and HCV infections among antibody-negative blood donors by nucleic acid-amplification testing. *N Engl J Med.* 2004;351:760-768.
- 1228 Jackson BR, Busch MP, Stramer SL, AuBuchon JP. The cost-effectiveness of NAT for HIV, HCV, and HBV in whole-blood donations. *Transfusion.* 2003;43:721-729.

- 
- 1229 Litvak E, Siegel JE, Pauker SG, Lallemand M, Fineberg HV, Weinstein MC. Whose blood is safer? The effect of the stage of the epidemic on screening for HIV. *Med Decis Making*. 1997;17:455-463.
- 1230 Urwijitaroon Y, Barusrux S, Romphruk A, Puapairoj C, Pakote L. Reducing the risk of HIV transmission through blood transfusion by donor self-referral. *Southeast Asian J Trop Med Public Health*. 1996;27:452-456.
- 1231 Pink J, Thomson A, Wylie B. Infectious disease markers in autologous and directed donations. *Transfus Med*. 1994;4:135-138.
- 1232 Burnouf T. Modern plasma fractionation. *Transfus Med Rev*. 2007;21:101-117.
- 1233 Bierig JR. Legal issues for blood banks. *Arch Pathol Lab Med*. 1994;118:442-453.
- 1234 Collier AC, Kalish LA, Busch MP, et al. Leukocyte-reduced red blood cell transfusions in patients with anemia and human immunodeficiency virus infection. *JAMA*. 2001;285:1592-1601.
- 1235 Yao F, Seed C, Farrugia A, Morgan D, Cordner S, Wood D, Zheng MH. The risk of HIV, HBV, HCV and HTLV infection among musculoskeletal tissue donors in Australia. *Am J Transplant*. 2007;7:2723-2726.
- 1236 Ahn J, Cohen SM. Transmission of human immunodeficiency virus and hepatitis C virus through liver transplantation. *Liver Transpl*. 2008;14:1603-1608.
- 1237 Centers for Disease Control. Guidelines for preventing transmission of human immunodeficiency virus through transplantation of human tissues and organs. *MMWR*. 1994;43(RR-8):1-17.
- 1238 Simonds RJ. HIV transmission by organ and tissue transplantation. *AIDS*. 1993;7(Suppl 2):S35-S38.
- 1239 Smith RA, Ingels J, Lochemes JJ, Dutkowsky JP, Pifer LL. Gamma irradiation of HIV-1. *J Orthop Res*. 2001;19:815-819.